



# Ultrasound and Magnetic Resonance Imaging Diagnosis for Rotator Cuff Tears: Does Acromial Morphology Affect the Results?

## *Diagnóstico de roturas del manguito rotador por ecografía y resonancia magnética: ¿La morfología acromial influye en los resultados?*

Patricio Meleán<sup>1,2</sup> Walter Rojas<sup>1</sup> Mauricio Agloni<sup>3</sup> Guillermo Droppelmann<sup>4</sup>

<sup>1</sup>Department of Traumatology and Orthopedics, Shoulder Team, Clínica MEDS, Santiago, Chile

<sup>2</sup>Department of Traumatology and Orthopedics, Shoulder and Elbow Surgery Transversal Coordinator, Red Salud, Chile

<sup>3</sup>Traumatology Unit, Shoulder and Elbow Team, Hospital la Florida, Santiago, Chile

<sup>4</sup>Academic Unit, Clínica MEDS, Santiago, Chile

Address for correspondence Patricio Meleán, Department of Traumatology and Orthopedics, Shoulder Team, Clínica MEDS, Av. Jose Alcalde Delano 10581, Lo Barnechea, Santiago, Chile 7691236 (e-mail: patricio.melean@gmail.com).

Rev Chil Ortop Traumatol 2022;63(2):e77–e82.

### Abstract

**Introduction** Currently, there are no studies that evaluate the agreement between ultrasound (US) and magnetic resonance imaging (MRI) scans in rotator cuff (RC) tears by the observation of parameters such as the acromial index (AI) and critical shoulder angle (CSA). We hypothesize that the greater coverage of the footprint by increased AI or CSA could affect the proper visualization of the RC in US scans by its interposition between the tendinous complex and the US transducer.

**Objective** To estimate the agreement between US and MRI in the diagnosis of patients with RC tears confirmed by arthroscopy and with AI and CSA greater than the normal average values (0.7 and 35° respectively). The secondary objective is to determine if the diagnostic agreement is comparable regarding different types of tear (partial and complete).

**Materials and Methods** A retrospective study of a consecutive case series of 100 patients with partial or complete RC tears confirmed by arthroscopy.

**Results** The mean age of the study group was of 55.7 ± 10.5 years. The mean AI was of 0.77 ± 0.08, and the mean CSA was of 37.42° ± 5.88°. The agreement regarding the US, the MRI and the AI was > 0.7 of 56.7% (K = 0.27; p = 0.01); and < 0.7 of 35.7% (K = 0.01; p = 0.46) respectively. And the agreement regarding the US, the MRI and the CSA was > 35° of 61.5% (K = 0.32; p = 0.001); and < 35° of 33.3% (K = -0.00; p = 0.52) respectively.

### Keywords

- ▶ rotator cuff
- ▶ ultrasound
- ▶ magnetic resonance imaging
- ▶ acromial index
- ▶ critical shoulder angle

received

January 26, 2021

accepted after revision

April 26, 2022

DOI <https://doi.org/10.1055/s-0042-1750094>.

ISSN 0716-4548.

© 2022. Sociedad Chilena de Ortopedia y Traumatología. All rights reserved.

This is an open access article published by Thieme under the terms of the Creative Commons Attribution-NonDerivative-NonCommercial-License, permitting copying and reproduction so long as the original work is given appropriate credit. Contents may not be used for commercial purposes, or adapted, remixed, transformed or built upon. (<https://creativecommons.org/licenses/by-nc-nd/4.0/>)

Thieme Revinter Publicações Ltda., Rua do Matoso 170, Rio de Janeiro, RJ, CEP 20270-135, Brazil

## Resumen

### Palabras Clave

- ▶ manguito rotador
- ▶ ecografía
- ▶ resonancia magnética
- ▶ índice acromial
- ▶ ángulo crítico

**Conclusion** The diagnostic agreement of the US compared with the MRI, in patients with RC tears confirmed by arthroscopy and with AI and CSA greater than the normal average values was fair. The diagnostic agreement of the US compared with the MRI, in patients with AI and CSA lower than the normal average values was poor. The diagnostic performance of the IS and MRI was similar for partial and complete tears.

**Introducción** Actualmente no existen estudios que evalúen la concordancia entre la ecografía (ECO) y la resonancia magnética (RM) observando parámetros como el índice acromial (IA) y el ángulo crítico (AC) para roturas del manguito rotador (MR). Se considera que la mayor cobertura de la huella por un IA o AC incrementados podría afectar la adecuada visualización del MR en estudios de ECO al interponerse entre el complejo tendíneo y el transductor ecográfico.

**Objetivo** Estimar la concordancia de la ECO y la RM en el diagnóstico de pacientes con roturas del MR confirmadas por artroscopia con IA y AC mayores al promedio normal (0.7 y 35°, respectivamente). Secundariamente, determinar si la concordancia diagnóstica es comparable entre tipos de rotura (espesor completo o parciales).

**Materiales y Métodos** Estudio retrospectivo de una serie consecutiva de 100 pacientes con roturas totales o parciales del MR confirmadas por artroscopia.

**Resultados** La edad media del grupo de estudio fue de  $55,7 \pm 10,5$  años. La media del IA fue de  $0,77 \pm 0,08$ , y la del AC, de  $37,42^\circ \pm 5,88^\circ$ . La concordancia entre la ECO y la RM y el IA fue  $> 0,7$  de 56,7% ( $K = 0,27$ ;  $p = 0,01$ );  $< 0,7$  de 35,7% ( $K = 0,01$ ;  $p = 0,46$ ), respectivamente. Y la concordancia entre la ECO y la RM y el AC fue  $> 35^\circ$  de 61,5% ( $K = 0,32$ ;  $p = 0,001$ );  $< 35^\circ$  de 33,3% ( $K = -0,00$ ;  $p = 0,52$ ), respectivamente.

**Conclusión** La concordancia diagnóstica de la ECO comparada con la de la RM, en pacientes con roturas del MR confirmada por artroscopia y con IA y AC mayores al promedio normal, fue justa. La concordancia diagnóstica de la ECO comparada con la RM, en pacientes con IA y AC menores al promedio normal, fue pobre. La capacidad diagnóstica fue similar entre la ECO y la RM para roturas parciales y totales.

## Introduction

Rotator cuff (RC) conditions are the most commonly observed by shoulder surgery subspecialists working in outpatient care.<sup>1-4</sup>

The initial diagnosis relies on two pillars: the clinical picture and imaging exams. The main imaging techniques are anteroposterior (AP) radiographs of the shoulder and axial subacromial radiographs. These images enable the analysis of the morphology of the acromion and its influence on the RC condition. They also provide several data on the subacromial space and determine the type of acromion. In addition, radiographs enable the determination of the acromial index (AI, the lateral coverage of the proximal humerus footprint by the acromion) and the critical shoulder angle (CSA, the more lateral angulation of the acromion).<sup>1,2</sup>

The second most requested test is shoulder ultrasound (US), which can detect RC tears with adequate specificity and sensitivity. In addition, it is a dynamic examination that may enable the real-time observation of anterior RC impingement by the acromion.<sup>1,3</sup>

Magnetic resonance imaging (MRI) substantially changed the diagnosis of RC tears. Its diagnostic sensitivity ranges from 80% to 97% for full-thickness RC tears and from 67% to

89% for partial RC tears, rates higher than those traditionally associated with US.<sup>1</sup>

Some studies<sup>5-7</sup> indicate that US has 80.8% of sensitivity and 100% of specificity to detect complete and partial RC tears. When removing partial tears, the sensitivity rises to 94.7%, whereas the specificity remains the same: 100%.<sup>8</sup>

Likewise, Cochrane reviews<sup>9</sup> indicate that US has 91% of sensitivity and 85% of specificity in the detection of RC tears. Magnetic resonance imaging presents 98% of sensitivity and 79% of specificity. These figures show that US and MRI have similar sensitivity and specificity in the identification of RC tears ( $p = 0.13$ ). However, their sensitivity to detect partial tears is lower, especially for US.

No current study determines the level of agreement between imaging techniques (US and MR) while considering acromial morphology and parameters such as the AI and the CSA provided by radiographs.

These measurements conceptually indicate a higher coverage of the supraspinatus and infraspinatus footprint regardless of glenoid inclination. Therefore, a higher footprint coverage resulting from an increased AI or CSA could hinder RC visualization on US because of the interposition of the tendinous complex and the US transducer.

To date, no study has analyzed the diagnostic agreement between US and MRI in arthroscopy-confirmed RC tears in patients with AI or CSA higher or lower than the average values reported in the literature.

## Objectives

The present study aims to estimate the agreement between US and MRI in the the diagnosis of RC tears in patients with injuries confirmed by arthroscopy (gold-standard method) and AI and CSA higher than average values (0.7 and 35° respectively).

A secondary objective is to determine if the diagnostic agreement is comparable between type of tear (full-thickness tear, partial-thickness bursal-sided tear, and partial-thickness articular-sided tear).

## Hypothesis

The agreement between US and MRI in the diagnosis of RC tears is similar in patients with arthroscopy-confirmed injuries with or without increased AI or CSA.

The diagnostic performance is better for partial RC bursal-sided tears in patients with AI or CSA lower than 0.7 and 35° respectively.

## Material and Methods

We conducted a retrospective study of a consecutive series of patients with RC conditions (total or partial tears) confirmed by arthroscopy (gold-standard method) and presenting radiographs, US, and MRI scans of the same affected shoulder obtained within 6 months.

For the calculation of the sample size, we used the two-sample t-test with the mean and standard deviation values reported in the literature on RC tears diagnosed by US and MRI.<sup>1,10-12</sup>

Statistical significance was set at 0.05, with 80% of power and a two-tailed hypothesis test. Each subgroup had 50 subjects, totaling 100 participants.

We used an imaging database (IMPAX, Agfa Healthcare, Mortsel, Belgium) to analyze US and MRI scans, and radiographs from patients with arthroscopy-confirmed RC tears diagnosed from January 2013 to January 2019.

### Inclusion Criteria

1. Arthroscopically-treated RC tears (supraspinatus/infraspinatus) with true AP radiographs, and US and MRI scans obtained within six months.

### Exclusion Criteria

1. Incomplete imaging.
2. Previous history of open or arthroscopic surgery.
3. Functional sequelae or previous traumatic injuries at the region of the ipsilateral shoulder girdle (sternoclavicular dislocations, clavicle fractures, previous acromioclavicular dislocation, scapular or proximal humerus fractures and dislocations).

4. Intrastance RC tears.

5. Shoulder stiffness (preventing proper evaluation using US).

### Radiological Analysis

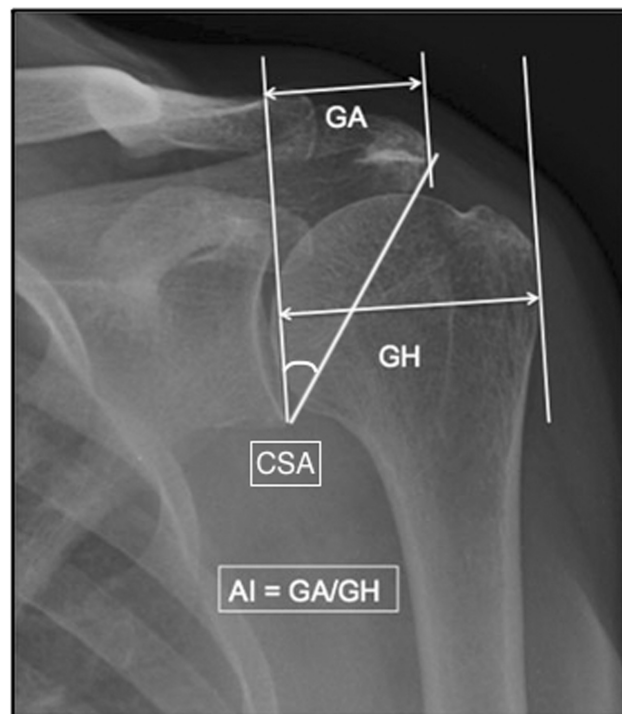
We analyzed digital images from the Picture Archiving and Communication System (PACS):

- (a) The AI according to Nyffeler et al.:<sup>13</sup> on a true AP radiograph, draw a first line connecting the superior and inferior bony margins of the glenoid fossa, representing the articular surface plane. The second and third parallel lines follow the lateral border of the acromion and the most lateral border of the proximal humerus. Measure the distance between the glenoid fossa and the acromion (GA) and from the glenoid fossa to the most lateral border of the proximal humerus (GH). The ratio between these two measurements is the AI (►Figure 1)
- (b) The CSA: on a true AP radiograph, evaluate the angle formed by a cephalic-to-caudal line parallel to the glenoid fossa and a line connecting the inferior and lateral points of the acromion (►Figure 1).

### Statistical Analysis

Pearson tests correlated the AI and CSA findings in healthy RCs and full-thickness, partial bursal-sided, and partial articular-sided RC tears documented by US and MRI. Mann-Whitney tests assessed the AI and CSA values.

The Cohen kappa coefficient determined the agreement between the diagnoses of no tear, partial tear, and full-thickness tear assessed by MRI and US.



**Fig. 1** Acromial index (AI) and critical shoulder angle (CSA) measurements. Abbreviations: GA, distance between the glenoid fossa and the acromion; GH, distance between the glenoid fossa and the most lateral border of the proximal humerus.

### Ethical Approval

The Scientific Ethics Committee for Adult Subjects of the Servicio de Salud Metropolitano Oriente of Santiago, Chile, evaluated and approved this protocol before its implementation.

### Results

The mean age of the study group was of  $55.7 \pm 10.5$  years. The mean values for the AI and CSA were of  $0.77 \pm 0.08$  and  $37.42 \pm 5.88$  respectively. In total, 64.7% of the subjects were male. It is noteworthy that there was a statistically significant difference between patients' age and RC tears ( $p = 0.006$ ).

We evaluated the agreement regarding the diagnoses of no rupture, partial rupture, and total rupture per MRI and US when the AI was higher than 0.7. The agreement rate was of 56.67%, with a kappa coefficient of 0.27 ( $p = 0.01$ ). These figures indicate a fair agreement per the Landis and Koch's<sup>14</sup> interpretation.

Next, we evaluated the agreement regarding no rupture, partial rupture, and total rupture on MRI and US using the Cohen kappa coefficient when the CSA was higher than  $35^\circ$ . With a kappa coefficient of 0.32, the agreement rate was of 61.54% ( $p = 0.001$ ), considered fair according to the Landis and Koch's interpretation.

Similarly, we evaluated the agreement regarding no rupture, partial rupture, and total rupture on MRI and US using the Cohen kappa coefficient when the AI was lower than 0.7. The agreement rate was of 35.71%, with a kappa coefficient of 0.01 ( $p = 0.46$ ). According to Landis and Koch,<sup>14</sup> these figures indicate a poor agreement.

In addition, we assessed the agreement regarding no rupture, partial rupture, and total rupture on MRI and US using the Cohen kappa coefficient when the CSA was lower than  $35^\circ$ . The agreement rate was of 33.33%, with a kappa coefficient of -0.00 ( $p = 0.52$ ), which is deemed poor according to Landis and Koch.

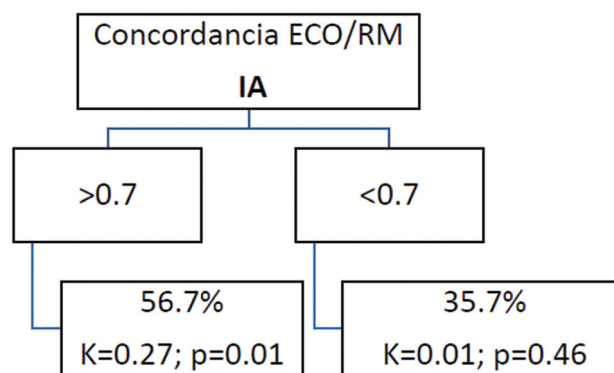
We also determined the agreement regarding no rupture, partial rupture, and total rupture on MRI and US using the Cohen kappa coefficient when the AI was higher than 0.7 and the CSA was higher than  $35^\circ$ . The agreement rate was of 60.87%, with a kappa coefficient of 0.30 ( $p = 0.02$ ), considered fair according to the Landis and Koch's<sup>14</sup> interpretation.

Lastly, we evaluated the agreement regarding no rupture, partial rupture, and total rupture on MRI and US using the Cohen kappa coefficient when the AI was lower than 0.7 and the CSA was lower than  $35^\circ$ . The agreement rate was of 27.27%, with a kappa coefficient of -0.15 ( $p = 0.79$ ). According to the Landis and Koch's<sup>14</sup> interpretation, these figures represent a poor agreement.

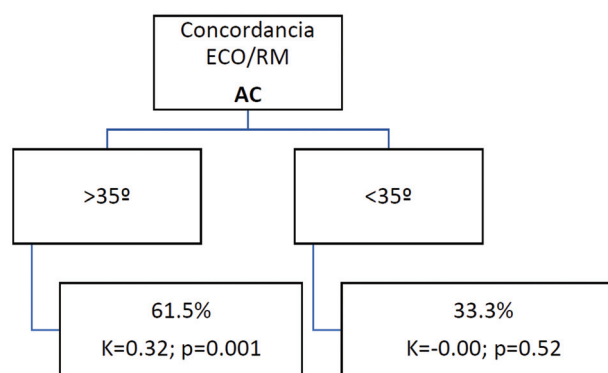
► Figures 2, 3, and 4 summarize these findings.

### Discussion

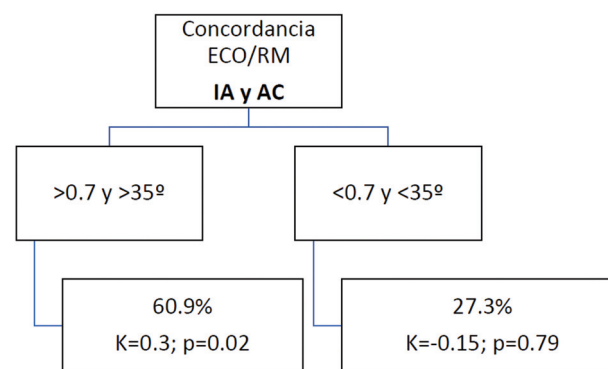
The literature still debates,<sup>1-4,10,15-18</sup> and there is no consensus on the causes of RC tears.



**Fig. 2** Agreement between ultrasound (US) and magnetic resonance imaging (MRI) in cases with acromial index (AI) higher or lower than 0.7. Abbreviations: K, Kappa value;  $p$ , statistical difference. Concordancia ECO/RM = Agreement US/MRI IA = AI



**Fig. 3** Agreement between ultrasound (US) and magnetic resonance imaging (MRI) in cases with critical shoulder angle (CSA) higher or lower than  $35^\circ$ . Abbreviations: K, Kappa value;  $p$ , statistical difference. Concordancia ECO/RM = Agreement US/MRI AC = CSA



**Fig. 4** Agreement between ultrasound (US) and magnetic resonance imaging (MRI) in cases with acromial index (AI) and critical shoulder angle (CSA) higher or lower than 0.7 and  $35^\circ$  respectively. Abbreviations: K, Kappa value;  $p$ , statistical difference. Concordancia ECO/RM = Agreement US/MRI IA y AC = AI and CSA > 0.7 y >  $35^\circ$  = > 0.7 and >  $35^\circ$  < 0.7 y <  $35^\circ$  = < 0.7 and <  $35^\circ$

Some authors<sup>18–20</sup> have comprehensibly discussed the interference of intrinsic factors; this RC damage theory states that tendon degeneration in older patients is the primary cause of the rupture.

Other authors<sup>11,12,21</sup> favor an extrinsic theory for RC injury, in which RC tendons are chronically damaged by subacromial impingement, mainly in the anterior and lateral areas of the acromion.

Neer<sup>22</sup> stated that chronic impingement below the acromion causes 95% of RC tears. Classically, many authors<sup>13,23</sup> have investigated the acromial morphology and its influence on RC tears, analyzing the shape of the acromion, the anterior tilt, the lateral acromial angle, and the lateral coverage of the acromion over the humeral head.

Nyffeler et al.<sup>13</sup> compared 105 patients with full-thickness RC tears, 47 age-matched patients with shoulder osteoarthritis and intact RC, and 70 age-matched volunteers with intact RCs (determined by US). They<sup>13</sup> detected significant differences in the lateral AI in patients with RC tears versus the control group and reported the increased AI as a cause of RC tears.

Zumstein et al.<sup>24</sup> studied a cohort of patients undergoing RC repair and found a higher AI in patients with recurring ruptures. These authors<sup>24</sup> evidenced that a lateral acromial extension can be a risk factor for RC tears and retears, mainly due to the deltoid function secondary to an upward vector force on the humeral head. This force would pinch the acromion, causing chronic degenerative damage and RC tear.<sup>25,26</sup>

Moor et al.<sup>27</sup> introduced the concept of CSA in 2013. In their casuistry, the association between angles higher than 35° and RC tears was more frequent.

To analyze the diagnostic ability of US in RC tears, Teefey et al.<sup>28</sup> conducted a prospective study of 71 consecutive cases comparing US, MRI, and arthroscopy (gold-standard method). They documented that US and MRI have comparable diagnostic ability to identify and measure partial-thickness and full-thickness RC tears.

We hypothesized that the higher footprint coverage due to an increased AI or CSA could hinder RC visualization on US due to the interposition of the tendinous complex and the US transducer.

Our findings demonstrated the opposite. Increased AI and CSA alone presented a fair agreement on US and MRI; when both parameters were higher in the same subject, the agreement remained fair.

We concluded that lower AI and CSA, either alone or combined, resulted in poor agreement in all points evaluated.

The reason for our findings remains unknown. It is probably secondary to an inadequate US evaluation of the medialized lateral acromial edge or an altered geometry that reduced the technical quality of the assessment of the region of the footprint.

The weaknesses of our study include the retrospective data collection and the fact that the AI and CSA were measured in radiographs taken by three different evaluators. There was no previous intra- or interobserver analysis, which may have affected the results described. We did not

analyze shoulder mobility at the time of US, so the acromial deprojection may not have been optimal to adequately visualize the RC tendon.

Further studies are required to evaluate these parameters to validate our findings and better understand the descriptions previously made.

## Conclusion

The diagnostic agreement between US and MRI in patients with arthroscopy-confirmed RC tears and AI and CSA higher-than-average was fair. The diagnostic agreement between US and MRI in patients with arthroscopy-confirmed RC tears and lower-than-average AI and CSA was poor. The diagnostic ability of the MRI and US was similar for partial and total tears.

## References

- Pfalzer F, Endeled D, Huth J, Bauer G, Mauch F. Clinical and MRI results after arthroscopic rotator cuff repair using the double-row technique. A consecutive study. [Klinische und magnetresonanztomographische Ergebnisse nach arthroskopischer Rotatorenmanschettenrekonstruktion in "Double-row"-Technik. Eine serielle Studie]. *Obere Extremität* 2011;6(04):267–274. Doi: 10.1007/s11678-011-0117-1
- Papadopoulos P, Karataglis D, Boutsiadis A, Fotiadou A, Christoforidis J, Christodoulou A. Functional outcome and structural integrity following mini-open repair of large and massive rotator cuff tears: a 3–5 year follow-up study. *J Shoulder Elbow Surg* 2011; 20(01):131–137
- Hanusch BC, Goodchild L, Finn P, Rangan A. Large and massive tears of the rotator cuff: functional outcome and integrity of the repair after a mini-open procedure. *J Bone Joint Surg Br* 2009;91(02):201–205. Doi: 10.1302/0301-620X.91B2.21286
- Cummins CA, Murrell GAC. Mode of failure for rotator cuff repair with suture anchors identified at revision surgery. *J Shoulder Elbow Surg* 2003;12(02):128–133. Doi: 10.1067/mse.2003.21
- Jacobson JA, Lancaster S, Prasad A, van Holsbeeck MT, Craig JG, Kolowich P. Full-Thickness and Partial-Thickness Supraspinatus Tendon Tears: Value of US Signs in Diagnosis. *Radiology* 2004;230(01):234–242
- Fang Zheng et al. Role of Ultrasound in the Detection of Rotator-Cuff Syndrome: An Observational Study. *Med Sci Monit* 2019; 25:5856–5863
- Okorooha KR, Mehran N, Duncan J, Washington T, Spiering T, Bey MJ, Moutzouros V. Characterization of Rotator Cuff Tears: Ultrasound Versus Magnetic Resonance Imaging. *Orthopedics* 2016;40(01):e124–e130
- Gilat R, Atoun E, Cohen O, et al. Recurrent rotator cuff tear: is ultrasound imaging reliable? *J Shoulder Elbow Surg* 2018;27(07): 1263–1267. Doi: 10.1016/j.jse.2017.12.017
- Lenza M, Buchbinder R, Takwoingi Y, Johnston RV, Hanchard NC, Faloppa F. Magnetic resonance imaging, magnetic resonance arthrography and ultrasonography for assessing rotator cuff tears in people with shoulder pain for whom surgery is being considered. *Cochrane Database Syst Rev* 2013;9(09):CD009020. Doi: 10.1002/14651858.CD009020.pub2
- Kluger R, Bock P, Mittlböck M, Krampla W, Engel A. Long-term survivorship of rotator cuff repairs using ultrasound and magnetic resonance imaging analysis. *Am J Sports Med* 2011;39(10): 2071–2081. Doi: 10.1177/0363546511406395
- Harrison AK, Flatow EL. Subacromial impingement syndrome. *J Am Acad Orthop Surg* 2011;19(11):701–708. Doi: 10.5435/00124635-201111000-00006



- 12 Papadonikolakis A, McKenna M, Warme W, Martin BI, Matsen FA III. Published evidence relevant to the diagnosis of impingement syndrome of the shoulder. *J Bone Joint Surg Am* 2011;93(19):1827–1832. Doi: 10.2106/jbjs.j.01748
- 13 Nyffeler RW, Werner CM, Sukthankar A, Schmid MR, Gerber C. Association of a large lateral extension of the acromion with rotator cuff tears. *J Bone Joint Surg Am* 2006;88(04):800–805. Doi: 10.2106/JBJS.D.03042
- 14 Landis JR, Koch GG. The measurement of observer agreement for categorical data. *Biometrics* 1977 Mar;33(01):159–174
- 15 Miller BS, Downie BK, Kohlen RB, et al. When do rotator cuff repairs fail? Serial ultrasound examination after arthroscopic repair of large and massive rotator cuff tears. *Am J Sports Med* 2011;39(10):2064–2070. Doi: 10.1177/0363546511413372
- 16 Cho NS, Lee BG, Rhee YG. Arthroscopic rotator cuff repair using a suture bridge technique: is the repair integrity actually maintained? *Am J Sports Med* 2011;39(10):2108–2116. Doi: 10.1177/0363546510397171
- 17 Denard PJ, Burkhart SS. Techniques for managing poor quality tissue and bone during arthroscopic rotator cuff repair. *Arthroscopy* 2011;27(10):1409–1421. Doi: 10.1016/j.arthro.2011.05.015
- 18 Laron D, Samagh SP, Liu X, Kim HT, Feeley BT. Muscle degeneration in rotator cuff tears. *J Shoulder Elbow Surg* 2012;21(02):164–174. Doi: 10.1016/j.jse.2011.09.027
- 19 Kang JR, Gupta R. Mechanisms of fatty degeneration in massive rotator cuff tears. *J Shoulder Elbow Surg* 2012;21(02):175–180. Doi: 10.1016/j.jse.2011.11.017
- 20 Kolbe AB, Collins MS, Sperling JW. Severe atrophy and fatty degeneration of the infraspinatus muscle due to isolated infraspinatus tendon tear. *Skeletal Radiol* 2012;41(01):107–110. Doi: 10.1007/s00256-011-1265-5
- 21 Garofalo R, Karlsson J, Nordenson U, Cesari E, Conti M, Castagna A. Anterior-superior internal impingement of the shoulder: an evidence-based review. *Knee Surg Sports Traumatol Arthrosc* 2010;18(12):1688–1693. Doi: 10.1007/s00167-010-1232-z
- 22 Neer CS II. Anterior acromioplasty for the chronic impingement syndrome in the shoulder: a preliminary report. *J Bone Joint Surg Am* 1972;54(01):41–50
- 23 Bigliani LU, Ticker JB, Flatow EL, Soslowsky LJ, Mow VC. The relationship of acromial architecture to rotator cuff disease. *Clin Sports Med* 1991;10(04):823–838
- 24 Zumstein MA, Jost B, Hempel J, Hodler J, Gerber C. The clinical and structural long-term results of open repair of massive tears of the rotator cuff. *J Bone Joint Surg Am* 2008;90(11):2423–2431. Doi: 10.2106/JBJS.G.00677
- 25 Kitay GS, Iannotti JP, Williams GR, Haygood T, Kneeland BJ, Berlin J. Roentgenographic assessment of acromial morphologic condition in rotator cuff impingement syndrome. *J Shoulder Elbow Surg* 1995;4(06):441–448. Doi: 10.1016/s1058-2746(05)80036-9
- 26 Hamid N, Omid R, Yamaguchi K, Steger-May K, Stobbs G, Keener JD. Relationship of radiographic acromial characteristics and rotator cuff disease: a prospective investigation of clinical, radiographic, and sonographic findings. *J Shoulder Elbow Surg* 2012;21(10):1289–1298. Doi: 10.1016/j.jse.2011.09.028
- 27 Moor BK, Bouaicha S, Rothenfluh DA, Sukthankar A, Gerber C. Is there an association between the individual anatomy of the scapula and the development of rotator cuff tears or osteoarthritis of the glenohumeral joint?: A radiological study of the critical shoulder angle. *Bone Joint J* 2013;95-B(07):935–941. Doi: 10.1302/0301-620X.95B7.31028
- 28 Teefey SA, Rubin DA, Middleton WD, Hildebolt CF, Leibold RA, Yamaguchi K. Detection and quantification of rotator cuff tears. Comparison of ultrasonographic, magnetic resonance imaging, and arthroscopic findings in seventy-one consecutive cases. *J Bone Joint Surg Am* 2004;86(04):708–716