

The Role of Tibial Plateau Angle in Canine Cruciate Ligament Rupture—A Review of the Literature

Anastasija Z. Todorović^{1,*} Mirjana V. Lazarević Macanović^{1,*} Marko B. Mitrović¹ Nikola E. Krstić¹
Henri J. J. van Bree² Ingrid M. L. V. Gielen^{1,3}

¹ Faculty of Veterinary Medicine, Department of Radiology and Radiation Hygiene, University of Belgrade, Belgrade, Serbia

² VetMedImage, Erondegem, Belgium

³ Faculty of Veterinary Medicine, Department of Morphology, Imaging, Orthopedics, Rehabilitation and Nutrition, Ghent University, Merelbeke, Belgium

Address for correspondence Mirjana V. Lazarević Macanović, DVM, PhD, Faculty of Veterinary Medicine, Department of Radiology and Radiation Hygiene, University of Belgrade, Bulevar oslobođenja 18, 11000 Belgrade, Serbia (e-mail: miramac@vet.bg.ac.rs).

Vet Comp Orthop Traumatol 2022;35:351–361.

Abstract

Cranial cruciate ligament disease is a common pathological condition in dogs that is often presented in daily clinical practice. Different risk factors for the development of this condition include breed, sex, age, bodyweight and neuter status, as well as different biological and biomechanical mechanisms. In the literature, special attention has been paid to the role of the tibial plateau angle in damage to the cranial cruciate ligament. Although the disease was first described at the beginning of last century, and since then different surgical methods have been developed to treat it, its aetiology remains unclear. In this review, contemporary literature data related to the role of tibial plateau angle in canine cranial cruciate ligament rupture are presented.

Keywords

- ▶ cranial cruciate ligament
- ▶ diagnostic imaging
- ▶ dog
- ▶ stifle joint
- ▶ tibial plateau angle

Introduction

The cranial cruciate ligament is a central stabilizer of the stifle joint. Its main roles are to restrict internal tibial rotation, and to prevent hyperextension of the stifle and cranial displacement of the tibia.^{1,2} The cranial cruciate ligament originates from a fossa on the caudomedial aspect of the lateral femoral condyle and attaches to the cranial intercondylar part of the tibial plateau.¹ The ligament is located intra-articularly and is composed of the craniomedial band, which is taut throughout flexion and extension, and the caudolateral band, which is taut only during extension. Changes in the joint angle alter the tension in separate bands because some fibres are exposed to the stress and others are not.³ In physiological conditions, this enables the cranial cruciate ligament to resist multi-axial stresses and

provide normal function and ranges of motion of the stifle joint.³

Cranial cruciate ligament disease is the most frequently diagnosed orthopaedic condition of the stifle joint and one of the leading causes of hindlimb lameness in dogs.³ In humans, rupture of the anterior cruciate ligament is mostly due to the acute, traumatic injury often associated with sport activities.⁴ In dogs, the exact aetiology of cranial cruciate ligament rupture remains unknown. As the biomechanics of the stifle joint differs significantly from that in humans, cranial cruciate ligament rupture usually occurs as a result of progressive degenerative changes in the ligament³ and this leads to inflammation, pain and osteoarthritis in affected joints.⁵ However, there is also evidence that osteoarthritis could be the cause of cranial cruciate ligament disease.⁶

To date, there is no consensus on the exact causative factors that predispose dogs for this disease. The relationship between a high tibial plateau angle and subsequent cranial

* Contributed equally to the study.

received

March 15, 2021

accepted after revision

May 17, 2022

published online

July 18, 2022

© 2022. Thieme. All rights reserved.

Georg Thieme Verlag KG,

Rüdigerstraße 14,

70469 Stuttgart, Germany

DOI <https://doi.org/>

10.1055/s-0042-1750316.

ISSN 0932-0814.

cruciate ligament rupture was considered almost 40 years ago.⁷ The tibial plateau has a significant role in force distribution during walking,⁸ and a close relationship between tibial plateau angle and the cranial tibial thrust produced during axial tibial loading was found.^{9–11} Cranial tibial thrust, defined as the cranially directed force produced by tibial compression, is responsible for cranial drawer motion in the cranial cruciate ligament deficient stifle, and is counteracted by this ligament.¹² It was reported that the magnitude of the cranial tibial thrust increases with increase in tibial plateau slope angle.¹³ Cranial tibial thrust is one of the main causes of the repetitive microtrauma¹⁴ that consequently leads to cranial cruciate ligament weakness and ligament disease.¹⁵ This article is an overview of literature data related to the role of tibial plateau angle in canine cranial cruciate ligament rupture.

Risks for Cranial Cruciate Ligament Rupture

Many hypotheses related to the primary cause of cranial cruciate ligament rupture are described and there are also many potential risk factors associated with this condition. The most common risk factors are breed, sex, age, body-weight and neuter status.^{6,16,17} In the literature, the following biological and biomechanical mechanisms have been proposed: inflammatory changes in the synovial membrane or in the cranial cruciate ligament epiligament and synovial fluid, immune-mediated arthritis, immune-mediated synovitis, apoptosis, conformation abnormalities such as straight stifle angle, narrowed intercondylar notch and elevated tibial plateau angle.^{5,6,16–18} Potential causes of ligament degeneration consider loss of fibroblasts, metaplasia of surviving fibroblasts to chondrocytes, disruption of collagen fibril architecture,¹⁹ osteoarthritis⁵ and abnormalities in cell phenotype with resultant alterations in extracellular matrix synthesis.⁵ Immobilisation also may lead to appreciable decreases in ligament strength and predispose ligament to rupture.²⁰

Breeds with a higher prevalence of cranial cruciate ligament rupture are the Rottweiler, Newfoundland, Labrador Retriever, Brazilian mastiff, Akita, Saint Bernard, Chow Chow, Bullmastiff, Bulldog, Boxer and American Staffordshire Terrier.^{17,21} It has been confirmed that increased body weight is a risk factor for cranial cruciate ligament disease in young large-breed dogs.¹⁶ Although large dog breeds are more affected, body size cannot be taken into consideration due to the high incidence of this disease in smaller dogs such as the West Highland White Terrier.²²

A genetic base was suggested in the Newfoundland, and several chromosomal regions are associated with cranial cruciate ligament rupture²³; however, there is a need for further investigation in other breeds as well. It is commonly accepted that an acute cranial cruciate ligament rupture in dogs induced by trauma is uncommon and that rupture of a healthy ligament occurs only under the influence of a force that is nearly four times greater than the body weight of the dog.²⁴

The average age of dogs at the time of diagnosis varies: 7 to 10⁶ and 6.6 years.²⁵ In small dog breeds, cranial cruciate

ligament disease has been reported in middle-aged to elderly animals.⁶ Spayed females and castrated males have a significantly higher risk for cranial cruciate ligament rupture than intact dogs, and females are at the highest risk.¹⁷

The Importance of Tibial Plateau Angle in Cranial Cruciate Ligament Rupture

Tibial plateau angle is defined as the angle formed between the slope of the medial tibial condyle and the line perpendicular to the mechanical axis of the tibia, which is determined by joining the centre of the tibial plateau, defined as the mid-point between the medial and lateral intercondylar tubercles, to the centre of the talocrural joint (► Fig. 1).¹² The estimation of tibial plateau angle is performed on medio-lateral radiographic view. Different results of angle measurements in healthy dogs^{26–31} and dogs with cranial cruciate ligament rupture^{26,29,31,32} are shown in ►Table 1 and statistical analyses is given in ►Table 2.

Some investigations indicated that the mean tibial plateau angle in dogs with cranial cruciate ligament rupture is higher than in dogs without it.²⁶ However, several studies failed to identify a significant association between tibial plateau angle and the risk of cranial cruciate ligament rupture pointing out

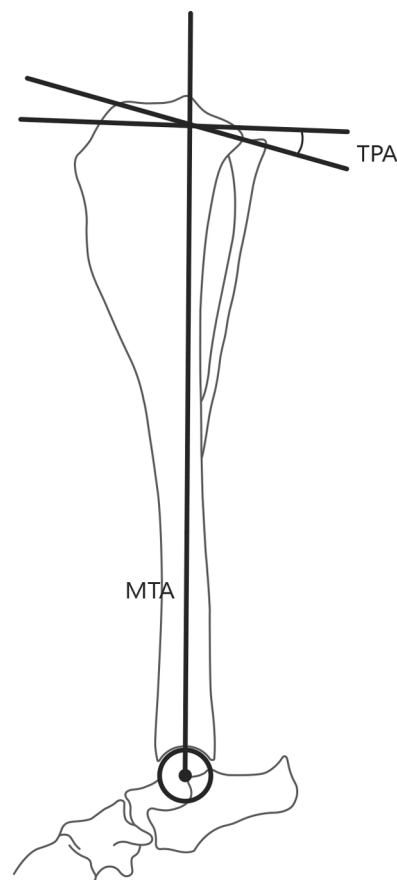


Fig. 1 Method of tibial plateau angle measurement established by Slocum and Devine.¹² Mechanical tibial axis (MTA)—the line that connects the mid-point between the medial and lateral intercondylar tubercles and the centre of the talocrural joint. Tibial plateau axis (TPA)—the angle between the slope of the medial tibial condyle and the line perpendicular to the MTA.

Table 1 Data related to the tibial plateau angle measurements in healthy dogs and dogs with cranial cruciate ligament rupture

	Healthy dogs	Dogs with CrCLR	
Breed	Mean ± SD (range)	Mean ± SD (range)	Reference
Different large breeds	18.1 ± 4.03 degrees	23.76 ± 3.88 degrees	26
Different breeds	23.5 degrees (17–31 degrees)	–	27
Different breeds	24.9 ± 3.0 degrees	–	28
Labrador Retrievers	23.6 ± 3.5 degrees (15–29 degrees)	23.5 ± 3.1 degrees (18–30 degrees)	29
Different large breeds	24.9 ± 2.7 degrees	–	30
Greyhounds	22.50 ± 0.84 degrees	–	31
Labrador Retrievers	27.97 ± 0.66 degrees	25.55 ± 0.55 degrees	31
Different breeds	–	29 ± 3.7 degrees	32

Abbreviations: CrCLR, cranial cruciate ligament rupture; SD, standard deviation.

Table 2 Statistical analysis of the tibial plateau angle measurements in healthy dogs and dogs with cranial cruciate ligament rupture

	Mean	Median	Min.	Max.	SD	CI of the SD – 95%	CI of the SD +95%
All dogs	24.30 degrees	23.76 degrees	18.1 degrees	29 degrees	2.86 degrees	2	5
Healthy dogs	23.64 degrees	23.6 degrees	18.1 degrees	27.97 degrees	3 degrees	1.93	6.6
Dogs with CrCLR	25.45 degrees	24.66 degrees	23.5 degrees	29 degrees	2.54 degrees	1.44	9.45

Abbreviations: CI, confidence interval; CrCLR, cranial cruciate ligament rupture; SD, standard deviation.

that many dogs with a steep angle do not develop cranial cruciate ligament disease, regardless of whether they are predisposed to this condition or not.^{16,28} This means that the tibial plateau angle may not be the single predisposing factor for cranial cruciate ligament rupture, even in breeds predisposed to the rupture.^{6,17}

A recent study indicated that small dog breeds have a higher mean tibial plateau angle in comparison to large breeds and questioned whether this angle has less influence on cranial cruciate ligament disease in small dogs.³³ It was reported that small dogs with cranial cruciate ligament rupture have a tibial plateau angle that is 4.9 degrees steeper than that in large dogs with the same pathology.³⁴ The connection between tibial plateau angle and the risk of cranial cruciate ligament rupture was indicated, with the explanation that this angle could play an important role in the pathogenesis of cranial cruciate ligament disease.³⁴

Neutering may be a risk factor for the development of the excessive tibial plateau angle in large-breed dogs since neutered dogs had significantly higher average angle values than intact dogs.³⁵ The significant difference in the average tibial plateau angle between females and males was not found, regardless of the neuter status.³² The effects of gonadectomy in dogs younger than 6 to 8 months were examined and it was documented that prepubertal gonad-

ectomy provokes widening of the growth plate and increasing longitudinal bone growth.³⁶ Furthermore, gonadectomy performed in 7-month-old dogs resulted in a delayed growth plate closure.³⁶ It was confirmed that the tibial plateau angle was significantly higher ($p < 0.05$) in small-breed male dogs than in small-breed female dogs, and that the angle was higher in small-breed healthy neutered dogs in comparison to the small-breed healthy intact dogs.³⁷ Also, the tibial plateau angle in small-breed dogs with cranial cruciate ligament rupture was 27.12 ± 0.62 degrees, which was significantly higher ($p < 0.001$) than that in small-breed healthy dogs (20.21 ± 0.32 degrees), indicating that higher tibial plateau angle values are associated with a higher risk of cranial cruciate ligament rupture.³⁷

The steepness of the tibial plateau, a larger stifle joint angle and a narrowing of the distal femoral intercondylar notch have been associated with cranial cruciate ligament disease.³⁸ The tibial plateau angle significantly influences the risk of contralateral cranial cruciate ligament rupture where an increased angle decreased contralateral ligament survival.³⁹ It was also demonstrated that structural changes within the cranial cruciate ligament are strongly correlated with an increasing tibial plateau angle and with a narrowing intercondylar notch, suggesting that increasing the angle increases the mechanical load of the cranial cruciate

ligament, which subsequently increases the compression and tension forces acting through the ligamentous tissues.⁴⁰ The role and influence of the tibial plateau angle in the pathogenesis of cranial cruciate ligament rupture are still being discussed.

Assessment of Tibial Plateau Angle by Different Diagnostic Imaging Methods

Radiography

Radiography is the most frequently used imaging technique for cranial cruciate ligament rupture diagnosis in dogs. Radiographic assessment of cranial cruciate ligament is accurate in 98% of cases if the tibial compression test is used.⁴¹ The procedure is known as “tibial compression radiography” or “stress radiography” and it should be performed on sedated animals.⁴¹ The dog is positioned in lateral recumbency and the stifle should be fixed at 90 degrees of flexion while manual stress is exerted on metatarsal bones to flex the hock joint maximally.⁴¹ A true lateral position is achieved when there is superimposition of the femoral condyles and superimposition of the tibial condyles.²⁸ In acute cases of cranial cruciate ligament rupture, radiographic changes imply intra-articular swelling and cranial displacement of the tibia in the mediolateral view with tarsal flexion applied, and in chronic cases osteoarthritis is present.⁴² Apart from lateral radiographs of the stifle joint being used for cranial cruciate ligament rupture diagnosis, cranio-caudal radiographs should also be performed for the assessment of osteoarthritis and other abnormalities.²

During radiography special attention should be paid on the X-ray beam centring and collimation to avoid image distortion that may affect the tibial plateau angle assessment. Centring the X-ray beam over the stifle joint is vital in obtaining an accurate tibial plateau angle, whereby the X-ray beam should be collimated to include the stifle and tarsocrural joints.^{9,43} Limb positioning relative to the X-ray beam influences the radiographic appearance of the tibial plateau and the magnitude of the measured angle.²⁸ Cranial and proximal positioning of the limb relative to the X-ray beam leads to overestimation, whereas caudal and distal positioning leads to underestimation of the tibial plateau angle. The maximal difference of the mean angle because of positioning is 3.61 degrees for classical method in which tibial plateau angle is expressed in relation to the mechanical axis.²⁸ In a recent study, mediolateral radiographs of hindlimbs with intact and transected cranial cruciate ligament were obtained at 0, 10, 20 and 30 degrees of internal and external rotation of the tibia to evaluate the effect of tibial rotation on the magnitude of the tibial plateau angle measurement.⁴⁴ No differences were found in the angle measurements between the intact and transected cranial cruciate ligament at 0, 10, 20 and 30 degrees of internal and external rotation ($p > 0.05$). Also, no differences were found in the tibial plateau angle measurements of intact cranial cruciate ligament between 0 degree and all degrees of internal rotation (10, 20 and 30 degrees), but the difference in angle of intact cranial cruciate ligament between 0 degree and all degrees of exter-

nal rotation, 10 degrees (-1.16 degrees, $p = 0.016$), 20 degrees (-1.36 degrees, $p = 0.001$) and 30 degrees (-1.6 degrees, $p < 0.001$) was noted.⁴⁴ Although established differences were significant, they did not have clinical significance because the maximum difference was only 1.6 degrees. No difference at any rotational view of transected cranial cruciate ligament compared with 0 degrees ($p > 0.05$) was found.⁴⁴

Differences between lateral and medial tibial plateau angles in dogs were explained in an osteological study performed by Sabanci and Ocal.⁴⁵ The difference between the mean medial (24.0 ± 3.19 degrees) and the mean lateral tibial plateau angle (25.5 ± 3.84 degrees) measured from photographs was significant ($p < 0.05$) and it was indicated that different medial and lateral angles could be factors leading to cranial cruciate ligament injury in these animals.⁴⁵ Even though the medial tibial plateau angle is essential for angular assessment of the tibial plateau on radiographs, the influence of lateral tibial plateau angle on cranial cruciate ligament rupture should be considered.

Despite the fact that the agreement on radiographic interpretation of cranial cruciate ligament rupture is high,⁴⁶ inter- and intraobserver variability has been documented in tibial plateau angle measurements, even when the same measurement technique and positioning were used.^{27,47,48} Measured tibial plateau angle values can be misinterpreted in cases of poor positioning of the limb, when the X-ray beam is not centred on the stifle joint during radiographic imaging.^{47,49} Also, severe osteophyte formations around tibial condyles can hinder the identification of the cranial and caudal margins of the tibial plateau.⁴⁷

Tibial Plateau Angle Measurements in Relation to Mechanical Tibial Axis

Most radiological measurements of the tibial plateau angle in dogs have relied on the inclination of the tibial plateau slope in relation to the mechanical (functional) axis that is a straight line connecting the centres of the joints proximal and distal to the bone (\rightarrow Fig. 1).⁵⁰

A modification of this widely used method for measuring the tibial plateau angle, defined as a gold standard, was proposed by two groups of authors who tried to estimate whether the use of the proximal part of the tibia could be adequate for angle measuring in dogs. The first group concluded that tibial plateau angle measurement using the shortest proximal reference axis (R1) was not accurate.⁵¹ However, if the length of the reference axis increases (R2, R3), the correlation with the reference gold standard (Rg) also increases (\rightarrow Fig. 2).⁵¹ The second group⁵² also tried to find an accurate method of tibial plateau angle measurement by using three different proximal tibial axes (TA-2, TA-2o, TA-2i) (\rightarrow Fig. 3). Even though all three measured angle values were within the previously reported range of 12.0 to 36.5 degrees,⁴⁷ only one (TA-2o) was found not to differ significantly from the gold standard (TA-0).⁵²

A method for determining the proximal and distal tibial joint reference angles in relation to the mechanical axis in the sagittal plane, that is, mechanical cranial distal tibial angle

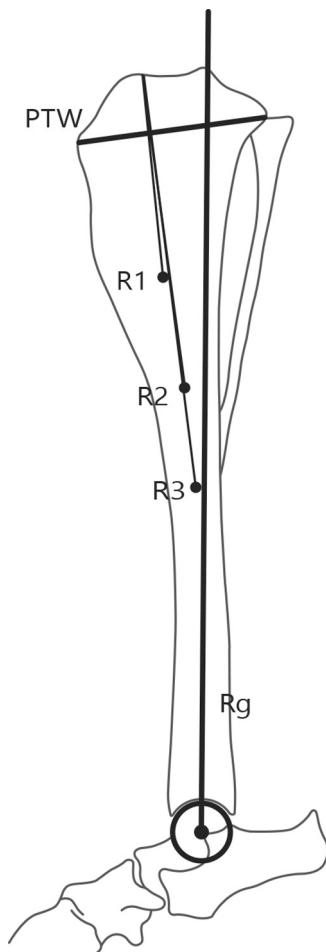


Fig. 2 Method of tibial plateau angle measurement using the proximal portion of the tibia described by Abel and colleagues.⁵¹ Proximal tibial width (PTW)—the distance between the proximal point of the tibial crest and the caudal point of the medial tibial condyle surface. Rg—gold standard reference axis of tibia (mechanical tibial axis). R1, R2, R3—reference axes formed by lines that connect the cranial aspect of the medial tibial condyle and the point distally determined by bisecting the tibia at distances equal to 1, 1.5 and $2 \times$ PTW.

and mechanical caudal proximal tibial angle, was also described (► Fig. 4).⁵³ It was found that the mechanical caudal proximal tibial angle is complementary to the tibial plateau angle, and that the reference range for the mechanical caudal proximal tibial angle represents the complement of a reference range for the tibial plateau angle. However, a limitation of this study is that all the dogs in this study had cranial cruciate ligament disease and there was no comparison with healthy stifle joints.⁵³

Tibial Plateau Angle Measurements in Relation to Anatomical Tibial Axis

Measurement of the tibial plateau slope on lateral radiographs in relation to the anatomical axis was introduced in both human and veterinary medicine. The anatomical tibial axis, which is often called the distal (diaphyseal) tibial axis, is defined as a line connecting the midpoint between the cranial and caudal tibial cortices at 50 and 75% of the tibial shaft length.^{8,54}

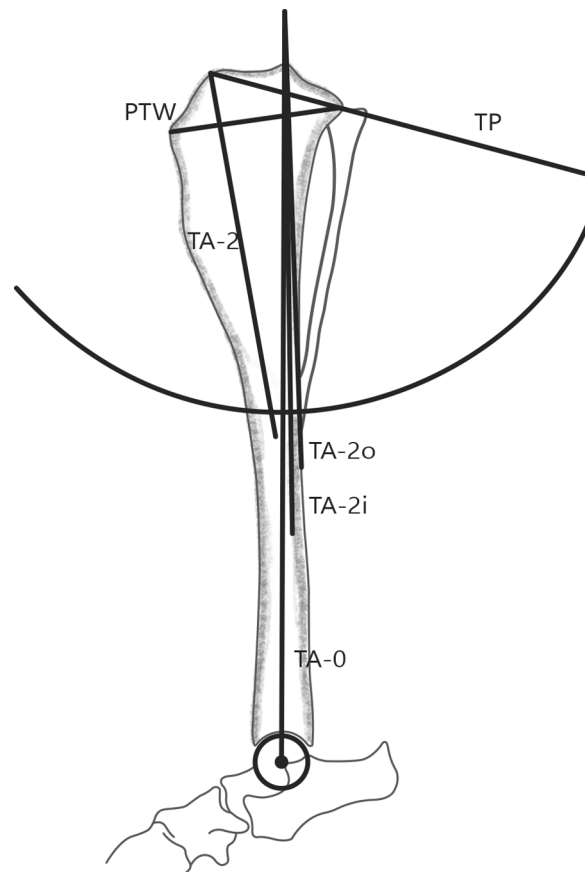


Fig. 3 Method of tibial plateau angle measurement using the proximal portion of the tibia described by Stehlik and colleagues.⁵² Tibial plateau (TP)—the line between the cranial edge of the tibial articular surface and the caudal edge of the medial tibial condyle. Proximal tibial width (PTW)—the distance between the proximal point of the tibial crest and the caudal point of the medial tibial condyle surface. TA-0—gold standard reference axis of tibia (mechanical tibial axis). TA-2—reference axis formed by the line that connects the cranial aspect of the medial tibial condyle and the point distally determined by bisecting the tibia at a distance equal to $2 \times$ PTW. TA-2o—reference axis formed by the line that connects the intercondylar eminence and the point on the periosteal surface of the caudal tibial cortex that is positioned at a circle of a radius of $2 \times$ the width of the proximal tibia and centred at the intercondylar tibial eminence. TA-2i—reference axis formed by the line that connects the intercondylar eminence and the point on the endosteal surface of the caudal tibial cortex that is positioned at a circle of a radius of $2 \times$ the width of the proximal tibia and centred at the intercondylar tibial eminence.

The relationships between some parameters in dogs with and without cranial cruciate ligament rupture, such as tibial plateau slope, diaphyseal tibial axis/proximal tibial axis angle, as well as tibial plateau orientation, were examined.⁵⁴ Tibial plateau orientation was defined as the angle between the diaphyseal tibial axis and the line tangential to the linear portion of the medial tibial condyle (► Fig. 5). It was found that dogs with a diaphyseal tibial axis/proximal tibial axis angle larger than 11.23 degrees (range: 11.4–13.91 degrees) had a ruptured cranial cruciate ligament and a steep tibial plateau slope. A higher tibial plateau slope (mean: 31.8 ± 4.11 degrees) and diaphyseal tibial axis/proximal tibial axis angle (mean: 6.0 ± 3.31 degrees) were registered in dogs with cranial cruciate ligament rupture in comparison to

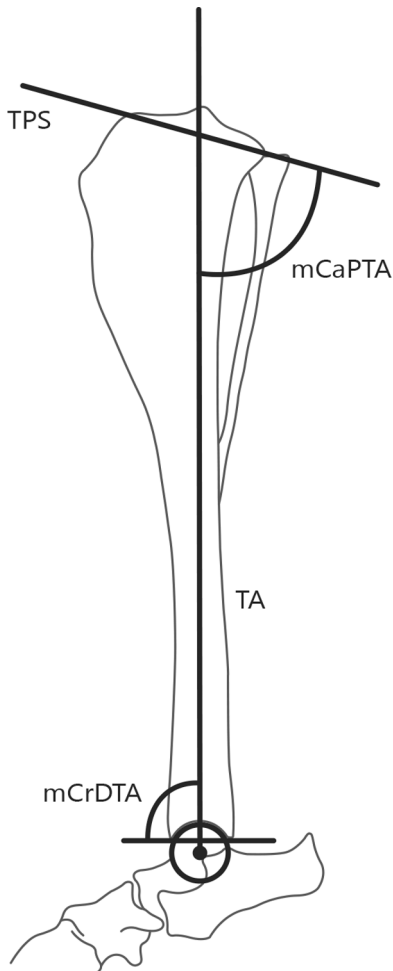


Fig. 4 Method of mechanical cranial distal tibial angle and mechanical caudal proximal tibial angle measurement described by Dismukes and colleagues.⁵³ TA—gold standard reference axis of tibia (mechanical tibial axis). TPS—tibial plateau slope defined by the line tangential to the linear portion of the medial tibial condyle. mCrDTA—mechanical cranial distal tibial angle. mCaPTA—mechanical caudal proximal tibial angle.

dogs without cranial cruciate ligament rupture that had a lower tibial plateau slope (mean: 23.6 ± 3.41 degrees) and diaphyseal tibial axis/proximal tibial axis angle (4.1 ± 2.21 degrees).⁵⁴

Using the previously described methodology (► **Fig. 5**),⁵⁴ the radiographic assessment of diaphyseal tibial axis/proximal tibial axis angle in dogs with cranial cruciate ligament rupture was also investigated by other authors and it was reported that the median tibial plateau angle was 27.9 degrees (range: 18.8–41.3 degrees) and the mean diaphyseal tibial axis/proximal tibial axis angle \pm standard deviation was 6.5 ± 2.81 degrees.⁸ A correlation between the age or weight of the dogs and the diaphyseal tibial axis/proximal tibial axis angle was not found ($p = 0.58$ and $p = 0.12$) but a moderate correlation between diaphyseal tibial axis/proximal tibial axis angle and tibial plateau angle was confirmed ($p < 0.0001$).⁸

The influence of tibial plateau slope and relative body weight on cranial cruciate ligament disease was also examined in small breeds dogs.¹⁴ The relative body weight was

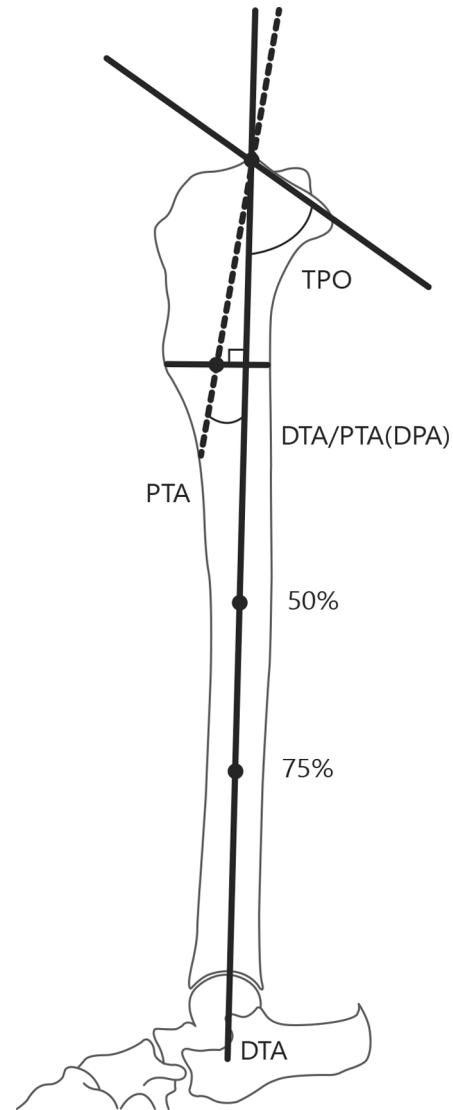


Fig. 5 Morphometric assessment of the proximal portion of the tibia performed by Osmond and colleagues.⁵⁴ Diaphyseal tibial axis (DTA)—a line that connects the midpoint between cranial and caudal tibial cortices at a distance of 50 and 75% of the tibial axis length (anatomical tibial axis). Proximal tibial axis (PTA)—a line that connects the cranial aspect of the medial tibial condyle and the craniocaudal midpoint at the distal aspect of the tibial crest. DTA/PTA (DPA)—the angle between DTA and PTA. Tibial plateau orientation (TPO)—the angle between DTA and the line tangential to the linear portion of the medial tibial condyle.

calculated as the ratio of body weight to diaphyseal tibial width, which was defined as the distance between the cranial and caudal cortices of the tibia measured in the middle of the tibial length on a line perpendicular to the anatomical axis of the tibia. By comparing the two examined groups (with and with no cranial cruciate ligament disease) of small dogs with body weight less than 15 kg, it was noticed that gender, age and relative body weight were not significantly different between these two groups, but it was also concluded that dogs with cranial cruciate ligament disease had a significantly greater tibial plateau angle ($p = 0.015$) and relative body weight ($p = 0.016$).¹⁴ Proximal tibial angulation has also been considered to be a predisposing factor for

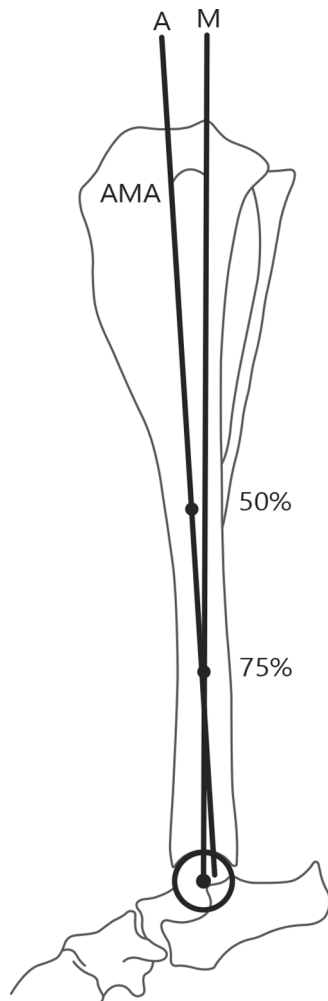


Fig. 6 Method of tibial anatomical-mechanical angle measurement described by Guénégo and colleagues.⁵⁵ A—anatomical tibial axis. M—mechanical tibial axis. AMA—anatomical-mechanical angle.

excessive tibial plateau angle and cranial cruciate ligament rupture in small and medium-sized dogs.²²

Measurements of the tibial anatomical-mechanical axis angle were also performed and it was reported that the anatomical-mechanical axis angle is significantly higher in dogs predisposed to cranial cruciate ligament rupture (►Fig. 6).⁵⁵ An anatomical-mechanical axis angle higher than 1.87 degrees predicts ligament rupture with a sensitivity of 0.941 and specificity of 0.965.⁵⁵

Computed Tomography

Computed tomography (CT) enables good visualization of osseous structures; however, ligaments can also be clearly observed on CT images.⁵⁶ Computed tomography is superior to radiography in assessing tibial torsion and its influence on improper positioning. In human medicine, the variation in measurements of the tibial plateau angle on lateral radiographs is more than 5 degrees even without rotation, but with rotation of the tibia the error increases up to 14 degrees.⁵⁷ By using multi-slice CT scans, the measurement error decreases to less than 3 degrees.⁵⁷ It was confirmed that three-dimensional (3D) CT morphological

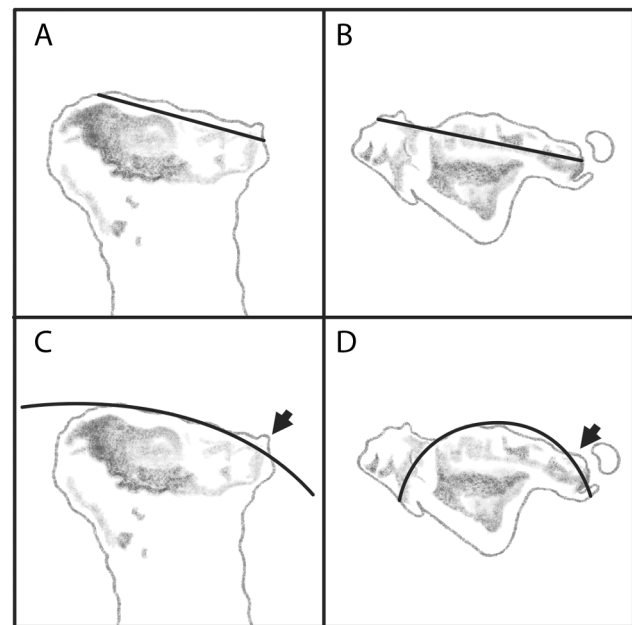


Fig. 7 Method of tibial plateau assessment on computed tomographic images described by Townsend and colleagues.⁶⁰ The medial and lateral tibial plateau angles measured separately on midsagittal planes of medial (A) and lateral (B) tibial condyles. Tibial plateau angles are represented by lines that intersect the most cranial and caudal margins of the medial and lateral tibial condyles. The medial and lateral tibial plateau radiuses of curvature of the subchondral bone surface measured separately on midsagittal planes of the medial (C) and lateral (D) tibial condyles. The subchondral bone surface of medial and lateral tibial plateaus is determined by digitally superimposing a circle that matches as closely as possible to the cranial-caudal length of each plateau. Small osteophytes (arrows) should be recognized and avoided.

measurements of the tibial plateau are more reproducible than measurements performed on radiographs.⁵⁸ A new 3D method for calculating posterior-inferior directed slope of the lateral tibial plateau from CT scans was proposed in human medicine.⁵⁹ This method will be useful in identifying relationships between this critical feature of tibial geometry and knee biomechanics, with the aim of preventing anterior cruciate ligament rupture and improving its treatment.⁵⁹

Morphologic analyses of the tibial plateau obtained by CT imaging that involved measurements of medial and lateral tibial plateau slopes as well as measurements of the medial and lateral tibial plateau curvature radiuses were recently performed in veterinary medicine (►Fig. 7).⁶⁰ It was concluded that the lateral tibial plateau angle was steeper than the medial angle ($p < 0.001$), but there were no differences in medial or lateral tibial plateau angles between cranial cruciate ligament affected stifles and contralaterally sound healthy stifles.⁶⁰ However, the radius of medial tibial plateau curvature was larger ($p = 0.002$) in cranial cruciate ligament affected stifles compared with contralaterally sound healthy stifles.⁶⁰ The same finding was also reported in radiographic studies.⁶¹ At the same time, no differences in the radiuses of lateral tibial plateau curvature between stifles with cranial cruciate ligament disease and contralaterally sound stifles were established, suggesting that increased plateau

asymmetry may be a trigger for cranial cruciate ligament damage.⁶⁰

Magnetic Resonance Imaging

Magnetic resonance imaging (MRI) is the modality of choice for assessing knee pathology.⁴ In humans, the tibial plateau measurement method based on MRI was proposed and the tibial plateau was defined by three slopes: medial, lateral and coronal tibial slope, as well as medial tibial depth—the depth of concavity of the medial plateau in the middle of the articular region (►Fig. 8).⁶² It was noticed that men with increased medial and lateral tibial slope combined with a decreased medial tibial depth were at an increased risk of suffering from anterior cruciate ligament injury.⁶³ Based on the lateral and medial tibial slope measurements by MRI, it

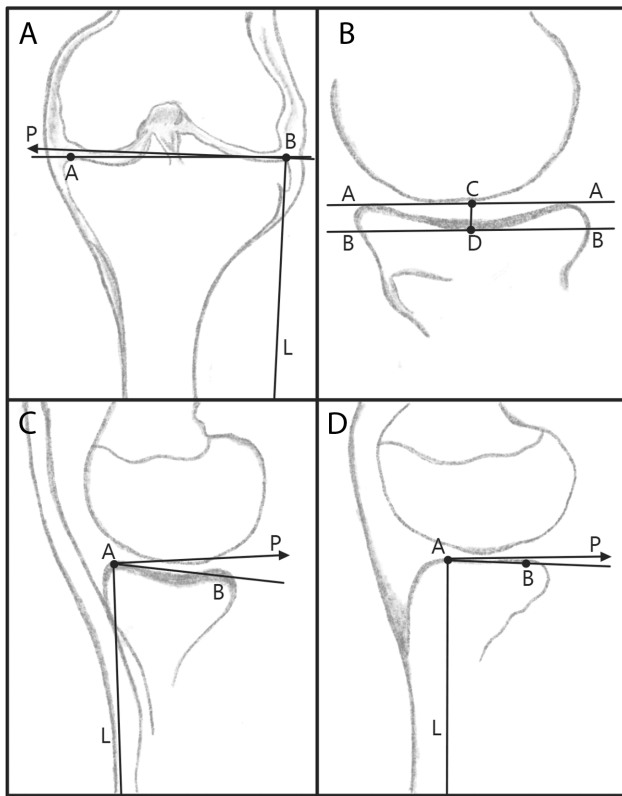


Fig. 8 Method of tibial plateau assessment with magnetic resonance imaging described by Hashemi and colleagues.⁶² The slope of the tibial plateau measured in the coronal plane (A). L—the copy of the longitudinal (diaphyseal) tibial axis that connects the two midpoints of the medial-to-lateral width of the tibia. AB—a line joining the peak points on the medial and lateral aspects of the plateau. The coronal slope of the tibial plateau was measured as the angle between AB line and P axis which was perpendicular to the longitudinal (diaphyseal) axis L. The depth of concavity of the medial tibial plateau in sagittal plane (B). AA—a line connecting the superior crests of the medial tibial plateau. BB—a line parallel to the line previously described that was drawn tangential to the lowest point of the concavity. CD—the perpendicular distance between AA and BB lines which represents the depth of concavity of the medial tibial plateau. The medial and lateral tibial plateau slopes measured separately in sagittal planes of medial (C) and lateral (D) tibial condyles. AB—the tibial plateau slope measured with respect to the P axis which was perpendicular to L axis. Both axes (P and L) were reconstructed on the anterior peak of the medial and lateral tibial plateaus on the sagittal plane.

was concluded that a steeper lateral tibial slope is an important risk factor for anterior cruciate ligament injury, especially in men, while women with a shallower medial tibial depth are at increased risk of sustaining anterior cruciate ligament injury.⁴ There are no available literature data about using MRI for tibial plateau angle measuring in veterinary medicine.

Discussion

In veterinary medicine, the slope of the tibial plateau to assess its impact on cranial cruciate ligament rupture is most often estimated on radiographs which provide a two-dimensional view of the tibia. Even though the method established by Slocum and Devine¹² which refers to the mechanical tibial axis represents the gold standard for tibial plateau angle measurement, different measurement methods which are focused on tibial plateau slope determination using different types of the proximal tibial axes have also been considered. The obtained results indicate that the values of tibial plateau slope measured in relation to different proximal axes correlate with the values of the slope measured in relation to the mechanical axis of the tibia, with the degree of correlation significantly depending on the length of the proximal axis (►Fig. 2)⁵¹ and its position (►Fig. 3).⁵²

Besides tibial plateau slope, the conformation of the proximal part of the tibia also has significant impact on the cranial cruciate ligament rupture occurrence. The quantification of proximal tibial angulation was attempted by measuring the diaphyseal tibial axis/proximal tibial axis angle whose value is proportional to the craniocaudal distance at the distal aspect of the tibial crest (►Fig. 5). It was reported that higher diaphyseal tibial axis/proximal tibial axis angle as well as higher tibial plateau slope were registered in dogs with cranial cruciate ligament rupture.^{8,54} The significance of the craniocaudal distance at the distal aspect of the tibial crest was also confirmed in the study in which the angle between the mechanical and anatomical tibial axis was measured (►Fig. 6). Increasing this distance results in increase of the angle, and values greater than 1.87 degrees predicts cranial cruciate ligament rupture.⁵⁵

Even though the limb positioning for the tibial plateau slope measurements on radiograph is fully described, variation in measurement results has been reported and they are related to the location of the limb relative to the primary X-ray beam.^{28,47,49} Cranial and proximal positioning of the normal limb relative to the X-ray beam causes a significant overestimation of the tibial plateau slope measurement with a variability among dogs reported to be 1.1 degree.^{47,49}

In dogs with moderate or severe osteoarthritis, it is often difficult to define the appropriate points from which the tibial plateau angle measurement should be obtained.⁴⁷ If the caudal reference point on the medial tibial condyle is not defined consistently, tibial plateau angles may significantly differ.⁶⁴ The variability of caudal point selection in the vertical direction can result in larger changes in tibial plateau angle when compared with horizontal displacement.⁴⁷ However, some authors did not confirm that presence of the

osteophytes on the tibial plateau leads to different angle values due to an inability to precisely locate the caudal point.⁵² This is in agreement with previous reports in dogs.^{11,65}

According to the literature data originated from human medicine, qualitatively analyse the asymmetric 3D proximal portion of the tibia on a two-dimensional lateral radiograph is not precise enough and therefore, 3D imaging methods such as CT an MRI enable an independent visualization and assessment of the lateral and medial part of the tibial plateau.⁶² Measurements based on 3D-CT were more reproducible than plain radiography in many studies.^{57,58,66} The radiation exposure during CT is higher, when compared with conventional radiography, but the improved accuracy may justify the added radiation dose.⁵⁸ It was reported that, in humans, the variation in measurements on radiographs was more than 5 degrees even without tibial rotation. In cases of rotation, the error increased significantly (up to 14 degrees).⁵⁷ In case of tibial plateau measuring on CT images performed by using multi-slice CT scans, the measurement error was less than 3 degrees.⁵⁷ Morphologic analyses of the tibial plateau recently performed on CT images in veterinary medicine confirmed that measuring tibial plateau angle on radiographs is a reflection of medial but not lateral angle. Even though, quantifying the lateral tibial plateau angle was more variable both between and within observers, no differences in the radiuses of lateral tibial plateau curvature between stifles with cranial cruciate ligament insufficiency and contralaterally sound stifles were established.⁶⁰ On the other hand, the larger radius of medial tibial plateau curvature and, therefore, less convex medial tibial plateau may predispose to the cranial cruciate ligament insufficiency in dogs (► Fig. 7).⁶⁰

Medial and lateral tibial plateau slopes measured in MRI studies in human population have been reported ranging from (mean values) -2.9 to 10.7 and -1.8 to 7.52 degrees, respectively.⁴ The great variation in values is due to the method of choosing the tibial angle and selecting sagittal images.⁴ There are findings suggesting that MRI studies should consider three tibial slopes: medial, lateral and coronal tibial slope, as well as medial tibial depth—the depth of concavity of the medial plateau as predictors of anterior cruciate ligament injury (► Fig. 8).^{62,63}

Conclusion

Tibial plateau angle might have an impact on cranial cruciate ligament rupture; however, it cannot be considered as a single predisposing factor. Tibial plateau angle values obtained following measurements on the lateral radiographs can be misinterpreted in cases of poor positioning of the limb, wrong X-ray beam centring, as well as the presence of osteophytes around tibial condyles that can hinder the identification of the cranial and caudal margins of the tibial plateau. The use of 3D imaging methods of examination could contribute to a more precise determination of the tibial plateau angle. This would not only provide a clinical reference to help surgeons in precise preoperative planning

for cranial cruciate ligament rupture stabilization, but would also provide a better understanding of the role of the tibial plateau angle in cranial cruciate ligament disease.

Authors' Contributions

A.Z.T. substantially contributed to the conception, article design as well as analysis and interpretation of data, drafting of the article and digital artwork preparation, and gave final approval of the version to be published.

M.V.L.M. was involved in conception, article design and interpretation of data and revising the article critically for important intellectual content, and gave final approval of the version to be published.

M.B.M. contributed substantially to the conception, article design as well as analysis and interpretation of data and drafting of the article and digital artwork preparation, and gave final approval of the version to be published.

N.E.K. substantially contributed to the conception and article design and drafting of the article, and gave final approval of the version to be published.

H.J.J.v.B. was involved in the conception, article design and interpretation of data and revising the article critically for important intellectual content, and gave final approval of the version to be published.

I.M.L.V.G. contributed substantially to the conception, article design and interpretation of data and revising the article critically for important intellectual content, and final approval of the version to be published.

Funding

The study was supported by the Ministry of Education, Science and Technological Development of the Republic of Serbia (Contract number 451-03-68/2022-14).

Conflict of Interest

None declared.

Acknowledgment

The authors are grateful to Kruna Jevtić for adapting the drawings to the journal roles and to Nikola Atanasijević DVM, Specialist in Veterinary Orthopaedic, who helped in providing some relevant literature data. We are also grateful to Prof. Dr Dragan Žikić for help in statistical comments.

References

- 1 Arnoczky SP, Marshall JL. The cruciate ligaments of the canine stifle: an anatomical and functional analysis. *Am J Vet Res* 1977; 38(11):1807-1814
- 2 Johnson JM, Johnson AL. Cranial cruciate ligament rupture. Pathogenesis, diagnosis and postoperative rehabilitation. *Vet Clin N Am-Small* 1993;23(04):717-733
- 3 de Rooster H, de Bruin T, van Bree H. Morphologic and functional features of the canine cruciate ligaments. *Vet Surg* 2006;35(08): 769-780
- 4 Khan MS, Seon JK, Song EK. Risk factors for anterior cruciate ligament injury: assessment of tibial plateau anatomic variables on conventional MRI using a new combined method. *Int Orthop* 2011;35(08):1251-1256

- 5 Cook JL. Cranial cruciate ligament disease in dogs: biology versus biomechanics. *Vet Surg* 2010;39(03):270–277
- 6 Whitehair JG, Vasseur PB, Willits NH. Epidemiology of cranial cruciate ligament rupture in dogs. *J Am Vet Med Assoc* 1993;203(07):1016–1019
- 7 Read RA, Robins GM. Deformity of the proximal tibia in dogs. *Vet Rec* 1982;111(13):295–298
- 8 Glassman M, Hofmeister E, Weh JM, et al. Radiographic quantitative assessment of caudal proximal tibial angulation in 100 dogs with cranial cruciate ligament rupture. *Vet Surg* 2011;40(07):830–838
- 9 Warzee CC, Dejardin LM, Arnoczky SP, Perry RL. Effect of tibial plateau leveling on cranial and caudal tibial thrusts in canine cranial cruciate-deficient stifles: an in vitro experimental study. *Vet Surg* 2001;30(03):278–286
- 10 Reif U, Hulse DA, Hauptman JG. Effect of tibial plateau leveling on stability of the canine cranial cruciate-deficient stifle joint: an in vitro study. *Vet Surg* 2002;31(02):147–154
- 11 Fujita Y, Hara Y, Ochi H, et al. The possible role of the tibial plateau angle for the severity of osteoarthritis in dogs with cranial cruciate ligament rupture. *J Vet Med Sci* 2006;68(07):675–679
- 12 Slocum B, Devine T. Cranial tibial thrust: a primary force in the canine stifle. *J Am Vet Med Assoc* 1983;183(04):456–459
- 13 Slocum B, Slocum TD. Tibial plateau leveling osteotomy for repair of cranial cruciate ligament rupture in the canine. *Vet Clin North Am Small Anim Pract* 1993;23(04):777–795
- 14 Janovec J, Kyllar M, Midgley D, Owen M. Conformation of the proximal tibia and cranial cruciate ligament disease in small breed dogs. *Vet Comp Orthop Traumatol* 2017;30(03):178–183
- 15 Hayashi K, Frank JD, Dubinsky C, et al. Histologic changes in ruptured canine cranial cruciate ligament. *Vet Surg* 2003;32(03):269–277
- 16 Duval JM, Budsberg SC, Flo GL, Sammarco JL. Breed, sex, and body weight as risk factors for rupture of the cranial cruciate ligament in young dogs. *J Am Vet Med Assoc* 1999;215(06):811–814
- 17 Witsberger TH, Villamil JA, Schultz LG, Hahn AW, Cook JL. Prevalence of and risk factors for hip dysplasia and cranial cruciate ligament deficiency in dogs. *J Am Vet Med Assoc* 2008;232(12):1818–1824
- 18 Doom M, de Bruin T, de Rooster H, van Bree H, Cox E. Immunopathological mechanisms in dogs with rupture of the cranial cruciate ligament. *Vet Immunol Immunopathol* 2008;125(1–2):143–161
- 19 Hayashi K, Manley PA, Muir P. Cranial cruciate ligament pathophysiology in dogs with cruciate disease: a review. *J Am Anim Hosp Assoc* 2004;40(05):385–390
- 20 Noyes FR. Functional properties of knee ligaments and alterations induced by immobilization: a correlative biomechanical and histological study in primates. *Clin Orthop Relat Res* 1977;123(123):210–242
- 21 Nečas A, Zatloukal J, Kecová J, Dvořák J. Predisposition of dog breeds to rupture of cranial cruciate ligament. *Acta Vet Brno* 2000;69:305–310
- 22 Macias C, Mckee WM, May C. Caudal proximal tibial deformity and cranial cruciate ligament rupture in small-breed dogs. *J Small Anim Pract* 2002;43(10):433–438
- 23 Wilke VL, Zhang S, Evans RB, Conzemius MG, Rothschild MF. Identification of chromosomal regions associated with cranial cruciate ligament rupture in a population of Newfoundlands. *Am J Vet Res* 2009;70(08):1013–1017
- 24 Gupta BN, Brinker WO, Subramanian KN. Breaking strength of cruciate ligaments in the dog. *J Am Vet Med Assoc* 1969;155(10):1586–1588
- 25 Lampman TJ, Lund EM, Lipowitz AJ. Cranial cruciate disease: current status of diagnosis, surgery, and risk for disease. *Vet Comp Orthopaed* 2003;16(03):122–126
- 26 Morris E, Lipowitz AJ. Comparison of tibial plateau angles in dogs with and without cranial cruciate ligament injuries. *J Am Vet Med Assoc* 2001;218(03):363–366
- 27 Caylor KB, Zumpano CA, Evans LM, Moore RW. Intra- and inter-observer measurement variability of tibial plateau slope from lateral radiographs in dogs. *J Am Anim Hosp Assoc* 2001;37(03):263–268
- 28 Reif U, Dejardin LM, Probst CW, DeCamp CE, Flo GL, Johnson AL. Influence of limb positioning and measurement method on the magnitude of the tibial plateau angle. *Vet Surg* 2004;33(04):368–375
- 29 Reif U, Probst CW. Comparison of tibial plateau angles in normal and cranial cruciate deficient stifles of Labrador Retrievers. *Vet Surg* 2003;32(04):385–389
- 30 Hazenfield KM, Nylund A, Valdes-Martinez A, et al. Accuracy of a radiographic stitching technique to measure tibial plateau angle in large and giant breed dogs. *Vet Comp Orthop Traumatol* 2014;27(03):230–235
- 31 Wilke VL, Conzemius MG, Besancon MF, Evans RB, Ritter M. Comparison of tibial plateau angle between clinically normal Greyhounds and Labrador Retrievers with and without rupture of the cranial cruciate ligament. *J Am Vet Med Assoc* 2002;221(10):1426–1429
- 32 Fox EA, Dycus DL, Leasure CS, Fox HA, Canapp SO Jr. Average tibial plateau of 3,922 stifles undergoing surgical stabilization for cranial cruciate ligament rupture. *Vet Comp Orthop Traumatol* 2020;33(03):167–173
- 33 Su L, Townsend KL, Au J, Wittum TE. Comparison of tibial plateau angles in small and large breed dogs. *Can Vet J* 2015;56(06):610–614
- 34 Aertsens A, Rincon Alvarez J, Poncet CM, Beaufrère H, Ragetly GR. Comparison of the tibia plateau angle between small and large dogs with cranial cruciate ligament disease. *Vet Comp Orthop Traumatol* 2015;28(06):385–390
- 35 Duerr FM, Duncan CG, Savicky RS, Park RD, Egger EL, Palmer RH. Risk factors for excessive tibial plateau angle in large-breed dogs with cranial cruciate ligament disease. *J Am Vet Med Assoc* 2007;231(11):1688–1691
- 36 Howe LM, Slater MR, Boothe HW, Hobson HP, Holcom JL, Spann AC. Long-term outcome of gonadectomy performed at an early age or traditional age in dogs. *J Am Vet Med Assoc* 2001;218(02):217–221
- 37 Seo BS, Jeong IS, Piao Z, et al. Measurement of the tibial plateau angle of normal small-breed dogs and the application of the tibial plateau angle in cranial cruciate ligament rupture. *J Adv Vet Anim Res* 2020;7(02):220–228
- 38 Comerford EJ, Tarlton JF, Avery NC, Bailey AJ, Innes JF. Distal femoral intercondylar notch dimensions and their relationship to composition and metabolism of the canine anterior cruciate ligament. *Osteoarthritis Cartilage* 2006;14(03):273–278
- 39 Muir P, Schwartz Z, Malek S, et al. Contralateral cruciate survival in dogs with unilateral non-contact cranial cruciate ligament rupture. *PLoS One* 2011;6(10):e25331
- 40 Kyllar M, Čížek P. Cranial cruciate ligament structure in relation to the tibial plateau slope and intercondylar notch width in dogs. *J Vet Sci* 2018;19(05):699–707
- 41 de Rooster H, Van Ryssen B, van Bree H. Diagnosis of cranial cruciate ligament injury in dogs by tibial compression radiography. *Vet Rec* 1998;142(14):366–368
- 42 Marino DJ, Loughin CA. Diagnostic imaging of the canine stifle: a review. *Vet Surg* 2010;39(03):284–295
- 43 Grierson J, Sanders M, Guitan J, Pead M. Comparison of anatomical tibial plateau angle versus observer measurement from lateral radiographs in dogs. *Vet Comp Orthop Traumatol* 2005;18(04):215–219
- 44 Buirkle CL, Aulakh KS, Gines JA, Rademacher N, Liu CC, Barnes K. Effect of tibial rotation on the tibial plateau angle measurement in dogs: an ex vivo study. *Vet Surg* 2019;48(03):408–416
- 45 Sabanci SS, Ocal MK. Lateral and medial tibial plateau angles in normal dogs. An osteological study. *Vet Comp Orthop Traumatol* 2014;27(02):135–140

- 46 Bogaerts E, Van der Vekens E, Verhoeven G, et al. Intraobserver and interobserver agreement on the radiographical diagnosis of canine cranial cruciate ligament rupture. *Vet Rec* 2018;182(17):484
- 47 Fettig AA, Rand WM, Sato AF, Solano M, McCarthy RJ, Boudrieau RJ. Observer variability of tibial plateau slope measurement in 40 dogs with cranial cruciate ligament-deficient stifle joints. *Vet Surg* 2003;32(05):471–478
- 48 Baroni E, Matthias RR, Marcellin-Little DJ, Vezzoni A, Stebbins ME. Comparison of radiographic assessments of the tibial plateau slope in dogs. *Am J Vet Res* 2003;64(05):586–589
- 49 Reif U. Influence of limb positioning and observation method on the measurement on the tibial plateau angle (abstr). Paper presented at: The Eleventh Annual American College of Veterinary Surgeons Symposium; October 11–14, 2001; Chicago, Illinois. Paper published as a Short Communication. *Vet Surg* 2001;30(05):505–505
- 50 Paley D. Normal lower limb alignment and joint orientation. In: Herzenberg JE, ed. *Principles of Deformity Correction*. Germany, Berlin: Springer-Verlag; 2002:1–18
- 51 Abel SB, Hammer DL, Shott S. Use of the proximal portion of the tibia for measurement of the tibial plateau angle in dogs. *Am J Vet Res* 2003;64(09):1117–1123
- 52 Stehlik L, Vignoli M, Proks P, Trnkova S, Necas A. A modified technique for radiographic measurement of the tibial plateau angle in dogs. *Vet Med-Czech* 2017;62(11):583–588
- 53 Dismukes DI, Tomlinson JL, Fox DB, Cook JL, Witsberger TH. Radiographic measurement of canine tibial angles in the sagittal plane. *Vet Surg* 2008;37(03):300–305
- 54 Osmond CS, Marcellin-Little DJ, Harrysson OLA, Kidd LB. Morphometric assessment of the proximal portion of the tibia in dogs with and without cranial cruciate ligament rupture. *Vet Radiol Ultrasound* 2006;47(02):136–141
- 55 Guénégo L, Payot M, Charru P, Verwaerde P. Comparison of tibial anatomical-mechanical axis angle between predisposed dogs and dogs at low risk for cranial cruciate ligament rupture. *Vet J* 2017;225:35–41
- 56 Pretorius ES, Fishman EK. Volume-rendered three-dimensional spiral CT: musculoskeletal applications. *Radiographics* 1999;19(05):1143–1160
- 57 Kessler MA, Burkart A, Martinek V, Beer A, Imhoff AB. Development of a 3-dimensional measuring method to determine the tibial slope in spiral CT. *Z Orthop Ihre Grenzgeb* 2003;141(02):143–147
- 58 Zhang Y, Chen Y, Qiang M, et al. Comparison between three-dimensional CT and conventional radiography in proximal tibia morphology. *Medicine (Baltimore)* 2018;97(30):e11632
- 59 Amirtharaj MJ, Hardy BM, Kent RN III, et al. Automated, accurate, and three-dimensional method for calculating sagittal slope of the tibial plateau. *J Biomech* 2018;79:212–217
- 60 Townsend S, Kim SE, Tinga S. Tibial plateau morphology in dogs with cranial cruciate ligament insufficiency. *Vet Surg* 2018;47(08):1009–1015
- 61 Guerrero TG, Geyer H, Hässig M, Montavon PM. Effect of conformation of the distal portion of the femur and proximal portion of the tibia on the pathogenesis of cranial cruciate ligament disease in dogs. *Am J Vet Res* 2007;68(12):1332–1337
- 62 Hashemi J, Chandrashekar N, Gill B, et al. The geometry of the tibial plateau and its influence on the biomechanics of the tibiofemoral joint. *J Bone Joint Surg Am* 2008;90(12):2724–2734
- 63 Hashemi J, Chandrashekar N, Mansouri H, et al. Shallow medial tibial plateau and steep medial and lateral tibial slopes: new risk factors for anterior cruciate ligament injuries. *Am J Sports Med* 2010;38(01):54–62
- 64 Ocal MK, Sabanci SS. Effect of anatomic variation in caudal tibial plateau on the tibial plateau angle in dogs: a cadaveric study. *J Small Anim Pract* 2013;54(10):537–540
- 65 Ritter MJ, Perry RL, Olivier NB, Kim SY, Dejardin LM. Tibial plateau symmetry and the effect of osteophytosis on tibial plateau angle measurements. *J Am Anim Hosp Assoc* 2007;43(02):93–98
- 66 Chen Y, Qiang M, Zhang K, Li H, Dai H. A reliable radiographic measurement for evaluation of normal distal tibiofibular syndesmosis: a multi-detector computed tomography study in adults. *J Foot Ankle Res* 2015;8:32