



# Prediction of Sentinel Lymph Node Biopsy Status in Breast Cancers with PET/CT Negative Axilla

Sheela Chinnappan<sup>1</sup> Piyush Chandra<sup>2</sup> Senthil Kumar<sup>3</sup> M.B. Sridev<sup>3</sup> Deepti Jain<sup>4</sup>  
Ganesan Chandran<sup>2</sup> Satish Nath<sup>2</sup>

<sup>1</sup>Department of Radio-diagnosis, Sri Ramachandra Institute of Higher Education and Research, Chennai, Tamil Nadu, India

<sup>2</sup>Department of Nuclear Medicine, MIOT International, Chennai, Tamil Nadu, India

<sup>3</sup>Department of Surgical Oncology, MIOT International, Chennai, Tamil Nadu, India

<sup>4</sup>Department of Pathology, MIOT International, Chennai, Tamil Nadu, India

Address for correspondence Piyush Chandra, MD, DNB, FEBNM, Department of Nuclear Medicine, MIOT International, Manapakkam, Chennai-600056, Tamil Nadu, India  
(e-mail: drpiyushchandrak@gmail.com).

World J Nuclear Med 2022;21:120–126.

## Abstract

**Background and Aim** Prior knowledge of axillary node status can spare a lot of patients with early breast cancer morbidity due to an unnecessary axillary dissection. Our study compared various metabolic and pathological features that can predict the sentinel lymph node biopsy (SLNB) status in patients with positron emission tomography/computed tomography (PET/CT) negative axilla.

**Patients and Methods** All consecutive patients with early breast cancers (< 5 cm) with PET/CT negative axilla who underwent breast surgery and SLNB from November 2016 to February 2020 were included. Various primary tumor (PT) pathological variables and metabolic variables on PET/CT such as maximum standardized uptake value (PT-SUV<sub>max</sub>), metabolic tumor volume (PT-MTV), and total lesion glycolysis (PT-TLG) were compared using univariate and multivariate analyses for prediction of SLNB status.

**Results** Overall 70 patients, all female, with mean age 55.6 years (range: 33–77) and mean tumor size 2.2 cm (range: 0.7–4.5), were included. SLNB was positive in 20% of patients ( $n = 14$ ) with nonsentinel nodes positive in 4% ( $n = 3$ ) patients. Comparing SLNB positive and negative groups, univariate analysis showed significant association of SLNB with low tumor grade, positive lymphovascular invasion (LVI), positive estrogen receptor (ER) status with lower mean Ki-67 index (34.41 vs. 52.02%;  $p = 0.02$ ), PT-SUV<sub>max</sub> (5.40 vs. 8.68;  $p = 0.036$ ), PT-MTV (4.71 cc vs. 7.46 cc;  $p = 0.05$ ), and PT-TLG (15.12 g/mL.cc vs. 37.10 g/mL.cc;  $p = 0.006$ ). On multivariate analysis, only LVI status was a significant independent predictor of SLNB status (odds ratio = 6.23; 95% confidence interval: 1.15–33.6;  $p = 0.033$ ).

**Conclusion** SLNB is positive in approximately 20% of early breast cancers with PET/CT negative axilla and SLNB status appears to be independent of PT size. SLNB+ PTs were

## Keywords

- ▶ sentinel lymph node biopsy
- ▶ breast cancers
- ▶ PET/CT negative axilla
- ▶ prediction

DOI <https://doi.org/10.1055/s-0042-1750333>.  
ISSN 1450-1147.

© 2022. World Association of Radiopharmaceutical and Molecular Therapy (WARMTH). All rights reserved.

This is an open access article published by Thieme under the terms of the Creative Commons Attribution-NonDerivative-NonCommercial-License, permitting copying and reproduction so long as the original work is given appropriate credit. Contents may not be used for commercial purposes, or adapted, remixed, transformed or built upon. (<https://creativecommons.org/licenses/by-nc-nd/4.0/>)

Thieme Medical and Scientific Publishers Pvt. Ltd., A-12, 2nd Floor, Sector 2, Noida-201301 UP, India

more likely to be LVI+ and ER + ve, with lower grade/ $K_r$ -67/metabolic activity ( $SUV_{max}/MTV/TLG$ ) compared with SLNB–ve tumors. Logistic regression analysis revealed LVI status as the only significant independent predictor of sentinel lymph node status.

## Introduction

GLOBOCAN 2018, produced by the International Agency for Research on Cancer, has estimated that breast cancer is the most common and leading cause of cancer deaths in India. With 162,468 cases per year, breast cancer is the most commonly diagnosed cancer (27.7%) and is the leading cause of deaths (23.5%) among females in India.<sup>1</sup> Treatment of breast cancer ranges from mastectomy to breast conservation surgery depending on tumor characteristics and patient factors.<sup>2</sup> Adjuvant chemotherapy, radiation, and hormone therapy are given as part of treatment protocol and help in reducing loco-regional recurrence and distant metastasis thus improving overall survival of patient.

Axillary lymph node dissection (ALND) has traditionally been an integral part of loco-regional therapy of breast cancer, which acts as both staging and therapeutic procedures. Since 2005, sentinel lymph node biopsy (SLNB) is the standard procedure for staging axilla in clinically node negative early breast cancer patients.<sup>3</sup> Sentinel lymph node (SLN) is defined as the first lymph node that receives lymphatic drainage from the primary tumor (PT), if cancer has spread to nodes. It is detected by various techniques like radiolabeled isotope, blue dye, indocyanine green, and many other upcoming modalities.<sup>4</sup> SNLB helps in reducing complications like seroma, wound edema, paresthesia, and arm mobility as compared with ALND.<sup>5</sup> Only 15 to 30% of patients undergoing SLNB have a positive node. The vast majority of 70 to 85% of them invariably are node negative.<sup>6</sup> Yet, they have to undergo a surgical procedure and its resultant morbidities. Older patients with T1N0 breast cancer can be treated by conservative breast surgery and no SLNB without adversely affecting breast cancer mortality or overall survival.<sup>7</sup>

The primary aim of the study was to ascertain the predictive factors of SLN status in early breast cancer patients who are at low risk of axillary metastases, that is, clinically and positron emission tomography/computed tomography (PET/CT) negative axilla.

## Patients and Methods

Our retrospective study analyzed consecutive patients with treatment naïve early breast cancer with fluorodeoxyglucose (FDG) PET/CT negative axilla who underwent breast surgery and SLNB in our hospital from November 2016 to March 2020. Patients fasted for 6 hours, and blood glucose was less than 180 mg/dL prior to the study in all patients. Then, 6 MBq/kg FDG was intravenously injected in the arm, and scans were acquired after 60 minutes. Imaging was performed on Discovery IQ 5 Ring block detector PET/CT (General Electric,

Milwaukee, WI), combining bismuth germanium oxide-based PET crystal and 16-slice CT components. CT and PET data were acquired from mid-thigh level to the top of the skull with the arms raised. Intravenous contrast was used in most eligible patients, and CT was of diagnostic quality. PET emission counts were collected over 2 minutes/table position, acquired in a three-dimensional mode with reconstruction done using Q.clear algorithm that has integrated correction for partial volume effects. PET/CT was read and evaluated by experienced nuclear medicine specialist. PET/CT was defined as negative for axillary disease if uptake of FDG was below the background activity in axilla and nodes measured less than 1 cm and/or showed intact fatty hilum. PT metabolic characteristics such as mean/maximum standardized uptake value ( $PT-SUV_{max}/SUV_{mean}$ ), metabolic tumor volume (PT-MTV), total lesion glycolysis (PT-TLG), and primary tumor-Liver (TL)  $SUV_{max}$  ratio were obtained by drawing region of interest over the PT using ADW 4.7 work station (General Electric, Milwaukee, WI). Patients with PET/CT positive axilla, multifocal/bilateral breast cancers, previous wide local excision, and previous chemotherapy/radiotherapy were excluded from the study.

SLNB was performed using both radiotracer and the intraoperative methylene blue dye injection. On the morning of surgery, with patient in supine position, using a tuberculin syringe, approximately 0.5 mCi/15 MBq  $^{99m}Tc$ -labeled human serum albumin nanocolloid was injected at two sites—one intradermal on skin overlying the tumor and another in the periareolar region of the same quadrant. Lymphoscintigraphy was done prior to shifting patient to operation theater on a dual-head gamma camera for 20 minutes or till any draining node was visualized. Intraoperatively, 0.5 mL of methylene blue dye was injected at the 9 o'clock position, at subareolar location of breast using an insulin syringe. A small inferior hair line axillary incision was made. The SLNs (both hot and blue nodes), hot nodes, blue nodes, and enlarged nodes were excised. Sentinel nodes were harvested using a handheld gamma probe Crystal Probe automatic CXS-OP-SP (Crystal Photonics GmbH, Berlin, Germany), a collimated reusable probe using the Cadmium-Zinc-Telluride detector, having energy range 60 to 511 keV. Excised SLNs were submitted for frozen section diagnosis. After careful gross examination, dissection of adipose tissue and several sampling cuts of tissues were done (smaller nodes in two while 3 to 5 mm cuts for bigger nodes). Sampling tissues were then processed by freezing them with frozen aerosol sprays and put into cryostat for sectioning (temperature between  $-20$  and  $-30^{\circ}C$ ) and finally the tissue stained with Hematoxylin and Eosin–H&E—for microscopic evaluation by an experienced pathologist. Criteria normally used for the positive

sentinel node was probe counts more than 10 times the background activity. SLNB was defined as false negative if the excised sentinel node was negative on frozen section but same node or other excised nonsentinel/enlarged nodes were positive on final histopathological evaluation. Immunohistochemistry information was available for all patients. As for detecting predictors of SLN metastasis, the quantitative variables were compared with Mann-Whitney *U* test and the categorical variables were compared with chi-square tests/Fisher's exact test. Multivariate analysis using logistic regression was performed to test the independent predictors for all significant variables from the univariate analysis. The significance threshold was set at *p*-value less than 0.05. SPSS software, version 20.0 (SPSS, Inc. Chicago, Illinois, United States), was used for all of the statistical analyses.

## Results

Overall 70 patients, all female, were recruited with mean age 55.6 years (range: 33–77 years). Patient characteristics are summarized in ►Table 1. Most patients were postmenopausal (64.2%) with T-staging as T1 (< 2 cm) in 38 patients (T1a, 0; T1b, 3; T1c, 35) and T2 (2–5 cm) in 32 patients. On immunohistochemistry, majority of the patients were positive for estrogen receptor (ER; 72.9%) and progesterone receptor (PR; 74.3%) and negative for human epidermal growth factor receptor 2 (HER2; 68.6%). Immunophenotype was Luminal A (ER+/PR+/HER2-; Ki-67 < 40%) in 37% (*n* = 26), Luminal B (ER/PR+; HER2 +/-; Ki-67 > 40%) in 44.2% (*n* = 31), HER2 amplified in 8.5% (*n* = 6), and triple-negative breast cancers or TNBCs (ER/PR/HER2-) in 10% (*n* = 7). Intraoperative findings showed total 188 sentinel nodes with average 2.7 nodes per patient; 46 hot nodes, 27 blue nodes, 115 hot and blue nodes, and 195 enlarged nodes. SLNB was positive in 20% (*n* = 14) patients and nonsentinel node positive disease was confirmed in 4.2% of patients (*n* = 3) on final histopathology evaluation. The sensitivity of combined Tc-99m-nanocolloid and intraoperative methylene blue dye injection technique was 95.7% with false negative rate of 4.2%. Sentinel nodes were positive in 31% of the T1c tumors and 18% of the T2 tumors.

On univariate analysis (►Tables 2 and 3), there was no significant difference in mean age (56.71 vs. 55.28, *p* = 0.633), mean tumor size (1.97 vs. 2.29 cm, *p* = 0.135), PR status (*p* = 0.13), HER2 receptor status (*p* = 0.420), and immunophenotype status (*p* = 0.122) between SLNB positive and negative groups. There was significant difference in tumor grade (*p* = 0.013), ER status (*p* = 0.0023), lymphovascular invasion (LVI) status (*p* = 0.004), mean Ki-67 index (34.41 vs. 52.02, *p* = 0.02), PT-SUV<sub>max</sub> (5.40 vs. 8.68, *p* = 0.036; ►Fig. 1), PT-SUV<sub>mean</sub> (3.32 vs. 5.44, *p* = 0.041), PT-MTV (4.71 vs. 7.46, *p* = 0.05), PT-TLG (15.12 vs. 37.10, *p* = 0.006), and TL ratio (1.55 vs. 2.65, *p* = 0.03) between SLNB positive and negative groups. On multivariate analysis, only LVI status showed statistical significance in predicting the sentinel node status (odds ratio = 6.23; 95% confidence interval: 1.15–33.6; *p* = 0.033; ►Table 4)

**Table 1** Patients and primary tumor characteristics

	No.	Percentage
Age (years)		
◦ ≤ 50	25	35.7
◦ > 50	45	64.2
Primary tumor size (range: 0.7–4.5 cm)		
◦ ≤ 2 cm	38	54.2
◦ > 2 cm	32	45.8
Grade		
◦ Low (I/II)	44	62.9
◦ High (III)	26	37.1
Estrogen receptor		
◦ Positive	51	72.9
◦ Negative	19	27.1
Progesterone receptor		
◦ Positive	52	74.3
◦ Negative	18	25.7
HER2 receptor		
◦ Positive	22	31.4
◦ Negative	48	68.6
Immunophenotype		
◦ Luminal (A/B)	57	81.4
◦ Nonluminal (HER2/TNBC)	13	18.6
◦ < 40	28	40
◦ ≥ 40	42	60
Lymphovascular Invasion		
◦ Positive	41	58.6
◦ Negative	29	41.4

Abbreviations: HER2, human epidermal growth factor receptor 2; TNBC, triple-negative breast cancer.

## Discussion

About 50% of patients with early breast cancers (primary breast tumors less than 5 cm with clinically negative axilla) do not have axillary nodes positive on SLNB or ALND. Apart from the excessive surgical morbidity, there are other limitations such as cost, availability of nuclear medicine centers, and trained surgical expertise, especially in developing nations.<sup>8,9</sup> Hence, it is important to identify patients with early breast cancers in whom SLNB can be avoided. One obvious way of avoiding SLNB is to detect all positive preoperatively axillary nodes by ultrasound-guided fine-needle aspiration cytology (US-FNAC)<sup>10</sup> or noninvasively by PET/CT and proceed for ALND.<sup>11</sup> However, in case of PET/CT/US-FNAC negative axilla, the conundrum of the surgeon can be sorted out by identifying clinico-pathological factors predicting the sentinel node status.

**Table 2** Univariate analysis of quantitative primary tumor variables using Mann–Whitney *U* test

Variables	Positive SLNB (Mean ± SD)	Negative SLNB (Mean ± SD)	p-Value
Mean age	56.71 ± 9.7	55.28 ± 10.9	0.633
Mean PT size (cm)	1.97 ± 0.67	2.29 ± 0.85	0.135
Mean PT SUV <sub>max</sub> (g/mL)	5.40 ± 2.2	8.68 ± 5.93	0.036
Mean PT SUV <sub>mean</sub> (g/mL)	3.32 ± 1.49	5.44 ± 3.95	0.041
Mean MTV (cc)	4.71 ± 4.7	7.46 ± 7.43	0.058
Mean TLG (g/mL.cc)	15.12 ± 17.9	37.10 ± 44.16	0.006
Mean T/L SUV <sub>max</sub> ratio	1.55 ± 0.73	2.65 ± 1.92	0.034
Mean K <sub>r</sub> -67 (%)	34.41 ± 16.1	52.02 ± 24.7	0.024

Abbreviations: MTV, metabolic tumor volume; PT, primary tumor; SD, standard deviation; SLNB, sentinel lymph node biopsy; SUV<sub>max</sub>, maximum standardized uptake value; SUV<sub>mean</sub>, mean standardized uptake value; T/L, primary tumor-Liver; TLG, total lesion glycolysis.

**Table 3** Univariate analysis of qualitative primary tumor variables using chi-squared test

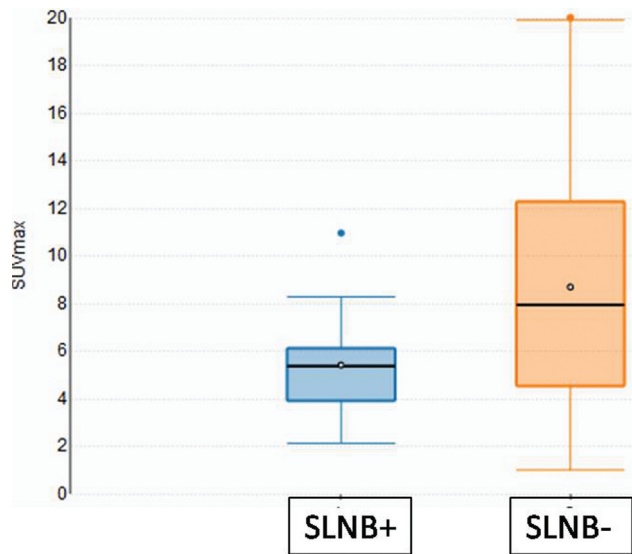
Variables	Positive SLNB	Negative SLNB	p-Value
Grade			
◦ Low grade (I/II)	15	29	0.013
◦ High grade (III)	2	24	
LVI			
◦ Positive	15	26	0.004
◦ Negative	2	27	
ER			
◦ Positive	16	35	0.023
◦ Negative	1	18	
PR			
◦ Positive	15	37	0.130
◦ Negative	2	16	
HER2			
◦ Positive	4	18	0.420
◦ Negative	13	35	
Immunophenotype			
◦ Luminal type (A/B)	16	41	0.122
◦ Nonluminal type	1	12	

Abbreviations: ER, estrogen receptors; HER2, human epidermal growth factor receptor 2; LVI, lymphovascular invasion; PR, progesterone receptor; SLNB, sentinel lymph node biopsy.

There are several studies published in the past two decades to identify clinico-pathological factors predicting SLN status in early breast cancers<sup>12-19</sup> (► **Table 5**). Most of these studies were retrospective studies done in early breast cancers and used multivariate analysis to identify various predictive factors. The sample size in these studies ranged from 157 to 4,351 and sentinel node biopsy (SNB) positivity rate ranged from 26 to 37.6%. Reviewing these studies, we can conclude that the size of the PTs and LVI are the two most common and consistent predictors of sentinel node status and these should definitely be considered when offering SNB

to early breast cancer patients. Other factors that were also identified in these studies were ductal histology (compared with lobular/mucinous/medullary), outer quadrant location of tumor, and multifocality, with some studies also identifying hormone receptor status as the predictive factors.

In our study, we recruited only early operable breast cancer patients (T1/T2) with PET/CT negative axilla. Using combination of Tc-nanocolloid and methylene blue dye, we found positive SNB in 20% patients (*n* = 14) and metastasis in nonsentinel nodes in approximately 4.2% (*n* = 3). The sensitivity of the SNLB procedure was 95.7% and false



**Fig. 1** Boxplot to show correlation of primary tumor maximum standardized uptake value ( $SUV_{max}$ ) with sentinel lymph node biopsy (SLNB) status.

negative rate 4.3%. We evaluated several tumor-specific pathological variables that could predict the sentinel node status. Using univariate analysis, we found that the SLNB positive patients were more likely to be low-grade tumors, having lower  $K_i$ -67 index, more likely to be ER + , more likely

to be have LVI, and more likely to be Luminal A/B subtype compared with HER2 amplified or TNBC subtypes. However, on multivariate analysis, only LVI was significant predictor of SLN status. Unlike previous studies, we did not find PT size to be a significant predictor of SLN status even on univariate analysis. This could be due to small sample size or because of larger proportion of our study patients having small PTs with overall mean tumor size of 2.2 cm. The other reason could be impact of molecular characteristic of PT on incidence of axillary node metastases. Reyal et al showed that ER +ve/HER2+ tumors show strong and almost linear correlation between PT size and percentage of axillary metastases. However, in ER/HER2- tumors, the nodal status was found to be independent of tumor size with a constant trend of positive axillary nodes at approximately 20%.<sup>20</sup> Also, aggressive tumors such as TNBC have been shown to be having low risk of axillary node status and are believed to have predilection for hematogenous spread instead.<sup>21</sup> In our study too we found that all patients (except one patient) with SLNB +ve disease had Luminal type A/B disease with strong hormone receptor positivity. Hence, based on our results we recommend that PT size should not be used as sole criteria for choosing patients for SLNB who have PET/CT negative axilla and consideration should also be given to molecular features of the PT for better patient selection for SLNB.

Semiquantitative variables such as  $SUV_{max}$  of the PT obtained using FDG PET/CT have been shown to have a

**Table 4** Multivariate logistic regression analysis of variables significant on univariate analysis

Variables	OR	95% CI	p-Value
Grade	3.422	0.506–23.158	0.207
LVI	6.232	1.156–33.605	0.033
ER	3.370	0.297–38.186	0.327
$K_i$ -67	1.007	0.974–1.042	0.674
PT- $SUV_{max}$	0.973	0.053–17.87	0.985
PT-SUVmean	0.867	0.009–79.38	0.951
PT-TLG	1.021	0.987–1.057	0.227
T/L- $SUV_{max}$ ratio	1.591	0.174–14.572	0.681

Abbreviations: CI, confidence interval; ER, estrogen receptors; LVI, lymphovascular invasion; OR, odds ratio; PT, primary tumor;  $SUV_{max}$ , maximum standardized uptake value; SUVmean, mean standardized uptake value; T/L, primary tumor-Liver; TLG, total lesion glycolysis.

**Table 5** Summary of various studies done to predict sentinel lymph node status in early breast cancers

Study authors, year	No. of patients	Patient profile	SLNB positivity	Significant predictive factors of sentinel node status by multivariate analysis
Postaci et al, 2013 <sup>14</sup>	157	T1/T2	37.6%	Size and LVI
Chen et al, 2002 <sup>12</sup>	250	T1/T2	28.4%	Size and LVI
Ozmen et al, 2006 <sup>13</sup>	400	T1/T2	38.5%	Size and LVI
Capdet et al, 2009 <sup>15</sup>	1,416	T1/T2/T3	26%	Size, location, histotype, and LVI
Viale et al, 2005 <sup>16</sup>	4,351	T1–T4	33.2%	Size, multifocality, histotype, LVI, and PR status
Majid et al, 2018 <sup>17</sup>	2,552	T1–T4	26.3%	Size, multifocality, LVI, and ER status

Abbreviations: ER, estrogen receptors; LVI, lymphovascular invasion; PR, progesterone receptor; SLNB, sentinel lymph node biopsy.

very strong correlation with pathological and biological prognostic factors in breast cancer.<sup>22</sup> Although there are studies that have explored the utility of the PET/CT in prediction of axillary nodal metastases by analyzing the  $SUV_{max}$  of the primary breast tumor, there is hardly any evidence linking the primary metabolic tumor characteristics and SLN status.<sup>23,24</sup> Using various metabolic information from preoperative PET/CTs, we found that PTs of SLNB+ patients were more likely to have a lower  $SUV_{max}$  (mean: 5.40), lower  $SUV_{mean}$  (mean: 3.32), lower MTV (mean: 4.71), lower TLG (mean: 15.12), and lower TL  $SUV_{max}$  ratio (mean: 1.55), compared with patients with SLNB-ve (mean: values of 8.68, 5.44, 7.46, 37.10, and 2.65, respectively). Low-grade activity metabolic patterns of SLNB +ve patients are consistent with favorable pathological characteristics that were also noted in our SLNB +ve compared with SLNB-ve patients, signifying the strong  $SUV_{max}$ -histology correlation in predicting SLN status. However, this predicting ability of metabolic variables, although significant on univariate analysis, did not show statistical significance on multivariate analysis. Larger prospective studies are needed to ascertain the clinical utility of metabolic information on PET/CT in predicting SLN status.

To our knowledge, our study is first of its kind attempting to identify predictive factors of sentinel node status in a group of early breast cancers patients with PET/CT negative axilla (most studies used clinical examination as the criteria to define preoperative axillary status). One of the most important findings of our study was that size of the PT was not a significant factor in determining the sentinel node status, a result contrary to previous studies. In addition, we found a strong negative association between metabolic features of PT and sentinel node status when patients' preoperative PET/CT scan is negative for axillary node involvement (i.e., PTs with low SUV values were more likely to be SLNB positive than those with higher values). Lastly, but most importantly, the SLNB positivity of approximately 20%, along with 4% of nonsentinel node positivity, found in our study clearly demonstrates that majority (close to 75% patients) early breast cancers, especially high grade/hormone receptor negative, with PET/CT negative axilla may not need SLNB or axillary dissection.

Major limitation of our study was the small sample size and its retrospective design. Although many factors were predictive of sentinel node status on univariate analysis, only LVI was found to be significant as an independent predictor on multivariate analysis. This could be due to small sample size or probable selection bias as is the case with retrospective study designs. Although LVI status was found to be a significant factor, it is available only on postoperative histopathology specimens. Larger studies are needed to identify preoperative factors for the surgeon to decide on avoiding SLNB in low-risk patients.

## Conclusion

In patients with early breast cancer and preoperative PET/CT negative axilla, SLNB is positive in approximately 20% patients with nonsentinel node positivity of approximately

4.2%. In this group of patients, we found SLNB status to be independent of PT size. PTs with positive sentinel nodes were more likely to be LVI +, ER +ve, and with lower grade, lower proliferation rate ( $K_i$ -67%), and lower metabolic activity ( $SUV_{max}/SUV_{mean}$ , MTV, TLG) compared with PTs with negative sentinel nodes. Among the several PT characteristics analyzed using logistic regression analysis, we found only positive LVI as the significant independent predictor of SLN status.

## Conflict of Interest

None declared.

## References

- 1 Dar M, Sharma K. Burden of cancer in India: GLOBOCAN 2018 Estimates Incidence, Mortality, prevalence and future projections of cancer in India. *Burden Cancer India* 2019
- 2 Fisher B, Bauer M, Margolese R, et al. Five-year results of a randomized clinical trial comparing total mastectomy and segmental mastectomy with or without radiation in the treatment of breast cancer. *N Engl J Med* 1985;312(11):665-673
- 3 Lyman GH, Giuliano AE, Somerfield MR, et al; American Society of Clinical Oncology. American Society of Clinical Oncology guideline recommendations for sentinel lymph node biopsy in early-stage breast cancer. *J Clin Oncol* 2005;23(30):7703-7720
- 4 Ahmed M, Purushotham AD, Douek M. Novel techniques for sentinel lymph node biopsy in breast cancer: a systematic review. *Lancet Oncol* 2014;15(08):e351-e362
- 5 Veronesi U, Viale G, Paganelli G, et al. Sentinel lymph node biopsy in breast cancer: ten-year results of a randomized controlled study. *Ann Surg* 2010;251(04):595-600
- 6 Park KU, Caudle A. Management of the axilla in the patient with breast cancer. *Surgical Clinics*, 2018surgical.theclinics.com
- 7 Martelli G, Boracchi P, De Palo M, et al. A randomized trial comparing axillary dissection to no axillary dissection in older patients with T1N0 breast cancer: results after 5 years of follow-up. *Ann Surg* 2005;242(01):1-6, discussion 7-9
- 8 Chandra P, Ravichander SK, Babu SM, Jain D, Nath S. Evaluation of diagnostic accuracy and impact of preoperative positron emission tomography/computed tomography in the management of early operable breast cancers. *Indian J Nucl Med* 2020;35(01):40-47
- 9 Parmar V, Hawaldar R, Nair NS, et al. Sentinel node biopsy versus low axillary sampling in women with clinically node negative operable breast cancer. *Breast* 2013;22(06):1081-1086
- 10 Cools-Lartigue J, Sinclair A, Trabulsi N, et al. Preoperative axillary ultrasound and fine-needle aspiration biopsy in the diagnosis of axillary metastases in patients with breast cancer: predictors of accuracy and future implications. *Ann Surg Oncol* 2013;20(03):819-827
- 11 Veronesi U, De Cicco C, Galimberti VE, et al. A comparative study on the value of FDG-PET and sentinel node biopsy to identify occult axillary metastases. *Ann Oncol* 2007;18(03):473-478
- 12 Chen M, Palleschi S, Khojenezhad A, Gecelter G, Marini CP, Simms HH. Role of primary breast cancer characteristics in predicting positive sentinel lymph node biopsy results: a multivariate analysis. *Arch Surg* 2002;137(05):606-609, discussion 609-610
- 13 Ozmen V, Karanlik H, Cabioglu N, et al. Factors predicting the sentinel and non-sentinel lymph node metastases in breast cancer. *Breast Cancer Res Treat* 2006;95(01):1-6
- 14 Postacı H, Zengel B, Yaraş U, et al. Sentinel lymph node biopsy in breast cancer: predictors of axillary and non-sentinel lymph node involvement. *Balkan Med J* 2013;30(04):415-421

- 15 Capdet J, Martel P, Charitansky H, et al. Factors predicting the sentinel node metastases in T1 breast cancer tumor: an analysis of 1416 cases. *Eur J Surg Oncol* 2009;35(12):1245–1249
- 16 Viale G, Zurrida S, Maiorano E, et al. Predicting the status of axillary sentinel lymph nodes in 4351 patients with invasive breast carcinoma treated in a single institution. *Cancer* 2005;103(03):492–500
- 17 Majid S, Rydén L, Manjer J. Predictive factors for sentinel node metastases in primary invasive breast cancer: a population-based cohort study of 2552 consecutive patients. *World J Surg Oncol* 2018;16(01):54
- 18 Ding J, Jiang L, Wu W. Predictive value of clinicopathological characteristics for sentinel lymph node metastasis in early breast cancer. *Med Sci Monit* 2017;23:4102–4108
- 19 Mao F, Yao R, Peng L, Zhao J-L, Liang Z-Y, Sun Q. Predictive clinicopathological characteristics affecting sentinel lymph node metastasis in early breast cancer patients. *Med Sci Monit* 2017;6(05):968–975
- 20 Reyal F, Rouzier R, Depont-Hazelzet B, et al. The molecular subtype classification is a determinant of sentinel node positivity in early breast carcinoma. *PLoS One* 2011;6(05):e20297
- 21 Bertucci F, Finetti P, Birnbaum D. Basal breast cancer: a complex and deadly molecular subtype. *Curr Mol Med* 2012;12(01):96–110
- 22 Groheux D, Giacchetti S, Moretti JL, et al. Correlation of high 18F-FDG uptake to clinical, pathological and biological prognostic factors in breast cancer. *Eur J Nucl Med Mol Imaging* 2011;38(03):426–435
- 23 Song BI, Kim HW, Won KS. Predictive value of <sup>18</sup>F-FDG PET/CT for axillary lymph node metastasis in invasive ductal breast cancer. *Ann Surg Oncol* 2017;24(08):2174–2181
- 24 Sun WY, Choi YJ, Song Y-J. Prediction of axillary nodal status according to the axillary lymph node to primary breast tumor maximum standardized uptake value ratio on 18F-fluorodeoxyglucose positron emission tomography/computed tomography. *J Breast Dis* 2016;4(02):92–99