



# Comparison of Endovascular Therapy for Ruptured Cerebral Aneurysm during Spasm and Nonspasm Period

Tomoya Kamide<sup>1</sup> Kouichi Misaki<sup>1</sup> Taishi Tsutsui<sup>1</sup> Iku Nambu<sup>1</sup> Akifumi Yoshikawa<sup>1</sup>  
Mitsutoshi Nakada<sup>1</sup>

<sup>1</sup>Department of Neurosurgery, Kanazawa University, Kanazawa, Ishikawa, Japan

Address for correspondence Tomoya Kamide, MD, PhD, Department of Neurosurgery, Kanazawa University, 13-1 Takara-machi, Kanazawa, Ishikawa, Japan (e-mail: kamide@med.kanazawa-u.ac.jp).

AJNS 2022;17:412–415.

## Abstract

**Objective** Cerebral vasospasm complicates the treatment of aneurysmal subarachnoid hemorrhage, and the optimal timing of surgery for ruptured intracranial aneurysm diagnosed during the cerebral vasospasm period has been a matter of debate. This study aimed to clarify the differences in endovascular treatment outcomes between the timing of intervention during spasm and nonspasm.

**Methods and Materials** We retrospectively reviewed 68 consecutive patients with ruptured cerebral aneurysms who underwent coil embolization between January 2016 and March 2021. Clinical presentations, radiographic findings, and outcomes were retrospectively reviewed and compared between patients who were treated at the time of spasm and nonspasm. Information regarding the following clinical characteristics was collected: age, sex, World Federation of Neurosurgical Societies (WFNS) grade on admission, aneurysm morphology, treatment result, and outcome. We defined from day 4 to day 14 as the timing of spasm, and vasospasm as more than 30% narrowing of the proximal anterior cerebral artery, middle cerebral artery, and internal carotid artery segment during the second examination compared with the first. The chi-squared test or Fisher's exact test were performed to evaluate the covariates for binary categorical dependent variables as appropriate, and nonnormal variables were compared using the Mann–Whitney *U* test.

**Results** Ten patients (14.7%) underwent coil embolization at the time of vasospasm. Age, sex, WFNS grade, and aneurysm morphology were not different between the spasm and nonspasm groups. Additionally, there were no significant between-group differences in volume embolization ratio, procedure-related complications, occurrence of delayed cerebral ischemia, and outcome at discharge.

**Conclusion** There were no significant between-group differences in treatment results and outcomes between the spasm and nonspasm groups. Endovascular treatment at the time of vasospasm could be the optimal treatment method for ruptured cerebral aneurysms.

## Keywords

- ▶ endovascular treatment
- ▶ cerebral aneurysm
- ▶ vasospasm
- ▶ treatment outcome

DOI <https://doi.org/10.1055/s-0042-1750782>.  
ISSN 2248-9614.

© 2022. Asian Congress of Neurological Surgeons. All rights reserved.

This is an open access article published by Thieme under the terms of the Creative Commons Attribution-NonDerivative-NonCommercial-License, permitting copying and reproduction so long as the original work is given appropriate credit. Contents may not be used for commercial purposes, or adapted, remixed, transformed or built upon. (<https://creativecommons.org/licenses/by-nc-nd/4.0/>)

Thieme Medical and Scientific Publishers Pvt. Ltd., A-12, 2nd Floor, Sector 2, Noida-201301 UP, India

## Key Messages

Endovascular treatment at the time of vasospasm could be the optimal treatment method for ruptured cerebral aneurysms.

## Introduction

Cerebral vasospasm complicates the treatment of aneurysmal subarachnoid hemorrhage (SAH), and microsurgical clipping during the vasospasm period was considered to be the worst timing of aneurysm treatment after SAH.<sup>1–3</sup> In recent years, endovascular coil embolization for ruptured cerebral aneurysms has become the mainstay of treatment, but it is controversial whether this treatment at the time of spasm is suitable. We reviewed our treatment outcome to clarify whether coil embolization for ruptured cerebral aneurysm during the spasm period is safe and effective.

## Methods and Materials

### Study Population and Data Collection

A total of 68 consecutive patients with ruptured cerebral aneurysms who underwent coil embolization at our institute between January 2016 and March 2021 were included in the analysis. We retrospectively reviewed the medical records and radiographic studies in our database. All patients were clinically assessed using the World Federation Neurological Surgeons (WFNS) grading scale at the time of admission. Clinical outcomes were assessed at the time of discharge using the modified Rankin Scale (mRS), and a good prognosis was defined as mRS 0–2.

We defined procedural complications as perioperative stroke including in asymptomatic patients, nonspotty infarction confirmed by postoperative magnetic resonance imaging (MRI), and hemorrhagic complications at the puncture site that required additional treatment such as manual compression or surgical closure. We defined from day 4 to day 14 as the timing of spasm, and vasospasm as more than 30% narrowing of the proximal anterior cerebral artery, middle cerebral artery, and internal carotid artery segments during the second examination compared with the first. Two neurosurgeons (T.K. and K.M.) evaluated the occurrence of vasospasm. Delayed cerebral ischemia (DCI) was defined as delayed new neurological deficit that was not assigned to any other cause.

This study was approved by our Institutional Review Board (3577–1), and individual patient consent was not required as this was a retrospective study.

### Statistical Analysis

All statistical analyses were performed using the commercially available software SPSS version 25 (IBM Corp, Armonk, New York, United States). Quantitative variables are expressed as the mean  $\pm$  standard deviation. The chi-squared test or Fisher's exact test were performed to evaluate the covariates for binary categorical dependent variables, as appropriate. Normality of the data was evaluated using the

Shapiro–Wilk test. Nonnormal variables were compared using the Mann–Whitney *U* test. *p*-Values of less than 0.05 were considered statistically significant.

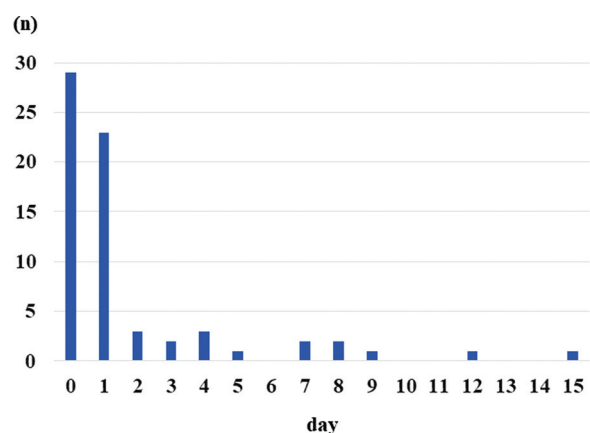
## Results

The timing of endovascular treatment in the patients included in this study is shown in **Fig. 1**. Among the 68 included patients, 10 (14.7%) underwent coil embolization during the spasm period. **Table 1** shows the clinical characteristics of the patients included in this study. Age, sex, and WFNS grade on admission showed no significant differences between the groups, but all except one patient in spasm group were WFNS grade 1 to 3. Concerning aneurysm location, only patients without posterior circulation aneurysm were included in the spasm group, but there were no differences in aneurysm morphology between the two groups.

Comparison of the treatment results between the spasm and nonspasm groups is summarized in **Table 2**. There were no significant between-group differences in volume embolization ratio, procedural complications, occurrence of hydrocephalus, development of DCI, and quality of outcome at discharge. In the nonspasm group, procedural complications were relatively frequent but the majority of those were asymptomatic, nonspotty infarction confirmed by postoperative MRI. Although 5 of 10 patients in the spasm group were confirmed to have mild to moderate angiographic spasm during the treatment, all procedures were completed. However, one patient developed a large infarction due to the progression of vasospasm immediately after endovascular treatment (**Fig. 2**).

## Discussion

Treatment of the ruptured aneurysm should be performed within 3 days after SAH to prevent rebleeding, because rebleeding from a ruptured aneurysm markedly decreases the chance of good recovery.<sup>4</sup> However, in patients diagnosed with aneurysmal SAH it is debatable whether aneurysm repair should be performed at the time of vasospasm. Aneurysm repair at the time of vasospasm (especially



**Fig. 1** The timing of endovascular treatment in patients included in this study.

**Table 1** Patient demographics included in this study

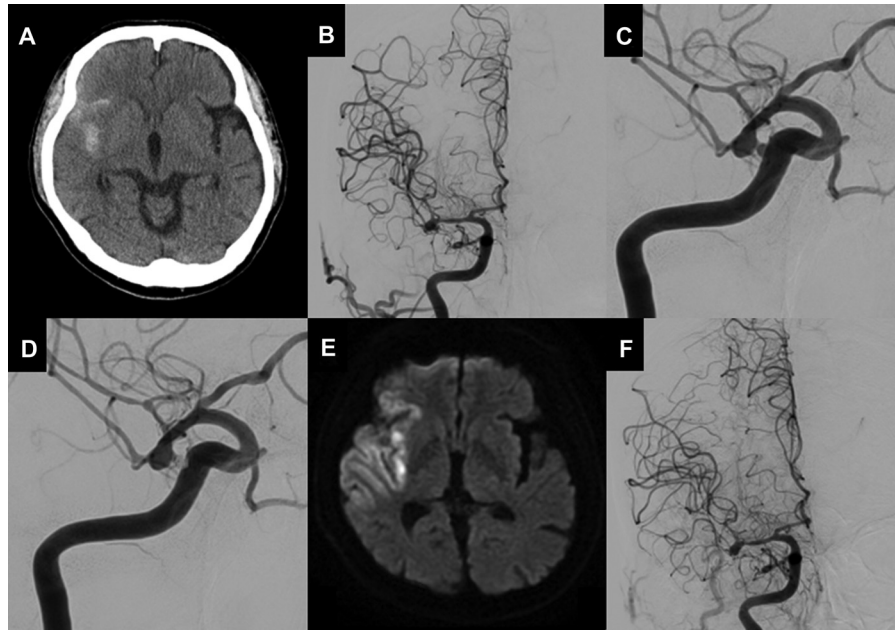
Variables	Nonspasm group (n = 58)	Spasm group (n = 10)	p-Value
Age, y	61.6 ± 12.8	57.4 ± 10.8	0.52
Females, n (%)	37 (63.8)	3 (30.0)	0.05
WFNS grade 1–3, n (%)	40 (69.0)	9 (90.0)	0.16
Aneurysm size, mm	8.2 ± 5.2	8.8 ± 6.0	0.98
Aneurysm location, n (%)			
ICA	19 (32.8)	4 (40.0)	0.21
ACA	20 (34.5)	5 (50.0)	
MCA	2 (3.4)	1 (10.0)	
P.C.	17 (29.3)	0 (0)	
Dissection, n (%)	7 (12.1)	0 (0)	0.31

Abbreviations: ACA, anterior cerebral artery; ICA, internal carotid artery; MCA, middle cerebral artery; P.C., posterior circulation; WFNS, World Federation of Neurosurgical Societies.

**Table 2** Comparison of treatment results between nonspasm and spasm groups

Variables	Nonspasm group (n = 58)	Spasm group (n = 10)	p-Value
VER, %	23.7 ± 4.9	25.1 ± 6.2	0.68
Procedural complications, n (%)	13 (22.4)	1 (10.0)	0.34
Hydrocephalus, n (%)	13 (22.4)	0 (0)	0.10
Angiographical vasospasm, n (%)	34 (58.6)	5 (50.0)	0.43
DCI, n (%)	15 (25.9)	4 (40.0)	0.29
mRS 0–2 at discharge, n (%)	30 (51.7)	8 (80.0)	0.09

Abbreviations: DCI, delayed cerebral ischemia; mRS, modified Rankin Scale; VER, volume embolization ratio.



**Fig. 2** A 67-year-old man presented with moderate headache and was diagnosed with subarachnoid hemorrhage on day 7 (A). Cerebral angiography demonstrated a ruptured right middle cerebral artery (MCA) aneurysm with moderate vasospasm (B). The aneurysm had relatively conspicuous bleb formation, but thought to be difficult to obtain complete obliteration by endovascular treatment because of wide neck and peripheral location (C). We planned endovascular treatment only for bleb formation on day 7 following microsurgical clipping after the period of vasospasm (D). However, the patient developed severe left-sided hemiparesis on day 8 and diffusion-weighted magnetic resonance imaging demonstrated large infarction of right hemisphere (E). Cerebral angiography on day 8 revealed narrowing of peripheral MCA compared with that on day 7, indicating worsening of vasospasm (F).

microsurgical clipping on days 5 to 10) has been reported to worsen DCI and to result in poor outcomes.<sup>5,6</sup> Conversely, the risk of rebleeding in patients awaiting a postponed aneurysm repair needs to be addressed. Several authors discussed this issue, but currently the optimal timing and treatment modality in patients diagnosed at the time of vasospasm are still under debate.

Recently, endovascular treatment has become a first-line modality for ruptured aneurysms, but it is unclear whether this treatment can be performed safely and effectively in patients at the time of vasospasm.<sup>7</sup> Lawson et al reported that they performed endovascular coil embolization safely on SAH patients during the vasospasm period.<sup>8</sup> Additionally, they mentioned that coil embolization during vasospasm can provide an opportunity to treat vasospasm at the time of the coiling procedure. Conversely, Dorhout et al reported that coil embolization between days 5 to 10 did increase the chance of DCI, but was not associated with poor outcome.<sup>9</sup> Our study demonstrates that the clinical outcome of endovascular treatment is not influenced by the timing of surgery in our setting, although one patient developed a large infarction immediately after successful endovascular treatment. In this representative case, endovascular treatment might induce DCI resulting in a large infarction. Further analyses are needed to clarify these issues in conjunction with progress of endovascular techniques and the design of new devices.

Endovascular coiling for ruptured cerebral aneurysm during vasospasm has been reported to be dangerous, especially in cases with severe vasospasm.<sup>2,3,5</sup> However, several authors reported the simultaneous endovascular treatment of a ruptured aneurysm and symptomatic vasospasm using balloon angioplasty and/or intra-arterial nimodipine.<sup>2,3,10,11</sup> Fortunately, there were no patients with severe vasospasm at the time of procedures requiring an adjunctive technique in this series. The safety and effectiveness of endovascular treatment during vasospasm should be reevaluated including in patients with severe spasm who require complicated endovascular techniques.

There were several limitations in this study. First, this was a retrospective, nonrandomized, single-center study, and our small sample size may not have reached statistical significance. Second, all patients except one in the spasm group had WFNS grades 1 to 3, which may strongly reflect the clinical outcome. Third, patients with severe spasm on presentation were not included. Well-powered studies are necessary to validate our results further.

## Conclusion

Although the majority of patients in the spasm group were WFNS grade 1 to 3 and none of these had severe spasm at the time of procedure, there were no significant differences in treatment outcome between spasm and nonspasm groups. Endovascular coil embolization at the time of spasm might be the optimal treatment option if the procedure can be completed successfully.

### Conflict of Interest

None declared.

## References

- Solomon RA, Onesti ST, Klebanoff L. Relationship between the timing of aneurysm surgery and the development of delayed cerebral ischemia. *J Neurosurg* 1991;75(01):56–61
- Sugiu K, Katsumata A, Ono Y, Tamiya T, Ohmoto T. Angioplasty and coiling of ruptured aneurysm with symptomatic vasospasm: technical case report. *Surg Neurol* 2003;59(05):413–417, discussion 417 [discussion 7]
- Wanke I, Dörfler A, Dietrich U, Aalders T, Forsting M. Combined endovascular therapy of ruptured aneurysms and cerebral vasospasm. *Neuroradiology* 2000;42(12):926–929
- Whitfield PC, Kirkpatrick PJ. Timing of surgery for aneurysmal subarachnoid haemorrhage. *Cochrane Database Syst Rev* 2001;2(02):CD001697
- Kassel NF, Torner JC, Jane JA, Haley EC Jr, Adams HP. The international cooperative study on the timing of aneurysm surgery. Part 2: surgical results. *J Neurosurg* 1990;73(01):37–47
- Ohman J, Heiskanen O. Timing of operation for ruptured supratentorial aneurysms: a prospective randomized study. *J Neurosurg* 1989;70(01):55–60
- Meyers PM, Schumacher HC, Higashida RT, et al; American Heart Association. Indications for the performance of intracranial endovascular neurointerventional procedures. *Circulation* 2009;119(16):2235–2249
- Lawson MF, Chi YY, Velat GJ, Mocco JD, Hoh BL. Timing of aneurysm surgery: the International Cooperative Study revisited in the era of endovascular coiling. *J Neurointerv Surg* 2010;2(02):131–134
- Dorhout Mees SM, Molyneux AJ, Kerr RS, Algra A, Rinkel GJ. Timing of aneurysm treatment after subarachnoid hemorrhage: relationship with delayed cerebral ischemia and poor outcome. *Stroke* 2012;43(08):2126–2129
- Chen CC, Yi-Chou Wang A, Chen CT, Hsieh PC. Coadjuvant treatment of vasospasm in ruptured unsecured cerebral aneurysms with aggressive angioplasty, intra-arterial nimodipine, and aneurysm embolization. *World Neurosurg* 2018;116:e452–e459
- Kurata A, Suzuki S, Iwamoto K, et al. Efficacy of endovascular surgery for ruptured aneurysms with vasospasm of the parent artery. *J Neurointerv Surg* 2012;4(03):190–195