Article published online: 2024-03-26

IDH1, ATRX, p53, and Ki67 Expression in Glioblastoma patients: Their Clinical and Prognostic Significance—A Prospective Study

Mukta Meel[1] Arpita Jindal[1] Mukesh Kumar[2] Kusum Mathur[1] Ashok Singh[1]

[1] Department of Pathology, SMS Medical College, Jaipur, Rajasthan, India
[2] Department of Neurosurgery, SMS Medical College, Jaipur, Rajasthan, India

Address for correspondence Mukesh Kumar, MS, MCH, Department of Neurosurgery, SMS Medical College, Jaipur 302004, Rajasthan, India (e-mail: drmannu84@gmail.com).

Asian J Neurosurg 2024;19:14–20.

Abstract

Context Glioblastoma multiforme (GBM) is a malignant and aggressive primary brain tumor with a poor prognosis. This adverse prognosis is due to the tumor's tendency for advancement and recurrence caused by highly intrusive nature of the persisting GBM cells that actively escape from the main tumor mass into the surrounding normal brain tissue. On the basis of biomarker illustration, it can be classified into molecular subgroups.

Aims (1) To determine the expression of IDH1, ATRX, p53, and Ki67 by immunohistochemistry, in a cohort of GBMs. (2) To determine whether altered protein expression of any of these growth-control genes in GBM will show association with patient survival. (3) To establish prognostically distinct molecular subgroups of GBM, irrespective of histopathological diagnosis.

Results In this prospective observational study, 35 histologically diagnosed cases of glioblastoma were enrolled. The mean age at the time of presentation was 43.46 ± 17.25 years with a male:female ratio of 1.3:1. Of the 35 cases, microvascular proliferation was seen in 23 cases. Large foci of necrosis ($>50\%$) were seen in 10 cases and 27 cases had mitotic count ≥ 5/high power field (HPF). Of 35 cases, 5 (14.3%) cases showed IDH1 immunopositivity and 30 (85.7%) cases were negative for IDH1. ATRX was retained in 24 (68.6%) cases, while it was lost in 11 (31.4%) cases. The p53 immunoexpression was seen in 31 (88.6%) cases, whereas p53 was negative in 4 (11.4%) cases. The overall median survival (OS) was 6 months. In two protein pairs, the three compositions were IDH1–/p53+ (74.3%), ATRX+/IDH1– (62.9%), and ATRX+/p53+ (57.1%). Combined three-protein immunohistochemical analysis revealed five different molecular variants. Also, 8.6% (3/35) of the samples had aberrant protein expression of all three proteins, i.e., ATRX–/p53+/IDH1+, while 11.4% (4/35) were wild-type protein expression group, i.e., ATRX+/p53–/IDH1–.

Keywords
- ATRX
- glioblastoma
- IDH1
- overall survival

article published online
March 26, 2024

DOI https://doi.org/10.1055/s-0042-1750783.
ISSN 2248-9614.

© 2024. Asian Congress of Neurological Surgeons. All rights reserved.
This is an open access article published by Thieme under the terms of the Creative Commons Attribution-NonDerivative-NonCommercial-License, permitting copying and reproduction so long as the original work is given appropriate credit. Contents may not be used for commercial purposes, or adapted, remixed, transformed or built upon. (https://creativecommons.org/licenses/by-nc-nd/4.0/)

Thieme Medical and Scientific Publishers Pvt. Ltd., A-12, 2nd Floor, Sector 2, Noida-201301 UP, India

Conclusion In patients with single protein expression, Kaplan–Meier survival analysis showed statistically better OS in IDH1 mutant glioblastomas. In cases with double protein pairs, IDH1/p53 revealed statistically significant association with better median OS. The survival analysis of patients with IDH1/ATRX/p53 protein combinations also denoted a better OS. Hence, GBM can be grouped into prognostically relevant subgroups using these protein expression signatures individually, as well as the combined protein expression signatures.

Introduction

Glioblastoma multiforme (GBM) is the most frequent brain tumor, constituting ∼12 to 15% of all intracranial neoplasms, 45.2% of primary malignant brain tumors, and 65 to 75% of all astrocytic tumors with a median survival range of 1.5 to 2 years. It manifests at any age, preferentially with a peak incidence between 45 and 75 year of age.[1] Glioblastoma and its variants correspond histologically to the World Health Organization (WHO) Grade IV. In the past, classification of brain tumors was primarily based on the concepts of histogenesis, whereas revised 2016 WHO Classification of Tumors of the Central nervous System has integrated the well-established molecular parameters in addition to the prevailing light microscopic appearance, immunohistochemical (IHC) expression of proteins, and the electron microscopic assessment of ultrastructural features. In the updated WHO 2016 classification, glioblastoma has been classified into three categories as follows: glioblastoma, IDH-wild type; glioblastoma, IDH-mutant; and glioblastoma, not otherwise specified (NOS). IDH-wild type glioblastoma corresponding with primary glioblastoma is the most common type accounting for ∼90% of all glioblastomas, and it lacks mutations in the *IDH* genes.[2] It usually arises de novo, affects adults with a mean age at diagnosis of 62 years, with a male-to-female ratio of ∼1.35:1. IDH-mutant glioblastomas synonymous with secondary glioblastoma account for ∼10% of all glioblastomas with a mutation in the *IDH1* or *IDH2* gene.[3] They mostly develop through malignant progression from diffuse or anaplastic astrocytoma, manifest in younger adults with a mean age at diagnosis of 45 years and carry a better prognosis. Glioblastoma, NOS, is defined as a high-grade glioma in which *IDH* mutation status has not been fully assessed. GBMs are most aggressive primary brain tumors, exhibit significant intratumoral heterogeneity at cytopathological, transcriptional, and genomic levels.[1] GBM bears a plenty of cytological and molecular alterations and there are a discrete number of genetic and signaling pathway events that appear to be central to GBM pathogenesis and survival. Beside *IDH* mutation, GBMs can have a peculiar expression of other growth control genes and their proteins including impaired α thalassemia/mental retardation syndrome X-linked (ATRX) expression (ATRX–) and p53 overexpression (p53 +). In GBMs, *ATRX* mutations are usually accompanied by *IDH* and *TP53* mutations.[4] For better prognosis in GBM, *IDH* mutations are proven markers but connection of *TP53* mutations with survival outcome is not uniform.[5–7] Mutations in *ATRX* are still under study to ascertain their connection with survival outcome in GBM patients and prove these mutations as prognostic factors.

In the current cohort, the clinical and histopathological features in 35 cases of glioblastoma were correlated with IHC parameters (IDH1, ATRX, p53, and Ki67) as well as with patient survival.

Aims

The current study was conducted with the aim to

1. Determine the expression of IDH1, p53, ATRX, and Ki67 by immunohistochemistry in the cohort of GBMs
2. Determine whether altered protein expression of any of these growth control genes will show association in patient survival and thereby establish prognostically distinct molecular subgroups of GBM irrespective of histopathological diagnosis.
3. Evaluate demographic profile (age, gender, and topographic details), clinical symptoms, and histopathological features in patients of glioblastoma.

Materials and Methods

This was the prospective observational study in which 35 histologically diagnosed cases of glioblastoma (WHO Grade IV) were enrolled. Clinical parameters such as age, gender, clinical features–signs and symptoms at the onset, and location of tumor were noted. After examining hematoxylin and eosin (H&E) stained slides of formalin-fixed, paraffin-embedded (FFPE) blocks were used for immunohistochemistry (IHC) analysis for IDH 1 (isocitrate dehydrogenase 1), ATRX (Alfa Thalassemia/intellectual Disability syndrome X-linked), P53, Ki67. Peroxidase, antiproxidase technique was used for IHC analysis. Antibodies used were Hmab-1 clone mouse monoclonal antibody from diagnostic Biosystems, USA, for IDH (R132H), D-5 clone mouse monoclonal antibody for ATRX, BP-53–12 clone mouse monoclonal antibody for p53, and MIB-1 clone mouse monoclonal antibody from PathnSitu, USA for Ki67.

Cytoplasmic expression of IDH1-R132H and nuclear expression/loss of ATRX were used to categorize the cases into glioblastoma-IDH wild-type (ATRX nuclear expression retained) and glioblastoma IDH-mutant (loss of nuclear ATRX expression). The score was calculated as a percentage of positively labeled nuclei. Overall, 1,000 tumor cells were counted in randomized fields throughout the section. The expression for all IHC markers was evaluated quantitatively as the percentage of positive tumor cells over total tumor cells. OS was defined as the time interval between surgery and death (because of any cause) or the date of last follow-up.

Statistical Analysis

All data were entered in Microsoft excel sheet and analyses were performed using Statistical Package. After histopathology and IHC data evaluation Kaplan–Meier test and log rank test were performed to assess the significant association of immunopositive versus immunonegative IDH1, ATRX, p53, proteins with overall survival (OS) times in GBM patients for a follow-up of 18 months after surgery. A *p*-value of < 0.05 was considered statistically significant.

Results

Clinical Data

The mean age of the presentation was 43.46 ± 17.25 year with a range of 14 to 78 years. There was a male preponderance with 20 male and 15 female patients with a male to female ratio of 1.3:1. The frequencies of tumor location were as follows: 6 (17.1%) in the temporal, 5 (14.3%) in frontoparietal, 4 (11.4%) in frontotemporal, temporalparietal, and parietooccipital in each. Likewise, three cases (8.6%) were in frontal, parietal, and frontotemporoparietal region and single cases (2.9%) were in the occipital, parietal region, and cerebellum. In 30 (85.7%) patients, macroscopic gross total tumor removal was done, whereas in 5 (14.7%) patients only subtotal tumor removal could be performed. No patient received preoperative neoadjuvant therapy. Duration of symptoms was variable, ranging from 5 days to 10 months. Headache was the most frequent symptom (64.6%), followed by seizures (52.6%), disorientation (44.8%), motor disturbances (32.2%), somnolence in (22.4%), and sensorial disturbances (18.6%). In the follow-up period of 18 months, 31 patients were given radiotherapy/chemotherapy postoperatively, whereas 4 patients opted out of this treatment.

Histopathological Data

Pattern of microvascular proliferation, extent of necrosis, mitotic activity, and presence of other components or variants were assessed in all cases.

Of the 35 cases, microvascular proliferation showing endothelial cell proliferation and glomeruloid tufts both were seen in 23 cases, while the remaining 12 cases showed only endothelial proliferation. Large foci of necrosis (> 50%) were seen in 10 (28.6%) cases, whereas in 25 (71.4%) cases, less than 50% of the tumor was necrotic (►**Fig. 1A**, **1B**). Mitotic count was ≤5 /HPF in 8 cases, whereas 27 cases had mitotic count ≥ 5/HPF. Mitotic activity was in conformation with the Ki67 index. Ki67 ranged from 5 to 90% with a mean value of 36.34 ± 21.05%. In our study, we had a few variants of GBM-like giant cell glioblastoma (3 cases), epithelioid glioblastoma (2 cases), and small cell glioblastoma (one case). In 15 (42.6%) cases, additional features such as gemistocytic cells, oligodendroglial-like cells and primitive neuronal component were noted.

Immunohistochemistry Data and Survival Analysis of GBMs with IDH1, ATRX, and p53 Protein Expression

Out of 35 cases, 5 cases showed IDH1 immunopositivity and 30 cases were negative for IDH1. ATRX was retained in 24 cases, while it was lost in 11 cases. The p53

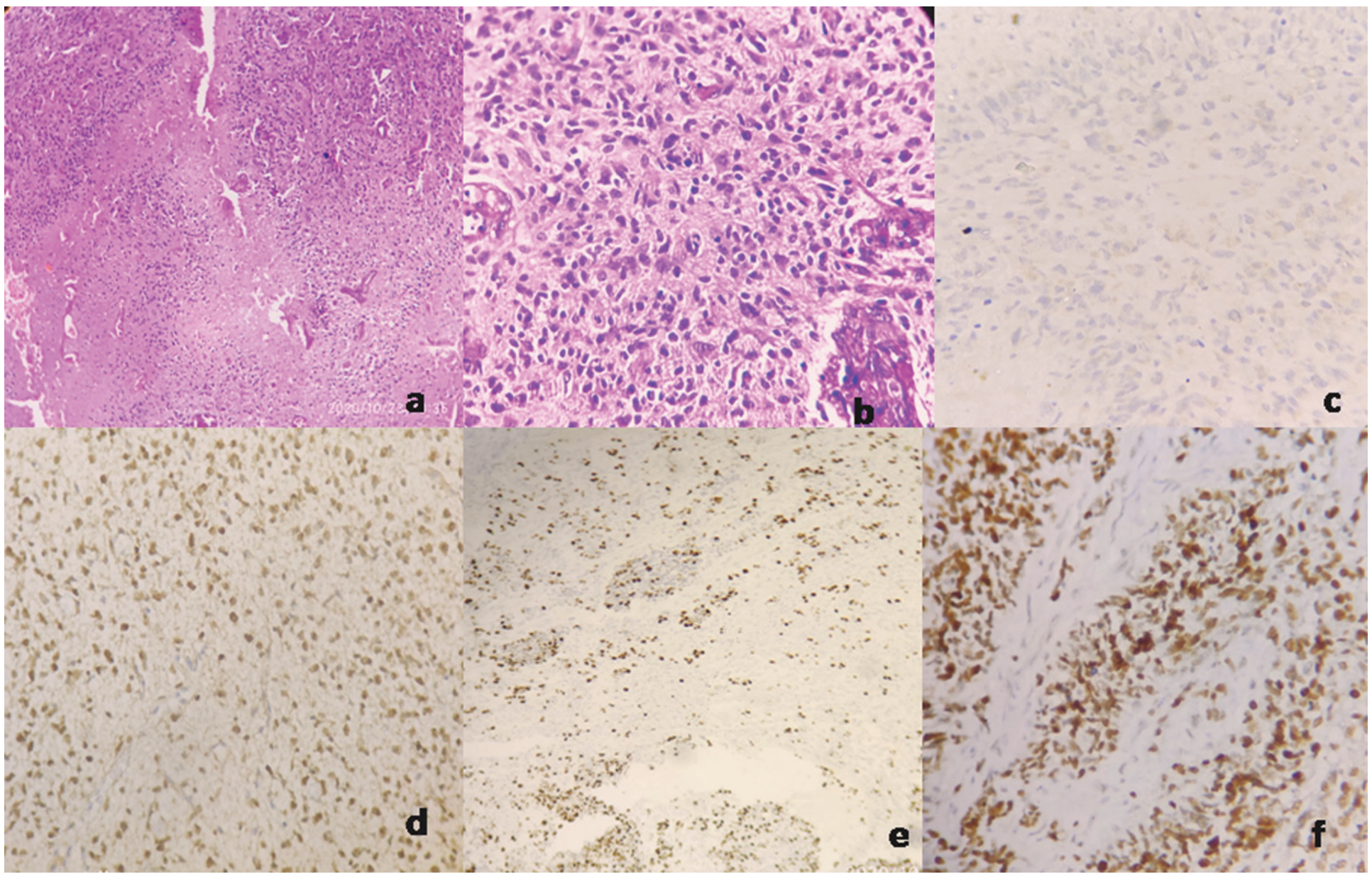

Fig. 1 (**A, B**) Microphotograph showing palisading necrosis and micro vascular proliferation in glioblastoma case (H&E, x100, x400); 1**C**, 1**D**, 1**E**, 1**F**) Microphotograph showing immunonegativity for IDH1, immunopositivity for IDH1, ATRX, and p53, respectively (x100, x400).

Table 1 IDH1, ATRX, and p53 immunoexpression in enrolled GBMs and median overall survival in each subgroup

Mutant Protein	Result of IHC No. (%)	Median OS (months)		*p*-Value
		Mutant protein	Wild type protein	
IDH1+	5 (14.3%)	–	6.00	0.011
ATRX–	11 (31.4%)	9.00	6.00	0.573
P53+	31 (88.6%)	3.00	6.00	0.762

immunoexpression was seen in 31 (88.6%) cases, whereas p53 was negative in 4 (11.4%) cases (►**Fig. 1C–1F**).

Overall median survival (OS) was 6 months. Aberrant protein expression status (each or combinations of three proteins), was correlated with median overall survival (►**Table 1**). The Kaplan–Meier survival analysis showed statistically better OS in IDH1-mutant glioblastomas (►**Fig. 2A–2C**).

Survival Analysis of GBMs with Combinations of Two Protein Expression

►**Table 2** shows immunohistochemical results of two protein pairs, ATRX/IDH1, ATRX/p53, and IDH1/p53 and their median OS.

In two protein pairs, the three compositions were IDH1–/p53+ (74.3%), ATRX+/IDH1– (62.9%), and ATRX+/p53+ (57.1%). The three smallest subgroups were IDH1–/p53– (11.4%), ATRX+/p53–(11.4%), and ATRX+/IDH1+ (5.7%) (►**Table 2**). By analyzing the patients' survival according to the combinations of the ATRX and p53 pair, ATRX–/p53+ expression revealed the highest median OS (9 months), while the ATRX+/p53–combination showed the lowest median OS (3 months). The analysis of IDH1 and p53 pair revealed that IDH1–/p53+ group correlated with the high median OS (6 months), while IDH1–/p53–group had the low median OS (3 months). The results of survival analysis for ATRX/IDH1 were censored as until the end of observation (18 months), all patients were alive. The Kaplan–Meier survival analysis of two protein expression pairs also revealed the same results (►**Fig. 3**).

Survival Analysis of GBMs with Combinations of Three Protein Expression

Combined three-protein immunohistochemical analysis revealed five different molecular variants (►**Table 3**). About

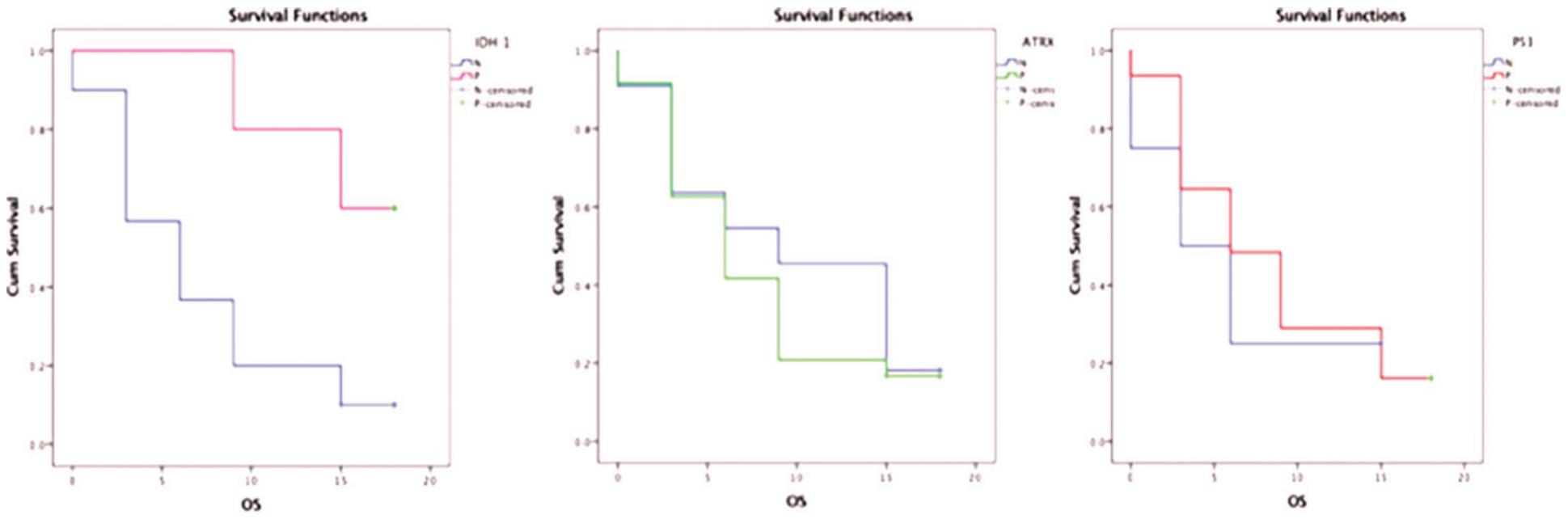

Fig. 2 (**A**) Median survival for IDH1+ (mutant and wild-type); (**B**) Median survival for ATRX (mutant and wild-type); (**C**) Median survival for p53+ (mutant and wild-type).

Table 2 Analysis of various combinations of two proteins pairs in GBMs and survival outcomes

Results of IHC		No (%), $n=35$	Median OS, mon	*p*-Value*
IDH1/ATRX #	IDH1+/ATRX–	3	–	0.062
	IDH1–/ATRX-	8	–	
	IDH1+/ATRX+	2	–	
	IDH1–/ATRX+	22	–	
IDH1/p53	IDH1+/P53+	5	–	0.038
	IDH1–/P53-	4	3.00	
	IDH1–/P53+	26	6.00	
ATRX/p53	ATRX+/P53-	4	3.00	
	ATRX–/P53+	11	9.00	0.840
	ATRX+/P53+	20	6.00	

#All cases are censored.

*Log rank test.

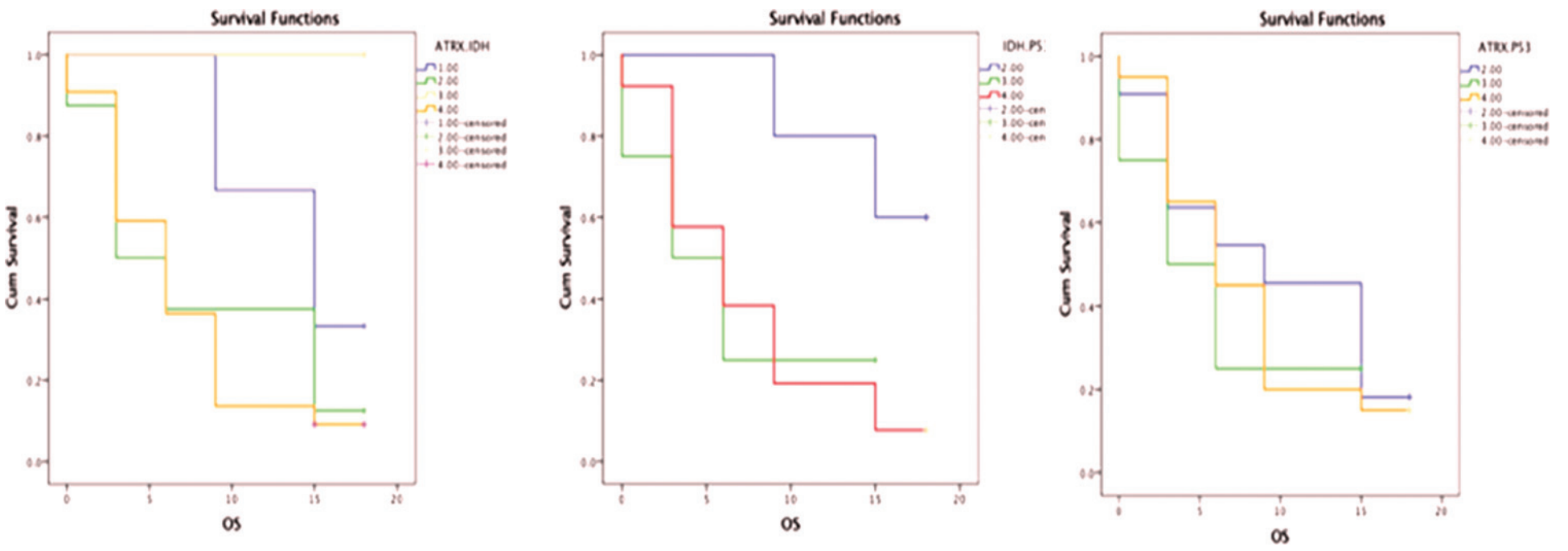

Fig. 3 (**A**) Median survival for IDH1 +/ATRX; (**B**) Median survival for IDH1/p53; (**C**) Median survival for ATRX/p53.

Table 3 Combined triple proteins of IDH1, ATRX, and p53 immunohistochemical results and survival outcomes

GBM variants	No (%), *n* =	Median OS, mon#	*p*-Value*
IDH1 +/ATRX-/P53+	3		0.117
IDH1 +/ATRX +/P53+	2		
IDH1–/ATRX +/P53-	4		
IDH1–/ATRX-/P53+	8		
IDH1–/ATRX +/P53+	18		

Abbreviations: ATRX–, loss of ATRX expression; ATRX +, positive ATRX protein expression; IDH1–, negative for mutated IDH1(R132H) protein; IDH1 +, positive IDH1 protein expression; OS, overall survival; p53–, lack of p53 expression; p53 +, overexpression of p53.

#All cases are censored.

*p-Value was obtained by log rank test of Kaplan–Meier survival analysis.

8.6% (3/35) of the samples consisted of aberrant protein expression of all three proteins, i.e., ATRX–/p53 +/IDH1 +, while 11.4% (4/35) were wild-type protein expression group, i.e., ATRX +/p53–/IDH1–. The survival analysis of patients with these three proteins combination were censored as until the end of observation (18 months); event of study i.e., death of patients did not occur (►**Fig. 4**).

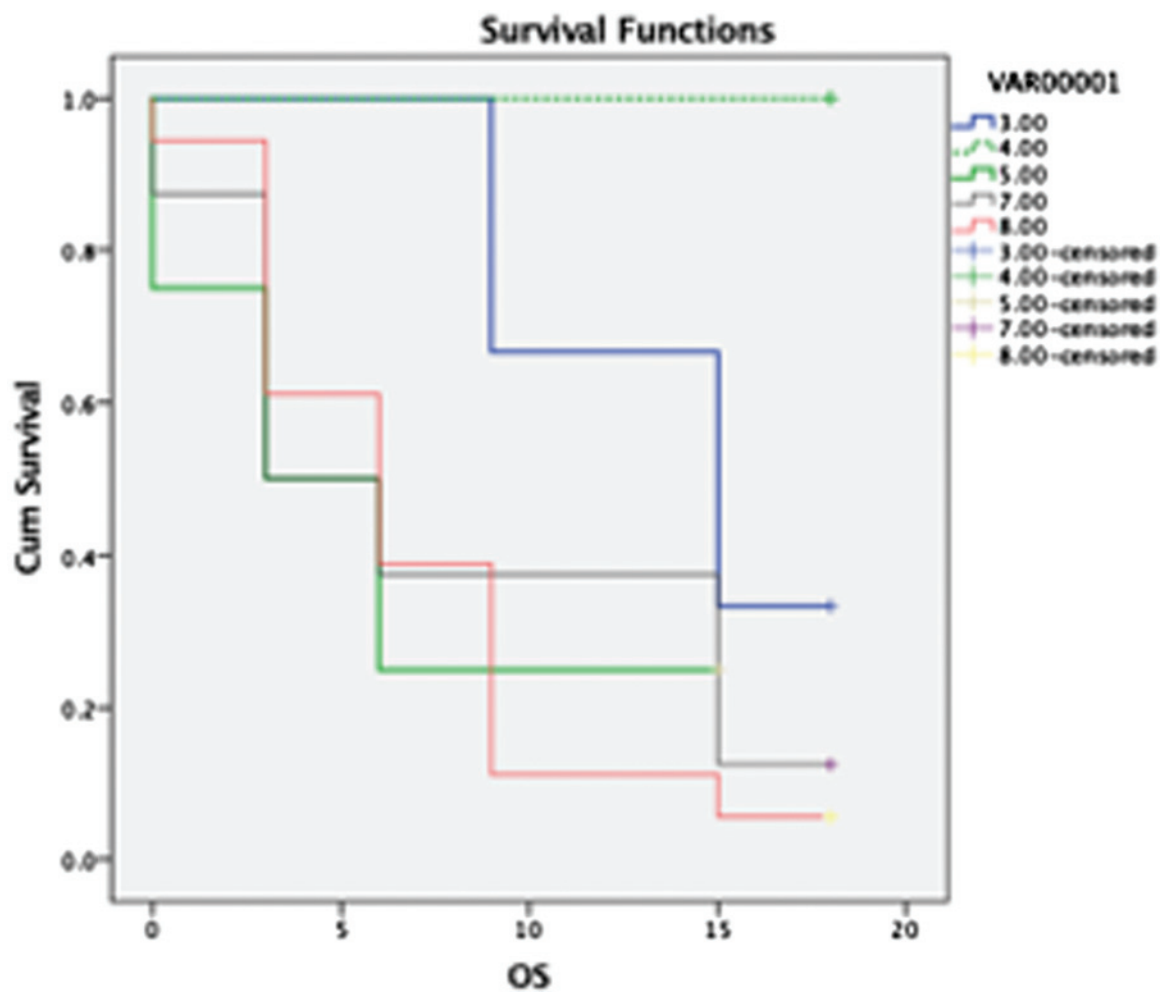

Fig. 4 Median survival with combination of IDH1/ATRX/P53.

Discussion

Glioblastomas are the most frequent and the most malignant of all brain tumors in adults, accounting for ~45 to 50% of all primary malignant brain tumors.[2] These tumors are delineated by diverse histology, genetic instability, and varied clinical behavior with a dismal prognosis.[8] Clinical, histological, immunohistochemical, and molecular variables affect the survival of glioblastoma patients. In the present study, the key clinical features, the major histopathological parameters and the immunohistochemical expression of ATRX, IDH1, and p53, individually, as well as in different combinations were analyzed and correlated with the overall median survival of patients.

In the past few years, some clinical variables in predicting survival in glioblastomas have been well defined. In various studies among the clinical variables, younger age has been associated with a prolonged survival.[9–11] In the current cohort, male predominance was noted with a male to female ratio of 1.3:1, which was similar to other studies.[12–14] In our study, the majority of tumors were located in the cerebral hemispheric region. This is in line with previous reported studies that have shown similar localization, with a predominance of hemispheric lesions, along with a lower incidence of tumors in the posterior fossa.[13,15] Another clinical variable associated with better survival in glioblastoma patients was near total/gross total resection in various studies.[16–18]

Histological features of GBM include hypercellularity, nuclear atypia, mitotic activity, micro vascular proliferation, and necrosis. We studied these parameters individually. The histological parameters have found significant association with patient's clinical outcome in some studies while not in others.[19–23] Our study did not show any correlation with any of these features.

Recently, for the classification of GBM, key molecular parameters such as IDH and ATRX have been incorporated in the 2016 WHO classification. The aim of the present study was to establish a correlation between survival (OS) of GBM patients and the immunohistochemical expression of ATRX, IDH1, and p53 individually as well as in different combinations to define certain molecular subtypes. These molecular subtypes do play a pivotal role in the clinical practice as the treatment strategies are planned in accordance to the molecular subtype.[6] In addition, these mandatory IHC markers (IDH and ATRX) deliver an increased level of objectivity.

Immunohistochemically, the IDH1 positivity was seen in 14.3% of patients, ATRX loss in 31.4%, and p53 overexpression in 88.6%. The results for IDH1 expression and p53 overexpression was in concordance with that of the study done by Pant et al.[24] Survival analysis was better in IDH1-positive as compared with IDH1-negative patients and found statistically significant ($p < 0.011$) in the Kaplan–Meier survivals analysis. Likewise, *ATRX* mutation (ATRX–) was associated with better overall survival as compared with ATRX-retained (ATRX +) cases. Some studies have exhibited a correlation between *TP53* gene mutations and decreased median survival, while others have not found such correlation. In our cohort, the Kaplan–Meier survivals analysis, the OS was better survivals in GBM patients with p53-ve than patients with counterpart result (**►Fig. 2**). We examined two or three protein combinations immunohistochemically to see their association with survival. Different survival rates in different protein alterations were assessed. In IDH1/ATRX combination and IDH1/ATRX/p53 combination, the overall median survival was better but not statistically significant. Statistical significance was seen in IDH1/p53 combination, with $p < 0.05$.

Conclusion

Aberrant expression of IDH1 individually as well as combination of IDH1/p53 was associated with a distinct and statistically significant increased survival rates and emerged as significant prognostic factors. Better overall survival was also noted in IDH1/ATRX combination and IDH1/ATRX/p53 combination denoting their prognostic value as well. Statistically significant association was not found in these cases. This may be due to small sample size, which is a limitation of the current study. Hence, GBM can be grouped into prognostically relevant subgroups by these protein expression signatures individually, as well as the combined protein expression signatures and these proteins may be used as prognostic markers in addition to diagnostic markers.

Ethical Approval
Ethical approval has been taken from institutional ethical committee.
All the authors have read and approved the manuscript.

Conflicts of Interest
None declared.

References

1 Louis DN, Ohgaki H, Wiestler OD, et al. The 2007 WHO classification of tumours of the central nervous system. Acta Neuropathol 2007;114(02):97–109
2 Ostrom QT, Gittleman H, Liao P, et al. CBTRUS statistical report: primary brain and central nervous system tumors diagnosed in the United States in 2007-2011. Neuro-oncol 2014;16(Suppl 4): iv1–iv63
3 Nobusawa S, Watanabe T, Kleihues P, Ohgaki H. IDH1 mutations as molecular signature and predictive factor of secondary glioblastomas. Clin Cancer Res 2009;15(19):6002–6007
4 Jiao Y, Killela PJ, Reitman ZJ, et al. Frequent ATRX, CIC, FUBP1 and IDH1 mutations refine the classification of malignant gliomas. Oncotarget 2012;3(07):709–722
5 Liu XY, Gerges N, Korshunov A, et al. Frequent ATRX mutations and loss of expression in adult diffuse astrocytic tumors carrying IDH1/IDH2 and TP53 mutations. Acta Neuropathol 2012;124(05):615–625
6 Nguyen DN, Heaphy CM, de Wilde RF, et al. Molecular and morphologic correlates of the alternative lengthening of telomeres phenotype in high-grade astrocytomas. Brain Pathol 2013; 23(03):237–243
7 Newcomb EW, Cohen H, Lee SR, et al. Survival of patients with glioblastoma multiforme is not influenced by altered expression of p16, p53, EGFR, MDM2 or Bcl-2 genes. Brain Pathol 1998;8(04): 655–667
8 Kleihues P, Burger PC, Collins VP, Newcomb EW, Ohgaki H, Cavenee WK. Glioblastoma. In: Kleihues P, Cavenee WK, eds. World Health Organization of Classification of Tumors: Pathology and Genetics of Tumors of the Nervous System. Lyon France: IARC; 2000:29–39
9 Jeremic B, Milicic B, Grujicic D, Dagovic A, Aleksandrovic J. Multivariate analysis of clinical prognostic factors in patients with glioblastoma multiforme treated with a combined modality approach. J Cancer Res Clin Oncol 2003;129(08):477–484
10 Lacroix M, Abi-Said D, Fourney DR, et al. A multivariate analysis of 416 patients with glioblastoma multiforme: prognosis, extent of resection, and survival. J Neurosurg 2001;95(02):190–198
11 Laws ER, Parney IF, Huang W, et al;Glioma Outcomes Investigators. Survival following surgery and prognostic factors for recently diagnosed malignant glioma: data from the Glioma Outcomes Project. J Neurosurg 2003;99(03):467–473
12 Song KS, Phi JH, Cho BK, et al. Long-term outcomes in children with glioblastoma. J Neurosurg Pediatr 2010;6(02):145–149
13 Das KK, Mehrotra A, Nair AP, et al. Pediatric glioblastoma: clinico-radiological profile and factors affecting the outcome. Childs Nerv Syst 2012;28(12):2055–2062
14 Suri V, Das P, Jain A, et al. Pediatric glioblastomas: a histopathological and molecular genetic study. Neuro-oncol 2009;11(03):274–280
15 Ganigi PM, Santosh V, Anandh B, Chandramouli BA, Sastry Kolluri VR. Expression of p53, EGFR, pRb and bcl-2 proteins in pediatric glioblastoma multiforme: a study of 54 patients. Pediatr Neurosurg 2005;41(06):292–299
16 Ammirati M, Vick N, Liao YL, Ciric I, Mikhael M. Effect of the extent of surgical resection on survival and quality of life in patients with supratentorial glioblastomas and anaplastic astrocytomas. Neurosurgery 1987;21(02):201–206
17 Simpson JR, Horton J, Scott C, et al. Influence of location and extent of surgical resection on survival of patients with glioblastoma multiforme: results of three consecutive Radiation Therapy Oncology Group (RTOG) clinical trials. Int J Radiat Oncol Biol Phys 1993;26(02):239–244
18 Kowalczuk A, Macdonald RL, Amidei C, et al. Quantitative imaging study of extent of surgical resection and prognosis of malignant astrocytomas. Neurosurgery 1997;41(05):1028–1036, discussion 1036–1038
19 Homma T, Fukushima T, Vaccarella S, et al. Correlation among pathology, genotype, and patient outcomes in glioblastoma. J Neuropathol Exp Neurol 2006;65(09):846–854
20 Pierallini A, Bonamini M, Pantano P, et al. Radiological assessment of necrosis in glioblastoma: variability and prognostic value. Neuroradiology 1998;40(03):150–153
21 Nelson JS, Petito CK, Scott CB, Rotman A, Asbel S, Murry K. Glioblastoma with oligodendroglial features radiation (GBM-OL):

Report from radiation therapy oncology group (RTOG) trial 8302. Lab Invest 1996;74:141A

22 Hilton DA, Penney M, Pobereskin L, Sanders H, Love S. Histological indicators of prognosis in glioblastomas: retinoblastoma protein expression and oligodendroglial differentiation indicate improved survival. Histopathology 2004;44(06):555–560

23 Kraus JA, Lamszus K, Glesmann N, et al. Molecular genetic alterations in glioblastomas with oligodendroglial component. Acta Neuropathol 2001;101(04):311–320

24 Pant I, Chaturvedi S, Suri V, Bansal AK, Jha DK, Gautam VK. Analysis of molecular markers in glioblastoma and correlation with survival pattern. Int J Clinicopathol Correl 2018;2:6–11