



# Endovascular Treatment Strategy for Acute Basilar Artery Occlusion with Unexpected Right-Sided Aortic Arch

Takashi Mizowaki<sup>1</sup> Atsushi Fujita<sup>2</sup> Shinichi Miura<sup>1</sup> Masahiro Nakahara<sup>1</sup> Hirotomoto Tanaka<sup>1</sup>  
Shinichi Matsumoto<sup>3</sup> Yoshiyuki Takaishi<sup>1</sup> Takeshi Kondoh<sup>1</sup>

<sup>1</sup> Department of Neurosurgery, Shinsuma General Hospital, Suma-ku, Kobe, Hyogo, Japan

<sup>2</sup> Department of Neurosurgery, Kobe University Graduate School of Medicine, Kusunoki-cho, Kobe, Hyogo, Japan

<sup>3</sup> Department of Radiology, Shinsuma General Hospital, Suma-ku, Kobe, Hyogo, Japan

Address for correspondence Takashi Mizowaki, MD, PhD, Department of Neurosurgery, Shinsuma General Hospital, 3-1-14 Kinugake-cho, Suma-ku, Kobe, Hyogo, 654-0048, Japan (e-mail: njapxblj@gmail.com).

AJNS 2022;17:383–385.

## Abstract

A right-sided aortic arch (RAA) is a rare variant of the aortic arch found. We present a case of endovascular treatment (EVT) for acute basilar artery (BA) occlusion with an RAA. A 70-year-old man developed acute ischemic stroke due to BA occlusion. During urgent EVT for BA occlusion with an RAA, which was observed unexpectedly, navigation of the catheter to the target vessel was achieved as a result of an early change in the access route. Flexible treatment strategies are warranted for cases of unexpected anatomical variant in the fight against time for emergent cases, such as acute ischemic stroke.

## Keywords

- ▶ right-sided aortic arch
- ▶ acute ischemic stroke
- ▶ endovascular treatment

## Introduction

A right-sided aortic arch (RAA) is a rare variant of the aortic arch found in approximately 0.01 to 0.1% of the general population.<sup>1</sup> We treated a patient with acute ischemic stroke due to basilar artery (BA) occlusion with an RAA, which was first observed during endovascular treatment (EVT). A favorable outcome was achieved by early change in the access route. Our experience may provide useful information to guide others when performing neuro-EVT in patients with this condition.

## Case Report

A 70-year-old man presented with severe disturbance of consciousness and quadriparesis and was admitted to our

hospital. He had no history of a congenital heart disease (CHD). His National Institutes of Health Stroke Scale (NIHSS) score was 26 points. Diffusion-weighted magnetic resonance imaging revealed acute ischemia of the pons (▶Fig. 1A), and magnetic resonance angiography (MRA) suggested BA occlusion (▶Fig. 1B). No intravenous tissue plasminogen activator was administered because the stroke had occurred over 13 hours before presentation.

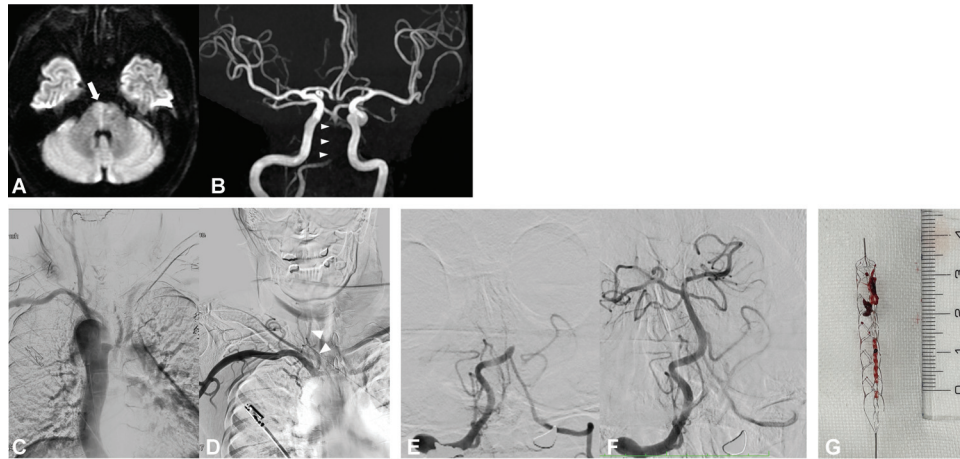
Urgent EVT was performed via a femoral artery approach. Aortic angiography revealed a RAA (▶Fig. 1C). Navigation of a 6-French ultra-long sheath to the dominant right vertebral artery (VA) was unsuccessful. Approximately 20 minutes after the initial groin puncture, successful navigation of another 6-French ultra-long sheath to the right VA was achieved via the right brachial artery approach (▶Fig. 1D). Right VA angiography revealed a BA occlusion

DOI <https://doi.org/10.1055/s-0042-1750805>.  
ISSN 2248-9614.

© 2022. Asian Congress of Neurological Surgeons. All rights reserved.

This is an open access article published by Thieme under the terms of the Creative Commons Attribution-NonDerivative-NonCommercial-License, permitting copying and reproduction so long as the original work is given appropriate credit. Contents may not be used for commercial purposes, or adapted, remixed, transformed or built upon. (<https://creativecommons.org/licenses/by-nc-nd/4.0/>)

Thieme Medical and Scientific Publishers Pvt. Ltd., A-12, 2nd Floor, Sector 2, Noida-201301 UP, India



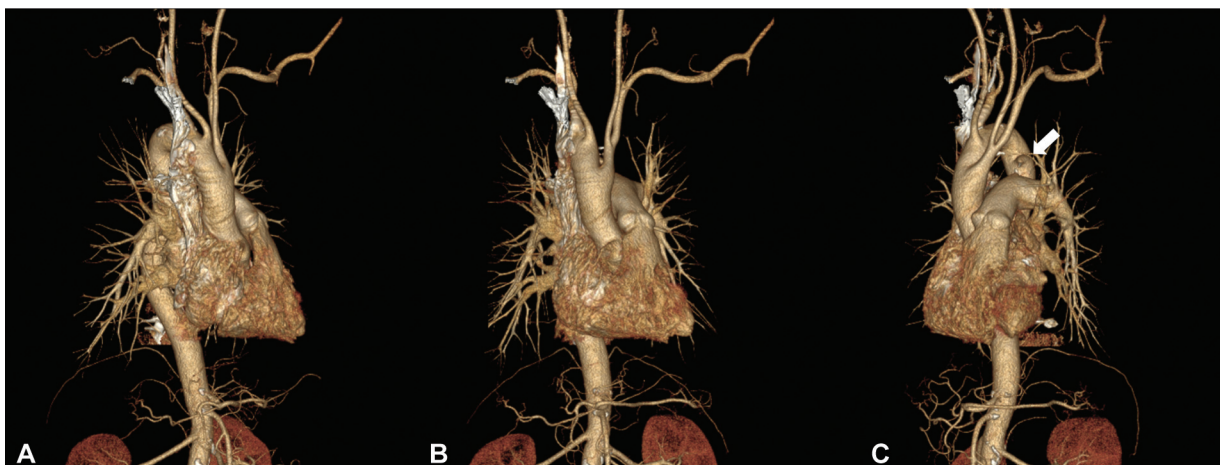
**Fig. 1** (A) Magnetic resonance imaging revealing acute ischemia of the pons (*white arrow*). (B) Magnetic resonance angiography revealing poor visualization of the basilar artery (*white arrowheads*). (C) Aortic angiography revealing a right-sided aortic arch. (D) Right subclavian angiography via the right brachial approach revealing the vertebral artery (*white arrowheads*). (E) Right vertebral angiography revealing basilar artery (BA) occlusion. (F) Right vertebral angiography revealed successful revascularization of the BA. (G) Image showing the retrieval stent and red clot.

(►**Fig. 1E**). After one pass of thrombectomy combined with the use of a retrieval stent (EMBOTRAP II 5.0 mm × 33 mm Revascularization Device [Cerenovus, Irvine, CA]) and aspiration catheter ([Penumbra, Alameda, CA, USA]), successful revascularization was achieved, and a red clot was retrieved (►**Fig. 1F, G**). The time from the initial groin puncture to revascularization was 57 minutes.

The patient's neurological symptoms improved rapidly, and 1 day postoperatively, his NIHSS score was 8 points with disorientation, ataxia, mild dysarthria, and moderate quadriparesis. MRA performed 1 day after the procedure confirmed successful revascularization, and diffusion-weighted imaging showed only small ischemic changes. Anticoagulant therapy (30 mg edoxaban daily) was commenced 24 hours after the procedure and was continued. Post-treatment Holter electrocardiogram showed paroxysmal atrial fibrillation. The patient was discharged on day 21, with no neurological deficit 3 months later.

## Discussion

Several classifications of this variant have been identified, which are based on the arrangement of the aortic arch vessels, relationships with the esophagus, or the presence of CHD.<sup>2–4</sup> Edwards classification<sup>5</sup> of RAA describes three types—Type I: RAA with mirror image branching is the most common type, which is strongly associated with CHD in up to 98% of cases, including tetralogy of Fallot, truncus arteriosus, tricuspid atresia, and transposition of the great arteries with pulmonary valve stenosis; Type II: RAA with aberrant left subclavian artery is the second most common type, which is usually not associated with CHD; and Type III: RAA with isolation of the left subclavian artery may cause congenital subclavian steal syndrome and vertebrobasilar insufficiency. Furthermore, this type is associated with CHD in over 50% of cases, most commonly tetralogy of Fallot. Our patient was diagnosed with mirror image branching RAA with Kommerell's diverticulum (Type I) using postoperative CT angiography (►**Fig. 2A–C**).



**Fig. 2** CT angiography revealed a right-sided aortic arch with mirror imaging branch. (A) Right anterior oblique view. (B) Front view. (C) Left anterior oblique view (*white arrow* is Kommerell's diverticulum).

To the best of our knowledge, this is the first case of EVT for acute large vessel occlusion with an RAA. A RAA may make catheterization difficult because most of the ready-made catheters used presently were designed for a left aortic arch. In our case, navigation of the guiding sheath to the right VA via the femoral artery approach may have been possible after a long period. However, EVT outcomes for acute ischemic stroke are time-dependent. Mokin et al.<sup>6</sup> reported a significant increase in the prognosis of revascularization cases within 6 hours after onset in 100 cases of posterior circulation including basilar artery occlusion. Mourand et al.<sup>7</sup> reported that the mean onset to revascularization time tended to be lower in patients with poor outcomes than in those with favorable outcomes ( $411 \pm 178$  minutes vs.  $663 \pm 296$  minutes,  $p = 0.03$ ) in 20 cases of basilar artery occlusions. Unexpected anatomical variant of the aortic arch may increase procedural difficulty of neuro-EVT via the femoral artery approach.<sup>8</sup> Even in cases of patients with a normal aorta, the meandering of tortuous vessels tends to delay the femoral artery access procedure by 30 minutes or more, which is also associated with unsuccessful revascularization.<sup>9</sup> Neuro-EVT is often performed via femoral artery approach. Due to the unexpected unfamiliar RAA, we switched to an anatomically familiar brachial artery approach to reduce the revascularization time. A right radial or brachial artery approach may be effective in navigating the catheter to the right VA for all types of RAAs when the angle formed by the VA and subclavian artery was 45 degrees or higher.<sup>10</sup> Performing an aortic angiography or MRA as a pretreatment image may lead to appropriate device selection and appropriate initial puncture site, whether anatomical normal or variant.

## Conclusion

Flexible treatment strategies are warranted for cases of unexpected anatomical variant in the fight against time for emergent cases, such as acute ischemic stroke.

### Ethical Approval

All procedures performed in studies involving human participants were in accordance with the ethical standards of the institutional and/or national research committee and with the 1964 Helsinki's declaration and its later amendments or comparable ethical standards.

### Informed Consent

Informed consent has been obtained from the patient for this study and publication of this case report with accompanying images. Consent for publication was obtained

from every individual whose personal data were included in the study.

### Funding

None.

### Conflict of Interest

None declared.

### Authors' Contributions

TM contributed to the study conception. SM and TM contributed to the data collection. SM, YT, HT, TK contributed to the investigation. TM contributed to the writing of the paper. All Authors contributed to critical review and revision, final approval of the article, and hold accountability for all aspects of the work.

## References

- Hastreiter AR, D'Cruz IA, Cantez T, Namin EP, Licata R. Right-sided aorta. I. Occurrence of right aortic arch in various types of congenital heart disease. II. Right aortic arch, right descending aorta, and associated anomalies. *Br Heart J* 1966;28(06): 722-739
- Felson B, Palayew MJ. The two types of right aortic arch. *Radiology* 1963;81:745-759
- Stewart JR, Kincaid OW, Edwards JE. An atlas of vascular rings and related malformation of the aortic arch system. Springfield, Ill: Charles C Thomas; 1964:8-13, 124-129
- Shuford WH, Sybers RG, Gordon IJ, Baron MG, Carson GC. Circumflex retroesophageal right aortic arch simulating mediastinal tumor or dissecting aneurysm. *Am J Roentgenol* 1986;146(03): 491-496
- Edwards JE. Anomalies of the derivatives of the aortic arch system. *Med Clin North Am* 1948;32:925-949
- Mokin M, Sonig A, Sivakanthan S, et al. Clinical and Procedural Predictors of Outcomes From the Endovascular Treatment of Posterior Circulation Strokes. *Stroke* 2016;47(03):782-788
- Mourand I, Machi P, Milhaud D, et al. Mechanical thrombectomy with the Solitaire device in acute basilar artery occlusion. *J Neurointerv Surg* 2014;6(03):200-204
- Ohtani T, Yamazaki T, Ohtaki H, et al. Carotid artery stenting in right-sided aortic arch: a case report. *NMC Case Rep J* 2015;3(01): 9-12
- Ribo M, Flores A, Rubiera M, et al. Difficult catheter access to the occluded vessel during endovascular treatment of acute ischemic stroke is associated with worse clinical outcome. *J Neurointerv Surg* 2013;5(Suppl 1):i70-i73
- Iwata T, Mori T, Miyazaki Y, Tanno Y, Kasakura S, Aoyagi Y. Anatomical features of the vertebral artery for transbrachial direct cannulation of a guiding catheter to perform coil embolization of cerebral aneurysms in the posterior cerebral circulation. *Interv Neuroradiol* 2015;21(03):381-386