



Large-Vessel Occlusion Stroke Treated by Endovascular Thrombectomy in Patient with Coronavirus Disease 2019

Yuko Tsurumi¹ Noriaki Matsubara² Hayato Yokoyama¹ Osamu Hososhima¹ Arihito Tsurumi¹

¹ Department of Neurosurgery, Tsurumi Hospital, Koga, Ibaraki, Japan

² Department of Neurosurgery, Soseikai General Hospital, Kyoto, Japan

Address for correspondence Yuko Tsurumi, MD, Department of Neurosurgery, Tsurumi Hospital, 813, Kami-katata, Koga, Ibaraki, 3060128, Japan (e-mail: yuko@tsurumi.pro).

AJNS 2022;17:489–494.

Abstract

We report a case of acute ischemic stroke caused by large-vessel occlusion in a patient infected with coronavirus disease 2019 (COVID-19) who was treated by endovascular thrombectomy. The patient was a 41-year-old man hospitalized with moderately severe COVID-19. Fourteen days after the onset of COVID-19, dysarthria and right hemiplegia were observed, and acute occlusion of the left middle cerebral artery was diagnosed. Mechanical thrombectomy was performed with a stent retriever while the patient was under local anesthesia and sedation. The staff involved in the intervention was as minimal as possible. The interventional surgeon wore a disposable surgical gown, an N95 mask, a face shield, and two pairs of gloves, while the patient was fitted with a surgical mask. The intervention involved the usual procedures, such as sheath insertion, catheter manipulation, and stent deployment, and the thrombus was removed with the stent retriever. The time from puncture to recanalization was within 30 minutes. No infection was observed in our staff or inpatients after the intervention. Thus, we were able to perform neuroendovascular treatment without spreading COVID-19 by taking appropriate measures to prevent infection.

Keywords

- ▶ COVID-19
- ▶ ischemic stroke
- ▶ thrombectomy
- ▶ infection prevention

Introduction

Since the start of 2020, coronavirus disease 2019 (COVID-19) has been spreading around the world, and various mutant strains of the virus (severe acute respiratory syndrome coronavirus 2 [SARS-CoV-2]) have already been reported. As of July 2021, the number of infections caused by novel mutant strains has been noted to increase in Japan. Although the preparation and management of endovascular therapy for acute ischemic stroke in patients positive for SARS-CoV-2 have been reported,^{1,2} the novel mutant strains have not

been mentioned widely. In this study, we report a case of acute ischemic stroke caused by large-vessel occlusion in an infected patient. In performing endovascular thrombectomy, we successfully prevented the spread of infection in the hospital, and we describe the precautions we used in the management of patients with stroke and COVID-19.

Case Presentation

The patient was a 41-year-old man who was a smoker and had no medical history. A family member living with the patient

DOI <https://doi.org/10.1055/s-0042-1750807>.
ISSN 2248-9614.

© 2022. Asian Congress of Neurological Surgeons. All rights reserved.

This is an open access article published by Thieme under the terms of the Creative Commons Attribution-NonDerivative-NonCommercial-License, permitting copying and reproduction so long as the original work is given appropriate credit. Contents may not be used for commercial purposes, or adapted, remixed, transformed or built upon. (<https://creativecommons.org/licenses/by-nc-nd/4.0/>)

Thieme Medical and Scientific Publishers Pvt. Ltd., A-12, 2nd Floor, Sector 2, Noida-201301 UP, India

had developed COVID-19, and because our patient was a close contact, he was tested by polymerase chain reaction (PCR) and found to be infected. Initially, he had only a fever and remained at home; on the 9th day, however, he was admitted to a general hospital with bilateral pneumonia. Diabetes mellitus was also diagnosed at the time of admission, and oral metformin and insulin therapy were started. Because his oxygen saturation was 95%, oxygen was not required. However, because of the image findings of pneumonia, his smoking history, and the diagnosis of diabetes mellitus, this case of COVID-19 was considered moderately severe, and treatment with dexamethasone was initiated.

On the 14th day after the onset of COVID-19, the patient exhibited dysarthria and right-sided hemiplegia and underwent cerebral computed tomography (CT) and cerebral magnetic resonance imaging (MRI), which revealed acute cerebral infarction of the left middle cerebral artery (MCA). The patient was then transferred to our hospital, which focuses on neurosurgery, because the general hospital had difficulty providing interventional radiology (IVR) treatment. Although we had no prior in-hospital arrangements for IVR treatment of COVID-19, patients with stroke were usually transferred to our hospital for neurosurgical diseases because the previous hospital lacked a full-time neurosurgeon, and a system of collaboration between the hospitals was already in place.

After the patient arrived at our hospital, a stretcher was set up outside the hospital, the patient was laid on it, and the SARS-CoV-2 antigen test was performed, which yielded a positive result. A surgical mask was placed on the patient. For the prevention of COVID-19 infections, personnel directly involved in the patient's care were limited to two physicians, one nurse, and one radiology technician, all of whom wore new N95 masks, face shields, long-sleeved gowns, caps, gloves, and shoe covers.

The patient arrived at our hospital approximately 440 minutes after the last well known. His hemoglobin A1c level was 11.2%, and his D-dimer level was 3.3 $\mu\text{g/mL}$ on

arrival. Atrial fibrillation, which was not detected at the previous hospital, was identified on electrocardiography at our hospital. Diffusion-weighted cerebral MRI showed areas of hyperintensity in the left temporal lobe, and fluid-attenuated inversion recovery sequences showed signal changes in the same area. Ischemic changes were also partially observed in the frontal/parietal lobes. Cerebral magnetic resonance angiography demonstrated occlusion of the M1 portion of the left MCA, caused by cardiogenic cerebral embolism. The National Institutes of Health Stroke Scale (NIHSS) score and the Diffusion-Weighted Imaging–Alberta Stroke Program Early Computed Tomography (DWI-ASPECT) scores were 27 and 5, respectively.

Because more than 8 hours had passed since the patient's symptoms began, intravenous tissue plasminogen activator (t-PA) therapy was not performed. Diffusion-weighted images showed a limited hyperintense area in the M1 portion of the left MCA; we assumed that some ischemic areas remained, and we decided to perform thrombectomy (**Fig. 1A–C**).

Three ceiling-mounted air conditioners with high-efficiency particulate air filters and six air purifiers had been installed in the angiography room. The air conditioners and air purifiers were at maximum output.

Only one physician performed the intervention; the other one stayed in the operating room whenever possible, moving between the angiography room and the operating room to bring out required devices and items or to administer drugs. The door between the angiography room and the operating room was closed except when staff needs to move from one room to the other, and nurses and laboratory technicians waited in the operating room except when transferring patients (**Fig. 2**).

Local anesthesia and sedation were induced with dexmedetomidine and propofol. The interventional surgeon wore a disposable surgical gown, an N95 mask, a face shield, and two pairs of gloves, and the patient was fitted with a surgical mask.

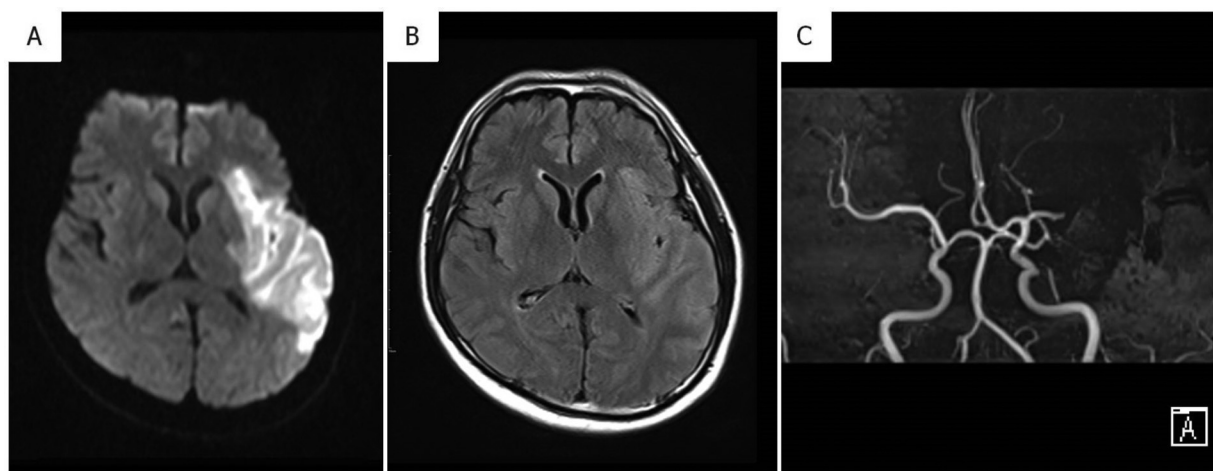


Fig. 1 Diffusion-weighted magnetic resonance imaging (A) and fluid-attenuated inversion recovery imaging (B) at onset revealed an area of hyperintensity in the left middle cerebral artery in the temporal lobe. Magnetic resonance angiography (C) showed the occlusion of the M1 segment of the left middle cerebral artery.

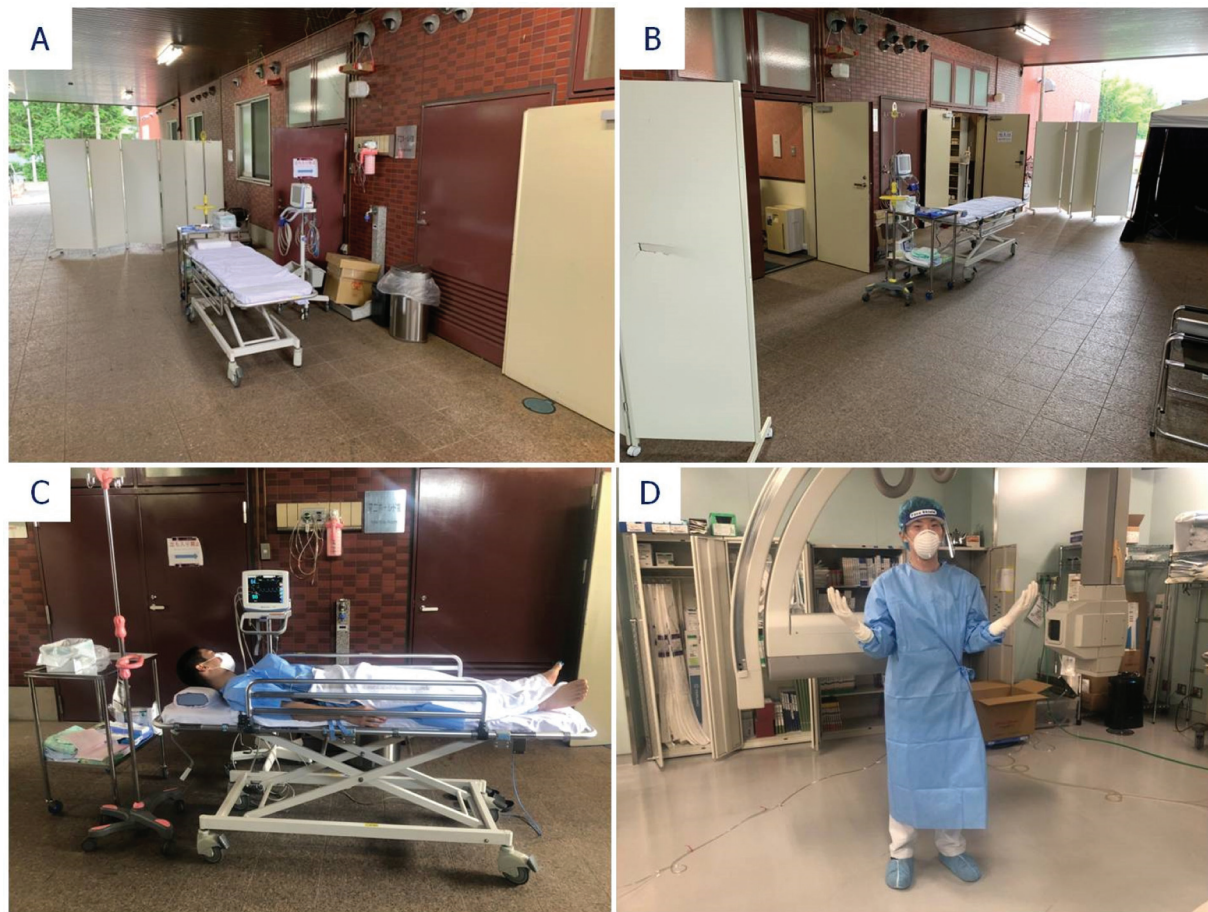

Fig. 2 The stretcher was set up outside the hospital (A and B). The patient was laid on the stretcher upon arrival (C), and the severe acute respiratory syndrome coronavirus 2 (SARS-CoV-2) antigen test was performed before image examinations (not shown). The interventional surgeon wore an N95 mask, a face shield, a long-sleeved disposable surgical gown, a cap, eye goggles, two pairs of gloves, and shoe covers (D).

An 8-Fr sheath was placed in the right common femoral artery, and an 8-Fr guiding catheter with a balloon (Optimo; Tokai Medical Products, Aichi, Japan) was advanced to the left internal carotid artery coaxially with a 6-Fr catheter (Slim-guide; Medikit, Tokyo, Japan) and a 4-Fr catheter (HK; Medikit). A microcatheter (Trevor Trak 21; Stryker Corporation, Kalamazoo, MI, USA) was guided distal to the occlusion in the MCA using a guide wire (Chikai black 14; Asahi Intec Co., Ltd., Aichi, Japan). The stent retriever (Solitaire 4 × 20 mm; Covidien/Medtronic, Irvine, CA, USA) was deployed to ensure adequate coverage of the clot. The thrombus was then retrieved in two passes, and thrombolysis in cerebral infarction (TICI) grade 2b recanalization of the left MCA was achieved. The time from puncture to recanalization was 24 minutes (► Fig. 3A–C).

After the procedure, staff members monitored each other when removing contaminated gowns and gloves, and they thoroughly disinfected their skin with isopropyl alcohol before touching clean areas. Areas such as examination room, angiography room, and elevators that were contacted by the patient with COVID-19 patient or staffs who cared for the patient directly were wiped down with isopropyl alcohol and disinfected.

The inpatient room was a private negative-pressure room, with a vital signs monitor positioned at the patient's bedside,

and vital signs were monitored from the nurses' station. The intravenous drip line was extended outside the room so that necessary medications could be administered from outside. Room visits by staff were kept to a minimum. Postoperatively, no infection was recognized in our staff or other hospitalized patients.

On the day after thrombectomy, the patient's NIHSS score was 15, and the patient nodded in response to questions. Cerebral CT showed no intracranial hemorrhage, and the patient returned that day to the initial general hospital where he had been admitted earlier for treatment of COVID-19. PCR testing was later performed and revealed that the patient was positive for SARS-CoV-2 with the N501Y mutant strain.

Discussion

We were able to perform endovascular thrombectomy for large-vessel occlusion in a patient with COVID-19 caused by the N501Y mutant strain. Some reports have suggested that the incidence of stroke in patients with COVID-19 does not differ significantly from that in the general population,³ whereas others have suggested that it could be significantly higher.^{4,5} The main causes of stroke in patients with COVID-19 are thought to be general risk factors such as

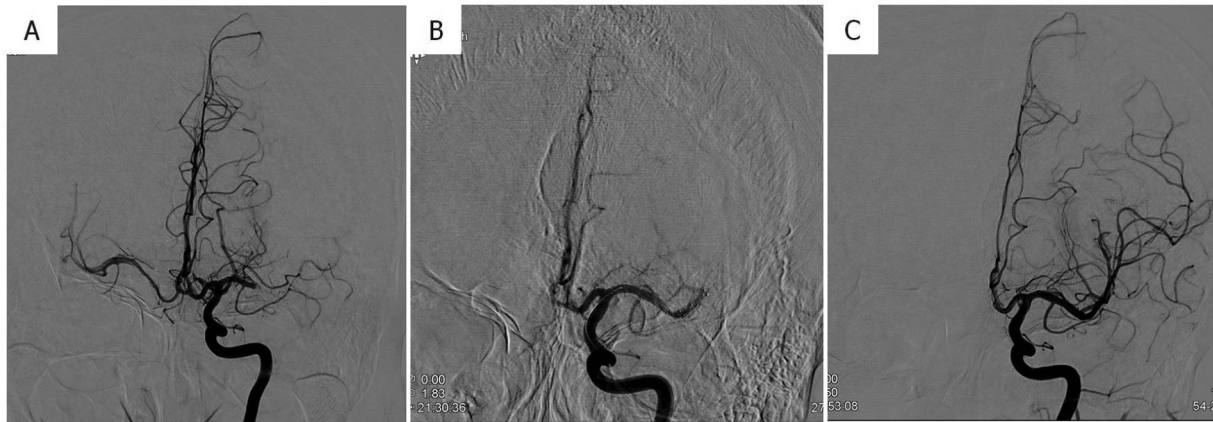


Fig. 3 Angiography of the left internal carotid artery (A) showed occlusion of the left middle cerebral artery (MCA). Angiography of the left carotid artery (B) obtained after stent retriever deployment showed partial recanalization of the left MCA. Angiography of the left carotid artery (C) obtained after thrombectomy showed revascularization of the MCA and confirmed that Thrombolysis in cerebral infarction (TICI) grade 2b recanalization had been achieved.

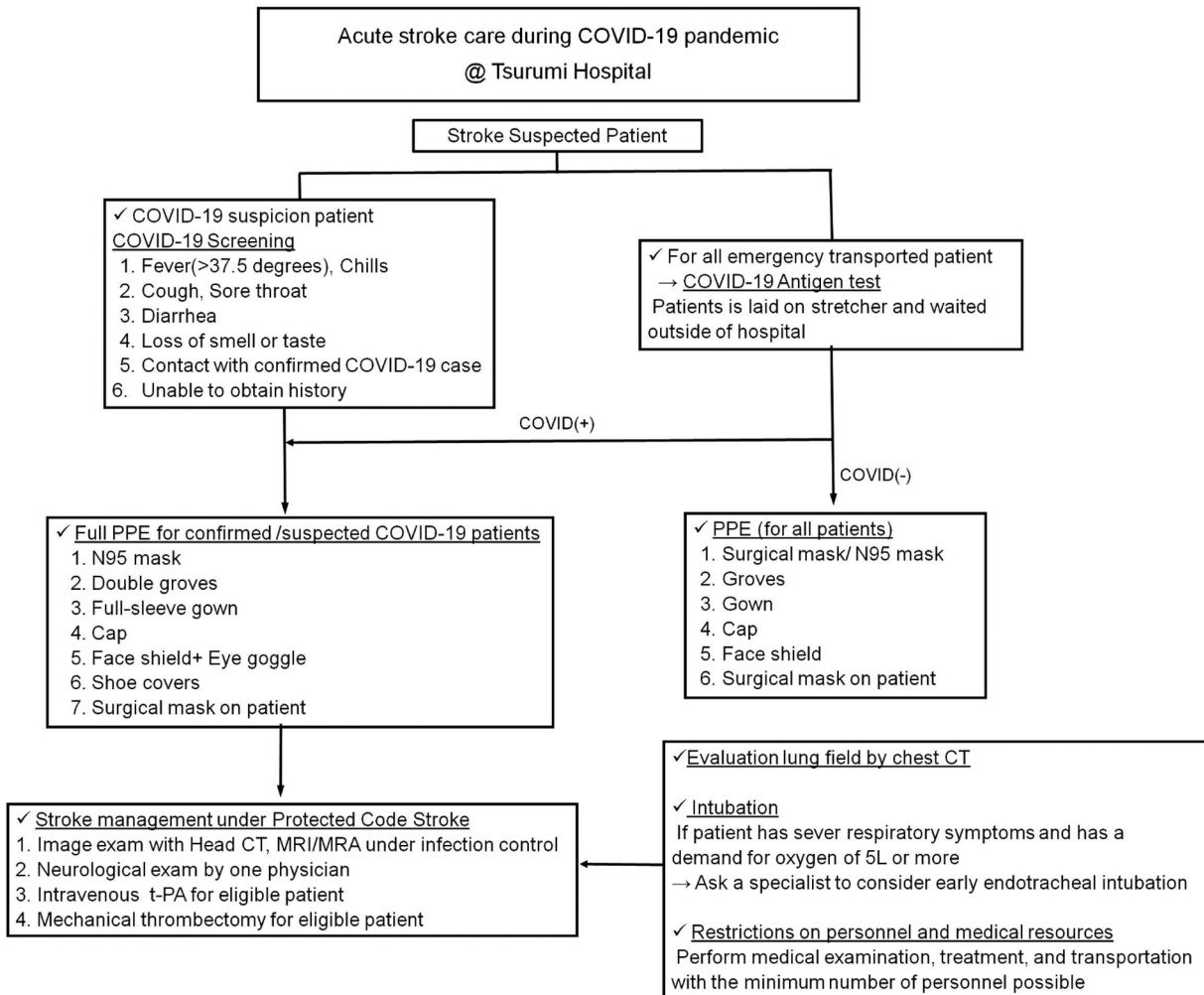


Fig. 4 Acute stroke care during COVID-19 pandemic at Tsurumi Hospital, Koga, Ibaraki, Japan.

atherosclerotic lesions and cardiogenic, as previously pointed out.^{3,6} However, the incidence of stroke is higher in cases of moderate or severe respiratory disease, as in our patient.³ In addition, some researchers theorize that COVID-19 is involved in plaque destabilization through inflammation and cytokine responses, which may increase the likelihood of thromboembolism, worsen cardiac function, and result in cardiogenic stroke through arrhythmia and heart failure. It may also be related to the interaction of multiple risk factors for each patient and the factors caused by COVID-19 infection.⁶

Our patient had moderately severe COVID-19 and required inpatient care. The patient, in whom diabetes mellitus was detected earlier, was also found to have atrial fibrillation, and cardiogenic cerebral embolism was diagnosed. Horiuchi et al.⁷ reported that the incidence of thrombosis, including arterial and venous thrombosis, among hospitalized patients with mild and moderate COVID-19 was 0.59%, in contrast to 13.5% among patients with severe cases, according to the results of a survey conducted in 399 hospitals in Japan. However, whether COVID-19 increases the incidence of embolic stroke, or whether the incidence of embolic cerebral infarction increases with increasing severity of COVID-19, has not yet been reported. In our patient, the embolism was thought to be cardiogenic because of the presence of atrial fibrillation, but it remains difficult to determine whether cerebral main artery occlusion was related to COVID-19 or occurred incidentally.

During the COVID-19 epidemic, all patients who have come to our hospital by ambulance are tested for SARS-CoV-2 antigen; a stretcher is prepared in the ambulance arrival space outside the hospital, and management is arranged according to the results of the antigen test (► Fig. 4). The reason is that our hospital is a single-specialty institution that focuses on neurosurgery and does not provide inpatient care for patients with COVID-19. Patients are tested for COVID-19 even if they have no symptoms. In the case of our patient, COVID-19 had been diagnosed previously, and the result of the SARS-CoV-2 antigen test performed in our hospital was positive. Normally, there are no restrictions on the number of personnel who can enter the angiography room: two or three physicians, one or two nurses, one or two radiologists, and two or three medical secretaries come and go as needed. But for this patient, the number of patient care personnel was kept as low as possible from the time of his arrival—two physicians, one nurse, and one radiologist—to prevent the spread of COVID-19 infection. Only one physician performed the intervention, while the other one waited in the operating room as much as possible, moving between the angiography room and the operating room only when necessary.

For the surgery, local anesthesia and sedation were induced. Yavagal et al.⁸ reported that COVID-19 infection rates did not differ between facilities that preferentially intubate and those that preferentially do not intubate during endovascular surgery, according to the results of 113 questionnaires from 25 countries. Our interventional procedure itself was the usual protocol, including sheath insertion, catheter advancement, and stent deployment and was performed without any particular problems. In addition, the thrombus

was removed in the usual manner (by stent retrieval) during the treatment procedure, and the gross appearance of the thrombus was no different from that in other patients. Contaminated gowns, gloves, and other personal protective equipment used were in accordance with the Japanese Stroke Association's version of the COVID-19-compliant stroke protocol (Protected Code Stroke: JSS-PCS). Patient transfer after the procedure and disinfection of laboratories and transfer routes were also performed according to this protocol.

Because emergency stroke management, including recanalization therapy, may be required, personnel who may come into contact with patients with COVID-19 should be familiar with how to properly put on and take off N95 masks, face shields, long-sleeved gowns, caps, gloves, and shoe covers to prevent infection on a daily basis.

After the intervention, COVID-19 infection was not observed in our staff or other hospitalized patients. A later PCR test in our patient yielded a positive result for SARS-CoV-2 with the N501Y mutation. N501Y mutation strains have been called as Alfa variant. As of June 2021, the number of infections caused by N501Y mutant strains has had been noted to increase in Japan. Alfa variant is reported more infectious than the original strains.⁹ More recently, L452R mutation strains have been widely spread in Japan. L452R mutation strains have been called as Delta variant and which are considered much more infectious than other variants. Although the preparation and management of endovascular therapy for acute ischemic stroke in patients positive for SARS-CoV-2 have been reported,^{2,3} the N501Y or L452R mutant strains have not been mentioned widely.

It has been reported that thrombus retrieval therapy for in-hospital stroke with large-vessel occlusion takes longer if the patient must be transferred to another hospital.¹⁰ In our patient, however, COVID-19 could be treated at the first hospital. Because our hospital is a single-specialty neurosurgery hospital, as mentioned previously, it was difficult to treat COVID-19; thus, after the neurosurgery, the patient returned to the general hospital where he had been hospitalized for COVID-19. In this way, collaboration between the hospitals enabled appropriate management. This demonstrates how vital collaboration is among hospitals not only during the COVID-19 epidemic but also at other times.¹¹

Conclusion

We performed recanalization therapy with thrombus retrieval for cerebral large-vessel occlusion in a patient infected with the novel mutant strain of SARS-CoV-2. We were able to avoid spreading the virus by taking appropriate measures to prevent infection.

Conflict of Interest

None declared.

References

- 1 Nguyen TN, Abdalkader M, Jovin TG, et al. Mechanical thrombectomy in the era of the COVID-19 pandemic: emergency preparedness for neuroscience teams: a guidance statement from the

- Society of Vascular and Interventional Neurology. *Stroke* 2020;51(06):1896–1901
- 2 Khosravani H, Rajendram P, Notario L, Chapman MG, Menon BK. Protected code stroke: hyperacute stroke management during the coronavirus disease 2019 (COVID-19) pandemic. *Stroke* 2020;51(06):1891–1895
 - 3 Requena M, Olivé-Gadea M, Muchada M, et al. COVID-19 and stroke: incidence and etiological description in a high-volume center. *J Stroke Cerebrovasc Dis* 2020;29(11):105225
 - 4 Chen J, Wu Y, Chen Z, et al. High incidence of stroke in COVID-19 patients. *Aging (Albany NY)* 2020;12(22):22390–22398
 - 5 Li B, Yang J, Zhao F, et al. Prevalence and impact of cardiovascular metabolic diseases on COVID-19 in China. *Clin Res Cardiol* 2020;109(05):531–538
 - 6 Bhatia R, Srivastava MVP. COVID-19 and stroke: incidental, triggered or causative. *Ann Indian Acad Neurol* 2020;23(03):318–324
 - 7 Horiuchi H, Morishita E, Urano T, Yokoyama K. Questionnaire-survey Joint Team on The COVID-19-related thrombosis. COVID-19-related thrombosis in Japan: final report of a questionnaire-based survey in 2020. *J Atheroscler Thromb* 2021;28(04):406–416
 - 8 Yavagal DR, Saini V, Inoa V, et al; MT2020 Global Executive Committee. International survey of mechanical thrombectomy stroke systems of care during COVID-19 pandemic. *J Stroke Cerebrovasc Dis* 2021;30(08):105806
 - 9 Liu H, Zhang Q, Wei P, et al. The basis of a more contagious 501Y. V1 variant of SARS-COV-2. *bioRxiv*. 2021.02.428884 (preprint)
 - 10 Matsubara N, Hiramatsu R, Yagi R, et al. Other hospital-onset acute ischemic stroke due to large vessel occlusion treated by mechanical thrombectomy after inter-hospital transfer. *Neurol Med Chir (Tokyo)* 2020;60(04):209–216
 - 11 Shigeta K, Ota T, Kaneko J, et al; TREAT study group. Negative impact of interhospital transfer on clinical outcomes of mechanical thrombectomy for fast progressive stroke. *J Stroke Cerebrovasc Dis* 2021;30(04):105633