



Anesthetic Considerations for a Patient with Autosomal Dominant Polycystic Kidney Disease, Having a Ruptured Intracranial Aneurysm for Endovascular Coiling: A Case Report

Shalvi Mahajan¹ Vidhya Narayanan² Vikas Bhatia³ Vinitha Narayan¹

¹ Division of Neuroanaesthesia, Department of Anaesthesia, Postgraduate Institute of Medical Education and Research (PGIMER), Chandigarh, India

² Department of Anaesthesia, Sree Balaji Medical College and Hospital, BIHER, Chennai, Tamil Nadu, India

³ Department of Radiodiagnosis, PGIMER, Chandigarh, India

Address for correspondence Vinitha Narayan, MD, Department of Anesthesia and Intensive Care, Postgraduate Institute of Medical Education and Research (PGIMER), Chandigarh, 160012, India (e-mail: vini.narayan@gmail.com).

AJNS 2022;17:379–382.

Abstract

Keywords

- autosomal dominant polycystic kidney disease (ADPKD)
- cerebrovascular aneurysm
- endovascular coiling

Autosomal dominant polycystic kidney disease (ADPKD) is a genetic disorder affecting 1 in 1,000 people worldwide. Intracranial aneurysms are an important extrarenal complication with a prevalence of 9 to 12%. The definitive management of an aneurysm includes surgical clipping or endovascular coiling. There is a paucity of literature regarding the anesthetic management of such patients. The pre-existing renal condition is an additional challenge in the management of these patients as the complications associated with chronic kidney disease are superimposed on those due to subarachnoid hemorrhage. Here, we describe anesthetic management of a patient with ADPKD who had a ruptured anterior communicating artery aneurysm, for which endovascular coiling was done.

Key Messages

1. Incidence of intracranial aneurysms is four times higher in patients with ADPKD.
2. Use of contrast agents and the subarachnoid hemorrhage itself can cause worsening of renal function perioperatively.
3. The goals of anesthetic management include 4 Hs—adequate Hydration, management of Hemodynamics, judicious use of Heparin, and avoiding High osmolar contrast agents.

Introduction

Autosomal dominant polycystic kidney disease (ADPKD) affects 1 in 1,000 people worldwide. Intracranial aneurysms are an important extrarenal manifestation, with a prevalence of 9 to 12%, which is four times higher than in the general population. Multiple intracranial aneurysms are often observed.¹

A steady deterioration in renal function observed in this population is often accompanied by hypertension, anemia, secondary hyperparathyroidism, poor nutrition,

DOI <https://doi.org/10.1055/s-0042-1750811>.
ISSN 2248-9614.

© 2022. Asian Congress of Neurological Surgeons. All rights reserved.

This is an open access article published by Thieme under the terms of the Creative Commons Attribution-NonDerivative-NonCommercial-License, permitting copying and reproduction so long as the original work is given appropriate credit. Contents may not be used for commercial purposes, or adapted, remixed, transformed or built upon. (<https://creativecommons.org/licenses/by-nc-nd/4.0/>)

Thieme Medical and Scientific Publishers Pvt. Ltd., A-12, 2nd Floor, Sector 2, Noida-201301 UP, India

and cardiovascular problems. These problems present an extra challenge to neuroanesthesiologist during perioperative treatment.²

Case Report

A 42-year-old female, diagnosed case of ADPKD, presented with severe headache and multiple episodes of vomiting for 2 days. An urgent noncontrast computed tomography scan of the head revealed blood in the anterior interhemispheric fissure and basal cisterns (►Fig. 1). To know the cause of bleeding, magnetic resonance angiography of cerebral vessels was performed, which identified an anterior communicating artery aneurysm (6.2 × 3.1 mm). The patient was classified into modified Hunt and Hess grade 2, World Federations of Neurological Surgeons grade 1, and modified Fisher grade 3 of subarachnoid hemorrhage (SAH), and endovascular coiling was planned.

Preoperative investigations showed blood urea (70.6 mg/dL) and creatinine (2.17 mg/dL). Arterial blood gases (ABG) showed pH (7.32), partial pressure of carbon dioxide (26 mm Hg), bicarbonate (10), and base deficit (13.7). Serum electrolytes were normal. An estimated glomerular filtration rate (eGFR) was 26 mL/min/1.73 m². Tablet sodium bicarbonate 500 mg orally three times a day and adequate hydration were started. Two-dimensional echocardiography showed an ejection fraction of 55% and grade 1 diastolic dysfunction.

Intraoperatively, standard American Society of Anesthesiologists monitors were applied. Induction of anesthesia was done with fentanyl (100 µg), and propofol, titrated to loss of consciousness (100 mg). Atracurium (35mg) was used for

paralysis. The airway was secured with a 7.5 mm endotracheal tube. Following induction, the left radial artery and the right internal jugular vein were cannulated, under ultrasound guidance, for continuous monitoring of arterial blood pressure and central venous pressure (CVP), respectively. Anesthesia was maintained with oxygen, nitrous oxide (N₂O), and isoflurane.

Intraoperatively, the neuroradiologist used 100 mL iso-osmolar contrast (iohexol) and 2 L heparinized flush solution with 1,000 U heparin. To avoid fluid overload, we restricted intravenous fluids to 500 mL of PlasmaLyte, targeting the CVP to 10 to 12 mm Hg. The urine output was adequate (800 mL) during the 3 hours procedure duration. Activated clotting time was regularly monitored and was in the range of 150 to 200 seconds. The patient remained hemodynamically stable throughout the procedure. Intraoperatively, ABG analysis showed pH (7.19), base deficit (16.2), and sodium (150 mg/dL). She was then shifted to the intensive care unit for mechanical ventilation. The metabolic parameters resolved within 48 hours, as shown in ►Fig. 2, but she developed paraparesis on the second postoperative day with a power of 1/5 in the lower limbs, and Glasgow Coma Scale (GCS) of E4VtM5. Angiography showed severe vasospasm in the left anterior cerebral artery and mild-to-moderate vasospasm in the M1 segment of the right middle cerebral artery (►Fig. 3). Nimodipine 3 mg in the left internal carotid artery and 4 mg in the right internal carotid artery was administered. Subsequently, she was discharged 10 days later with a GCS of E4VtM5.

Discussion

The anesthetic considerations in this patient stem from both the presence of chronic kidney disease (CKD) and the complications related to SAH. SAH can cause worsening renal function. Acute kidney injury has been reported in 3 to 12% of patients with SAH. Activation of the sympathetic nervous system and the application of hypertensive therapy postoperatively could be the reason.³ In a study, Tujjar et al⁴ found the occurrence of vasospasm and the use of vancomycin are main predictors of deteriorating renal function. Altered endothelial function secondary to vasospasm may increase the risk of renal vasoconstriction and thereby affect renal

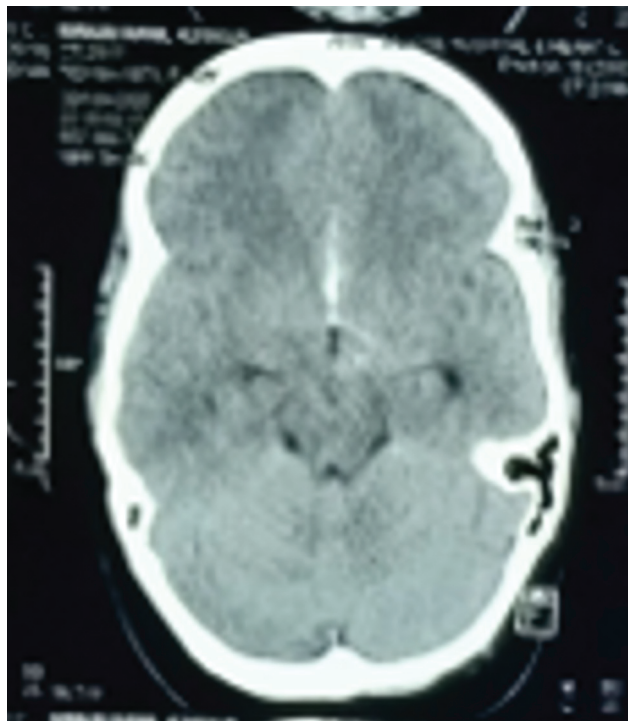


Fig. 1 CT brain showing subarachnoid haemorrhage with blood in the anterior inter-hemispheric fissure.

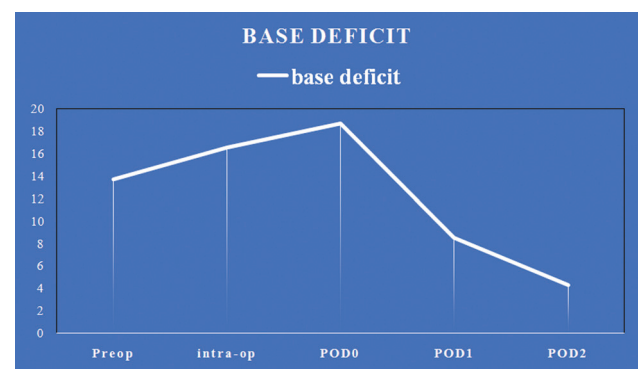


Fig. 2 Trends of base deficit (mEq/L). POD, postoperative day.

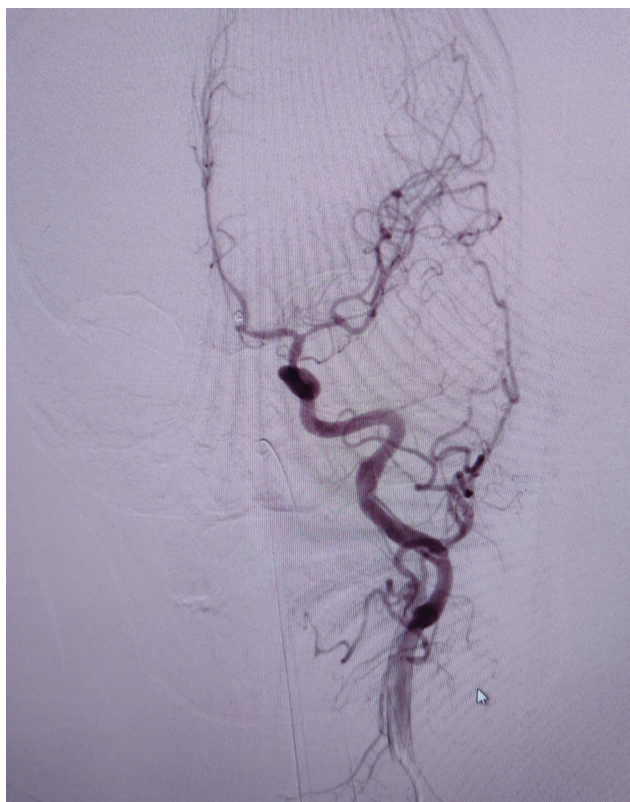


Fig. 3 Digital subtraction angiography showing severe vasospasm in left anterior cerebral artery and mild-to-moderate vasospasm in M1 segment of right middle cerebral artery.

perfusion. This could be the reason for worsening of renal function in SAH.

CKD is associated with an increased risk of cardiovascular complications such as hypertension, left ventricular hypertrophy, cardiomyopathy, myocardial infarction, and congestive cardiac failure. The presence of autonomic neuropathy secondary to CKD and the sympathetic stimulation following aneurysmal rupture enhances the vulnerability to intraoperative hemodynamic fluctuations. Hence, it is imperative to use invasive hemodynamic monitoring for guiding blood pressure and fluid management as done in the indexed case. Blunting of hypertensive response during laryngoscopy, intubation, and extubation is equally important to prevent intraoperative aneurysmal rupture.²

Patients with CKD are prone to fluid overload with increased susceptibility to pulmonary edema. Hence, fluids must be administered judiciously using goal-directed fluid therapy and keeping a watch on the volume of heparin flush solution being used by the neuroradiologist. Goal-directed fluid therapy involves monitoring of CVP and the pulse pressure variation from the arterial blood pressure trace. Since large volumes of heparinized saline are often used by continuous irrigation, it is advisable to restrict the volume of intravenous fluids administered. We have used CVP monitoring in this case. Also, we have used only 800 mL of PlasmaLyte during the entire procedure, keeping a watch on the urine output.

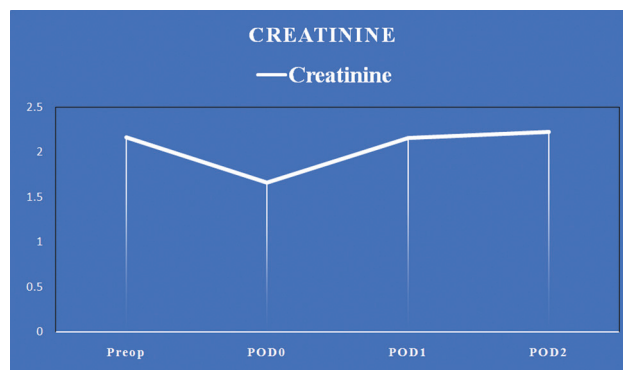


Fig. 4 Trends of creatinine values (mg/dL). POD, postoperative day.

Pre-existing renal dysfunction is the most important predisposing factor for the development of postoperative renal failure. During interventional neuroradiological procedures, patients are exposed to contrast media. This increases the risk of contrast-induced nephropathy (CIN). CIN is an acute kidney injury that occurs within 48 hours of contrast administration and causally linked to the administration of contrast medium. Monitoring renal functions for 48 to 72 hours following contrast administration is advised. In indexed case, 100 mL of contrast medium was used. Our patient did not have worsening renal function, as seen from daily creatinine values, shown in ►Fig. 4.

Adequate hydration is the single most important precaution to reduce CIN in patients with eGFR less than 45 mL/min/1.73 m². The volume of contrast media used should be restricted to less than 100 to 150 mL. Low or iso-osmolar contrast agents are preferred over high osmolar agents. In the CARE study, low and iso-osmolar contrast agents were compared in patients undergoing cardiac catheterization.⁵ There was no significant difference in the rate of CIN. N-acetyl cysteine (NAC), a cysteine derivative, has often been used for renal protection, due to its antioxidant property. However, its efficacy is questionable, with some meta-analyses showing it to be beneficial, and some showing no benefit. Although NAC has no major adverse effects, it should not be used as an alternative to adequate hydration.⁶

Another theoretical risk in CKD patients undergoing interventional neuroradiological procedures is heparin exposure. These patients may exhibit exaggerated bleeding tendencies after heparin administration, due to pre-existing platelet dysfunction. Even the half-life of unfractionated heparin has been found to be prolonged with renal dysfunction. However, there is no recommendation regarding dose reduction in heparin. Additionally, these patients have an increased tendency toward hypercoagulation due to CKD and SAH. Hence, close monitoring of coagulation parameters has been recommended.⁷ In our case, activated clotting time was monitored regularly during intraoperative period.

In the referenced case, fentanyl and propofol were used to induce anesthesia, while oxygen/nitrous oxide/isoflurane were employed to maintain anesthesia. Isoflurane, a frequently used inhalational agent to provide general anesthesia, exhibits minimal biotransformation, hence can be

administered safely used in patients with documented renal impairment. N₂O was used due to nonavailability of medical air in the remote location (digital subtraction angiography suite). Increase in cerebral metabolic requirement of oxygen, cerebral blood flow, and intracranial pressure are known with N₂O. Analgesic and amnesic property of N₂O decreases the requirement of other anesthetic and analgesic agents. Post-hoc analyses of the intraoperative hypothermia for aneurysm surgery trial data found that N₂O did not influence long-term neurological morbidity.⁸ Moreover, Singh et al suggested that avoidance of N₂O in neurosurgical patients may not affect their outcome in terms of intensive care stay or hospital stay.⁹

There is a paucity of literature regarding the anesthetic management of these patients, with only two case reports available. Mitra et al¹⁰ successfully managed an end-stage renal disease (ESRD) patient with unruptured cerebral aneurysms posted for endovascular coiling by maintaining adequate intravascular volume and avoiding fluid overload. In another report of endovascular coiling of cerebral aneurysm in a patient with ESRD, Samagh et al¹¹ restricted the volume of heparinized flush solution used by the radiologist, timed the last dialysis 12 to 24 hours prior to the procedure, and used a low volume of iso-osmolar contrast agent, avoiding ionic and high osmolar contrast agents.

Conclusion

Endovascular coiling can be safely and successfully performed in patients with chronic kidney disease provided “4Hs” are followed during the intraoperative period—adequate Hydration, close monitoring of Hemodynamics, judicious use of Heparin, and avoidance of High osmolar contrast agents. Monitoring renal function in the postoperative period is a must. Our patient had an uneventful procedure; however, the dismal outcome was due to the development of symptomatic vasospasm.

Conflict of Interest

None declared.

Funding

None.

References

- 1 Cornec-Le Gall E, Alam A, Perrone RD. Autosomal dominant polycystic kidney disease. *Lancet* 2019;393(10174):919–935
- 2 Craig RG, Hunter JM. Recent developments in the perioperative management of adult patients with chronic kidney disease. *Br J Anaesth* 2008;101(03):296–310
- 3 Chen S, Li Q, Wu H, Krafft PR, Wang Z, Zhang JH. The harmful effects of subarachnoid hemorrhage on extracerebral organs. *BioMed Res Int* 2014;2014:858496
- 4 Tujjar O, Belloni I, Hougardy JM, et al. Acute kidney injury after subarachnoid hemorrhage. *J Neurosurg Anesthesiol* 2017;29(02):140–149
- 5 Solomon RJ, Natarajan MK, Doucet S, et al; Investigators of the CARE Study. Cardiac Angiography in Renally Impaired Patients (CARE) study: a randomized double-blind trial of contrast-induced nephropathy in patients with chronic kidney disease. *Circulation* 2007;115(25):3189–3196
- 6 Owen RJ, Hiremath S, Myers A, Fraser-Hill M, Barrett BJ. Canadian Association of Radiologists consensus guidelines for the prevention of contrast-induced nephropathy: update 2012. *Can Assoc Radiol J* 2014;65(02):96–105
- 7 Grand'Maison A, Charest AF, Geerts WH. Anticoagulant use in patients with chronic renal impairment. *Am J Cardiovasc Drugs* 2005;5(05):291–305
- 8 McGregor DG, Lanier WL, Pasternak JJ, et al; Intraoperative Hypothermia for Aneurysm Surgery Trial Investigators. Effect of nitrous oxide on neurologic and neuropsychological function after intracranial aneurysm surgery. *Anesthesiology* 2008;108(04):568–579
- 9 Singh GP, Prabhakar H, Bithal PK, Dash HH. A comparative evaluation of nitrous oxide-isoflurane vs isoflurane anesthesia in patients undergoing craniotomy for supratentorial tumors: a preliminary study. *Neurol India* 2011;59(01):18–24
- 10 Mitra R, Rath GP, Dube SK, Hasija N. Anesthetic management in a patient of autosomal dominant polycystic kidney disease with end stage renal disease undergoing endovascular coiling for multiple intracranial aneurysms. *J Anaesthesiol Clin Pharmacol* 2017;33(02):256–258
- 11 Samagh N, Singh N, Jangra K, Kumar A. Endovascular coiling in a patient with chronic kidney disease- a challenge for anesthesiologist. *J Neuroanaesth Crit Care* 2020;08;. Doi: 10.1055/s-0040-1712081