



# Comparative Study of Intraoperative Fluorescein and Indocyanine Green Videoangiography for Ruptured Cerebral Aneurysms Clipping: A Single Centre Study of 30 Cases

Deepak Kumar Singh<sup>1</sup> Gaurav Sharma<sup>1</sup> Vipin Kumar Chand<sup>1</sup> Mohammad Kaif<sup>1</sup> Kuldeep Yadav<sup>1</sup>

<sup>1</sup>Department of Neurosurgery, Ram Manohar Lohia Institute of Medical Sciences, Lucknow, Uttar Pradesh, India

Address for correspondence Gaurav Sharma, MCH, 301, Tower 10, Parasvath Planet, Gomti Nagar, Lucknow 226010, Uttar Pradesh, India (e-mail: dr.gaurav\_87@yahoo.co.in).

AJNS 2023;18:25–29.

## Abstract

**Aim** This study assesses the application of microscope integrated videoangiography techniques in aneurysm clipping surgery using Indocyanine Green and Fluorescein fluorophores and evaluates merits and demerits of each technique.

**Materials and Methods** Total 30 patients of cerebral aneurysmal clipping were included. Standard microsurgical procedures were done. After clipping, we administered a 25 mg bolus intravenous dose of indocyanine green with microscope focused through the INFRARED 800 camera module, followed by administration of 60 mg bolus intravenous dose of fluorescein with microscope focused through the yellow 560 module and images were assessed.

**Results** The average aneurysm size was 17 mm. In 12 patients (40%), FL-VA allowed better assessment of perforating arteries (seven cases) or distal branches (three cases) or both (two cases), when compared with ICG-VA. In one case of MCA (M1) aneurysm, ICG-VA showed no fluorescent signal in one of the distal trunks whereas FL-VA showed normal signal. In one case of ACOM aneurysm, perforators were missed on ICG-VA but were seen on FL-VA. FL-VA was able to identify inadequate aneurysm clipping in one case. In two patients, FL-VA provided the advantage of real-time manipulation of the vessels to expose the vessels and aneurysms of interest. Fluorescein detected all the perforators that were visible under white light (68/68) whereas ICG was able to detect 56 (82.35%) perforators ( $p$ -value < 0.05).

**Conclusion** Intraoperative ICG and Fluorescein videoangiography recognize inadequate occlusion of aneurysm, decreased flow in branches or perforators. When various study parameters were considered such as ability to assess small size perforators, branching vessels, adequacy of aneurysmal clipping, and useful information on repeat imaging, FL-VA was found superior to ICG-VA.

## Keywords

- ▶ aneurysm
- ▶ clipping
- ▶ Indocyanine Green
- ▶ fluorescein

article published online  
March 27, 2023

DOI <https://doi.org/10.1055/s-0042-1751006>.  
ISSN 2248-9614.

© 2023. Asian Congress of Neurological Surgeons. All rights reserved.

This is an open access article published by Thieme under the terms of the Creative Commons Attribution-NonDerivative-NonCommercial-License, permitting copying and reproduction so long as the original work is given appropriate credit. Contents may not be used for commercial purposes, or adapted, remixed, transformed or built upon. (<https://creativecommons.org/licenses/by-nc-nd/4.0/>)

Thieme Medical and Scientific Publishers Pvt. Ltd., A-12, 2nd Floor, Sector 2, Noida-201301 UP, India

## Introduction

Intraoperative videoangiography was developed to evaluate ischemic insult during aneurysm clipping and to confirm complete occlusion of aneurysm. Evaluation of blood flow in main trunk, branches, and perforators is important for ensuring the safety of aneurysmal clipping surgery. Use of Indocyanine Green to assess blood flow in cerebral vessels was first reported in 2003.<sup>1</sup> Fluorescein dye was used by Wrobel et al to see perforating arteries.<sup>2</sup> These techniques have proven to be beneficial and have resulted in better patient outcome as they allow prompt identification of decreased flow and inadequate clipping of aneurysm. However, studies comparing ICG-VA and FL-VA are few. Our study compares FL-VA and ICG-VA during clipping of aneurysm and discuss the merits and demerits of each technique based on our experience of 30 patients of aneurysmal clipping surgery.

## Material and Methods

Total 30 consecutive patients of cerebral aneurysmal clipping surgery from March, 2020 to January, 2021 were included in this study. Patients with Hunt and Hess (H&H) grade from 1 to 4 were included. Patients with H&H grade of 5 were excluded from the study. There were 21 female patients and nine male patients and with age ranging from 30 to 67 years (mean 41 years). Among these, 10 were ACOM aneurysms, eight were MCA aneurysms, four were ICA aneurysms, three were DACA aneurysms, three were PCOM aneurysms, and two were BA aneurysms. Patient characteristic is summarized in ►Table 1.

Standard microsurgical procedures for clip ligation of aneurysms were done with flow assessment using ICG-VA and FL-VA. All patients were evaluated using a Carl Zeiss Surgical Microscope OPMI PENTERO 900 with an integrated fluorescence-based videoangiography camera module, INFRARED 800 for visualizing ICG fluorescence, and fluorescence filter module (YELLOW 560) for assessment of fluorescein fluorescence. After clipping, we administered a 25 mg bolus intravenous dose of indocyanine green with microscope focused on the desired area of interest through the INFRARED 800 camera module and images are assessed. This is followed by administration of 60 mg bolus intrave-

nous dose of fluorescein through a peripheral intravenous line and the microscope was focused through the YELLOW 560 module. We performed indocyanine green videoangiography (ICG-VA) and fluorescein videoangiography (FL-VA) under the same recommended settings, keeping operative field, focal length (300 nm), and magnification (4.5×) of the surgical microscope identical for both dyes.

## Results

### ICG-VA

After aneurysm clipping, all patients underwent ICG-VA (25 mg) to confirm the occlusion of aneurysm and blood flow in branching arteries and perforators. Images were evaluated on adjacent monitor under Infrared 800 module. This technique allowed adequate evaluation of images after reinjection of dye in patients who underwent clip repositioning. In our experience redosing can be done after 10 minutes of initial injection to have reasonable evaluation. Image quality of ICG-VA was often deteriorated in deeper operative fields. Another demerit of this technique is that it does not permit dissection or manipulation of parent vessel or perforators in real time.

### FL-VA

After ICG videoangiography, 60-mg bolus dose of sodium fluorescein was given through a peripheral intravenous access and operative field was evaluated through operative oculars with microscope integrated YELLOW 560 module. This technique allowed real-time manipulation of clip, parent and branching vessels, and perforators. Assessment of images was difficult after redosing as structures remained stained from previous injection. Another demerit of using fluorescein was that it stained the Dura (►Fig. 1) which made assessment difficult in few cases.

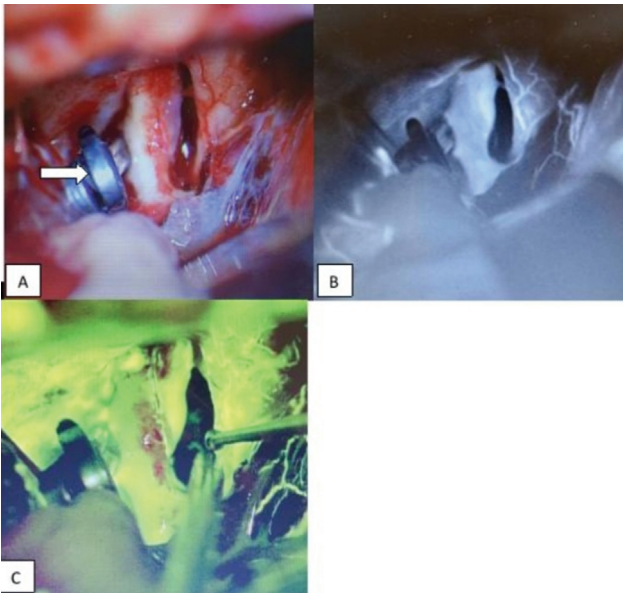
### Comparison of FL-VA and ICG-VA

The average aneurysm size was 17 mm (range 5–44 mm). All aneurysms were ruptured aneurysms. All patients underwent clip ligation of aneurysms through pterional craniotomy. In 12 patients (40%), FL-VA allowed better assessment of perforating arteries (seven cases) or distal branches (three cases) or both (two cases), when compared with ICG-VA. In one case of MCA (M1) aneurysm, ICG-VA showed no fluorescent signal in one of the distal trunks whereas FL-VA showed normal signal (►Fig. 2). Repeat injection of ICG, after some time, however, showed fluorescent signal. Postoperative imaging showed no evidence of infarct. In another case of ACOM aneurysm, perforators were missed on ICG-VA but were seen on FL-VA (►Fig. 3). FL-VA was able to identify inadequate aneurysm clipping in one case. FL-VA had no effect on clip repositioning, which was done to avoid corresponding perforator injury. When various study parameters were considered such as ability to assess small size perforators, branching vessels, adequacy of aneurysmal clipping, and useful information on repeat imaging, FL-VA was found superior to ICG-VA. In 2 patients, FL-VA provided the advantage of real-time manipulation of the vessels to expose the

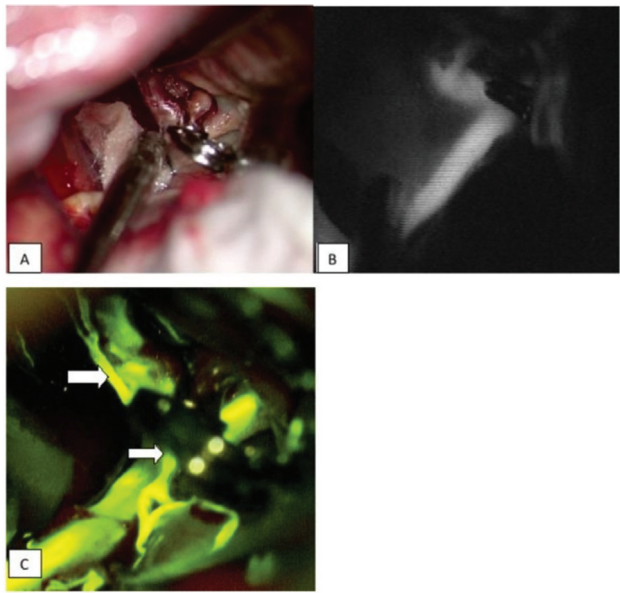**Table 1** Patient characteristics

Number of patients	30
Sex (M:F)	21:9 (7:3)
Age	30–67 (41)
Location of aneurysm	ACOM-10 MCA-8 ICA-4 DACA-3 PCOM-3 BA-2

Abbreviations: ACOM, anterior communicating artery; BA, basilar artery; DACA, distal anterior cerebral artery; ICA, internal carotid artery; MCA, middle cerebral artery; PCOM, posterior communicating artery.



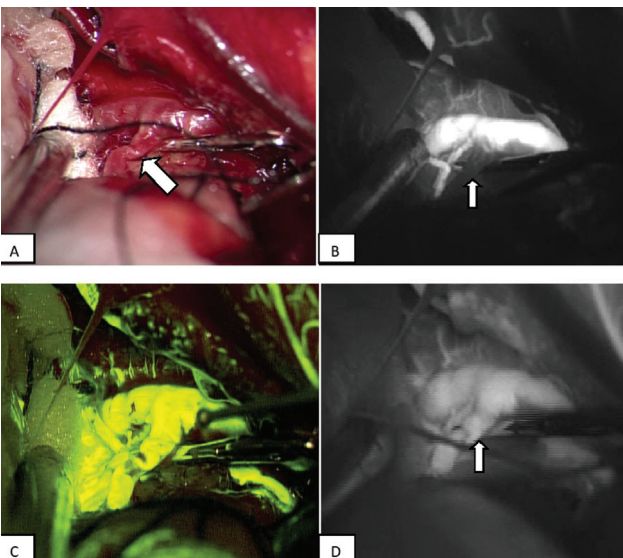
**Fig. 1** A 53-year-old male presented with SAH due to ruptured PCOM artery aneurysm and underwent clipping of aneurysm (A) through pterional craniotomy. Although ICG-VA (B) and FL-VA (C) both showed comparable images, however, FL-VAG caused staining of dura/tentorium which made interpretation difficult intraoperatively.



**Fig. 3** This 47-year-old female presented with a ruptured 7-mm ACOM artery aneurysm. She underwent clipping of aneurysm through pterional craniotomy (A). The patency of the perforators was more evident on FL-VA (C) compared with ICG-VA (B).

vessels and aneurysms of interest. The image quality of ICG-VA was often deteriorated at higher magnification in deep operative fields, partly due to the chromatic aberration. Blood clots, aneurysm, or brain tissue often obscured the view of vasculature in both ICG-VA and FL-VA. Overall, FL-VA provided superior details throughout the magnification range and was able to identify small and perforating arteries even in deeper operative fields. In one patient (5%), the FL-VA

showed aneurysmal filling after clipping while ICG-VA showed complete obliteration of aneurysm. Residual blood flow was confirmed by aneurysm puncture and was then occluded by application of additional clip. Infarcts related to perforating vessel injury were seen in three patients (10%) on postoperative imaging. However, all the three patients were asymptomatic. In all cases, perforator occlusion was due to clip application and was seen on intraoperative FL-VA and not ICG-VA. Fluorescein detected all the perforators that were visible under white light (68/68) whereas ICG was able to detect 56 (82.35%) perforators, showing statistically significant difference with *p*-value less than 0.05 (Fisher's exact test) (► **Table 2**). Out of 12 perforators missed by ICG-VA, six were PCOM perforators (► **Table 3**).



**Fig. 2** A 52-year-old female with a ruptured 18-mm right MCA (M1) aneurysm. (A) After aneurysm clipping, one of the trunks of MCA showed spasm. (B) ICG-VA showed no flow in the vessel whereas (C) FL-VA showed flow in the same vessel. (D) Repeat injection of ICG after some time showed flow in the same vessel although the image quality was degraded.

**Table 2** Number of perforators detected by ICG-VA and FL-VA

Number of perforators detected	ICG	Fluorescein	<i>p</i> -Value
	56/68 (82.35%)	68/68 (100%)	< 0.05

**Table 3** Location of perforators not detected by ICG-VA

Location of aneurysm	Number of perforators not detected
PCOM	06
ACOM	03
MCA	03

## Discussion

This paper presents our experience with the use of ICG-VA and FL-VA in 30 patients of aneurysmal clipping surgery. Ischemic complications can be present postoperatively in up to a quarter of cases of aneurysmal clipping surgery due to inadvertent occlusion of vessel.<sup>3</sup> Intraoperative detection of vessel compromise with immediate repositioning of clip is fundamental in preventing these ischemic complications. Various methods are used for evaluation of main trunk, branches, and perforators for ensuring safety of surgery with each having their merits and demerits.

Microvascular Doppler Ultrasonography is a commonly used technique to assess the quality of clipping.<sup>4</sup> It offers the advantage of being non-invasive. Small probe sizes with high frequency capabilities allow intraoperative evaluation of flow in arteries. However, its use is limited with arteries in deep operative field or to assess flow in small arteries or perforators. Also it does not give information on inadequacy of clipping.<sup>5</sup>

Another method which is helpful in assessing regional ischemia is electrophysiological monitoring but it does not give information regarding adequacy of clipping of aneurysm or vessel stenosis.<sup>6</sup> Findings are also influenced by anesthetic drugs.<sup>7</sup> Patients may also have new deficits even after complete recovery of somatosensory evoked potentials.<sup>8</sup>

Digital subtraction angiography done intraoperatively is another method to assess aneurysm obliteration and blood flow and is considered as the gold standard method but its use is limited as it is time consuming and is associated with high procedural risks.<sup>9</sup> Cost of equipment also makes it inaccessible for many centers in world.

Fluorescein angiography in neurosurgery was first introduced by Feindel et al in 1967 when he injected fluorescein dye in carotid artery.<sup>10</sup> ICG and fluorescein are two unique fluorescent agents used successfully in aneurysm surgery and based on their properties they have their advantages and disadvantages. Microscope-based ICG-VA and FL-VA were developed to evaluate not only anatomical vascular structures, but also visualization of cerebral blood flow. Both techniques do not require interruption of surgery for image acquisition. The dose recommended for ICG-VA is between 0.2 and 0.5 mg/kg and not to exceed a maximum dose of 5 mg/kg. ICG (25 mg) diluted in 5 mL of water is given intravenously as a standard bolus dose.<sup>11</sup> Within 1 to 2 seconds of intravenous administration, the ICG binds to plasma proteins. ICG has short half-life of 3 to 4 minutes and dose can be repeated after 10 minutes of administration.<sup>12</sup> The maximum wavelength of fluorescein is 465 to 490/520 to 530 nm and ICG is 805/835 nm and angiography by intravenous administration of these dyes has no interference with each other's detection.<sup>13</sup>

One disadvantage associated with ICG-VA technique is that it does not allow manipulation of clip and vessels while assessing ICG-VA as it does not visualize fluorescent and non-fluorescent tissue at the same time as it uses near infrared light with wavelengths longer than the visible spectrum. At the same time, it offers the advantage of repeatability within minutes which allows assessment after clip repositioning.<sup>14</sup> Disadvantage with ICG-VA is degradation of

images at higher magnifications and in deep surgical fields due to associated chromatic aberrations. Lane et al analyzed 22 patients who underwent ICG-VA and FL-VA after clip ligation. They also concluded that FL-VA provides superior information in deeper surgical field.<sup>14</sup>

Intravenous Fluorescein sodium remains within the vessels for longer period of time, which allows assessment of adequacy of clipping or if repositioning of clip is required. It also offers the advantage of manipulating brain, vessels and clip under the fluorescent mode. Also FL-VA provides good image assessment in deep operative field.

Intravenous fluorescein impregnates the vessel wall and clipped aneurysmal wall making the assessment difficult after repeat dosing. Fluorescein has longer clearance time and therefore longer time is required to elapse before another dose can be administered. As a result, FL-VA should be used as a final assessment tool after aneurysmal clipping. Kuroda et al used intra-arterial injections of fluorescent dyes and favored this route as quality of fluorescent images was superior to intravenous injection.<sup>15</sup> Intra-arterial administration resulted in rapid wash-out of dyes which allowed repeat serial angiography. We preferred intravenous route of administration as it was the simpler method of administration.

In our study, intravenous Fluorescein sodium detected all the perforators that were visible under white light (68/68) whereas ICG was able to detect 56 (82.35%) perforators. In study by Saito, fluorescent angiography detected all perforators (34/34) whereas ICG angiography detected 30 perforators (88.2%).<sup>16</sup>

Common disadvantage with both the methods is that they assess blood flow qualitatively, it is still difficult to assess whether the blood flow is adequate to avoid infarction.

## Limitations

This study was conducted in a single institute with small sample size. Fluorescent signals were assessed on recorded images which might differ from the images under microscope. It was difficult to evaluate superiority of one dye in detection of perforators under same conditions. Especially with ICG, depth of surgical field affects image quality.

## Conclusion

Intraoperative ICG and Fluorescein videoangiography are practical and cost effective techniques and promptly recognizes inadequate occlusion of aneurysm, decreased flow in branches or perforators. Image quality of both techniques is affected by angle of surgical approach, exposure of vasculature, presence of blood clots and brain tissue. In addition image quality of ICG-VA is affected by the depth of surgical field. ICG-VA, however, allows repeat injection of dye. Fluorescein-VA allows real time manipulation of clip and vessels and works in full magnification range. Considering the merits and demerits of both techniques, we recommend using ICG and Fluorescein videoangiography as complementary tools.

**Funding**  
None.

**Conflict of Interest**

None declared.

**References**

- 1 Raabe A, Beck J, Gerlach R, Zimmermann M, Seifert V. Near-infrared indocyanine green video angiography: a new method for intraoperative assessment of vascular flow. *Neurosurgery* 2003;52(01):132–139, discussion 139
- 2 Wrobel CJ, Meltzer H, Lamond R, Alksne JF. Intraoperative assessment of aneurysm clip placement by intravenous fluorescein angiography. *Neurosurgery* 1994;35(05):970–973, discussion 973
- 3 Barker FG II, Amin-Hanjani S, Butler WE, Ogilvy CS, Carter BS. In-hospital mortality and morbidity after surgical treatment of unruptured intracranial aneurysms in the United States, 1996–2000: the effect of hospital and surgeon volume. *Neurosurgery* 2003;52(05):995–1007, discussion 1007–1009
- 4 Akdemir H, Oktem IS, Tucer B, Menkü A, Başaslan K, Günaldi O. Intraoperative microvascular Doppler sonography in aneurysm surgery. *Minim Invasive Neurosurg* 2006;49(05):312–316
- 5 Durand A, Penchet G, Thines L. Intraoperative monitoring by imaging and electrophysiological techniques during giant intracranial aneurysm surgery. *Neurochirurgie* 2016;62(01):14–19
- 6 Dengler J, Cabraja M, Faust K, Picht T, Kombos T, Vajkoczy P. Intraoperative neurophysiological monitoring of extracranial-intracranial bypass procedures. *J Neurosurg* 2013;119(01):207–214
- 7 Schick U, Döhnert J, Meyer J-J, Vitzthum H-E. Effects of temporary clips on somatosensory evoked potentials in aneurysm surgery. *Neurocrit Care* 2005;2(02):141–149
- 8 Mizoi K, Yoshimoto T. Permissible temporary occlusion time in aneurysm surgery as evaluated by evoked potential monitoring. *Neurosurgery* 1993;33(03):434–440, discussion 440
- 9 Chiang VL, Gailloud P, Murphy KJ, Rigamonti D, Tamargo RJ. Routine intraoperative angiography during aneurysm surgery. *J Neurosurg* 2002;96(06):988–992
- 10 Feindel W, Yamamoto YL, Hodge CP. Intracarotid fluorescein angiography: a new method for examination of the epicerebral circulation in man. *Can Med Assoc J* 1967;96(01):1–7
- 11 Alander JT, Kaartinen I, Laakso A, et al. A review of indocyanine green fluorescent imaging in surgery. *Int J Biomed Imaging* 2012; 2012:940585
- 12 Raabe A, Nakaji P, Beck J, et al. Prospective evaluation of surgical microscope-integrated intraoperative near-infrared indocyanine green videoangiography during aneurysm surgery. *J Neurosurg* 2005;103(06):982–989
- 13 Suzuki K, Ichikawa T, Wayanabe Y. Evaluation of cortical blood flow by intra-arterial fluorescence cerebral angiography: comparison between indocyanine-green and fluorescein in three cases. *Surg Cereb Stroke* 2014;42(03):207–213
- 14 Lane B, Bohnstedt BN, Cohen-Gadol AA. A prospective comparative study of microscope-integrated intraoperative fluorescein and indocyanine videoangiography for clip ligation of complex cerebral aneurysms. *J Neurosurg* 2015;122(03):618–626
- 15 Kuroda K, Kinouchi H, Kanemaru K, et al. Intra-arterial injection fluorescein videoangiography in aneurysm surgery. *Neurosurgery* 2013;72(suppl operative 2):ons141–ons150, discussion ons150
- 16 Saito A. Comparison between Indocyanine-Green and Fluorescein for cerebrovascular surgery. *World J Surg Surgical Res* 2018; 1:1017