



Surgical Outcomes of Full-Endoscopic Lumbar Discectomy in the Early Adoption Phase

Ryoji Imoto¹ Michiari Umakoshi¹ Masatoshi Yunoki¹ Masaki Tatano¹ Koji Hirashita¹
Kimihiro Yoshino¹ Yasuhiko Nishimura²

¹Department of Neurosurgery, Kagawa Rosai Hospital, Kagawa, Japan

²Department of Neurosurgery, Koyo Hospital, Wakayama, Japan

Address for correspondence Masatoshi Yunoki, MD, PhD,
Department of Neurosurgery, Kagawa Rosai Hospital, 3-3-1 Joto-cho,
Marugame, Kagawa, 763-8502, Japan
(e-mail: yunomasato@yahoo.co.jp).

AJNS 2022;17:474–479.

Abstract

Background We adopted full-endoscopic lumbar discectomy (FELD) in 2019 with the assistance of the Japanese Society for Minimally Invasive and Endoscopic Techniques of Spinal Neurosurgery (JASMETS). This study analyzed short-term outcomes in our initial FELD cases and compared them with microdiscectomy cases performed during the same period.

Methods FELD was performed in 21 patients over a period of 2 years and 6 months (15 men and 6 women; mean age, 57.0 ± 17.0 years). The transforaminal approach was performed in 8 patients, the posterolateral approach in 3, and the interlaminar approach in 10. During the same period, microdiscectomy was performed in 30 patients. Japanese Orthopaedic Association (JOA) and visual analog scale (VAS) scores, operation time, blood loss volume, complications, and incidence of lumbar disc herniation recurrence were compared between the groups.

Results Preoperative VAS and JOA scores did not significantly differ between the FELD and microdiscectomy groups. JOA and VAS scores significantly improved in both groups after surgery. Operation time and incidence of recurrence rate did not differ.

Conclusion Spine surgeons who adopt FELD can achieve good surgical outcomes similar to those of microdiscectomy, even in the early period. Participation in JASMETS seminars and training and proctoring by a certified endoscopic spine surgeon were instrumental in our experience.

Keywords

- ▶ lumbar disc herniation
- ▶ complications
- ▶ full-endoscopic lumbar discectomy
- ▶ introduction
- ▶ surgical result

Introduction

Full-endoscopic lumbar discectomy (FELD) is a minimally invasive surgical treatment for symptomatic lumbar disc herniation (LDH) that removes the herniation through an 8-mm diameter cannula using a microforceps under micro-endoscopic visualization (▶ **Fig. 1A**).^{1,2} Full-endoscopic techniques can be used to treat recurrent and upper level LDH, nerve root compression due to degenerative spondylosis, as

well as purulent discitis/spondylitis.² However, spine surgeons are often hesitant to introduce FELD into their practice because specialized equipment and training are required.³ The Japanese Society for Minimally Invasive and Endoscopic Techniques of Spinal Neurosurgery (JASMETS), formerly known as the Society for Minimally Invasive and Endoscopic Techniques of Spinal Neurosurgery (SMET-SNS), has been conducting seminars and hands-on training and dispatching

DOI <https://doi.org/10.1055/s-0042-1751012>.
ISSN 2248-9614.

© 2022. Asian Congress of Neurological Surgeons. All rights reserved.

This is an open access article published by Thieme under the terms of the Creative Commons Attribution-NonDerivative-NonCommercial-License, permitting copying and reproduction so long as the original work is given appropriate credit. Contents may not be used for commercial purposes, or adapted, remixed, transformed or built upon. (<https://creativecommons.org/licenses/by-nc-nd/4.0/>)

Thieme Medical and Scientific Publishers Pvt. Ltd., A-12, 2nd Floor, Sector 2, Noida-201301 UP, India

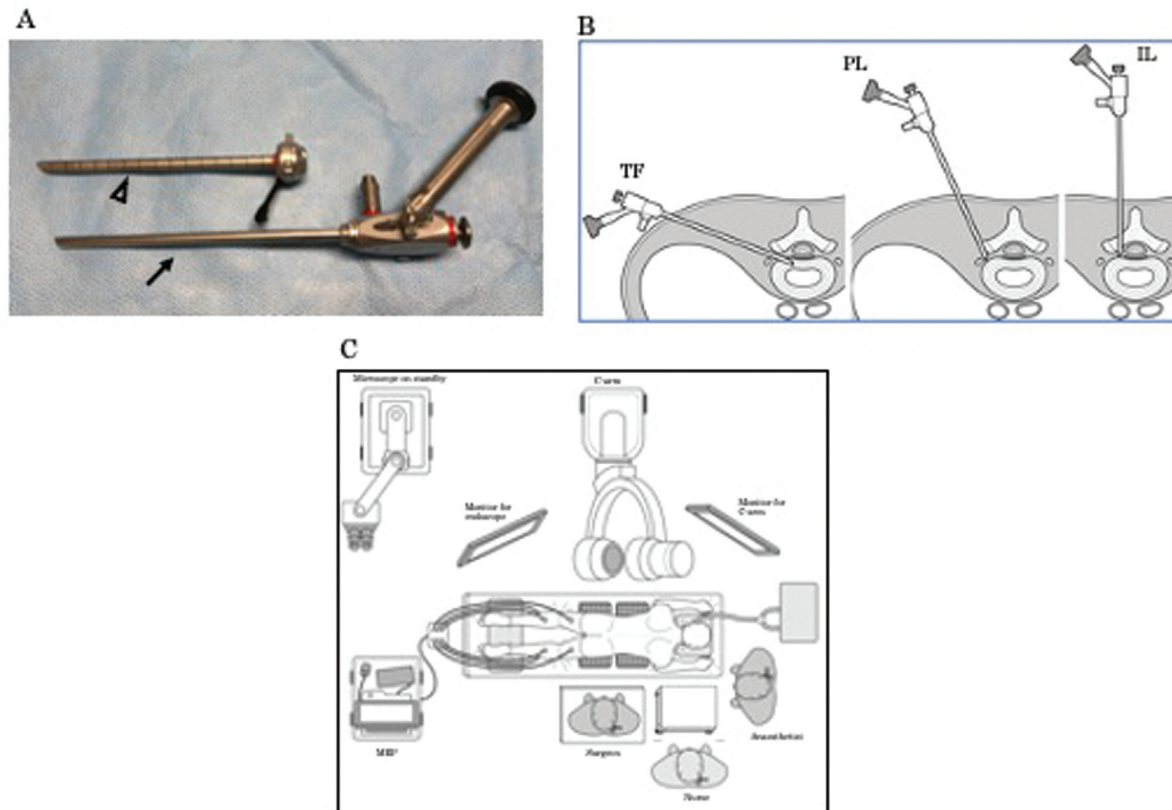


Fig. 1 (A) An endoscope (→) and a cannula (△) used for a full-endoscopic lumbar discectomy (FELD). An endoscope is inserted into a cannula in FELD, and instruments are manipulated through the endoscope. (B) Schematic illustration of the three approaches in FELD. TF, transforaminal approach; PL, posterolateral approach; IL, interlaminar approach. (C) Schematic diagram of the operating room setup for FELD.

surgical experts around the country to educate and assist fellow neurosurgeons in adopting FELD. As a result, we began to use FELD in our institution in 2019. This article provides an overview of our adoption of FELD and compares our early short-term FELD outcomes with those of microscopically performed lumbar discectomy during the same period.

Materials and Methods

FELD Introduction

An experienced spinal surgeon from our institution participated in two technical certification seminars and a hands-on spine endoscopy certification course organized by JASMETs. This training was supplemented by direct guidance from a SMET-SNS-certified endoscopic spine surgeon during the surgeon's first three FELD cases. Proficiency was further increased by participating in cadaver training.

Patients

Fifty-one consecutive patients who underwent surgical treatment for LDH from July 2019 to December 2021 were retrospectively analyzed. The indication for surgery in all patients was symptomatic LDH despite conservative treatment. The patients selected the type of lumbar discectomy (FELD or microdiscectomy) after being informed of the details of each approach; they were also informed that FELD was in the introductory stage. The study was approved by the Ethics Committee of Kagawa Rosai Hospital on May 15, 2020 (No. R2–2).

Pre- and postoperative visual analog scale (VAS) and Japan Orthopaedic Association (JOA) scores, operative time, blood loss volume, surgical complications, and LDH recurrence were recorded. Twenty-one patients elected FELD (15 men and 6 women; mean age, 57.0 ± 17.0 years) and 30 elected microdiscectomy (22 men and 8 women; mean age, 58.3 ± 15.9 years).

Outcomes were evaluated using the VAS and JOA score recovery rates. The VAS recovery rate was defined as $(\text{preoperative VAS score} - \text{postoperative VAS score}) / \text{preoperative VAS} \times 100 (\%)$. The JOA recovery rate was defined as $(\text{preoperative JOA score} - \text{postoperative JOA score}) / (29 - \text{preoperative JOA score}) \times 100 (\%)$. Recovery rate of 75% or higher was considered excellent, 74 to 50% was considered good, 49 to 25% was considered fair, and 24% or lower was considered poor.⁴

Continuous variables are expressed as means \pm standard deviation and were compared using the *t*-test. Categorical variables are expressed as numbers with percentage and were compared using Fisher's exact test. A *p*-value of less than 0.05 was considered significant.

FELD Surgical Technique

All patients underwent surgery in the prone position under general anesthesia and free-running motor evoked potential monitoring. One of three FELD approaches was used: transforaminal (TF), posterolateral (PL), or interlaminar (IL)¹ (–Fig. 1B). The TF approach was performed by puncturing

10 to 12 cm from the midline at an angle of 22 to 24 degrees from the horizontal plane and entering the disc through the safety triangle in the intervertebral foramen. The PL approach was performed by puncturing 5 to 8 cm from the midline at an angle between 30 and 60 degrees from the horizontal plane; this approach was mainly applied to LDHs outside the intervertebral foramen. The IL approach was mainly applied to L5/S1 disc herniations in which the TF approach was considered difficult because of the anatomical position of the iliac crest. This approach was usually performed by puncturing 1 to 2 cm from the midline and drilling off the vertebral arch if necessary; the LDH was then removed via the same route as microdiscectomy. The operating room setup for FELD is shown in ▶Fig. 1C. Fluoroscopy and endoscopy monitors were placed opposite to the approach side. The scrub nurse was positioned to the right of the surgeon to ensure smooth handing of surgical instruments. In the TF approach, the patient was placed in a flexed position under fluoroscopy to open the intervertebral foramen. After induction of anesthesia, 1 to 2 mL of a 1:1 mixture of indigo carmine dye and Omnipaque 240 contrast (GE Healthcare, Tokyo, Japan) was injected into the disc under fluoroscopic guidance to increase disc visibility before surgery. In addition, a wide scaffold was prepared and used to facilitate operation of the foot switches of the bipolar electrocautery and drill at a height that would allow the surgeon to operate the endoscope in a natural position without shoulder strain³ (▶Fig. 2A, ⇔). In addition, a draping method was applied to prevent water leakage from the intraoperative irrigation system (▶Fig. 2B, △).

Results

Among the 21 patients in the FELD group, the TF, PL, and IL approaches were performed in 8, 3, and 10 patients, respectively. The preoperative VAS and JOA scores in the FELD group were 4.9 ± 0.8 and 15.9 ± 3.2 , respectively, and did not significantly differ from those in the microdiscectomy group. Intraoperative dural tears occurred in one patient in each group; these were closed with suture during surgery. The dural tear in the FELD group occurred in the nerve root axilla

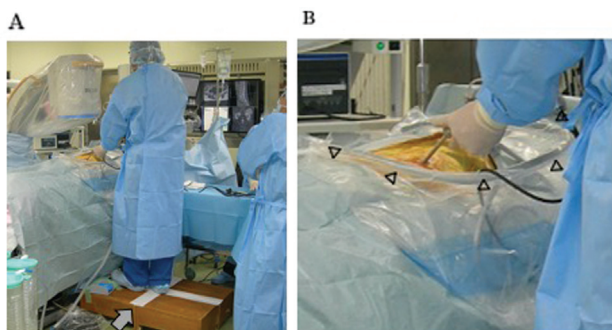


Fig. 2 (A) To enable the easy operation of bipolar and drill foot switches at a height that allows the endoscope to be operated naturally (⇔), we prepared and used a wide scaffold. (B) Because full-endoscopic lumbar discectomy (FELD) is performed with saline perfusion, the technical instructor taught the draping method, less likely to cause water leakage (△).

during an IL approach and was addressed by converting to microdiscectomy. No other serious complications occurred. Both JOA and VAS scores significantly improved in both groups. The VAS and JOA recovery rates in the FELD group were $71\% \pm 12\%$ (good) and $75\% \pm 12\%$ (excellent), respectively. In the microdiscectomy group, the corresponding scores were $74\% \pm 21\%$ (good) and $86\% \pm 9\%$ (excellent), respectively. Operative time did not significantly differ between the FELD and microdiscectomy groups (138.5 ± 62.5 vs. 112.8 ± 31.9 minutes). Blood loss volume was small (32.6 ± 25.3 mL) in the microdiscectomy group and almost negligible (≤ 5 mL) in the FELD group. Mean follow-up was 10.4 ± 7.5 months in the FELD group and 9.1 ± 5.3 months in the microdiscectomy group. Recurrent LDH occurred in one patient in each group (▶Table 1).

Illustrative Cases

Case 1: L5/S1 Disc Herniation Removed Using the IL Approach

A 20-year-old male presented with lumbago and right lower extremity pain for 3 months that persisted despite analgesic treatment. Magnetic resonance imaging (MRI) showed a right L5/S1 disc herniation (▶Fig. 3A, B). Right S1 sensory disturbance was noted on neurological examination. JOA and VAS scores were 17 and 5, respectively. After informed consent was obtained, FELD using the IL approach was performed. After the yellow ligament was removed during surgery, the blue-stained prolapsed herniated mass was identified lateral to the right S1 nerve root (▶Fig. 3C) and removed. This decompressed the nerve root, which moved laterally. After confirming no lateral or ventral S1 nerve root compression (▶Fig. 3D), the operation was terminated. Immediately after surgery, the patient reported symptom relief without pain at the surgical site. He was discharged on the third postoperative day with JOA and VAS scores of 28 and 1, respectively. The MRI at discharge showed a sufficient reduction in the size of the hernia (▶Fig. 3E, E). No symptom recurrence was observed at the 2-month follow-up.

Case 2: L3/4 Disc Herniation Using the TF Approach

A 72-year-old male was referred to us by his local physician to evaluate lumbago and severe right lower extremity pain. MRI showed a left L3/4 disc herniation that reached the left intervertebral foramen (▶Fig. 4A, B). A left L3 nerve root block provided temporary relief. Preoperative JOA and VAS scores were 11 and 8, respectively. After informed consent was obtained, FELD was performed using the TF approach. During surgery, the blue-stained disc was identified (▶Fig. 4C) and a cavity in the disc was created. As the angle of the endoscope shifted more horizontally, the epidural dissection was performed and the traversing nerve root was identified (▶Fig. 4D). The endoscope and cannula were then gradually shifted superiorly until the exiting nerve root was visible and the migrated herniated disc fragment was dissected (▶Fig. 4E). The cannula was then withdrawn under fluoroscopy to confirm nerve root decompression. The patient's symptoms improved immediately and he was

Table 1 Surgical results of the FELD and microdiscectomy groups

		FELD (n = 21)	Microdiscectomy (n = 30)	p-Value
Age		56.5 ± 17.6	58.3 ± 15.9	0.71
Sex (M:F)		15:06	22:08	1
Level	L2/3	3 (TF)	1	0.097
	L3/4	4 (TF)	7	
	L4/5	4 (TF)	14	
	L5/S1	10 (IL)	8	
VAS	Preop	5.4 ± 1.3	6.0 ± 1.9	0.15
	Postop	1.8 ± 1.3 ^a	1.5 ± 0.7 ^a	0.36
	Rate of improvement	0.67 ± 0.17	0.73 ± 0.16	0.21
JOA score	Preop	15.9 ± 3.2	14.4 ± 4.9	0.24
	Postop	25.8 ± 2.7 ^a	25.9 ± 1.8 ^a	0.89
	Rate of improvement	0.76 ± 0.16	0.78 ± 0.12	0.57
Complication		Dural injury: 1	Dural injury: 1	1
Operative time		131.5 ± 45.2 min	111.0 ± 29.3 min	0.057
Blood loss		Small amount	32.6 ± 25.3 mL	–
Follow-up (mo)		8.9 ± 5.8	7.3 ± 5.6	0.076
Recurrence		1	1	1

Abbreviations: F, female; FELD, full-endoscopic lumbar discectomy; IL, interlaminar; JOA score, Japan Orthopaedic Association score; M, male; TF, transforaminal; VAS, visual analog scale.

^aSignificantly different ($p < 0.05$) compared with the preoperative values of each group.

discharged 7 days later with JOA and VAS scores of 28 and 1. MRI at discharge showed a sufficient reduction in the size of the hernia (–Fig. 4E, F). No symptom recurrence was observed at the 3-month follow-up.

Discussion

Microdiscectomy for LDH is associated with good surgical outcomes⁵ and has been commonly performed by surgeons in our department. Since the introduction of FELD in Japan in 2003,⁶ its use has been increasing; however, some spine surgeons have been reluctant to adopt it. Reasons include good microdiscectomy outcomes and the fact that FELD is a completely different technique that requires new skills and training.⁷ Surgeons usually experience a higher incidence of FELD complications in the period early after adopting the technique⁸; therefore, it is important to obtain good outcomes in this phase. In Japan, JASMETs regularly holds seminars and hands-on sessions to educate fellow surgeons regarding minimally invasive spinal endoscopic surgery, FELD in particular. Certified surgeons are also available to attend FELD surgeries upon request to assist in operating room setup and provide guidance. By participating in JASMETs seminars and workshops and inviting a certified surgeon to provide guidance, we were able to safely perform 21 FELD cases in the first 2 years and 6 months after adopting the technique. We found that direct detailed instruction regarding surgical instrument handling and operating room setup was essential to our success.

We were able to invite a certified physician to our institution for guidance only three times because of the

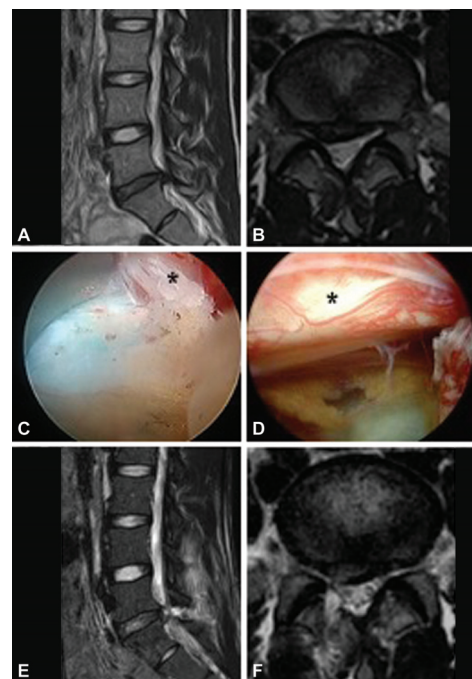


Fig. 3 Images of a 20-year-old male who underwent full-endoscopic lumbar discectomy (FELD) with the interlaminar approach. Preoperative right paramedian sagittal (A) and axial (B) T2-weighted magnetic resonance images showing a right herniated disc at L5/S1. Endoscopic view showing a blue-stained herniated disc compressing the right S1 nerve root (*) medially (C). After removing the herniated disc medial to the right S1 nerve root, we confirmed sufficient decompression of the right S1 nerve root (D). Postoperative magnetic resonance imaging (MRI) at 3 days showed a reduction in the size of the hernia. (E) Left paramedian sagittal image. (F) Axial image at L5/S1.

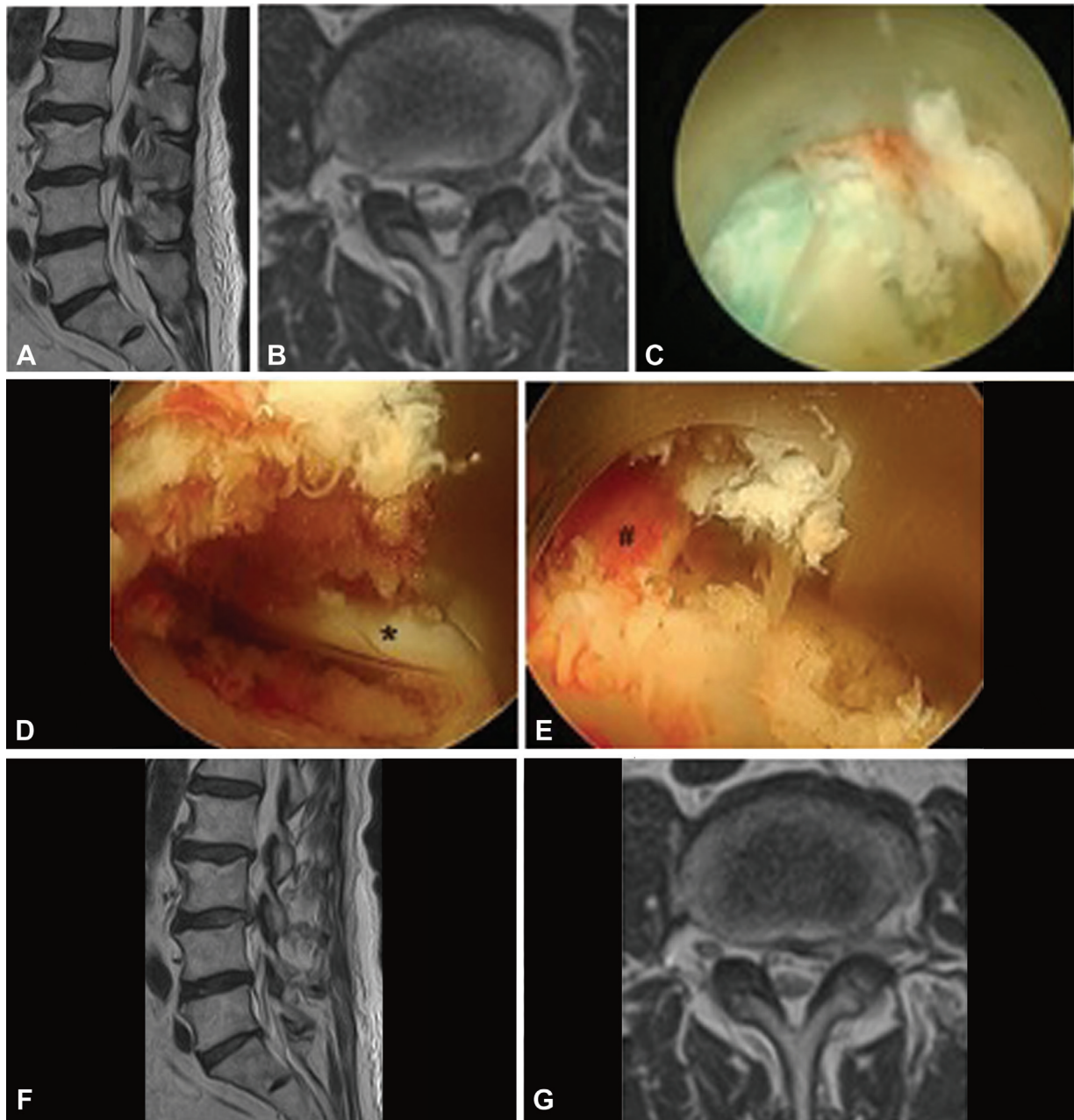


Fig. 4 Images of a 72-year-old man who underwent full-endoscopic lumbar discectomy (FELD) with the transforaminal approach. Preoperative left paramedian sagittal (A) and axial (B) T2-weighted magnetic resonance imaging (MRI) demonstrating a left herniated disc at L3/4 that reached the right intervertebral foramen. The endoscopic view shows a blue-stained disc (C). The traversing nerve root (*) was identified after the epidural dissection was performed (D). The endoscope and cannula were then gradually shifted cranially, and the migrated herniated disc fragment was dissected, then the exiting nerve root (#) was decompressed (E). Postoperative MRI at 3 days confirmed a reduction in the size of the hernia. (F) Left paramedian sagittal image. (G) Axial image at L3/4.

coronavirus disease 2019 pandemic; however, our relationship with him has continued and he has been available to respond to any questions. Our surgical skill improvement has relied on his continued direct guidance. We consider such a relationship to be essential.

FELD has several advantages. It causes little damage to muscle tissue, the vertebral arch, yellow ligament, and posterior longitudinal ligament. In addition, it provides a view of the LDH that is not possible with microscopy and the operative field is kept clean owing to water irrigation.

Furthermore, the TF approach can be used for revision surgery without passing through adherent scar tissue.⁷

A LDH located inside or outside the intervertebral foramen, as in case 2, often does not respond to conservative treatment.^{9,10} The conventional posterior median and paraspinal methods are highly invasive, while FELD is less so.¹⁰ Our case series included three such cases and all experienced good results. We consider these to be a good indication for FELD.

Another advantage of FELD is that the technique and skills required can be applied to diseases other than LDH as the

surgeon's skills improve. Other full-endoscopic spine surgery techniques include percutaneous endoscopic laminoplasty for lumbar spinal stenosis, percutaneous endoscopic cervical keyhole foraminotomy for cervical radiculopathy, and percutaneous endoscopic discectomy and drainage for pyogenic spondylitis. Further developments in full-endoscopic spine surgery are expected in the future.⁷

Complications of FELD include postoperative dysesthesia (owing to surgical nerve root stimulation), intra-abdominal organ injury during disc puncture in the high lumbar spine, and less frequently, massive bleeding from an intraforaminal artery. Dural injury is a relatively common complication of the TF and IL approaches.^{11,12} The one we experienced occurred during an IL approach to an L5/S1 disc herniation. In this case, the herniation appeared axillary on preoperative MRI; however, it was actually in the shoulder region. After the injury, we immediately switched to microscopic surgery and performed a successful repair. Such a possibility should be explained to the patient before surgery.

On a technical note, meticulous hemostasis at the time of endoscope removal is essential. Moreover, discontinuation of antiplatelet agents and anticoagulants before surgery is required. Even a small wound hematoma can cause symptoms because of the small size of the wound.¹³ Intracranial hypertension must also be considered, as it has been reported in cases of high perfusion pressure or prolonged surgery. Furthermore, epileptic seizures may occur after neck pain or headache. However, we have not experienced any such complications to date, probably because of our participation in the JASMETS seminars and training.

Conclusion

Spine surgeons who adopt FELD can achieve good surgical outcomes similar to those of microdiscectomy, even in the early period. Participation in JASMETS seminars and training and proctoring by a certified endoscopic spine surgeon were instrumental in our experience.

Conflict of Interest

None declared.

References

- Ahn Y, Oh HK, Kim H, Lee SH, Lee HN. Percutaneous endoscopic lumbar foraminotomy: an advanced surgical technique and clinical outcomes. *Neurosurgery* 2014;75(02):124–133, discussion 132–133
- Ruetten S, Komp M, Merk H, Godolias G. Full-endoscopic interlaminar and transforaminal lumbar discectomy versus conventional microsurgical technique: a prospective, randomized, controlled study. *Spine* 2008;33(09):931–939
- Lee DY, Lee SH. Learning curve for percutaneous endoscopic lumbar discectomy. *Neurol Med Chir (Tokyo)* 2008;48(09):383–388, discussion 388–389
- Kim K, Sasaki M, Kawamoto T, Koyanagi I. Guidelines for the assessment of neurological state in spine and spinal cord disorders – scoring system for clinical studies. *Spinal Surg* 2016;30:41–52
- Arts MP, Brand R, van den Akker ME, Koes BW, Bartels RH, Peul WCLeiden-The Hague Spine Intervention Prognostic Study Group (SIPS) Tubular discectomy vs conventional microdiscectomy for sciatica: a randomized controlled trial. *JAMA* 2009;302(02):149–158
- Yeung AT, Tsou PM. Posterolateral endoscopic excision for lumbar disc herniation: surgical technique, outcome, and complications in 307 consecutive cases. *Spine* 2002;27(07):722–731
- Ohara Y, Mizuno J, Nishimura Y. Percutaneous endoscopic lumbar discectomy: comprehending the present and proceeding towards the future. *Spinal Surg* 2016;30:152–158
- Wang H, Zhou Y, Li C, Liu J, Xiang L. Risk factors for failure of single-level percutaneous endoscopic lumbar discectomy. *J Neurosurg Spine* 2015;23(03):320–325
- Kong M, Xu D, Gao C, et al. Risk factors for recurrent L4-5 disc herniation after percutaneous endoscopic transforaminal discectomy: a retrospective analysis of 654 cases. *Risk Manag Healthc Policy* 2020;13:3051–3065
- Jang JS, An SH, Lee SH. Transforaminal percutaneous endoscopic discectomy in the treatment of foraminal and extraforaminal lumbar disc herniations. *J Spinal Disord Tech* 2006;19(05):338–343
- Sairyo K, Matsuura T, Higashino K, et al. Surgery related complications in percutaneous endoscopic lumbar discectomy under local anesthesia. *J Med Invest* 2014;61(3-4):264–269
- Tezuka F, Sakai T, Nishisho T, et al. Variations in arterial supply to the lower lumbar spine. *Eur Spine J* 2016;25(12):4181–4187
- Dezawa A, Yunokawa S, Hirota K, Dezawa T. Surgical technique of endoscopic decompression for spinal canal stenosis using DPEL scope. *Spine & Spinal Cord* 2021:107–114