

Butterfly Graft Technique for Addressing the Internal Nasal Valve

Rahul Varman, MD¹  Madison Clark, MD²

¹Department of Otolaryngology—Head and Neck Surgery, Texas Tech University Health Science Center, Lubbock, Texas

²Department of Otolaryngology—Head and Neck Surgery, University of North Carolina at Chapel Hill, Chapel Hill, North Carolina

Address for correspondence Madison Clark, MD, Division of Facial Plastic and Reconstructive Surgery, Department of Otolaryngology, University of North Carolina, 170 Manning Drive, Campus Box 7070, Chapel Hill, NC 27599 (e-mail: madison_clark@med.unc.edu).

Facial Plast Surg 2022;38:347–352.

Abstract

Keywords

- ▶ butterfly graft
- ▶ rhinoplasty
- ▶ nasal obstruction
- ▶ internal nasal valve
- ▶ conchal cartilage

Nasal airway obstruction is a common presenting complaint to otolaryngology clinics, with the internal valve a commonly implicated anatomic area of obstruction. The nasal butterfly graft is a robust technique to address this subsite with good reported functional and aesthetic outcomes in both primary and secondary rhinoplasty. We describe our approach to patient evaluation, surgical candidate selection, operative technique, and outcomes assessment for this technique.

Nasal airway obstruction (NAO) is a common complaint presenting to ear, nose, and throat clinics. Nasal obstruction impacts quality of life (QOL) for patient, as well as confers a significant economic burden on society.¹ The mission of the otolaryngologist presented with this problem becomes to determine medical or surgical etiologies for nasal congestion and NAO and offer appropriate treatments which may optimize functional and aesthetic nasal outcomes for the patient.

The inferior corridor of the nasal valve is an anatomic area bordered by the inferior nasal septum and inferior turbinate and represents a common anatomical area contributing to NAO in around 67% of patients.² The superior corridor, defined by the area superior to an imaginary horizontal line at the superior margin of the inferior turbinate is bordered by the superior nasal septum and the caudal margin of the upper lateral cartilage (ULC).³ Methods to address the internal nasal valve (INV) include techniques that can change the three-dimensional shape of borders. Specific techniques include but are not limited to septoplasty, turbinate reduction, spreader grafts, butterfly grafts, and batten grafts. Traditionally, septoplasty and spreader grafts have been the mainstay of addressing the INV.

The butterfly graft was first described by Clark and Cook in 2002 and has gained popularity in surgical correction of nasal valve compromise.⁴ Cadaveric computational fluid dynamic models have shown that butterfly graft provides

up to twice as much reduction in nasal airflow resistance compared with spreader grafts.⁵ Functional and aesthetic outcomes studies in recent years have continued to support butterfly graft as a powerful technique to address the INV.^{6,7} Modifications to the technique in recent years have continued to optimize outcomes and have shown this technique to be a robust option in both primary and secondary rhinoplasties.

Herein we will discuss an approach employed to selecting an ideal candidate for this graft technique, nuances of performing the technique, in addition to outcomes and complications to counsel and monitor for when providing the prospective patient with proper informed consent.

Patient Assessment

Evaluation of patients presenting with a complaint of nasal obstruction begins with comprehensive history and physical examination. History should focus on the patient's nasal narrative, including factors such as other underlying medical conditions affecting nose, when the complaints began, prior treatments tried, and how nasal breathing affects patient QOL. Most insurance companies require that a patient "fail" a trial of 4 to 6 weeks of an intranasal steroid as a prerequisite for approval of nasal surgery. Improvement in nasal breathing with nasal strips can predict success of butterfly graft.⁸

Issue Theme Functional Facial Plastic Surgery; Guest Editors: Clinton D. Humphrey, MD, FACS, and J. David Kriet, MD, FACS

© 2022, Thieme. All rights reserved. Thieme Medical Publishers, Inc., 333 Seventh Avenue, 18th Floor, New York, NY 10001, USA

DOI <https://doi.org/10.1055/s-0042-1753521>.
ISSN 0736-6825.

Other key history points that should not be missed include a history of trauma or prior surgeries to the nose, as these may predict a paucity of septal cartilage for support or structural grafting. Validated questionnaires such as Nasal Obstruction Symptom Evaluation (NOSE) questionnaire or FACE-Q scale can be utilized to compare the effect of treatment.

Physical exam should start with a comprehensive head and neck exam prior to a thorough nasal examination. Donor site for butterfly graft is conchal cartilage thus ear examination becomes especially important. Clinical findings indicating deficient or malformed auricular cartilage (cauliflower ear, calcification, etc.) may influence the chosen surgical technique. Next, the surgeon should employ a comprehensive and systematic physical examination of the nose.

External exam of the nose begins with assessment in the context of the face, including vertical and horizontal discrepancies, any overall facial asymmetries, and asymmetry in the facial muscle movement on the nose. Nasal skin should then be assessed for thickness and any traumatic or surgical scars. Other nasal features such as narrow bony vault, dorsal hump, deviated nose, and tip concerns should also be examined as butterfly graft is often performed in addition to other rhinoplasty techniques. Palpation is an underappreciated but critically important part of the nasal examination, especially the palpable strength of the ULCs in patients with nasal valve collapse (NVC).

Internal nasal exam should focus on various subsites which may be contributing to nasal obstruction, paying specific attention to both the inferior and superior corridors.

Septal deviation can often be seen on anterior rhinoscopy, and sometimes flexible nasal endoscopy may need to be performed to assess the posterior septum, as well as to visualize the superior corridor without manipulation of the nostril by the nasal speculum. Inferior turbinate hypertrophy should be noted, including features suggestive of underlying allergic rhinitis which would portend long-term medical treatment of the mucosal disease. ULC assessment is of key importance for selecting a patient for butterfly graft. Improvement in perception of nasal airflow with modified Cottle maneuver is a more specific indicator of improvement with INV surgical techniques.⁹

Preoperative Counseling

As outcomes from nasal surgery are primarily judged based on subjective criteria, appropriate surgical selection and counseling on expectations and risks is especially important. Since the donor site is the ear, patients should be counseled on expectations and risks to the ear including pain, local infection (2.9%), hematoma (6.7%), and scarring.¹⁰ Using pre- and postoperative photos, demonstration of the increased nasal supratip width that will occur as with use of spreader grafts is critical to establish appropriate expectations.¹¹ Camouflage of the butterfly graft is more difficult and aesthetically apparent in patients with long, slender noses or thin skin. With appropriate modifications, the graft is most often not visible to medical professionals but should be discussed as likely to be visible to the patient.⁷ Also discussed

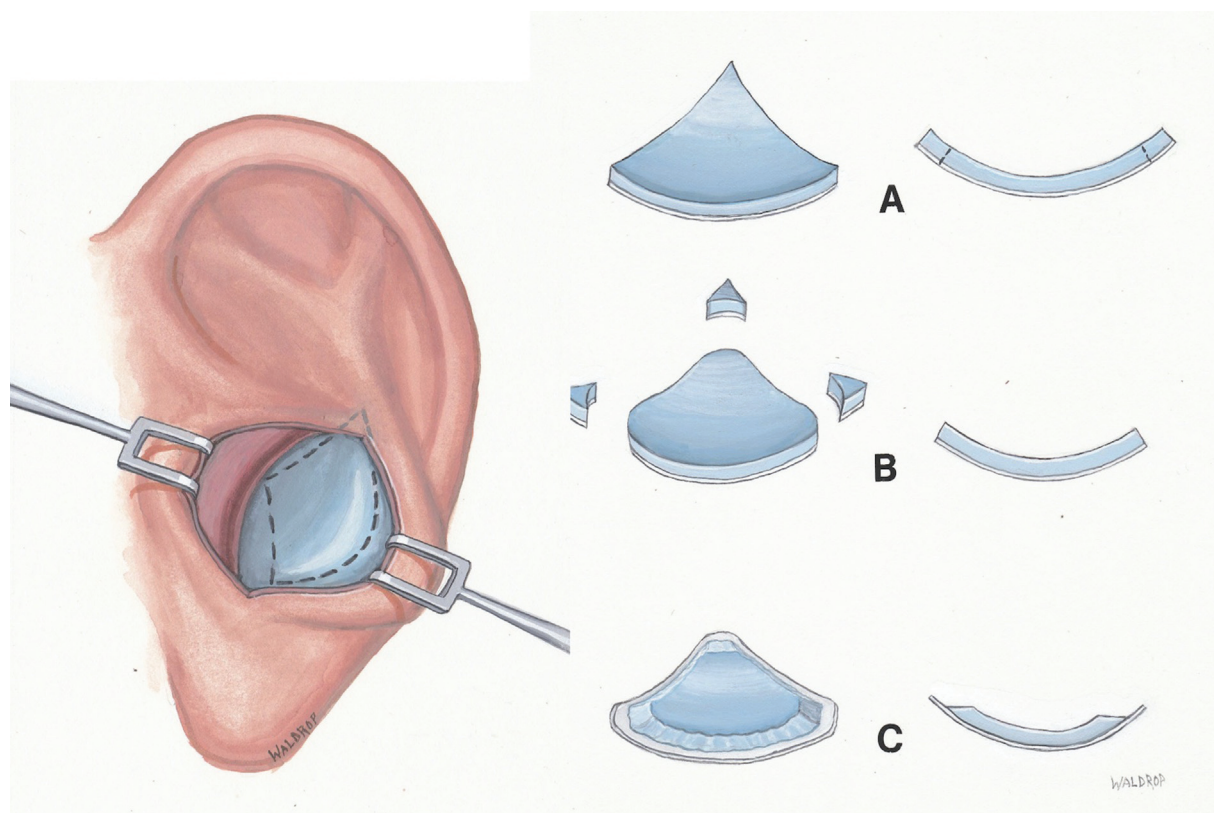


Fig. 1 During conchal cartilage harvest, a thin layer of perichondrium is preserved anteriorly (to avoid cartilage fracture) and more robust perichondrium is preserved posteriorly (to “hold” suture).

is the fact that no surgical treatment of NVC is perfect, and persistent nasal obstruction either improved or unchanged with butterfly grafting technique is reported around 13.3% of patients.¹² The patient should be informed that mucosal contributors to NAO may require ongoing medical management, even after successful surgery.

Operative Technique: Butterfly Graft

Conchal Cartilage Graft Harvest

The butterfly graft technique is usually performed as part of a reconstructive septorhinoplasty under general anesthesia. Attention first turned toward harvesting auricular cartilage. Local anesthesia (1:1 of 1% lidocaine with 1:100,000 epinephrine and 0.5% bupivacaine with 1:200,000 epinephrine) injected anterior ear and posterior ear in subcutaneous fashion to allow posterior cartilage to remain adherent to perichondrium on the convex aspect of the graft. A curvilinear incision is made along the medial antihelix with back cut into the conchal bowl between the antitragus and antihelix. Blunt dissection anteriorly is performed to expose the conchal cartilage, leaving a thin layer of perichondrium anteriorly to help avoid inadvertent cartilage fracture. (► Fig. 1) A #15 blade is then used to incise through cartilage and posterior perichondrium in a triangular shape approximately 2.2 cm × 1.2 cm. Supraperichondrial dissection is then

carried until graft is freed and placed into saline on back table. After adequate hemostasis is obtained, incisions are closed and Telfa bolster is placed as a pressure dressing.

Graft Carving

The auricular cartilage graft is then carved to fit the desired inset location. The tips are trimmed to create smooth corners, and then edges on the superior concave side are beveled while leaving a drupe of perichondrium to allow smooth transition into the iatrogenic nasal defect at the anterior septal angle (► Fig. 2). If the graft is overly strong, Brown-Adson forceps or cartilage morselizer can be used to weaken the cartilage. Average size of carved cartilage is around 2 cm × 1 cm, but varies depending on the nasal features (size and shape of the nose and aesthetic expectations of the patient). The caudal medial “corners” of the graft are marked with a marking pen to assist centering the graft at the anterior septal angle.

Septum/Turbinates

If indicated, septoplasty and turbinate reductions are completed prior to butterfly graft procedure.

Nasal Dorsum Preparation

Endonasal and open approaches can be utilized to expose location for butterfly graft placement, although the senior

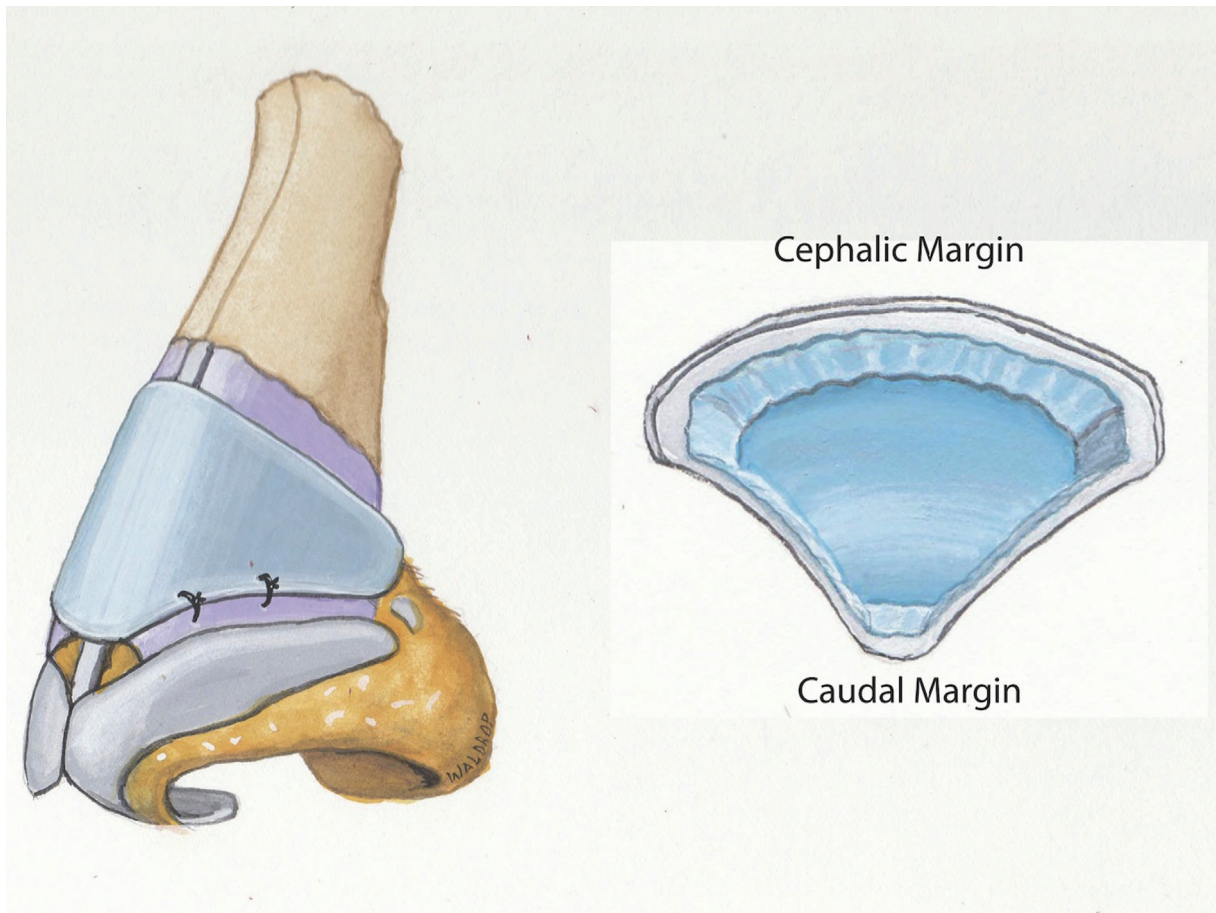


Fig. 2 The cephalic margin of the sculpted graft fits into the defect created at the caudal end of the dorsal septum and upper lateral cartilages.

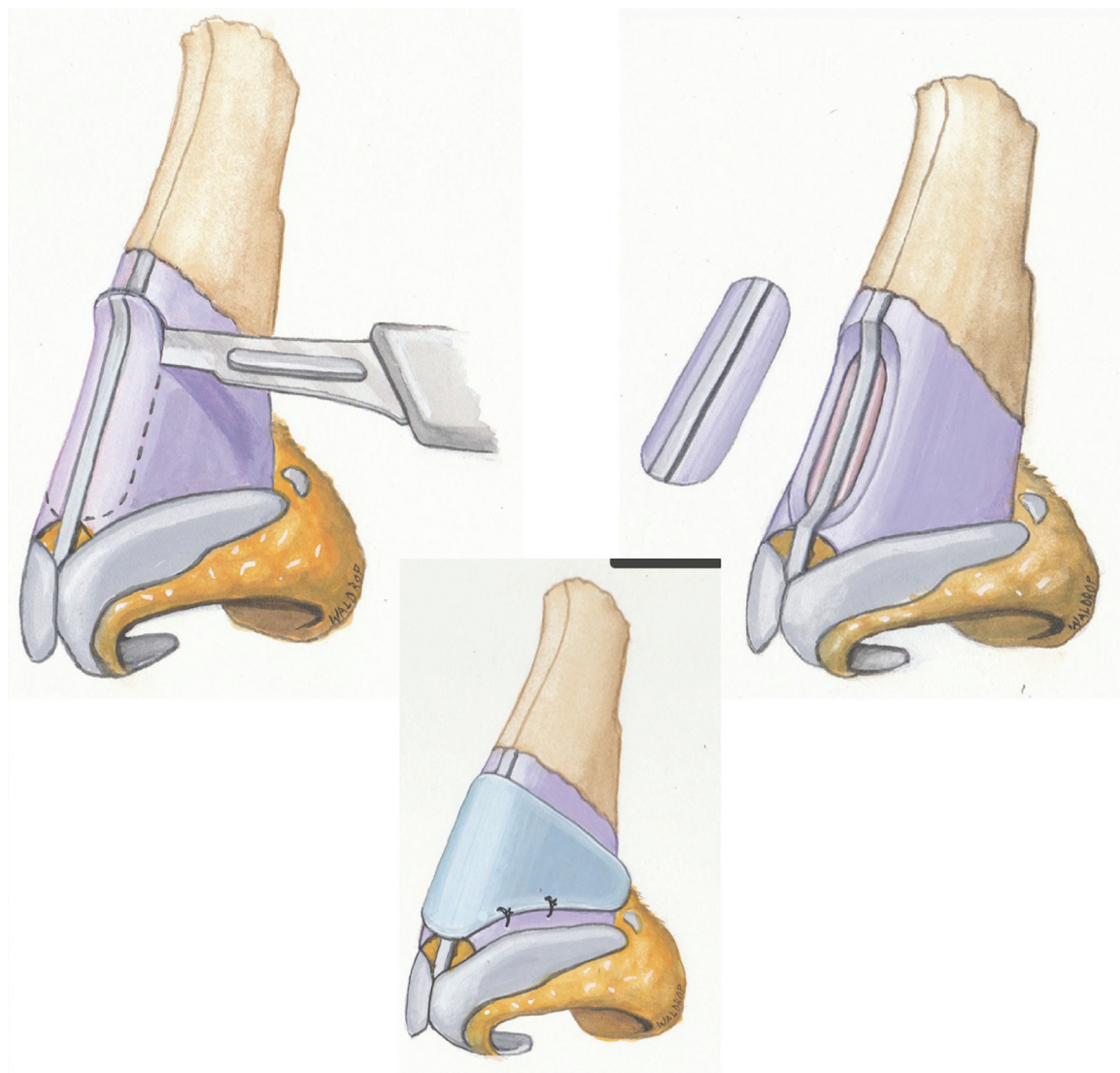


Fig. 3 The precise release of the caudal dorsal septum and upper lateral cartilage to match the dimensions of the butterfly graft.

author strongly prefers the endonasal approach. In either approach, the skin soft tissue envelope is elevated in the standard fashion cephalically to the nasion. A #15 blade is used to create a few millimeter depression in the dorsal septum cephalic to and including the anterior septal angle while preserving underlying mucoperichondrium, deepening as the cut is made caudally to allow for thickness of the butterfly graft (► **Fig. 3**). Areas of ULC which are still attached to the septum are released to allow for controlled placement of the caudal margins of the ULCs.

Graft Placement

The graft is placed into the depression defect with an open approach or inserted through the right intercartilaginous incision in the endonasal approach (► **Video 1**). The cephalic margin of the graft fits precisely in the defect created for graft placement. The graft is placed as caudally as possible to improve camouflage. 5–0 Polydioxanone sutures on P-2 needle are used to secure the graft. Medially using the markings,

the graft is secured to the medial and caudal aspects of the ULC. Once centered, the lateral sutures are placed laterally to allow two-point suture stabilization on bilateral sides. This both has the effect of widely opening the apex of the INV and reduces the visibility of the lateral “wings” of the butterfly graft. The soft tissue envelope is then redraped over the framework, and external contour is evaluated. In situ graft modifications can be performed as needed to address and contour deformities prior to closure of the incisions.

Video 1

Endonasal Placement of the Butterfly Graft. Online content including video sequences viewable at: <https://www.thieme-connect.com/products/ejournals/html/10.1055/s-0042-1753521>.

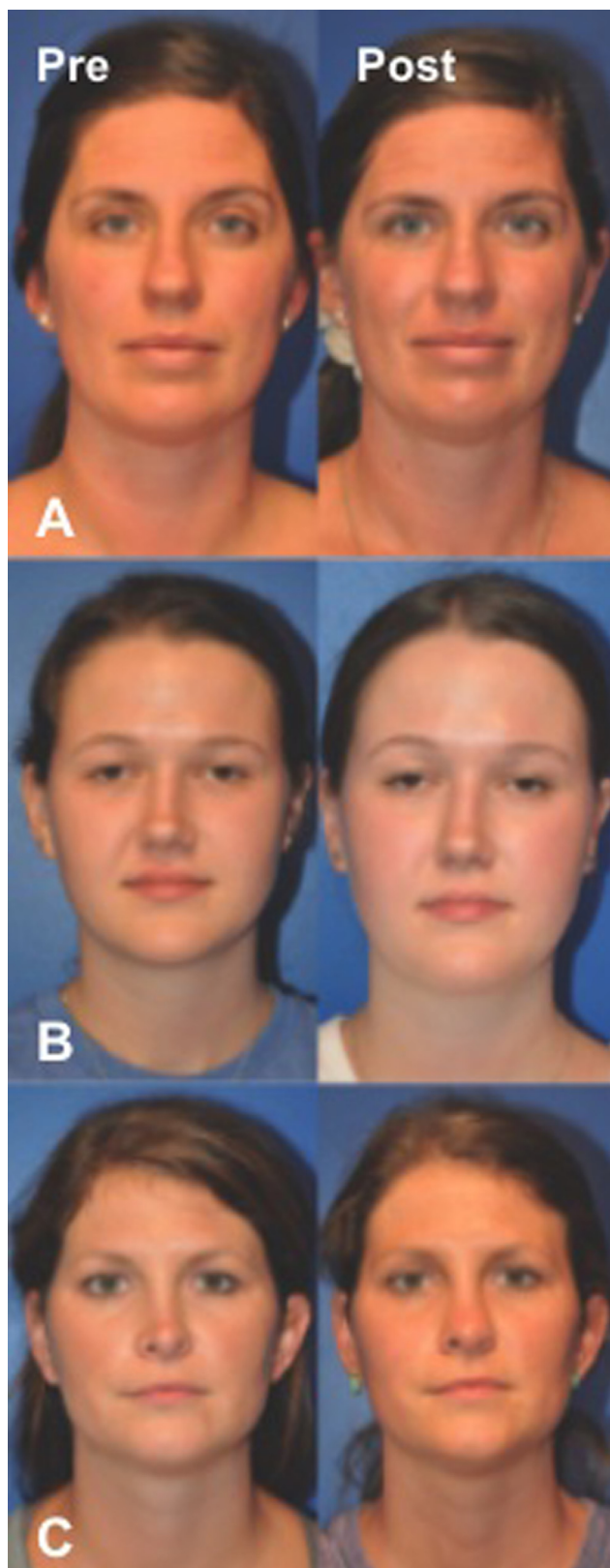

Fig. 4 Pre- and post-photos of (A) a young Caucasian woman with thin skin, demonstrating minimal postoperative supratip fullness with the butterfly graft in primary septorhinoplasty. (B) A teenage Caucasian woman with very thin skin, demonstrating very minimal postoperative supratip fullness with the butterfly graft in a tertiary septorhinoplasty. (C) A young Caucasian woman with extremely thin skin demonstrating minimal postoperative supratip fullness and overall aesthetic improvement with the butterfly graft.

Dressings

The nasal dorsum is dressed with adhesive and paper tape and a thermoplastic cast is used to allow for wearing of glasses on top of the cast for 6 weeks postoperatively.

Postoperative Care

Patients are instructed to continue saline irrigations and steroid nasal sprays twice daily for 2 weeks, and then once daily for 3 months. On postoperative day 1, ear is addressed by removing Telfa bolster and cleaning the ear incision. The nasal cavities are cleaned and suctioned. Tape and the thermoplastic cast are removed on postop day 5. The skin is usually retaped to encourage skin and soft tissue envelope redraping. The tape is removed on postoperative day 12. Suctioning is repeated on postoperative days 5 and 12.

Outcomes

Functional outcomes following butterfly graft technique have been favorable supporting its use in primary and secondary rhinoplasty. Common methods reported for outcomes reporting are combination of subjective chief complaint improvement or use of a validated questionnaire such as NOSE score. In one large study, 444 of 512 patients (86.7%) reported they experienced complete resolution of nasal obstruction, 49 patients (9.6%) reported that their nasal obstruction improved, and 19 patients (3.7%) reported no improvement. No patient reported worsening nasal breathing after butterfly graft placement (Howard). It should be noted that correlation of patient-reported symptoms (perception of nasal airflow) does not always correlate with objective measures (Mohan). This should be discussed with patients preoperatively.

Aesthetic outcome with butterfly graft focuses on visibility of graft postoperatively in the supratip area. Outcomes in prior studies have been reported as surgeons measured changes to anatomy, patient self-perception of changes, or photographic third-person assessments of changes. After the initial description of technique, one study found an average increase in supratip width by 6.4% and an average increase in supratip projection by 8.5%.¹³ Modifications including the perichondrium, carving of the graft tips with beveled edges, release of ULC from dorsal septum, and in situ reduction of lateral graft wings have allowed for improved nasal aesthetic outcomes since the technique was first described. Prior to implementation of the above modifications 281/349 patients (80.5%) reported their appearance as either unchanged or improved, and since the modifications to the technique 154/163 patients (94%) reported their appearance as either unchanged or improved¹² (→ Fig. 4).

Conclusion

NAO is a common presenting complaint to otolaryngology clinics, with the internal valve a commonly implicated anatomic area of obstruction. The nasal butterfly graft is a robust technique to address this subsite with good reported

functional and aesthetic outcomes in both primary and secondary rhinoplasty.

Conflict of Interest

None declared.

References

- 1 Stewart M, Ferguson B, Fromer L. Epidemiology and burden of nasal congestion. *Int J Gen Med* 2010;3:37–45
- 2 Clark DW, Del Signore AG, Raithatha R, Senior BA. Nasal airway obstruction: prevalence and anatomic contributors. *Ear Nose Throat J* 2018;97(06):173–176
- 3 Mims MM, Clark JM. The Butterfly Graft. *Rhinoplasty Archive*; 2020
- 4 Clark JM, Cook TA. The 'butterfly' graft in functional secondary rhinoplasty. *Laryngoscope* 2002;112(11):1917–1925
- 5 Brandon BM, Austin GK, Fleischman G, et al. Comparison of airflow between spreader grafts and butterfly grafts using computational flow dynamics in a cadaveric model. *JAMA Facial Plast Surg* 2018;20(03):215–221
- 6 Clark JM. Does the butterfly graft really work? *Curr Otorhinolaryngol Rep* 2022;10:369
- 7 Loyo M, Gerecci D, Mace JC, Barnes M, Liao S, Wang TD. Modifications to the butterfly graft used to treat nasal obstruction and assessment of visibility. *JAMA Facial Plast Surg* 2016;18(06):436–440
- 8 Gruber RP, Lin AY, Richards T. A predictive test and classification for valvular nasal obstruction using nasal strips. *Plast Reconstr Surg* 2010;126(01):143–145
- 9 Fung E, Hong P, Moore C, Taylor SM. The effectiveness of modified Cottle maneuver in predicting outcomes in functional rhinoplasty. *Plast Surg Int* 2014;2014:618313
- 10 Lan MY, Park JP, Jang YJ. Donor site morbidities resulting from conchal cartilage harvesting in rhinoplasty. *J Laryngol Otol* 2017;131(06):529–533
- 11 Lindsay RW. Disease-specific quality of life outcomes in functional rhinoplasty. *Laryngoscope* 2012;122(07):1480–1488
- 12 Howard BE, Madison Clark J. Evolution of the butterfly graft technique: 15-year review of 500 cases with expanding indications. *Laryngoscope* 2019;129(S1):S1–S10
- 13 Chaiet SR, Marcus BC. Nasal tip volume analysis after butterfly graft. *Ann Plast Surg* 2014;72(01):9–12