


Size Comparison of the Cadaveric Anterior Cruciate Ligament Midsubstance Cross-Sectional Area and the Cross-Sectional Area of Semitendinosus Double-Bundle Anterior Cruciate Ligament Reconstruction Autografts in Surgery

Yoshiyuki Yahagi, MD, PhD¹  Takanori Iriuchishima, MD, PhD^{2,3} Genki Iwama, MD⁴
Makoto Suruga, MD, PhD⁴ Takashi Horaguchi, MD, PhD⁴ Shin Aizawa, MD, PhD³
Kazuyoshi Nakanishi, MD, PhD¹

¹ Department of Orthopaedic Surgery, Nihon University School of Medicine, Tokyo, Japan

² Department of Orthopaedic Surgery, Kamimoku Spa Hospital, Minakami, Japan

³ Department of Functional Morphology, Nihon University School of Medicine, Tokyo, Japan

⁴ Department of Orthopaedic Surgery, Nihon University Hospital, Tokyo, Japan

Address for correspondence Yoshiyuki Yahagi, MD, PhD, Department of Orthopaedic Surgery, Nihon University School of Medicine, 30-1, Ohyaguchikami-cho, Itabashi-ku, Tokyo 173-8610, Japan (e-mail: yoshiyuki.yahagi.yokohama@gmail.com).

J Knee Surg 2023;36:1247–1252.

Abstract

The purpose of this study was to compare the cadaveric midsubstance cross-sectional anterior cruciate ligament (ACL) area and the cross-sectional semitendinosus (ST) double-bundle ACL autograft area in surgery. Thirty-nine nonpaired formalin-fixed cadaveric knees and 39 subjects undergoing ST double-bundle ACL reconstruction were included in this study. After soft tissue resection, cadaveric knees were flexed at 90 degrees, and the tangential line of the femoral posterior condyles was marked and sliced on the ACL midsubstance. The cross-sectional ACL area was measured using Image J software. In the patients undergoing ACL surgery, the harvested ST was cut and divided into anteromedial (AM) bundle and posterolateral (PL) bundle. Each graft edge diameter was measured by a sizing tube, and the cross-sectional graft area was calculated: $(AM \text{ diameter}/2)^2 \times 3.14 + (PL \text{ diameter}/2)^2 \times 3.14$. Statistical analysis was performed for the comparison of the cross-sectional area between the cadaveric ACL midsubstance and the ST double-bundle ACL autografts. The cadaveric midsubstance cross-sectional ACL area was $49.0 \pm 16.3 \text{ mm}^2$. The cross-sectional ST double-bundle autografts area was $52.8 \pm 7.6 \text{ mm}^2$. The ST double-bundle autograft area showed no significant difference when compared with the midsubstance cross-sectional ACL area. ST double-bundle autografts were shown to be capable of reproducing the midsubstance cross-sectional ACL area.

Keywords

- ▶ ACL
- ▶ ACL reconstruction
- ▶ midsubstance cross-sectional ACL area
- ▶ ST double-bundle ACL reconstruction

received

April 25, 2020

accepted after revision

June 19, 2022

article published online

August 9, 2022

© 2022, Thieme. All rights reserved.
Thieme Medical Publishers, Inc.,
333 Seventh Avenue, 18th Floor,
New York, NY 10001, USA

DOI <https://doi.org/10.1055/s-0042-1755377>
ISSN 1538-8506.

In recent decades, anatomical anterior cruciate ligament (ACL) reconstruction has become more popular.^{1–4} Many studies have reported more favorable results in anatomical ACL reconstruction when compared with nonanatomical ACL reconstruction.^{5–11} In addition, double-bundle ACL reconstruction is a better method for avoiding anterior–posterior instability and rotatory laxity compared with single-bundle ACL reconstruction.^{5,8,12–15} In most cases of ACL reconstruction using an autograft, the semitendinosus (ST) is mainly used. One of the purposes of anatomical ACL reconstruction is to reproduce native ACL anatomy.¹ However, the reconstructed ACL size is determined by the harvested autograft size, and not by the native ACL insertion site and ACL midsubstance cross-sectional size.^{9,15,16}

Few studies have addressed whether the ACL graft is capable of reproducing native ACL midsubstance morphology. Previously, Iriuchishima et al¹⁷ compared the ACL midsubstance cross-sectional area and the size of commonly used autografts using cadaveric knees. Revealing whether ACL autografts are capable of reproducing native ACL midsubstance morphology is essential, not only to reproduce native ACL anatomy, but also to prevent graft impingement in ACL reconstruction.^{5,18,19} If proper attention is not given to the reproduction of ACL native midsubstance morphology, graft impingement is likely in clinical situations.

The purpose of this study was to compare the cadaveric midsubstance cross-sectional ACL area and the cross-sectional area of ST double-bundle ACL reconstruction autografts in surgery. The hypothesis of this study was that a difference would be found between the ST double-bundle ACL autograft area and the cadaveric midsubstance cross-sectional ACL area.

Materials and Methods

Midsubstance Cross-Sectional ACL Area of Cadaveric Knees

Thirty-nine nonpaired Japanese cadaveric knees were used. The mean age of the subjects at the time of death was 79.9 ± 10.6 years (18 males and 21 females). All surrounding muscles, ligaments other than ACL, and other soft tissues around the knee were resected before ACL dissection. After soft tissue resection, knees were flexed at 90 degrees, and the tangential line of the femoral posterior condyles was marked with ink on the ACL. Then, the ACL was cut from approximately 5 mm distal to femoral insertion to 5 mm proximal to tibial insertion. The cut-out ACL was sliced at the level of the tangential line of the femoral posterior condyles with sharp razors (–Fig. 1A). The midsubstance cross-sectional ACL area was photographed, and the images were downloaded to a personal computer. The midsubstance cross-sectional ACL area was analyzed using Image J software (National Institute of Health; –Fig. 1B). Image J is public-domain open-source software for processing and analyzing scientific images. The accuracy of the area measurement of Image J software was less than 0.1 mm and 0.1 mm².

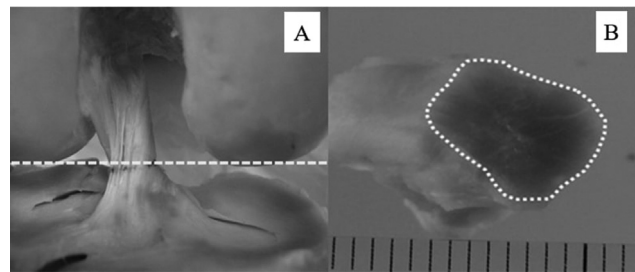


Fig. 1 (A, B) Measurement of the midsubstance cross-sectional ACL size. (A) The plane of the midsubstance cross-section ACL was sliced at the tangential plane of the femoral posterior condyles at 90° of knee flexion. (B) Midsubstance cross-sectional ACL size measurement. ACL, anterior cruciate ligament.

Cross-Sectional ST Double-Bundle Autograft Area in Surgery

Between January 2017 and September 2019, 51 nonpaired Japanese subjects underwent anatomical ACL reconstruction. The exclusion criteria were single-bundle reconstruction, ST and gracilis autograft use, and bone–tendon–bone (BTB) autograft reconstruction; 12 subjects were excluded. If the harvested ST length was under 24 mm and the two-strand ST graft diameter was under 4.5 mm, a three-strand single bundle or an additional harvest of the gracilis tendon was selected. The BTB autograft was selected mainly for revision surgery. Finally, 39 subjects with ST double-bundle ACL autografts were included (18 males and 21 females; mean age: 31.8 ± 13.0 years).

From the tibial side of the insertion site to the proximal end of the tendon, ST was harvested using a closed tendon stripper. All muscles were resected from the tendon. First, the length of the harvested ST graft was measured. After cutting the ST in half, the thicker half of the graft was regarded as the anteromedial (AM) bundle and the thinner half was regarded as the posterolateral (PL) bundle.

Harvested ST autografts were two-stranded, and an ULTRABUTTON (Smith and Nephew Inc., Andover, MA) was inserted on the femoral side. On the tibial side, the graft ends were sutured using No.3 polyester yarn (Matsuda Ika Kogyo Co., Ltd, Tokyo, Japan) with a baseball suture. After tensioning the grafts over 10 N for 10 minutes with a graft tensioner ACUFEX GRAFTMASTER (Smith and Nephew Inc, Andover, MA), both graft edge diameters were measured using a graft sizing tube (Smith and Nephew Inc, Andover, MA). After going through a graft sizing tube, the graft was circular in shape, and the cross-sectional midsubstance ST double-bundle autograft diameter (mm) was calculated as the average diameter of both edges: tibial side diameter/2 + femoral side diameter/2. The cross-sectional ST double-bundle (AM + PL) autograft area (mm²) was calculated as: (AM bundle autograft diameter/2)² × 3.14 + (PL bundle autograft diameter/2)² × 3.14.

Statistical Analysis

Data are presented as means ± standard deviations. The Mann–Whitney U-test was used to compare gender differences of the cadaveric midsubstance cross-sectional ACL

area, ST double-bundle autografts area (AM + PL), and the cadaveric midsubstance cross-sectional ACL area and the ST double-bundle autografts area (AM + PL). The statistical significance was assumed when $p < 0.05$. The coverage of the ST double-bundle (AM + PL) autograft area over the cadaveric midsubstance cross-sectional ACL area was calculated as: ST double-bundle autograft area/cadaveric midsubstance cross-sectional ACL area $\times 100$ (%).

Calculated sample size of each group was 21 (G* Power software: Priori, Wilcoxon Mann-Whitney test).

Results

Cadaveric Midsubstance Cross-Sectional ACL Area

The measured cadaveric midsubstance cross-sectional ACL area was $49.0 \pm 16.3 \text{ mm}^2$ (male: $51.8 \pm 16.8 \text{ mm}^2$, female: $48.1 \pm 16.0 \text{ mm}^2$). No significant gender difference was observed in the cadaveric midsubstance cross-sectional ACL area ($p = 0.438$).

Cross-Sectional ST Double-Bundle Autograft Diameter and Area

The midsubstance AM bundle area was $27.9 \pm 4.2 \text{ mm}^2$ (male: $30.0 \pm 4.1 \text{ mm}^2$, female: $26.1 \pm 3.5 \text{ mm}^2$). The midsubstance PL bundle autograft area was $24.9 \pm 3.8 \text{ mm}^2$ (male: $26.0 \pm 4.4 \text{ mm}^2$, female: $24.0 \pm 3.0 \text{ mm}^2$). The midsubstance ST double bundle (AM + PL) area was $52.8 \pm 7.6 \text{ mm}^2$ (male: $56.0 \pm 8.2 \text{ mm}^2$, female: $50.0 \pm 5.9 \text{ mm}^2$).

The AM and PL autograft diameters on the femur and tibia sides and the midsubstance graft diameters are shown in **Table 1**.

The cross-sectional ST double-bundle autograft area was significantly large in the male subjects when compared with that in the female subjects ($p < 0.01$).

The cross-sectional ST double-bundle autograft area showed no statistically significant difference when compared with the cadaveric midsubstance cross-sectional ACL area (in male, female, and total) (**Fig. 2**).

The coverage of the ST double-bundle autograft area over the cadaveric midsubstance cross-sectional ACL area was 107.9% (male: 108.1%, female: 104.0%).

Discussion

The most important finding of this study was that the cross-sectional ST double-bundle autograft area showed no statistically significant difference when compared with the

cadaveric midsubstance cross-sectional ACL area. No gender difference was observed in this trend. The coverage of the ST double-bundle autografts over the cadaveric midsubstance cross-sectional ACL area was approximately 108%. The results of this study show that ST double-bundle autografts are capable of reproducing native ACL midsubstance morphology.

Magnussen et al and Conte et al reported that lower 8 mm in diameter single-bundle ST grafts is associated with higher risk for failure^{20,21} (measured area of 8 mm graft = 50.2 mm^2). Magnussen et al and Conte et al reports have used single-bundle grafts, and since there are no reports of double-bundle grafts, comparisons are difficult to make, our study, the double-bundle grafts area were 52.8 mm^2 , so double-bundle grafts may be capable grafts size.

In recent ACL studies, the topics of focus have been mainly femoral and tibial ACL footprint anatomy, ACL biomechanical testing according to the reconstruction method, and graft selection.^{5,6,13,15,22-31} Many studies have reported that double-bundle reconstruction using hamstrings and rectangular BTB grafts^{1,6,7,11,15} can reproduce native ACL footprint anatomy. However, not many studies have attempted to reveal the morphological correlation between the midsubstance of the reconstructed autograft and the native midsubstance ACL. In knees with ACL tear, it is impossible for surgeons to evaluate the intact native ACL midsubstance morphology, and therefore, it is extremely difficult to obtain accurate information about the intact ACL midsubstance size. Some authors have evaluated the size of the contralateral ACL using magnetic resonance imaging; however, none of the studies evaluated the size directly. In this study, although no information was obtained about contralateral knees, the ST double-bundle ACL autograft area in surgery was compared with the midsubstance ACL area in cadaveric knees of a similar Japanese population. Considering that the cadaveric knees used for comparison were formalin-fixed knees, the calculated area of the midsubstance ACL is likely to have been underestimated when compared with nonformalin-fixed knees or ACL autografts. However, in this study, the coverage of the ST double-bundle autograft area over the cadaveric midsubstance ACL area was shown to be sufficient, at approximately 108%. Even when considering the degree of contraction present in formalin-fixed ACL specimens, the ST double-bundle cross-sectional area was seen to be capable of reproducing the native ACL midsubstance cross-sectional area.

Table 1 ST autograft diameter and size

	Femur side AM diameter (mm)	Tibia side AM diameter (mm)	AM bundle diameter (mm)	AM bundle size (mm ²)	Femur side PL diameter (mm)	Tibia side PL diameter (mm)	PL bundle diameter (mm)	PL bundle size (mm ²)	ST double-bundle (AM + PL) size (mm ²)
Mean	5.7	6.2	5.9	27.9	5.3	6.0	5.6	24.9	52.8
Male	5.9	6.4	6.2	30.0	5.3	6.1	5.7	26.0	56.0
Female	5.4	6.1	5.8	26.1	5.2	5.8	5.5	24.0	50.0

Abbreviations: AM, anteromedial; PL, posterolateral; ST, semitendinosus.

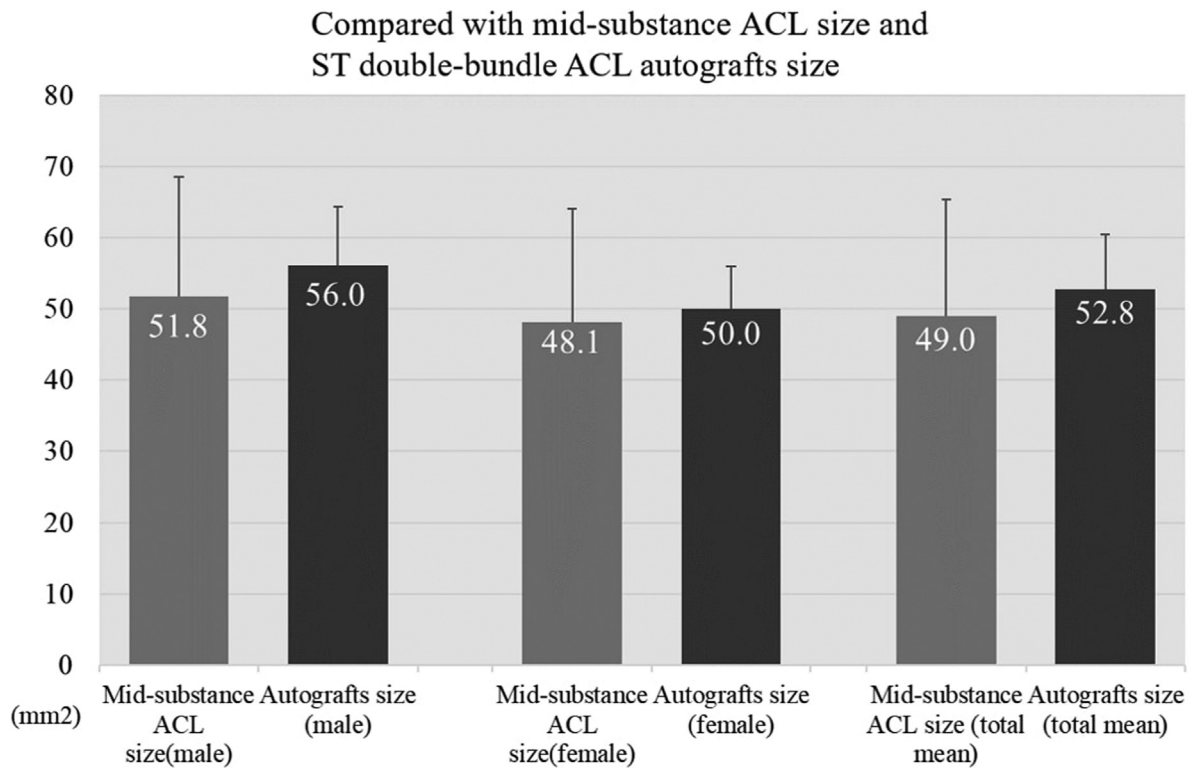


Fig. 2 Comparison of midsubstance ACL size and ST double-bundle ACL autograft size. The cross-sectional ST double-bundle autograft area showed no statistically significant difference when compared with the cadaveric midsubstance cross-sectional ACL area (in male, female, and total). ACL, anterior cruciate ligament; ST, semitendinosus.

Although this study was reported for the ST double-bundle autograft area, other contribution to graft survival by Noyes et al³² reported that structural mechanical properties of different grafts, such as bone–patellar tendon–bone, ST, gracilis, iliotibial tract, quadriceps tendon, should be evaluated.

One of the major complications of ACL reconstruction is intercondylar roof or PCL impingement.^{33–35} Marzo et al³⁶ and Toritsuka et al³⁷ reported with arthroscopic second looks that graft deterioration occurred mainly in the mid-substance portion. Natsu-ume et al³⁸ reported that partial tears of grafts were correlated with an increased side-to-side anterior laxity. Iriuchishima et al^{5,18,19} reporting on graft impingement in anatomical ACL reconstruction concluded that a correctly placed ACL graft within the native footprint does not result in roof or PCL impingement. Based on these reports, it is clear that reproducing native ACL midsubstance morphology is required to avoid ACL graft impingement. In this study, ST double-bundle autografts were shown to be capable of reproducing the native midsubstance cross-sectional ACL area.

Some authors have attempted to measure the midsubstance cross-sectional ACL area.^{6,16,17,39–42} Harner et al³⁹ measured the ACL at five different, equidistant midsubstance levels and calculated an average to determine the cross-sectional area. The ACL midsubstance area was found to be approximately 40 mm². Hashemi et al⁴⁰ measured the midsubstance cross-sectional ACL area using a three-di-

mensional camera system, and the result was 46.75 ± 12.62 mm². Muneta et al⁴² measured the ACL mid-substance area by cutting in the middle, perpendicular to its long axis, and found the area to be 41.9 mm². The results of these studies are similar to the results of the present study. As the ACL runs in the knee three-dimensionally, the plane and the part that should be used to measure the ACL midsubstance cross-sectional area need to be determined. In this study, to obtain the midsubstance cross-section with high reproducibility, the ACL was cut at the level of the tangential line of the femoral posterior condyles at 90 degrees of knee flexion.

Several authors have reported about hamstring single-bundle graft average diameters: Park et al⁴³ reported 7.2 mm (measured area = 40.7 mm²), Mariscalco et al⁴⁴ reported 7.8 mm (47.8 mm²), and Magnussen et al²⁰ reported 7.9 mm (49.0 mm²). The graft sizes in these reports were not so different compared with the double-bundle graft size. The limitations of this study were: (1) the cadaveric ACL dissection was performed by macroscopic evaluation only. This might allow for human error and bias. (2) The mean age of the cadaveric knee subjects was significantly higher than the average age of patients undergoing ACL reconstruction. (3) The study sample size was not large. (4) The graft sizing tube is in 5 mm increments, so no finer values could be given for the graft diameter. (5) This study could not include direct sampling of the contralateral normal ACL; it should be evaluated in the future studies.

Conclusion

ST double-bundle autografts were shown to be capable of reproducing the native midsubstance cross-sectional ACL area. For clinical relevance, ST double-bundle autografts are recommended for the accurate production of native ACL midsubstance morphology in ACL reconstruction.

Conflict of Interest

None declared.

References

- 1 Fu FH. Double-bundle ACL reconstruction. *Orthopedics* 2011;34(04):281–283
- 2 Fu FH, van Eck CF, Tashman S, Irrgang JJ, Moreland MS. Anatomic anterior cruciate ligament reconstruction: a changing paradigm. *Knee Surg Sports Traumatol Arthrosc* 2015;23(03):640–648
- 3 Iriuchishima T, Ingham SJ, Tajima G, et al. Evaluation of the tunnel placement in the anatomical double-bundle ACL reconstruction: a cadaver study. *Knee Surg Sports Traumatol Arthrosc* 2010;18(09):1226–1231
- 4 Tompkins M, Ma R, Hogan MV, Miller MD. What's new in sports medicine. *J Bone Joint Surg Am* 2011;93(08):789–797
- 5 Iriuchishima T, Tajima G, Ingham SJ, et al. Intercondylar roof impingement pressure after anterior cruciate ligament reconstruction in a porcine model. *Knee Surg Sports Traumatol Arthrosc* 2009;17(06):590–594
- 6 Karlsson J, Irrgang JJ, van Eck CF, Samuelsson K, Mejia HA, Fu FH. Anatomic single- and double-bundle anterior cruciate ligament reconstruction, part 2: clinical application of surgical technique. *Am J Sports Med* 2011;39(09):2016–2026
- 7 Kondo E, Yasuda K, Azuma H, Tanabe Y, Yagi T. Prospective clinical comparisons of anatomical double-bundle versus single-bundle anterior cruciate ligament reconstruction procedures in 328 consecutive patients. *Am J Sports Med* 2008;36(09):1675–1687
- 8 Kopf S, Musahl V, Tashman S, Szczodry M, Shen W, Fu FH. A systematic review of the femoral origin and tibial insertion morphology of the ACL. *Knee Surg Sports Traumatol Arthrosc* 2009;17(03):213–219
- 9 Muneta T, Koga H, Mochizuki T, et al. A prospective randomized study of 4-strand semitendinosus tendon anterior cruciate ligament reconstruction comparing single-bundle and double-bundle techniques. *Arthroscopy* 2007;23(06):618–628
- 10 van Eck CF, Schreiber VM, Mejia HA, et al. "Anatomic" anterior cruciate ligament reconstruction: a systematic review of surgical techniques and reporting of surgical data. *Arthroscopy* 2010;26(9, Suppl):S2–S12
- 11 Yasuda K, van Eck CF, Hoshino Y, Fu FH, Tashman S. Anatomic single- and double-bundle anterior cruciate ligament reconstruction, part 1: basic science. *Am J Sports Med* 2011;39(08):1789–1799
- 12 Fujita N, Kuroda R, Matsumoto T, et al. Comparison of the clinical outcome of double-bundle, anteromedial single-bundle, and posterolateral single-bundle anterior cruciate ligament reconstruction using hamstring tendon graft with minimum 2-year follow-up. *Arthroscopy* 2011;27(07):906–913
- 13 Iriuchishima T, Tajima G, Shirakura K, et al. In vitro and in vivo AM and PL tunnel positioning in anatomical double bundle anterior cruciate ligament reconstruction. *Arch Orthop Trauma Surg* 2011;131(08):1085–1090
- 14 Mascarenhas R, Cvetanovich GL, Sayegh ET, et al. Does double-bundle anterior cruciate ligament reconstruction improve post-operative knee stability compared with single-bundle techniques? A systematic review of overlapping meta-analyses. *Arthroscopy* 2015;31(06):1185–1196
- 15 Yasuda K, Kondo E, Ichiyama H, Tanabe Y, Tohyama H. Clinical evaluation of anatomic double-bundle anterior cruciate ligament reconstruction procedure using hamstring tendon grafts: comparisons among 3 different procedures. *Arthroscopy* 2006;22(03):240–251
- 16 Anderson AF, Dome DC, Gautam S, Awh MH, Rennert GW. Correlation of anthropometric measurements, strength, anterior cruciate ligament size, and intercondylar notch characteristics to sex differences in anterior cruciate ligament tear rates. *Am J Sports Med* 2001;29(01):58–66
- 17 Iriuchishima T, Yorifuji H, Aizawa S, Tajima Y, Murakami T, Fu FH. Evaluation of ACL mid-substance cross-sectional area for reconstructed autograft selection. *Knee Surg Sports Traumatol Arthrosc* 2014;22(01):207–213
- 18 Iriuchishima T, Horaguchi T, Kubomura T, Morimoto Y, Fu FH. Evaluation of the intercondylar roof impingement after anatomical double-bundle anterior cruciate ligament reconstruction using 3D-CT. *Knee Surg Sports Traumatol Arthrosc* 2011;19(04):674–679
- 19 Iriuchishima T, Tajima G, Ingham SJ, Shen W, Smolinski P, Fu FH. Impingement pressure in the anatomical and nonanatomical anterior cruciate ligament reconstruction: a cadaver study. *Am J Sports Med* 2010;38(08):1611–1617
- 20 Magnussen RA, Lawrence JT, West RL, Toth AP, Taylor DC, Garrett WE. Graft size and patient age are predictors of early revision after anterior cruciate ligament reconstruction with hamstring autograft. *Arthroscopy* 2012;28(04):526–531
- 21 Conte EJ, Hyatt AE, Gatt CJ Jr, Dhawan A. Hamstring autograft size can be predicted and is a potential risk factor for anterior cruciate ligament reconstruction failure. *Arthroscopy* 2014;30(07):882–890
- 22 Araki D, Kuroda R, Kubo S, et al. A prospective randomised study of anatomical single-bundle versus double-bundle anterior cruciate ligament reconstruction: quantitative evaluation using an electromagnetic measurement system. *Int Orthop* 2011;35(03):439–446
- 23 Bedi A, Maak T, Musahl V, et al. Effect of tunnel position and graft size in single-bundle anterior cruciate ligament reconstruction: an evaluation of time-zero knee stability. *Arthroscopy* 2011;27(11):1543–1551
- 24 Duthon VB, Barea C, Abrassart S, Fasel JH, Fritschy D, Ménétrety J. Anatomy of the anterior cruciate ligament. *Knee Surg Sports Traumatol Arthrosc* 2006;14(03):204–213
- 25 Iwama G, Iriuchishima T, Horaguchi T, Aizawa S. Measurement of the whole and midsubstance femoral insertion of the anterior cruciate ligament: the comparison with the elliptically calculated femoral anterior cruciate ligament footprint area. *Indian J Orthop* 2019;53(06):727–731
- 26 Oka S, Schuhmacher P, Brehmer A, Traut U, Kirsch J, Siebold R. Histological analysis of the tibial anterior cruciate ligament insertion. *Knee Surg Sports Traumatol Arthrosc* 2016;24(03):747–753
- 27 Suruga M, Horaguchi T, Iriuchishima T, et al. The correlation between the femoral anterior cruciate ligament footprint area and the morphology of the distal femur: three-dimensional CT evaluation in cadaveric knees. *Eur J Orthop Surg Traumatol* 2019;29(04):849–854
- 28 Takahashi M, Doi M, Abe M, Suzuki D, Nagano A. Anatomical study of the femoral and tibial insertions of the anteromedial and posterolateral bundles of human anterior cruciate ligament. *Am J Sports Med* 2006;34(05):787–792
- 29 Yagi M, Wong EK, Kanamori A, Debski RE, Fu FH, Woo SL. Biomechanical analysis of an anatomic anterior cruciate ligament reconstruction. *Am J Sports Med* 2002;30(05):660–666
- 30 Yahagi Y, Horaguchi T, Iriuchishima T, Suruga M, Iwama G, Aizawa S. Correlation between the mid-substance cross-sectional anterior cruciate ligament size and the knee osseous morphology. *Eur J Orthop Surg Traumatol* 2020;30(02):291–296

- 31 Van Zyl R, Van Schoor AN, Du Toit PJ, et al. The association between anterior cruciate ligament length and femoral epicondylar width measured on preoperative magnetic resonance imaging or radiograph. *Arthrosc Sports Med Rehabil* 2019;2(01):e23–e31
- 32 Noyes FR, Butler DL, Grood ES, Zernicke RF, Hefzy MS. Biomechanical analysis of human ligament grafts used in knee-ligament repairs and reconstructions. *J Bone Joint Surg Am* 1984;66(03):344–352
- 33 Howell SM. Principles for placing the tibial tunnel and avoiding roof impingement during reconstruction of a torn anterior cruciate ligament. *Knee Surg Sports Traumatol Arthrosc* 1998;6(Suppl 1):S49–S55
- 34 Tanksley JA, Werner BC, Conte EJ, et al. ACL roof impingement revisited: does the independent femoral drilling technique avoid roof impingement with anteriorly placed tibial tunnels? *Orthop J Sports Med* 2017;5(05):2325967117704152
- 35 van der List JP, Zuiderbaan HA, Nawabi DH, Pearle AD. Impingement following anterior cruciate ligament reconstruction: comparing the direct versus indirect femoral tunnel position. *Knee Surg Sports Traumatol Arthrosc* 2017;25(05):1617–1624
- 36 Marzo JM, Bowen MK, Warren RF, Wickiewicz TL, Altchek DW. Intraarticular fibrous nodule as a cause of loss of extension following anterior cruciate ligament reconstruction. *Arthroscopy* 1992;8(01):10–18
- 37 Toritsuka Y, Shino K, Horibe S, et al. Second-look arthroscopy of anterior cruciate ligament grafts with multistranded hamstring tendons. *Arthroscopy* 2004;20(03):287–293
- 38 Natsu-ume T, Shino K, Nakata K, Nakamura N, Toritsuka Y, Mae T. Endoscopic reconstruction of the anterior cruciate ligament with quadrupled hamstring tendons. A correlation between MRI changes and restored stability of the knee. *J Bone Joint Surg Br* 2001;83(06):834–837
- 39 Harner CD, Livesay GA, Kashiwaguchi S, Fujie H, Choi NY, Woo SL. Comparative study of the size and shape of human anterior and posterior cruciate ligaments. *J Orthop Res* 1995;13(03):429–434
- 40 Hashemi J, Chandrashekar N, Cowden C, Slauterbeck J. An alternative method of anthropometry of anterior cruciate ligament through 3-D digital image reconstruction. *J Biomech* 2005;38(03):551–555
- 41 Iriuchishima T, Shirakura K, Yorifuji H, Aizawa S, Fu FH. Size comparison of ACL footprint and reconstructed auto graft. *Knee Surg Sports Traumatol Arthrosc* 2013;21(04):797–803
- 42 Muneta T, Takakuda K, Yamamoto H. Intercondylar notch width and its relation to the configuration and cross-sectional area of the anterior cruciate ligament. A cadaveric knee study. *Am J Sports Med* 1997;25(01):69–72
- 43 Park SY, Oh H, Park S, Lee JH, Lee SH, Yoon KH. Factors predicting hamstring tendon autograft diameters and resulting failure rates after anterior cruciate ligament reconstruction. *Knee Surg Sports Traumatol Arthrosc* 2013;21(05):1111–1118
- 44 Mariscalco MW, Flanigan DC, Mitchell J, et al. The influence of hamstring autograft size on patient-reported outcomes and risk of revision after anterior cruciate ligament reconstruction: a Multicenter Orthopaedic Outcomes Network (MOON) Cohort Study. *Arthroscopy* 2013;29(12):1948–1953