



Traumatic Carotid Artery Dissection — A Case Report

Dissecção traumática de artéria carótida – Um relato de caso

Taís Otilia Berres¹ Wagner Lazaretto Padua¹ Artur Eduardo Martio¹ Yasmynni Escher¹
Luciano Bambini Manzato¹ José Ricardo Vanzin¹ Octávio Ruschel Karam¹
Paulo Moacir Mesquita Filho¹

¹Neurosurgery Department, Hospital de Clínicas de Passo Fundo, Passo Fundo, Brazil

Address for correspondence Paulo Moacir Mesquita Filho, MD, Tiradentes Street, 295, Passo Fundo, ZIP 99010-260, Brazil (e-mail: pmesquitafilho@hotmail.com).

Arq Bras Neurocir 2023;42(4):e343–e347.

Abstract

Traumatic carotid artery dissection (TCAD) usually occurs after a direct cervical trauma or blunt trauma that causes hyperextension and excessive rotation of the neck. The most frequent presentation of TCAD is stroke, with 80% of patients developing a stroke in the first week after the trauma. Recent data indicate that symptoms start later in non-survivors (19.5 hours after trauma) compared with survivors (12.5 hours). In this case report, a young boy, 14 years-old, developed TCAD after he fell from his bike. He developed ischemic stroke symptomatology in the eighth day of hospitalization, with full recovery of symptoms after acetylsalicylic acid (AAS) administration. The use of antithrombotic medication is recommended, aiming for better neurological outcomes and prevention of stroke in TCAD patients, as highlighted by our case. However, the treatment recommendations are based on observational studies and expert opinion, owing to the lack of concrete data on the treatment of carotid artery blunt trauma. New studies and data are required to improve diagnosis and treatment of TCAD.

Keywords

- ▶ traumatic carotid artery dissection
- ▶ pediatrics

Resumo

A dissecção traumática da artéria carótida (TCAD) geralmente ocorre após um trauma cervical direto ou contuso que gera hiperextensão e rotação excessiva do pescoço. A apresentação mais frequente da TCAD é o acidente vascular cerebral (AVC), com 80% dos pacientes desenvolvendo um AVC na primeira semana após o trauma. Dados recentes indicam que os sintomas começam mais tardiamente nos não sobreviventes (19,5 horas após o trauma) do que nos sobreviventes (12,5 horas). Apresentamos o caso de um jovem de 14 anos que sofreu TCAD após cair da bicicleta. Ele desenvolveu sintomatologia de AVC isquêmico no oitavo dia de internação, com recuperação completa dos sintomas após administração de ácido acetilsalicílico (AAS). O uso de medicação antitrombótica é recomendada, visando melhores resultados neurológicos e prevenção do AVC em pacientes com TCAD, como destacado em nosso caso. No entanto, as recomendações de tratamento são baseadas em estudos observacionais e opinião de especialistas, devido à falta de dados concretos sobre o tratamento do trauma contuso da artéria carótida. Novos estudos e dados são necessários para melhorar o diagnóstico e tratamento do TCAD.

Palavras-chave

- ▶ dissecção da artéria carótida interna
- ▶ pediatria

received

April 4, 2022

accepted

June 21, 2022

article published online

October 20, 2023

DOI <https://doi.org/>

10.1055/s-0042-1755453.

ISSN 0103-5355.

© 2023. Sociedade Brasileira de Neurocirurgia. All rights reserved.

This is an open access article published by Thieme under the terms of the Creative Commons Attribution-NonDerivative-NonCommercial-License, permitting copying and reproduction so long as the original work is given appropriate credit. Contents may not be used for commercial purposes, or adapted, remixed, transformed or built upon. (<https://creativecommons.org/licenses/by-nc-nd/4.0/>)

Thieme Revinter Publicações Ltda., Rua do Matoso 170, Rio de Janeiro, RJ, CEP 20270-135, Brazil

Introduction

Internal carotid artery (ICA) dissection can occur spontaneously or as a result of a traumatic event. These events are separate clinical entities, with different mechanisms and predisposing factors. Traumatic carotid artery dissection (TCAD) is usually secondary to blunt trauma that causes excessive hyperextension or rotation of the neck or a direct blow to the anterolateral aspect of the neck.¹ It is present in about 2.6% of all severe blunt trauma patients, and in 2.7% of patients with multisystemic traumatism.² Traumatic carotid artery dissection can be asymptomatic in some cases, but the majority of patients develop ischemic stroke sooner or later. Mortality can be as high as 40%.³ The onset of symptoms is highly variable, initiating immediately (in up to 10% of all cases) or only after several months.^{1,3-5} As mentioned previously, risk factors for spontaneous carotid artery dissection (SCAD) and TCAD differ, and conditions such as systemic arterial hypertension, cigarette smoking, collagen-related diseases, and other general vascular risk factors, not always contribute to the occurrence of TCAD, especially in younger patients.⁴ We describe the case of a young male patient with TCAD and delayed onset of symptoms.

Case Report

A previously healthy 14-year-old male patient came to the emergency room after falling from his bike while riding. He reported posttraumatic amnesia, which led to a computed tomography (CT) scan that revealed a small extradural hematoma (8 mm) in the right temporal pole (►Fig. 1), without any associated fractures, and a small hypodense area in the right frontal lobe, seemingly without cause. The neurosurgical team was called to evaluate this patient, and no surgery was indicated, but he was admitted for observation. Two days after hospitalization, a sequential CT scan was performed, confirming that the epidural hematoma remained stable, and the patient asymptomatic. On the 5th day of admission, the patient developed aphasia and paresis in the left arm, followed by loss of consciousness, which led

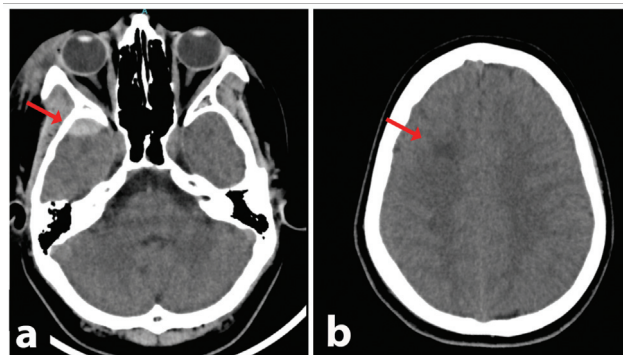


Fig. 1 Initial head computed tomography scan, performed on admission. (a) Axial plane image, showing a small (8 mm) epidural hematoma in the middle cranial fossa on the right side (red arrow). (b) Axial plane image, showing a small, nonspecific, hypodense subcortical lesion in the right frontal lobe (red arrow). Aside from the aforementioned features, no alterations could be seen.

to the presumptive diagnosis of seizure, and treatment with intravenous phenytoin (20 mg/Kg), followed by maintenance dosage. On the 8th day of hospitalization, the patient presented a new episode of aphasia, but this time with hemiparesis on the left side. A new course of phenytoin was prescribed, but without resolution of the symptoms. A magnetic resonance imaging (MRI) was performed (►Fig. 2), demonstrating an area that was hyperintense in the diffusion-weighted imaging (DWI), and hypointense in the apparent diffusion coefficient (ADC) map, suggesting an acute ischemic area, with correspondence on fluid attenuation inversion recovery (FLAIR). A complementary computed tomography angiography (angio-CT) scan was performed (►Fig. 3), demonstrating an imagiologic pattern suggestive of carotid artery dissection. The artery caliber started to reduce at the C1 segment, keeping the smaller size up to the C6 segment, with no signs of pseudoaneurysm or rupture of the vessel, with the dissection being classified as type 2 on the Denver scale. After the diagnosis was made, treatment with 100 mg of acetylsalicylic acid was immediately initiated. The patient evolved with amelioration of the symptoms after 5 days of pharmacological treatment and physical therapy, being discharged thereafter.

At the outpatient follow-up consultation 1 month after discharge, the patient referred no symptoms, with resolution of every neurological deficit. The patient remains using the same medication, and a 3-month follow-up angio-CT scan demonstrated that the dissection remained stable, with no need for further treatment indication. Clinical follow-up with the neurosurgery team is ongoing.

Discussion

About 1 to 2.6% of blunt trauma patients develop TCAD.² Dissection occurs when the artery is excessively stretched, or it may result from a direct blow to the anterolateral aspect of the neck. The stretching mechanism usually occurs during excessive hyperextension and contralateral rotation of the head and is probably associated with the direct contact of the artery with the lateral processes of the cervical vertebrae in the majority of cases, which contributes to the artery's injury. These phenomena lead to laceration of the artery's intimal layer, which can be worsened by its blood flow. The trauma mechanisms involved are diverse, going from high speed automobilistic accidents to more trivial traumas, such as falling from a bike.^{1,6-8} The main risk factors for TCAD differ from those related to SCAD, with the conventional cardiovascular risk factor being unimportant in the former, with the exception of diagnosed migraine and connective tissue disease.^{1,4}

The incidence of stroke after TCAD can be as high as 60 to 80%, depending on the population studied.^{1,3} The onset of the ischemic symptoms varies widely, from immediate onset to symptoms that take months to present. Nevertheless, it usually occurs in between the 1st hour and 7 days after the trauma.^{5,9-12} The average onset time of symptoms is also different in patients that survive from those that do not survive (12.5 vs 19.5 hours, respectively). Since immediate

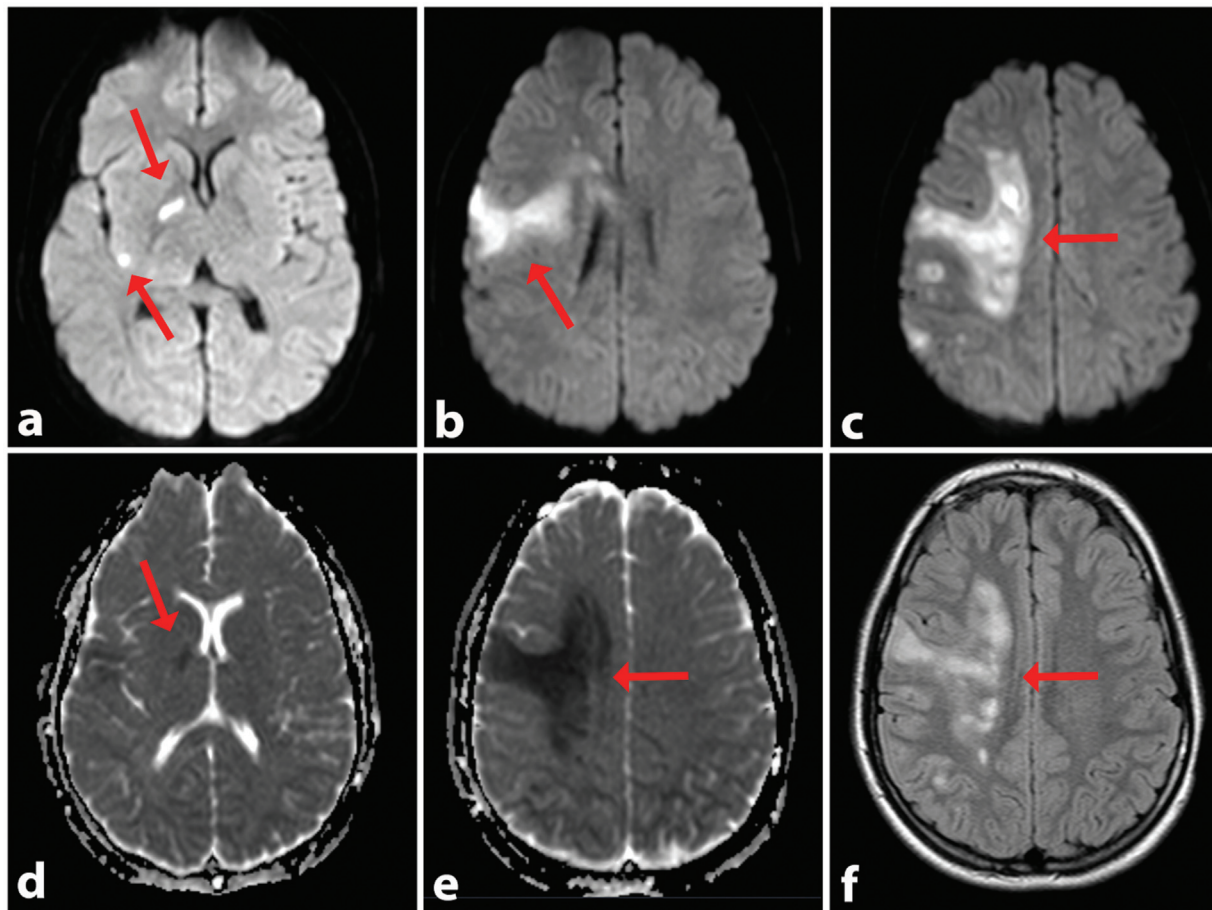


Fig. 2 Magnetic resonance imaging performed on the eighth day. All figures are on the axial plane. (a,b,c) Diffusion-weighted imaging showing hyperintense areas on the right middle cerebral artery vascular territory, suggestive of acute ischemia (red arrows). (d,e) Apparent diffusion coefficient map imaging showing hypointense signal on the middle cerebral artery vascular territory (red arrows), confirming the suspicion of acute ischemia. (f) Fluid attenuation inversion recovery sequence, evidencing perilesional edema in the ischemic territory (red arrows).

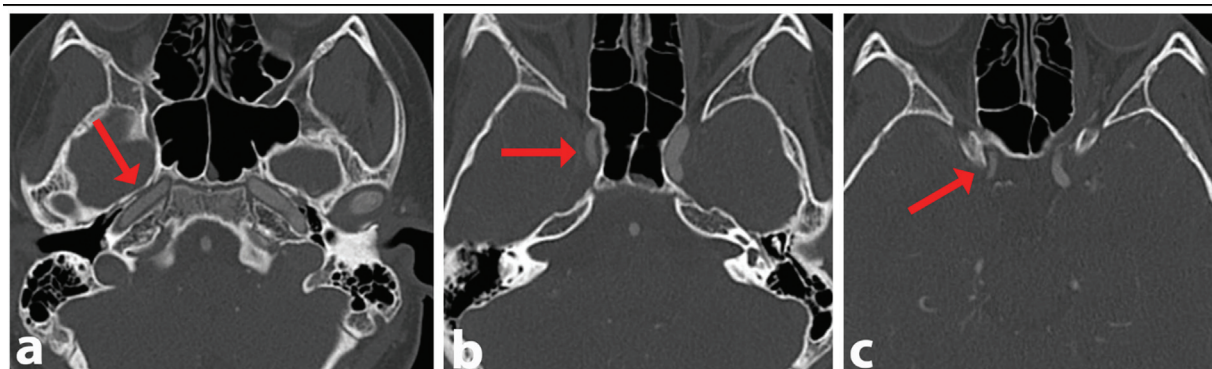


Fig. 3 Angio computed tomography scan. All figures are on the axial plane. (a) This image shows a subtle narrowing in the petrous segment of the right internal carotid artery (ICA) (red arrow). (b) Shows a more pronounced narrowing of the right ICA (red arrow). (c) Shows a narrowing in the intracranial portion of the right ICA (red arrow).

onset of symptoms occurs in only 10% of cases, serial repetition of the neurological examination is extremely important in diagnosis and clinical follow-up.¹

In severe trauma, screening for TCAD is often recommended since, although uncommon, TCAD has high morbidity and mortality rates (up to 43%). The gold standard for

TCAD diagnosis is digital subtraction angiography; however, angio CT scan is also indicated for screening, albeit with some controversy regarding its sensitivity.^{1,3} Aside from ischemic symptoms, TCAD can also present with Horner syndrome (due to a cervical hematoma mass effect) and cranial nerve palsy, but these are not as common. Additionally, the Denver

Table 1 Blunt carotid arterial injury grading scale

Injury grade	Description	AIS 90 score	
		Intracranial	Cervical
I	Luminal irregularity or dissection with < 25% luminal narrowing	3	3
II	Dissection or intramural hematoma with > 25% luminal narrowing, intraluminal thrombus, or raised intimal flap	3	3
III	Pseudoaneurysm	3	3
IV	Occlusion	4	3
V	Transection with free extravasation	5	4

^aAdd 1 point if neurologic deficit (stroke) is not head-injury related.

group described a variety of signs and symptoms associated with carotid lesions. Cervical, buccal or nasal bleeding, carotid murmur, growing cervical hematoma, focal neurological deficits and neuroimaging studies (MRI or CT scans) with ischemic findings, in the context of trauma, are highly suggestive of TCAD, and indicate the need for further investigation even in trauma cases that are not considered severe.^{1,13} In our case, no clinical signs were present initially, or they were attributed to the epidural hematoma, a fact that withheld earlier investigation for TCAD. However, the initial CT scan showed a small, nonspecific hypodense lesion on the right frontal lobe (►Fig. 1b) that was not given much attention at that moment. In retrospect, it is clear that it was an ischemic finding, highly suggestive of TCAD. This goes to show that a small inattention can lead to a delayed diagnosis of a severe disease.

The Denver group also developed a scale that quantifies the risk of stroke and death in patients with blunt carotid trauma (►Table 1). Grade-I lesions are determined as an angiographic aspect of irregularity of the wall of the vessel or dissection causing at least 25% of luminal stenosis. Grade-II lesions include those with intraluminal thrombus, elevated intimal flap, dissections, or intramural hematoma with narrowing of luminal vessel bigger than 25%. The presence of a pseudoaneurysm is classified as grade III, and vessel occlusion as grade IV. When transection of the vessel occurs, it is defined as grade V.^{6,9}

The treatment for TCAD is still a matter of debate. The majority of the studies are observational, and the recommendations are derived from these studies as well as expert's opinions. One point of convergence is that the use of antithrombotic drugs, usually acetylsalicylic acid (AAS), is superior to expectant conduct. Surgery or endovascular carotid treatment can also be performed, but its role is still not well established. Due to the severity of the disease and the possibility of progression of the dissection, some authors recommend performing a follow-up angiographic study at the end of the higher risk period for development of neurological symptoms (7th day).^{7,14}

Conclusion

Traumatic carotid artery dissection has a low incidence but is capable of resulting in serious neurological deficits

and death. Fortunately, in the present case, the delay in the TCAD diagnosis did not significantly worsen the patient's outcome, but one should remember that this was an exception. The delay happened even in the presence of a highly suggestive sign of TCAD, which goes to show that suspicion levels should always be high in trauma patients. Ours was not, and so the diagnosis was delayed for several days. After diagnosis, the treatment should be promptly initiated. There are no clear and quality evidence-based treatment indications for the diagnosis and management of TCAD patients. We would like to highlight the lack of evidence about TCAD treatment in the literature as well as the need for further research on the subject.

Conflict of Interests

The authors have no conflict of interests to declare.

References

- Galyfos G, Filis K, Sigala F, Sianou A. Traumatic Carotid Artery Dissection: A Different Entity without Specific Guidelines. *Vasc Spec Int* 2016;32(01):1–5. Doi: 10.5758/vsi.2016.32.1.1
- Seth R, Obuchowski AM, Zoarski GH. Endovascular repair of traumatic cervical internal carotid artery injuries: a safe and effective treatment option. *AJNR Am J Neuroradiol* 2013;34(06):1219–1226
- Lee TS, Ducic Y, Gordin E, Stroman D. Management of carotid artery trauma. *Craniomaxillofac Trauma Reconstr* 2014;7(03):175–189
- Thomas LC, Rivett DA, Attia JR, Levi CR. Risk factors and clinical presentation of craniocervical arterial dissection: a prospective study. *BMC Musculoskelet Disord* 2012;13:164
- Makhlouf F, Scolan V, Detante O, Barret L, Paysant F. Post-traumatic dissection of the internal carotid artery associated with ipsilateral facial nerve paralysis: diagnostic and forensic issues. *J Forensic Leg Med* 2013;20(07):867–869
- Martinakis VG, Dalainas I, Katsikas VC, Xiromeritis K. Endovascular treatment of carotid injury. *Eur Rev Med Pharmacol Sci* 2013;17(05):673–688
- Cothren CC, Moore EE, Biffi WL, et al. Anticoagulation is the gold standard therapy for blunt carotid injuries to reduce stroke rate. *Arch Surg* 2004;139(05):540–545, discussion 545–546
- Zelenock GB, Kazmers A, Whitehouse WM Jr, Graham LM, Erlandson EE, Cronenwett JL, Lindenauer SM, Stanley JC. *Arch Surg*. Abril de 1982;117(04):425–432
- Biffi WL, Moore EE, Offner PJ, Brega KE, Franciose RJ, Burch JM. Lesões arteriais carotídeas contúndentes: implicações de uma nova escala de graduação. *J Trauma* 1999;47(05):845–853

- 10 Cogbill TH, Moore EE, Meissner M, et al. O espectro da lesão contusa da artéria carótida: uma perspectiva multicêntrica. *J Trauma* 1994;(37):473-479
- 11 Biousse V, D'Anglejan-Châtillon J, Touboul PJ, Amarenco P, Boussier MG. Curso de tempo dos sintomas em dissecções da artéria carótida extracraniana. Uma série de 80 pacientes. *Golpe*. 1995; 26(02):235-239
- 12 Burlew CC, Biffi WL, Moore EE, Barnett CC, Johnson JL, Bensard DD. Lesões cerebrovasculares contundentes: redefinindo os critérios de triagem na era do diagnóstico não invasivo. *J Trauma Acute Care Surg* 2012;72(02):330-335, 336-337, 539
- 13 Miller PR, Fabian TC, Croce MA, et al. Rastreamento prospectivo para lesões cerebrovasculares contusas: análise das modalidades diagnósticas e resultados. Setembro de 2002;236(03):386-393; discussão 393-5
- 14 Biffi WL, Cothren CC, Moore EE, et al. Western Trauma Association decisões críticas em trauma: triagem e tratamento de lesões cerebrovasculares contusas. *J Trauma* 2009;67(06):1150-1153