






# Intraoperative Ultrasonography in Neurosurgery: Experience of an Institution

## *Ultrassonografia intraoperatória em neurocirurgia: Experiência de uma instituição*

Robinson Antonio Menegotto Marques<sup>1</sup>  Adriana Hernandez Marques<sup>2</sup>   
Amanda Hernandez Marques<sup>3</sup> 

<sup>1</sup> Department of Neurosurgery, Cajuru University Hospital, Curitiba, PR, Brazil

<sup>2</sup> Medical Student, School of Medicine, Federal University of Paraná (UFPR), Curitiba, Brazil

<sup>3</sup> Medical Student, School of Medicine, Pontifical Catholic University of Paraná (PUCPR), Curitiba, Brazil

Address for correspondence Robinson Antonio Menegotto Marques, MD, Department of Neurosurgery, Hospital Universitário Cajuru, Av. São José 300, Cristo Rei, Curitiba, Paraná, CEP 80050-350, Brazil (e-mail: menegottom@yahoo.com.br).

Arq Bras Neurocir 2023;42(4):e269–e276.

### Abstract

**Objective** Intraoperative ultrasound (IOUS) is an imaging method that can be used in various neurosurgical procedures. It assists in the removal of brain tumors, hematomas, in the insertion of ventricular catheters, and in spinal and peripheral nerve surgeries. The original studies using IOUS were performed with devices that produced lower-quality images, generating little interest in their use. The introduction of ultrasound devices that yielded higher-quality images associated with a relative low cost and ease of use rendered IOUS attractive. Thus, we started using it in multiple neurosurgical procedures, studying its practicality, efficacy and limitations.

**Materials and methods** A retrospective case study on the use of IOUS in neurosurgery from August 2014 to December 2020 at a single institution, evaluating its practicality, efficacy and limitations.

**Results** A total of 127 IOUS scans were performed in 112 patients aged 19 to 83 (mean: 53.8) years: 106 scans of the brain, 4 of the spinal cord, and 2 of the peripheral nerves. Brain tumors were the majority, with 86 cases (67.8%). The IOUS was unsatisfactory in 9 cases (7.1%), and there were no cases of infection related to the IOUS.

**Conclusion** The IOUS is a dynamic, safe, and practical exam. It can be performed in a few minutes and repeated several times during the surgical procedure. It enables surgeons to observe the pulsation of tissues and vessels, the displacement of lumps in liquid collections, and to monitor the drainage of cysts and collections, in vivid, interactive and real-time images.

### Keywords

- ▶ intraoperative ultrasound
- ▶ image-guided surgery
- ▶ brain tumor
- ▶ intramedullary tumor
- ▶ peripheral nerve tumor

received  
January 19, 2021  
accepted  
June 16, 2021

DOI <https://doi.org/10.1055/s-0042-1756209>.  
ISSN 0103-5355.

© 2023. Sociedade Brasileira de Neurocirurgia. All rights reserved. This is an open access article published by Thieme under the terms of the Creative Commons Attribution-NonDerivative-NonCommercial-License, permitting copying and reproduction so long as the original work is given appropriate credit. Contents may not be used for commercial purposes, or adapted, remixed, transformed or built upon. (<https://creativecommons.org/licenses/by-nc-nd/4.0/>)  
Thieme Revinter Publicações Ltda., Rua do Matoso 170, Rio de Janeiro, RJ, CEP 20270-135, Brazil

**Resumo**

**Objetivo** A ultrassonografia intraoperatória (USIO) é um método de imagem que pode ser utilizado em vários procedimentos neurocirúrgicos. Auxilia na remoção de tumores cerebrais, hematomas, no implante de cateteres ventriculares, e em cirurgias espinhais e de nervos periféricos. Os estudos iniciais com a USIO eram realizados com aparelhos que disponibilizavam imagens de baixa qualidade, o que gerava pouco interesse no seu uso. Com o desenvolvimento de aparelhos de ultrassom que produzem imagens de melhor qualidade, eram de fácil manuseio e tinham relativo baixo custo, reacendeu-se o interesse na USIO. Por este motivo, iniciamos a utilização da USIO em múltiplos procedimentos neurocirúrgicos, e estudamos sua praticidade, eficácia e limitações.

**Materiais e métodos** Estudo retrospectivo dos casos em que a USIO foi utilizada em neurocirurgia de agosto de 2014 a dezembro de 2020 em uma só instituição, com a avaliação de sua praticidade, eficácia e limitações.

**Resultados** Foram realizadas 127 USIOs em 112 pacientes com idades entre 19 e 83 (média: 53,8) anos, 106 no encéfalo, 4 em medula espinhal, e 2 em nervo periférico. Os tumores cerebrais foram a maioria, com 86 casos (67,8%). A USIO foi insatisfatória em 9 casos (7,1%), e não houve casos de infecção relacionada à USIO.

**Conclusões** A USIO é um exame dinâmico, seguro e prático. Pode ser feito em poucos minutos e repetido várias vezes durante o procedimento cirúrgico. É possível observar a pulsação dos tecidos e vasos, o deslocamento de grumos em coleções líquidas, e acompanhar a drenagem de cistos e coleções, em imagens vivas, interativas e em tempo real.

**Palavras-chave**

- ▶ ultrassom intraoperatório
- ▶ cirurgia guiada por imagem
- ▶ tumor cerebral
- ▶ tumor intramedular
- ▶ tumor de nervo periférico

**Introduction**

Intraoperative ultrasound (IOUS) is an imaging method used in neurosurgery to help locate brain tumors, guide the insertion of ventricular catheters and perform biopsies, identify anatomical structures, evaluate tissue vascularization, monitor the progress of surgery, and perform the final evaluation.<sup>1,2</sup> Initially, studies<sup>3</sup> with IOUS used devices with low image resolution that did not provide satisfactory spatial orientation. In addition, the transducers also had limitations: given that they were not intended for intracranial use, they did not fit perfectly in the surgical cavity, which generated many artifacts, reducing even further the quality of the image. Thus, many neurosurgeons lost interest in this modality of image-guided surgery. With the development of ultrasound devices that yield images with better contrast resolution, transducers that are better coupled in the surgical cavity, bringing them closer to the area of interest, reducing artifacts, the possibility of generating three-dimensional (3D) images, and the coupling to navigation systems, the interest in IOUS was rekindled.<sup>4,5</sup> Additionally, the IOUS devices are portable, easy to handle, and relatively inexpensive compared with other more expensive and laborious methods of image-guided surgery, such as intraoperative magnetic resonance imaging (MRI); thus IOUS has become a very interesting method, especially in our field. Therefore, we decided to use IOUS in various types of neurosurgical procedures and evaluate its practicality, efficacy and limitations.

**Material and Methods**

The present is a retrospective case study of the use of IOUS in neurosurgery from August 2014 to December 2020. All procedures were performed by the senior author of the present article. The ultrasound equipment used was Micro-Maxx (SonoSite Inc., Bothell, WA, United States). Two types of transducers were used: a linear 6 MHz to 13 MHz and a 1 MHz to 5 MHz for deeper lesions or insertion of an intra-ventricular catheter. For the assembly of the equipment, the transducer was wrapped in a sterile plastic cover used in video-laparoscopy filled with ultrasound gel at the end next to the transducer and fixed with rubber bands. The equipment console was also covered in transparent sterile plastic to enable its handling during surgery.

For encephalic injuries, we followed this protocol: after bone flap removal, the intact dura mater was analyzed in two planes perpendicular to each other to map the lesion, and assess its location, characteristics, and relationship with adjacent structures, followed by color Doppler to study the vascularization of the lesion and identify the vessels in the region. The opening of the dura mater was planned according to the data obtained. In cases of subcortical injuries, new evaluations were performed after the opening of the dura to plan the best approach. In cases of brain tumors, the evaluations were repeated as many times as necessary to monitor the evolution of the resection and to detect possible iatrogenic lesions. The surgical cavity was filled with saline. After the dura mater was closed, a new study was performed to

assess the resection and detect bruises. Difficulties in performing the exam and problems encountered were noted.

In cases of spinal tumors, only the 6 MHz to 13 MHz linear transducer was used. The IOUS was performed after the removal of posterior bone elements, debris, and clots, and filling the cavity with saline. The scan was performed in the sagittal and axial planes before opening the dura. The location of the lesion, its characteristics, and changes in the structure of the spinal cord were evaluated followed by the use of color Doppler to map the vessels. The dura mater was opened according to the findings. The exams were repeated to follow the evolution of the resection. At the end of the procedure, with the dura mater closed, a new scan was performed for final evaluation and detection of hematomas.

For surgeries of peripheral nerve tumors, the 6 MHz to 13 MHz linear transducer was used in perpendicular planes to locate the tumor and plan the skin incision. The IOUS was then used to guide dissection and tumoral resection as well

as to confirm complete resection and formation of hematomas at the end of surgery.

## Results

A total of 127 IOUS scans were performed on 112 patients between August 2014 and December 2020. The age of the patients ranged from 19 to 83 (mean: 53.8) years, and the sample was composed of 52 male and 60 female patients. Of the 15 patients in which more than one procedure was performed, 9 had tumor recurrence (7 cases of high-grade glioma and 2 cases of meningiomas), and 6 had multiple lesions (5 cases of metastasis and 1 of meningioma). Brain lesions were the majority, with 106 cases, followed by spinal tumors in 4, and peripheral nerve tumors in 2 cases. ►Table 1 shows a summary of the pathologies and the number of procedures.

Regarding the practicality of use, we observed that the ultrasound device takes up little space in the operating room, its assembly is quick, and it can be used both in elective and

**Table 1** Pathologies and number of intraoperative ultrasound procedures performed

		Number of cases	Number of procedures
<b>Brain</b>			
	Glioma	19	25
	Meningioma	22	25
	Metastasis - Supratentorial - Infratentorial	14 3	18 5*
	Vestibular schwannoma	6	6
	Epidermoid/dermoid cyst - Supratentorial - Infratentorial	3 1	3 1
	Hypophyseal adenoma	2	2
	Frontal invasive spinocellular carcinoma	1	1
	Cavernoma	3	3
	Rathke cleft cyst	1	1
	Intracerebral hematoma	3	3
	Ischemic stroke/biopsy	1	1
	Arteriovenous malformation	7	7
	Aneurysm	19	19
	Neurocysticercosis	1	1
<b>Spinal cord</b>			
	Astrocytoma	1	1
	Ganglioglioma	1	1
	Meningioma	1	1
	Hemangioma	1	1
<b>Peripheral nerve</b>			
	Schwannoma	2	2
<b>Total</b>		112	127

Note: \*Intraventricular catheter insertion guided by intraoperative ultrasound.

emergency surgeries. Few cases were necessary in order for us to become familiar with the operation of the device and the examination. The IOUS itself requires only a few minutes to be performed, and it can be repeated as many times as necessary without adding too much time to the surgical procedure.

Most brain injuries were brain tumors, which were all easily located, even those deep and small. We could identify cystic and necrotic areas, vessels, edema and ventricular displacements. It was particularly useful in monitoring resection and in the identification of residual tumors, especially in gliomas.

Intracerebral hematomas were also identified. In a particular case, IOUS was determinant to define the conduct in real time, as it identified a ruptured aneurysm inside an intracerebral hematoma. We had the opportunity to use IOUS in five giant aneurysms, four in the internal carotid artery (ICA) and 1 in the middle cerebral artery. The aneurysms were easily identified. Three giant ICA aneurysms were partially thrombosed, and IOUS clearly showed the aneurysmal sac wall and its relationship with adjacent structures, the intramural thrombus, and the swirling flow within the aneurysm through Doppler. After insertion of a clip, IOUS enabled the confirmation of the exclusion of the aneurysm from the circulation, which was corroborated by postoperative angiography. We used IOUS in seven surgeries to resect arteriovenous malformations (AVMs). It was useful to identify and define the AVM, and to locate drainage veins and nourishing arteries before opening the dura mater, thus avoiding unnecessary openings and accidents.

For the insertion of an intraventricular catheter, IOUS proved to be of great value because it accurately guided the ventricular puncture and the positioning of the catheter. Similarly, it was very useful to guide the resection of deep lesions aided by metal cannulas.

In spinal cord surgeries, we were able to identify the tumors in all cases and observe the sonographic characteristics of the normal spinal cord and its pathological changes. The IOUS was also useful in peripheral nerve surgeries to locate and guide tumor resection.

In the 127 procedures performed, IOUS was unsatisfactory in 9 (7,1%) cases, all of brain tumors. In three cases, IOUS was interrupted due to perforation and extravasation of gel through the plastic layer, without contaminating the surgical field. In five procedures (four cases of glioma and one case of metastasis), we did not obtain the proper coupling of the transducer in the surgical cavity, as it was not possible to completely fill the cavity with saline due to the position of the patient's head, which generated many artifacts and impaired the assessment of the progression of the resection. In one case of recurring meningioma, the evaluation was impaired due to calcification of the dura mater above the tumor, which compromised visualization. There were no infectious complications related to IOUS.

## Illustrative Cases

### Case 1

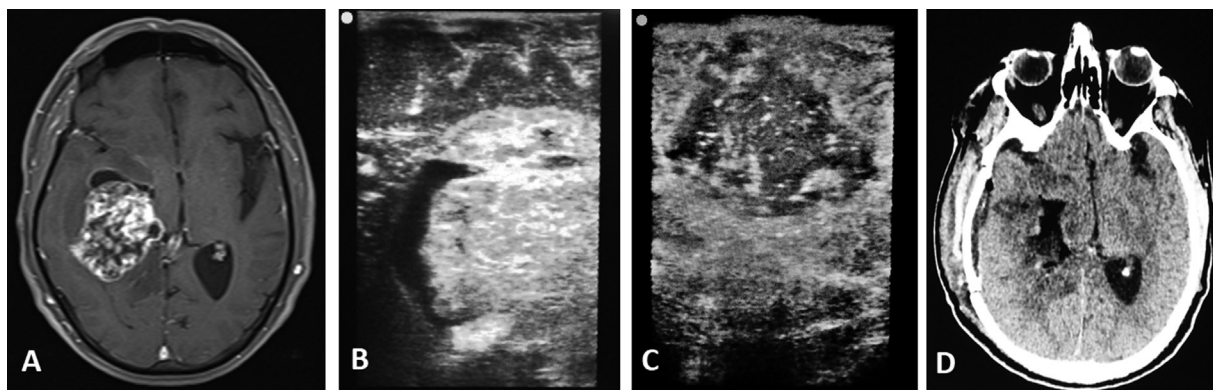
A 59-year-old male patient presented with headache, vomiting, reduced visual acuity, and left hemiparesis. An MRI scan showed a deep temporal lesion to the right. The IOUS clearly identified the lesion, its heterogeneous appearance, and the cystic area, which presented with similar aspect on the MRI, as well as the control after resection. A computed tomography (CT) scan in the immediate postoperative period confirmed gross total resection of the lesion, an anaplastic astrocytoma (► Fig. 1).

### Case 2

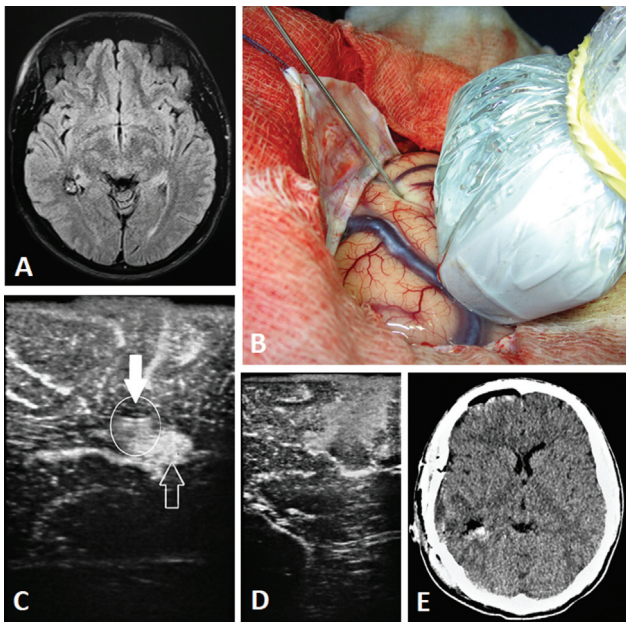
A 27-year-old male patient with a history of generalized seizures and normal neurological examination. An MRI scan showed a 12-mm lesion located adjacent to the right ventricular atrium. The IOUS located the lesion and, aided by a metal probe, shown in the image with the typical reverberation sign, guided the resection of this cavernoma and evaluated the resection control. A CT scan in the immediate postoperative period confirmed complete resection (► Fig. 2).

### Case 3

A 58-year-old female patient with a history of progressive paraparesis and dorsal back pain with 10 months of



**Fig. 1** (A) T1-weighted magnetic resonance imaging (MRI) scan with gadolinium in the preoperative period, showing a heterogeneous temporal tumor with a cystic area. (B) Intraoperative ultrasound (IOUS) scan showing the tumor with heterogeneous appearance and the cystic area, similar to the preoperative MRI. (C) The IOUS for final resection control showing gross total resection. (D) Immediate postoperative computed tomography (CT) scan confirming gross total resection.



**Fig. 2** (A) Preoperative T2-fluid-attenuated inversion recovery (FLAIR) MRI scan showing a lesion adjacent to the right ventricular atrium. (B) The IOUS guiding the metal probe to the lesion. (C) The IOUS demonstrating the reverberation caused by the metallic probe (full white arrow and circle) and the hyperechoic lesion (white hollow arrow). (D) Control IOUS showing complete resection. (E) Postoperative CT scan confirming complete resection.

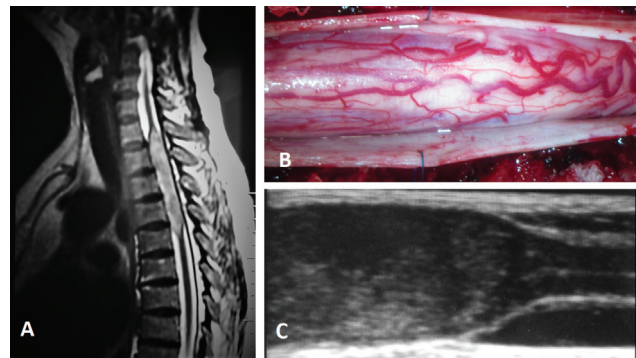
evolution. An MRI scan showed an intramedullary tumor in the cervical-thoracic transition. Surgery enabled the visualization of the spinal cord enlargement without precise limits, whereas the IOUS defined the tumor precisely, with widening of the spinal cord, with a slightly more hyperechoic appearance than the normal spinal cord. We could clearly observe the loss of normal sonographic aspects of the spinal cord in the area of the tumor, which was a ganglioglioma (► Fig. 3).

#### Case 4

A 28-year-old male patient complaining of burning pain in the lateral compartment of the right thigh associated with loss of strength and atrophy of the right thigh after 12 months of evolution, which showed, on physical examination, hypotrophy of the right quadriceps and paresis for extension of the right leg. A thigh MRI scan revealed a tumor with 2 cm in diameter on the lateral and deep compartment of the right thigh, suggestive of schwannoma. Electroneuromyography showed involvement of the right femoral nerve. The IOUS identified the tumor easily in terms of location and depth, enabling a less aggressive surgery for this case of schwannoma of the femoral nerve (► Fig. 4).

#### Case 5

A 54-year-old female patient admitted to the emergency department with a history of sudden headache followed by decreased level of consciousness and a score of 6 on the Glasgow Coma Scale (GCS). A CT scan revealed a left temporal intracerebral hematoma associated with subarachnoid and intraventricular hemorrhage. It was not possible to perform



**Fig. 3** (A) Preoperative T2-weighted MRI scan showing a cervico-thoracic intramedullary tumor. (B) Surgical image showing spinal cord enlargement without precise limits. (C) The IOUS showing the tumor, slightly hyperechoic, widening the spinal cord. It is possible to distinguish the exact point in which the medulla loses its normal sonographic aspects (the high reflectivity of the medullary surface, the hypoechogenicity of the nervous tissue, and the central echo).

CT angiography (angio-CT) or angiography. Emergency surgery was performed. The IOUS identified the entire intracerebral hematoma and diagnosed an aneurysm of the left middle cerebral artery in the middle of the hematoma before dural opening, enabling the surgeon to change the approach strategy in real time (► Fig. 5).

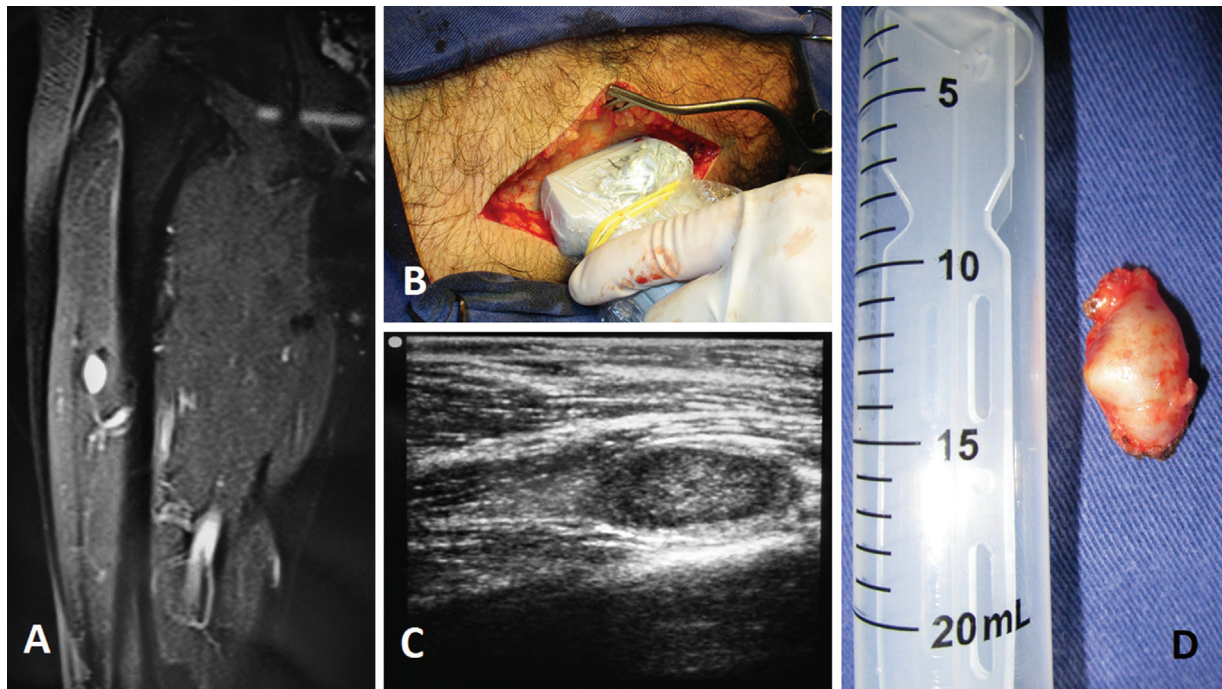
## Discussion

The IOUS is an auxiliary method of image-guided surgery capable of providing information in real time in the initial phase as well as during the surgery, compensating distortions caused by the brain shift.<sup>6</sup> Comparatively to other image-guided surgeries, IOUS is less costly, consumes less time, it is easily adaptable to the operating room, and does not expose the patient and health professionals to ionization radiation.<sup>7</sup>

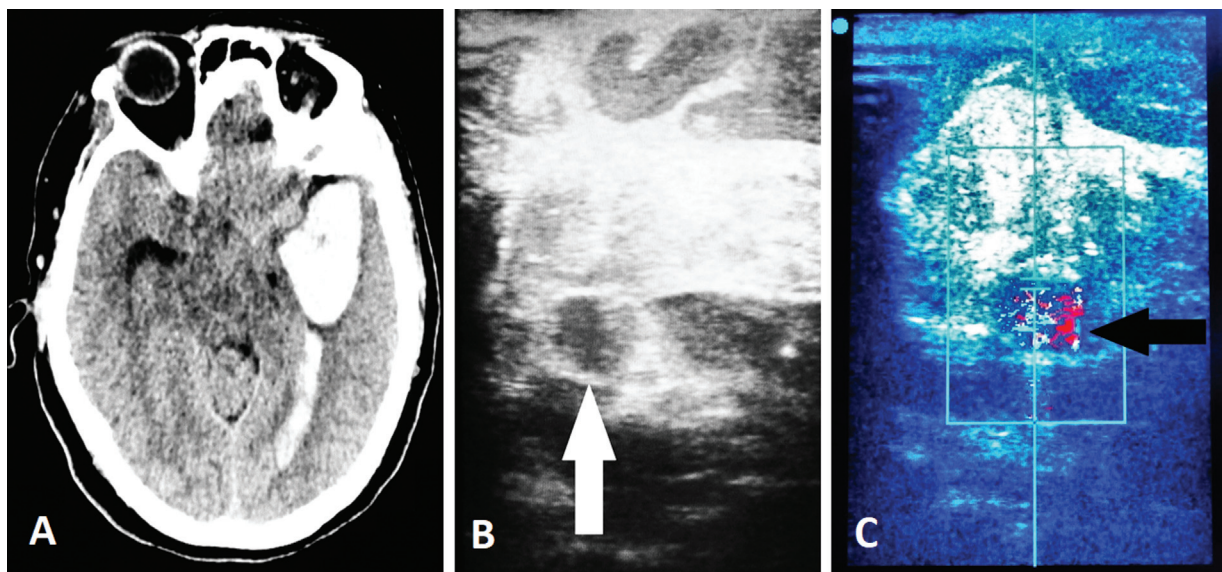
The indications for the use of IOUS range from elective procedures to emergency surgeries due to its ease of use and portability. In pediatric neurosurgery, IOUS is used in peritoneal ventricular derivation in neonates, drainage of arachnoid cysts,<sup>8</sup> and control of resection of Chiari malformation type I.<sup>9</sup> In adults, IOUS is extremely versatile, and is used to insert catheters and electrodes,<sup>10</sup> drain cysts and abscesses, and identify and remove foreign bodies.<sup>11,12,13</sup>

In intracerebral hematoma drainage surgeries, IOUS can accurately identify the location of the clot, map the vessels, identify aneurysms or associated AVMs, and evaluate the final result of the surgery. We had the opportunity of using IOUS in an emergency surgery to drain an intracerebral hematoma suspected of having a ruptured aneurysm in which it was not possible to perform angio-TC or angiography to confirm the diagnosis in the preoperative period. The IOUS easily delimited the area of the hematoma and confirmed the diagnosis of a ruptured middle cerebral artery aneurysm prior to dural opening, completely changing the approach strategy in real time.

The IOUS also assists in the insertion of intraventricular catheters, and is of crucial importance in cases associated



**Fig. 4** (A) T1-weighted MRI scan with gadolinium showing a tumor in the depth of the right thigh. (B) A photograph of the IOUS guiding the surgery. (C) The IOUS demonstrating the tumor. (D) A photograph of the surgical specimen.



**Fig. 5** (A) Preoperative CT scan showing left temporal intracerebral hematoma associated with subarachnoid hemorrhage and intraventricular hemorrhage suggesting aneurysmal rupture. (B) The IOUS showing the hyperechoic intracerebral hematoma associated with a circular image with a hyperechoic wall and hypoechoic content suggestive of aneurysm (white arrow). (C) The IOUS with color Doppler showing swirling flow inside the circular lesion, confirming the diagnosis of aneurysm (black arrow).

with compression and deviation of the ventricles. Wilson et al.<sup>14</sup> studied 249 cases of ventriculoperitoneal shunt and compared the accuracy of the insertion of the intraventricular catheter using IOUS, stereotaxic navigation, and the free hand, and concluded that there was greater precision in the insertion and reduction of the proximal obstruction of the catheter when guided by ultrasound and stereotaxic navigation.

In biopsies or surgeries involving small and deep lesions, IOUS is very useful because it enables surgeons to easily

visualize and insert metal probes and silicone catheters into the chosen target with great precision.<sup>15</sup> Di Lorenzo et al.<sup>16</sup> compared biopsies guided by IOUS and stereotactic biopsies guided by CT and concluded that, for supratentorial lesions greater than 15 mm, the accuracy of the methods are similar, with IOUS having the advantages of being faster, simpler, and having a lower cost.

In brain tumor surgeries, IOUS is applied to map the lesion, and identify its limits, cystic and necrotic areas, and the relationship of the tumor with adjacent anatomical

structures such as vessels, ventricles and bony prominences, providing real-time information to assist in the surgeon's decision regarding the best approach strategy and minimize surgical aggression. It enables the evolutionary monitoring of the resection and the identification of residual lesions, maximizing the removal of the tumor.<sup>17,18</sup> In our experience, IOUS was able to identify all brain tumors studied, including low-grade gliomas, and clearly determine their limits, their relationships with large vessels, their cystic or necrotic portions, the associated hematomas, and the areas of edema when present.

In surgeries for spinal tumors, IOUS is a tool of great help to the surgeon because it enables the visualization of intraspinal abnormalities and monitoring of the progress of the resection and the result of the surgery. Quencer and Montalvo,<sup>19</sup> studying the sonographic characteristics of the spinal cord, observed regularity in three characteristics of the normal spinal cord: the high reflectivity of the medullary surface; the hypoechogenicity of the nervous tissue; and the central echo. In their experience,<sup>19</sup> the absence of these sonographic characteristics indicates the presence of neoplastic pathological processes affecting the spinal cord. Epstein et al.<sup>20</sup> analyzed 186 intramedullary tumors and observed that astrocytomas expand the spinal cord asymmetrically and are slightly more echogenic than normal tissue. Ependymomas expand the medulla symmetrically and are located in the central region. They are hyperechogenic, uniform, and with well-defined limits. Epstein et al.<sup>20</sup> easily identified rostrocaudal cysts: in 4 cases of spinal cord demyelinating disease, they observed sonographic characteristics different from those found in spinal tumors, such as minimal spinal cord expansion or normal spinal thickness, hypoechogenicity without associated hyperechogenicity, and visualization of the central canal. The central canal was not observed in any of the 182 cases of intramedullary tumors, confirming the findings by Quencer and Montalvo.<sup>19</sup> Therefore, IOUS, in addition to aiding in the location of the lesion, the characterization of the tumor, the identification of the cystic areas, and the monitoring of the tumor resection, may suggest its nature according to its sonographic characteristics, whether neoplastic or demyelinating disease, thus avoiding unnecessary resections. To increase the accuracy of IOUS in spinal tumor surgeries, studies<sup>21</sup> with 3D ultrasound coupled to navigation systems have been conducted, and they show encouraging results.

The IOUS is also beneficial for peripheral nerve tumor surgeries and resections of neuromas, especially those of small dimensions, located in deep regions; IOUS helps the surgeon perform procedures that are more precise and less traumatic to the patient.<sup>22</sup>

Critics<sup>23,24,25</sup> point out that IOUS yields poor image quality due to poor spatial and contrast resolution compared with other auxiliary modalities of image-guided surgery, such as intraoperative MRI and intraoperative CT. They also report that the quality of the IOUS image suffers a gradual deterioration during the surgical procedure due to the production of artifacts caused by blood, air, instruments, and poorly-coupled transducers in the surgical cavity. After

the resection starts, the formed cavity introduces significant changes in the sound-attenuation factor. There is a need to fill with saline solution, which has a sound attenuation close to zero. The difference in attenuation of the saline solution with the brain tissue causes an artifact perceived as a shiny, hyperechoic area, which can be misinterpreted as a tumor remnant. The artifact can be observed in the images as an area of increased brightness below the bottom of the cavity filled with saline. This is the most common artifact found on IOUS in brain tumor surgeries.<sup>26</sup>

Nowadays, there are commercial ultrasound devices that provide high-quality images, which are equipped with transducers of various sizes and frequencies that can be introduced into the surgical cavity, bringing the transducer closer to the area of interest and reducing the formation of artifacts. They generate two-dimensional (2D) images and 3D reconstructions, and enable the fusion of images with magnetic resonance and coupling to neuronavigation systems.<sup>4,5,6,21,27,28</sup> To minimize the artifacts generated by surgical manipulation, researchers are studying the use of liquids with impedance similar to that of brain tissue to fill the surgical cavity to reduce the reverberations and noise caused by the change in sound transmissibility and maintain the image quality during the evolution of the procedure.<sup>26</sup> For the monitoring of the resection and identification of the tumor remains, optimizing resection, notably in high-grade gliomas, ultrasound contrast may be used.<sup>29,30</sup> Prada et al.<sup>31</sup> demonstrated that the use of contrast is extremely specific in the identification of residual tumors. The ability to distinguish the tumor, the artifacts and a normal brain is based on the ability to show the degree of vascularity and not the echogenicity of the tissues.

## Conclusion

The IOUS is a dynamic, safe and practical examination that, despite showing a 2D image on screen, when scanning the studied area, enables a very accurate 3D perception of the location and dimensions of the lesion addressed and the anatomy of the region. Additionally, it can be performed in a few minutes and repeated several times during the surgical procedure. It enables the observation of the pulsation of tissues and vessels, the displacement of lumps in liquid collections, and the monitoring of the drainage of cysts and collections, in vivid, interactive and real-time images.

### Conflict of Interests

The authors have no conflict of interests to declare.

## References

- Gooding GAW, Boggan JE, Powers SK, Martin NA, Weinstein PR. Neurosurgical sonography: intraoperative and postoperative imaging of the brain. *AJNR Am J Neuroradiol* 1984;5(05):521–525
- Mittelstaedt CA, Staab EV, Drobnes WE, Daniel EB. The intraoperative uses of real-time ultrasound. *Radiographics* 1984;4(02):267–282
- Chandler WF, Knake JE, McGillicuddy JE, Lillehei KO, Silver TM. Intraoperative use of real-time ultrasonography in neurosurgery. *J Neurosurg* 1982;57(02):157–163

- 4 Gronningsaeter A, Kleven A, Ommedal S, et al. SonoWand, an ultrasound-based neuronavigation system. *Neurosurgery* 2000; 47(06):1373–1379, discussion 1379–1380
- 5 Moiyadi AV, Shetty P. Direct navigated 3D ultrasound for resection of brain tumors: a useful tool for intraoperative image guidance. *Neurosurg Focus* 2016;40(03):E5
- 6 Tronnier VM, Bonsanto MM, Staubert A, Knauth M, Kunze S, Wirtz CR. Comparison of intraoperative MR imaging and 3D-navigated ultrasonography in the detection and resection control of lesions. *Neurosurg Focus* 2001;10(02):E3
- 7 Knake JE, Chandler WF, McGillicuddy JE, Silver TM, Gabrielsen TO. Intraoperative sonography for brain tumor localization and ventricular shunt placement. *AJR Am J Roentgenol* 1982;139(04):733–738
- 8 Shkolnik A, Atlas S, McLone DG. Intraoperative neurosonography in pediatrics. *Radiographics* 1984;4(06):945–962
- 9 Yeh DD, Koch B, Crone KR. Intraoperative ultrasonography used to determine the extent of surgery necessary during posterior fossa decompression in children with Chiari malformation type I. *J Neurosurg* 2006;105(1, Suppl)26–32
- 10 Altman NR, Duchowny MS, Jayakar P, Resnick TJ, Alvarez LA, Morrison G. Placement of intracerebral depth electrodes during excisional surgery for epilepsy: value of intraoperative ultrasound. *AJNR Am J Neuroradiol* 1992;13(01):254–256
- 11 Rogers JV III, Shuman WP, Hirsch JH, Lange SC, Howe JF, Burchiel K. Intraoperative neurosonography: application and technique. *AJNR Am J Neuroradiol* 1984;5(06):755–760
- 12 Knake JE, Chandler WF, Gabrielsen TO, Latack JT, Gebarski SS. Intraoperative sonography in the nonstereotaxic biopsy and aspiration of subcortical brain lesions. *AJNR Am J Neuroradiol* 1983;4(03):672–674
- 13 Quencer RM, Montalvo BM. Time requirements for intraoperative neurosonography. *AJNR Am J Neuroradiol* 1977;7:155–158
- 14 Wilson TJ, Stetler WR Jr, Al-Holou WN, Sullivan SE. Comparison of the accuracy of ventricular catheter placement using freehand placement, ultrasonic guidance, and stereotactic neuronavigation. *J Neurosurg* 2013;119(01):66–70
- 15 Enzmann DR, Irwin KM, Marshall WH, Silverberg GD, Britt RH, Hanbery JW. Intraoperative sonography through a burr hole: guide for brain biopsy. *AJNR Am J Neuroradiol* 1984;5(03):243–246
- 16 Di Lorenzo N, Esposito V, Lunardi P, Delfini R, Fortuna A, Cantore G. A comparison of computerized tomography-guided stereotactic and ultrasound-guided techniques for brain biopsy. *J Neurosurg* 1991;75(05):763–765
- 17 Gooding GAW, Boggan JE, Weinstein PR. Characterization of intracranial neoplasms by CT and intraoperative sonography. *AJNR Am J Neuroradiol* 1984;5(05):517–520
- 18 LeRoux PD, Berger MS, Ojemann GA, Wang K, Mack LA. Correlation of intraoperative ultrasound tumor volumes and margins with preoperative computerized tomography scans. An intraoperative method to enhance tumor resection. *J Neurosurg* 1989;71(5 Pt 1):691–698
- 19 Quencer RM, Montalvo BM. Normal intraoperative spinal sonography. *AJR Am J Roentgenol* 1984;143(06):1301–1305
- 20 Epstein FJ, Farmer JP, Schneider SJ. Intraoperative ultrasonography: an important surgical adjunct for intramedullary tumors. *J Neurosurg* 1991;74(05):729–733
- 21 Kolstad F, Rygh OM, Selbekk T, Unsgaard G, Nygaard OP. Three-dimensional ultrasonography navigation in spinal cord tumor surgery. Technical note. *J Neurosurg Spine* 2006;5(03):264–270
- 22 Lee FC, Singh H, Nazarian LN, Ratliff JK. High-resolution ultrasonography in the diagnosis and intraoperative management of peripheral nerve lesions. *J Neurosurg* 2011;114(01):206–211
- 23 Zhuang DX, Liu YX, Wu JS, et al. A sparse intraoperative data-driven biomechanical model to compensate for brain shift during neuronavigation. *AJNR Am J Neuroradiol* 2011;32(02):395–402
- 24 Selbekk T, Solheim O, Unsgård G. Ultrasound-guided neurosurgery: experiences from 20 years of cross-disciplinary research in Trondheim, Norway. *Neurosurg Focus* 2016;40(03):E2
- 25 Ashraf M, Choudhary N, Hussain SS, Kamboh UA, Ashraf N. Role of intraoperative computed tomography scanner in modern neurosurgery - An early experience. *Surg Neurol Int* 2020;11(247):1–8
- 26 Selbekk T, Jakola AS, Solheim O, et al. Ultrasound imaging in neurosurgery: approaches to minimize surgically induced image artefacts for improved resection control. *Acta Neurochir (Wien)* 2013;155(06):973–980
- 27 Nossek E, Korn A, Shahar T, et al. Intraoperative mapping and monitoring of the corticospinal tracts with neurophysiological assessment and 3-dimensional ultrasonography-based navigation. Clinical article. *J Neurosurg* 2011;114(03):738–746
- 28 Nikas DC, Hartov A, Lunn K, Rick K, Paulsen K, Roberts DW. Coregistered intraoperative ultrasonography in resection of malignant glioma. *Neurosurg Focus* 2003;14(02):e6
- 29 Nolte I, Vince GH, Maurer M, et al. Iron particles enhance visualization of experimental gliomas with high-resolution sonography. *AJNR Am J Neuroradiol* 2005;26(06):1469–1474
- 30 Lekht I, Brauner N, Bakhsheshian J, et al. Versatile utilization of real-time intraoperative contrast-enhanced ultrasound in cranial neurosurgery: technical note and retrospective case series. *Neurosurg Focus* 2016;40(03):E6
- 31 Prada F, Bene MD, Fornaro R, et al. Identification of residual tumor with intraoperative contrast-enhanced ultrasound during glioblastoma resection. *Neurosurg Focus* 2016;40(03):E7