



# Bilateral Cerebral Venous Thrombosis with a Rare Presentation in a COVID-19 Patient: A Case Report

## *Trombose venosa cerebral bilateral com apresentação rara em paciente com COVID-19: Relato de caso*

Iman Ahrari<sup>1</sup> Arash Saffarian<sup>1</sup> Abbas Rakhsha<sup>1</sup> Mahsa Ghavipisheh<sup>2</sup> Mohamad Reza Gholami<sup>3</sup>

<sup>1</sup>Department of Neurosurgery, Medical School, Shiraz University of Medical Sciences, Shiraz, Iran

<sup>2</sup>Department of Psychiatry, Medical School, Shiraz University of Medical Sciences, Shiraz, Iran

<sup>3</sup>Department of Ophthalmology, Medical School, Shiraz University of Medical Sciences, Shiraz, Iran

Address for correspondence Iman Ahrari, Department of Neurosurgery, Shiraz University of Medical Sciences, Shiraz, Iran (e-mail: Imanahrari@gmail.com).

Arq Bras Neurocir 2023;42(4):e354–e357.

### Abstract

Since the COVID-19 pandemic started, millions of peoples are involved. The presentation of the disease varies from mild respiratory symptoms and multiple organ failure to coma and death. Neurological symptoms such as headache or seizure are also coincident with COVID-19. Thromboembolic events increase in COVID-19 patients due to hypercoagulability and inflammation, particularly in severely ill patients. Thrombosis may cause venous thrombosis, pulmonary embolism, or cerebral sinus venous thrombosis (CSVT). Cerebral sinus venous thrombosis is a rare phenomenon that is usually found in critically ill patients with bad prognoses. In the present case report, we present a 40-year-old man with COVID-19 confirmed by real-time polymerase chain reaction (RT-PCR) who was admitted due to acute bilateral visual loss due to bilateral transverse sinus thrombosis. Pseudotumor cerebri disease was confirmed through high lumbar puncture. Early surgical intervention (optic nerve fenestration) was performed and, fortunately, his visual acuity improved. Cerebral sinus venous thrombosis is a rare incident in COVID-19 patients, but due to irreversible complications, an early diagnosis is fundamental. In any neurologic change in COVID-19 patients, CSVT must be considered. Also, prophylactic thrombolytic therapy should be kept in mind as the patient is admitted.

### Keywords

- ▶ SARS-COV-19
- ▶ CSVT
- ▶ thrombosis
- ▶ pseudotumor cerebri
- ▶ venous thrombotic event
- ▶ visual loss

received  
February 7, 2022  
accepted  
July 12, 2022  
article published online  
October 18, 2023

DOI <https://doi.org/10.1055/s-0042-1756458>.  
ISSN 0103-5355.

© 2023. Sociedade Brasileira de Neurocirurgia. All rights reserved. This is an open access article published by Thieme under the terms of the Creative Commons Attribution-NonDerivative-NonCommercial-License, permitting copying and reproduction so long as the original work is given appropriate credit. Contents may not be used for commercial purposes, or adapted, remixed, transformed or built upon. (<https://creativecommons.org/licenses/by-nc-nd/4.0/>)  
Thieme Revinter Publicações Ltda., Rua do Matoso 170, Rio de Janeiro, RJ, CEP 20270-135, Brazil

## Resumo

Desde o início da pandemia da COVID-19, milhões de pessoas estão envolvidas. A apresentação da doença varia desde sintomas respiratórios leves e falência de múltiplos órgãos até coma e morte. Sintomas neurológicos, como dor de cabeça ou convulsão, também coincidem com COVID-19. Os eventos tromboembólicos aumentam em pacientes com COVID-19 devido à hipercoagulabilidade e inflamação, particularmente em pacientes gravemente enfermos. A trombose pode causar trombose venosa, embolia pulmonar ou trombose venosa do seio cerebral (TVC). A trombose venosa do seio cerebral é um fenômeno raro, geralmente encontrado em pacientes gravemente enfermos e com mau prognóstico. No presente relato de caso, apresentamos um homem de 40 anos com COVID-19 confirmado por reação em cadeia da polimerase em tempo real (RT-PCR) que foi internado devido a perda visual bilateral aguda causada pela trombose bilateral do seio transverso. A doença pseudotumor cerebral foi confirmada através de punção lombar alta. Foi realizada intervenção cirúrgica precoce (fenestração do nervo óptico) e, felizmente, sua acuidade visual melhorou. A trombose venosa do seio cerebral é um incidente raro em pacientes com COVID-19, mas devido a complicações irreversíveis, um diagnóstico precoce é fundamental. Em qualquer alteração neurológica em pacientes com COVID-19, a TVCS deve ser considerada. Além disso, a terapia trombolítica profilática deve ser lembrada quando o paciente é internado.

## Palavras-chave

- ▶ SARS-COV-19
- ▶ CSVT
- ▶ trombose
- ▶ pseudotumor cerebral
- ▶ evento trombótico venoso
- ▶ perda visual

## Introduction

Since 2019, when COVID-19 spread around the world, ~ 250 million people were infected and ~ 5 million died. The disease causes multiple organ morbidity. The most common symptom of the disease is pulmonary involvement and pneumonia, which are fully studied. COVID-19 mostly presents with respiratory tract involvement such as cough and dyspnea accompanied by fever. The disease may also cause neurological manifestations such as decreased level of consciousness and myopathy.<sup>1,2</sup>

Some studies also reported involvement of the central nervous system (CNS).<sup>3,4</sup> The most common symptoms of CNS involvement consist of headache, decreased level of consciousness, seizure, and smelling impairment.<sup>3</sup> COVID-19 has been shown to cause coagulation impermanent, which can lead to cerebrovascular manifestations. Critically ill patients were reported as having developed ischemic and hemorrhagic stroke, which can burden the severity of the disease. The possible cause could be the hypercoagulation state due to the cytokine storm produced by COVID-19.<sup>4</sup>

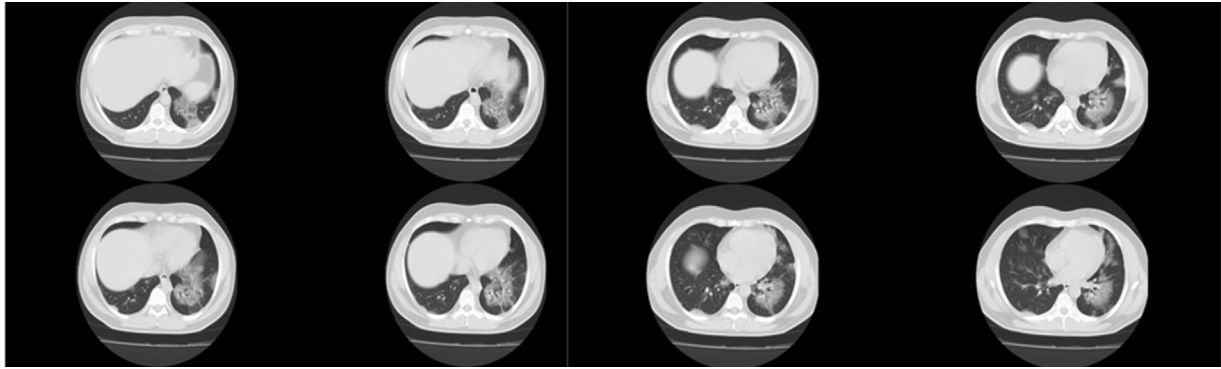
Venous thrombosis may occur anywhere in veins. The venous system of the brain may also be involved, resulting in cerebral sinus venous thrombosis (CSVT). The early diagnosis in COVID-19 patients is important considering that these patients are sedated intentionally to have a better pulmonary function.

The occurrence of CSVT as a complication of COVID-19 is rare, but some cases have been previously reported. Most of the cases presented with thrombosis in the sagittal sinus or unilateral sinus occlusion. In present study, a rare case of bilateral transverse sinus thrombosis in a COVID-19 patient

is presented. The patient presented with bilateral visual loss due to bilateral occlusion of the transverse sinus as a complication of CSVT. The SARS-COV-19 virus activates many inflammatory factors that start a thrombosis cascade, such as angiotensin converting enzyme 2 (ACE2) and D-dimer.<sup>5,6</sup>

## Case Presentation

A 40-year-old man was referred to our center due to blurred vision for 2 days before admission and a history of fever, malaise, and dry cough for 1 week before admission. The patient was admitted due to respiratory involvement in a COVID-19 hospital center. He had only a history of HTN, which was controlled with medication. At the time of admission, his vital signs were within the normal limits. The results of the laboratory tests performed upon admission were: blood glucose 250 mg/dL, white blood cell count 10, neutrophil lymphocyte ratio (NLR) 33, erythrocyte sedimentation rate (ESR) 93 mm/h, C-reactive protein (CRP) 6 mg/dL. The results showed hyperglycemia, leukocytosis, and increased NLR. The ESR showed a considerable increase, whereas CRP was slightly increased. Also, D-dimer, as an inflammatory factor, was increased. All laboratory data confirmed the inflammatory process which is consistent with COVID-19 infection. The patient underwent RT-PCR for diagnosis of the disease, whose positive result indicated the involvement of the SARS-COV-19 virus. Prophylactic treatment with enoxaparin for deep vein thrombosis (DVT) was administered subcutaneously during the course of the COVID-19 treatment. A thorax computed tomography (CT) showed bilateral patchy ground glass opacities throughout



**Fig. 1** Base line axial thorax computed tomography showing multiple bilateral ground-glass patchy opacities and subpleural effusion in both lungs, particularly in the upper lobe, with a fibrotic appearance in the left lung.

both lungs (►Fig. 1). The patient developed with sudden blurred vision and decrease in visual acuity of both eyes 1 week after admission due to the COVID-19 infection. When the patient was admitted to our center, his visual acuity was: No light perception (NLP) in the right eye and finger count (FC) in the left eye.

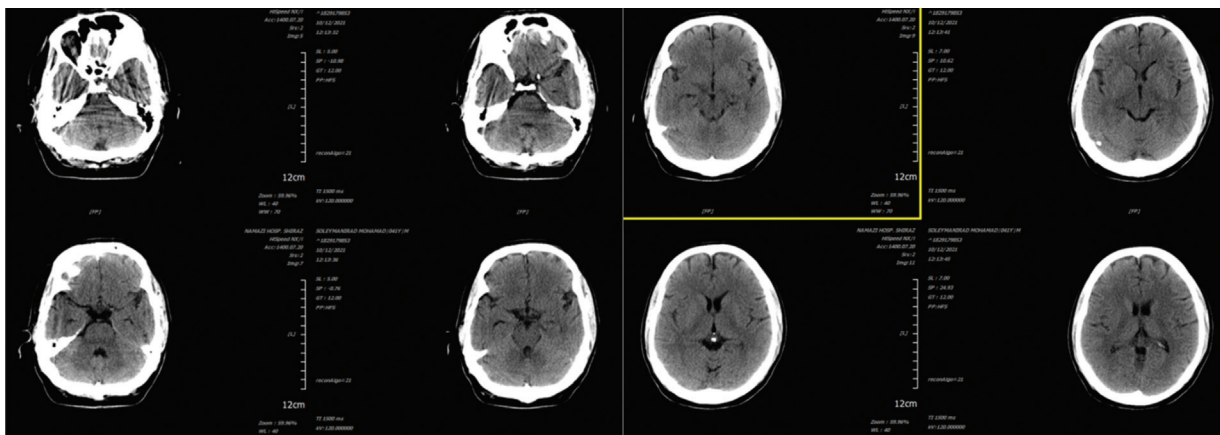
A noncontrast brain CT scan did not show any specific findings that could explain the decreased vision. There were no significant hyperdensities in the brain CT, but the patient had bilateral pupillary edema in the clinical examination, which, in concurrence with the presence of brain edema, was suggestive of pseudotumor cerebri (PTC) (►Fig. 2). A lumbar puncture (LP) was performed in the patient with an opening pressure of 40 cm h<sub>2</sub>O, confirming PTC. The patient underwent an ophthalmologic consultation that showed papillary edema grade 5 with no other problems. The visual field test showed bilateral visual loss. Magnetic resonance venography (MRV) was performed and showed bilateral transverse sinus (TS) thrombosis, which confirmed CSVT (►Fig. 3). The cerebrospinal fluid (CSF) analysis was normal and did not show anything indicative of encephalitis. Due to the high intracranial pressure (ICP) and to the sudden decrease in visual acuity, the patient underwent an emergency operation for optic fenestration. A serial LP was performed, showing decreased CSF pressure. Medications, including enoxaparin,

were continued until the patient was discharged 2 weeks after admission, when the respiratory clinical manifestations were improved, and VA were: 20/400 and 20/200.

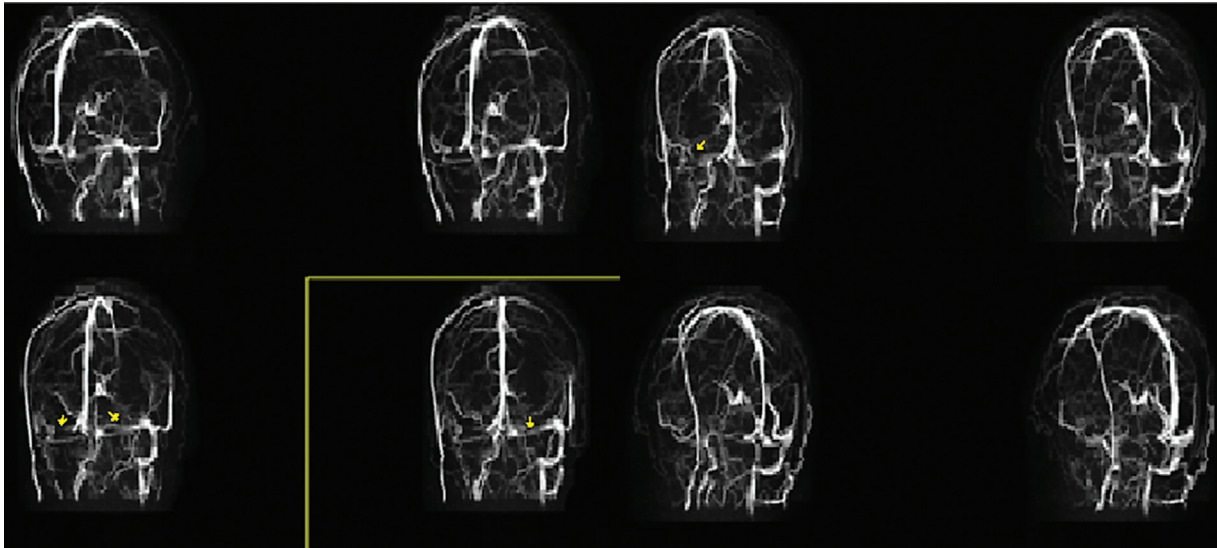
## Discussion

The neurological manifestations of COVID-19 vary from headache to encephalopathy with decreased level of consciousness and coma.<sup>3</sup> The SARS-COV-19 virus can involve the neurological system directly or affect the CNS through a severe inflammatory response which is started by systemic infection.<sup>7</sup> Cerebral sinus venous thrombosis is a rare phenomenon with an incidence rate of ~ 0.5 to 1% of all strokes. The patients usually develop with neurological deficits such as motor deficit or decreased level of consciousness. The diagnosis is usually made by brain MRV or CTV. Computed tomography scans show wedge-shaped hypodensities in the involved areas, which explains the venous cause of thrombosis. The presentation of clinical symptoms depends on the site of thrombosis and occur due to brain edema and infarction. The severity of the disease depends on predisposing factors such as age, gender, and medical condition.<sup>8,9</sup>

COVID-19 has been shown to induce hypercoagulation statue by starting an inflammatory cascade that results in the



**Fig. 2** Axial noncontrast brain computed tomography showing obliteration of the basal cisterna and narrowed sulcal spaces, which is suggestive of brain edema and in favor of PTC.



**Fig. 3** Bilateral filling defect of both transverse sinuses (TS) are shown in magnetic resonance venography (MRV) that confirmed the diagnosis of cerebral sinus venous thrombosis. The hypodensities in the transverse sinuses are made by clot formation in the vein lumen. Due to acute occlusion, few collateral veins could be found. Also, partial filling defects in the right sigmoid and jugular veins were noted.

release of many cytokines, such as interleukin-1 $\beta$  (IL-1 $\beta$ ), interleukin-6 (IL-6), interleukin-12 (IL-12), and interferon- $\gamma$  (IFN- $\gamma$ ), which are associated with inflammation in pulmonary tissue and fibrosis. As shown in previous reports, the CRP, D-dimer and other inflammatory cytokine levels are high. Thrombosis may happen in the venous system everywhere in the body consisting brain venous system. The most common site of thrombosis in the brain is the superior sagittal sinus.<sup>10</sup>

Patients with predisposing factors like OCP who develop CSVT could be diagnosed due to typical neurological changes, but in severely ill patients, the level of consciousness may be decreased due to hypoxia or intentional anesthesia (to have a better pulmonary function). Therefore, the incidence of CSVT could be missed due to primary decreased LOC. Cerebral sinus venous thrombosis can increase ICP and cause irreversible damage to the brain, so an early diagnosis is fundamental.<sup>11</sup>

In the present case, the patient presented with sudden bilateral visual loss without any predisposing factors. Fortunately, considering that the patient had a good score in the Glasgow coma scale (GCS) and was admitted to the hospital early, the diagnosis was made with brain CT and lumbar puncture. The visual acuity of the patient returned to normal after proper treatment.

## Conclusion

Sinus venous thrombosis is one of the uncommon presentations of COVID-19 that cause increased intracranial hypertension and visual loss. Early diagnosis and treatment are critical and can significantly improve the condition of the patient.

**Funding**  
None.

## Conflict of Interests

The authors have no conflict of interests to declare.

## References

- Sitanggang PA, Tini K, Susilawathi NM, Wijayanti IAS, Dewi PU, Samatra DPGP. Case reports of cerebral sinus venous thrombosis in COVID-19 patients. *Egypt J Neurol Psychiat Neurosurg* 2021;57 (01):83
- Wang D, Hu B, Hu C, et al. Clinical characteristics of 138 hospitalized patients with 2019 novel coronavirus-infected pneumonia in Wuhan, China. *JAMA* 2020;323(11):1061–1069
- Mao L, Jin H, Wang M, et al. Neurologic Manifestations of Hospitalized Patients With Coronavirus Disease 2019 in Wuhan, China. *JAMA Neurol* 2020;77(06):683–690
- Klein DE, Libman R, Kirsch C, Arora R. Cerebral venous thrombosis: A typical presentation of COVID-19 in the young. *J Stroke Cerebrovasc Dis* 2020;29(08):104989
- Zhou F, Yu T, Du R, et al. Clinical course and risk factors for mortality of adult inpatients with COVID-19 in Wuhan, China: a retrospective cohort study. *Lancet* 2020;395(10229):1054–1062
- Spiezia L, Boscolo A, Poletto F, et al. COVID-19-related severe hypercoagulability in patients admitted to intensive care unit for acute respiratory failure. *Thromb Haemost* 2020;120(06):998–1000
- Dmytriw AA, Song JSA, Yu E, Poon CS. Cerebral venous thrombosis: state of the art diagnosis and management. *Neuroradiology* 2018;60(07):669–685
- Devasagayam S, Wyatt B, Leyden J, Kleinig T. Cerebral venous sinus thrombosis incidence is higher than previously thought: a retrospective population-based study. *Stroke* 2016;47(09):2180–2182
- Coutinho JM, Zuurbier SM, Aramideh M, Stam J. The incidence of cerebral venous thrombosis: a cross-sectional study. *Stroke* 2012;43(12):3375–3377
- Wong CK, Lam CW, Wu AK, et al. Plasma inflammatory cytokines and chemokines in severe acute respiratory syndrome. *Clin Exp Immunol* 2004;136(01):95–103
- Abou-Ismaïl MY, Diamond A, Kapoor S, Arafah Y, Nayak L. The hypercoagulable state in COVID-19: Incidence, pathophysiology, and management. *Thromb Res* 2020;194:101–115