



# Morphometric Study for C1 Pedicle Screw Placement in Thai Patients

Pakorn Yuwakosol<sup>1</sup>

<sup>1</sup>Neurosurgical Unit, Department of Surgery, Mukdahan Hospital, Thai Board of Neurological Surgery, Faculty of Medicine, Prince of Songkla University, Songkhla, Thailand

Address for correspondence Pakorn Yuwakosol, MD, Neurosurgical Unit, Department of Surgery, Mukdahan Hospital, Mukdahan, 49000, Thailand (e-mail: tunpakorn@hotmail.com).

AJNS 2022;17:429–434.

## Abstract

**Background** Traumatic atlantoaxial (upper cervical spine) leads to instability in weight-bearing movement and neurological deficit. Presently, C1 (axial) lateral mass or pedicle screws for fixation are the most popular because of excellent mechanical performance for internal fixation. C1 pedicle screw fixation can reduce intraoperative blood loss and postoperative occipital neuralgia more than C1 lateral mass screws. However, screws cannot be inserted completely through the pedicle in some patients due to C1 size.

**Objective** We aimed to determine the ideal pedicle screw entry point, angle of screw projection, and pedicle height in the Thai population.

**Methods** Patient data were collected and measured using the INFINITT program at Mukdahan Hospital from September 2020 to June 2021. The C1 measurements, i.e., distance from the midline to the medial edge of the posterior arch (DPA) and medial edge transverse foramen (DTF), angle of screw projection, and length and height of the pedicle were recorded. Descriptive statistics and *t*-test were used to analyze the data.

**Results** The mean Thai pedicle dimensions were DPA = 14.17 mm (range: 11.19–19.70 mm), DTF = 22.09 mm (range: 18.13–26.44 mm), ideal screw entry point = 18.13 mm (range: 15.19–22.00 mm), ideal angle of screw projection medial angulation = 2.67 degrees (range: 0–7 degrees), and height of posterior arch (pedicle) = 4.77 mm (range: 2.68–7.22 mm). Forty of 167 patients (24.0%) had a pedicle height less than 4.0 mm (bilateral 11 patients and unilateral 29 patients).

**Conclusions** The ideal C1 pedicle screw entry point is approximately 18.13 mm from the midline. In the Thai samples with C1 pedicle height less than 4.0 mm, the screws cannot be inserted completely through the pedicle. Therefore, screw insertion should be partially through the pedicle (notching technique).

## Keywords

- ▶ morphometry
- ▶ pedicle
- ▶ atlas

## Introduction

Traumatic atlantoaxial instability leads to difficulties in weightbearing and movement. The results of injury are

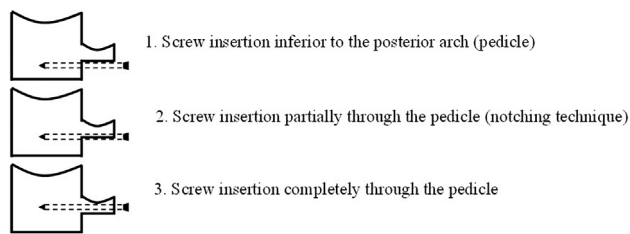
disability, pain, paresis, vertebral deformity, and even sudden death. Multiple surgical methods are available to obtain stability, realignment, and prevent and reduce neurological deficits.

DOI <https://doi.org/10.1055/s-0042-1756625>.  
ISSN 2248-9614.

© 2022. Asian Congress of Neurological Surgeons. All rights reserved.

This is an open access article published by Thieme under the terms of the Creative Commons Attribution-NonDerivative-NonCommercial-License, permitting copying and reproduction so long as the original work is given appropriate credit. Contents may not be used for commercial purposes, or adapted, remixed, transformed or built upon. (<https://creativecommons.org/licenses/by-nc-nd/4.0/>)

Thieme Medical and Scientific Publishers Pvt. Ltd., A-12, 2nd Floor, Sector 2, Noida-201301 UP, India



**Fig. 1** C1 lateral mass screw technique.

C1–C2 wiring with a bone graft<sup>1–3</sup> entails a wire between the C1 and C2 cervical spine and the addition of bone at the posterior part of the C1–C2 for fusion. C1–C2 clamps<sup>4</sup> were also popular as an alternative method for C1–C1 spine fusion.

Multiple methods to perform C1–C2 posterior fixation include C1–C2 transarticular screw fixation (Magerl technique),<sup>5</sup> C1 lateral mass–C2 pedicle screw fixation (Harms technique),<sup>6</sup> and the technique using C1 lateral mass screws and C2 laminar screws (Wright technique).<sup>7</sup> These techniques are used worldwide due to immediate stability and high rates of fusion. However, C1–C2 transarticular screws have a higher risk of vertebral artery injury more than C1 lateral mass–C2 pedicle screw fixation but the fusion rates are nearly the same.<sup>8,9</sup>

Obviously, the present C1 lateral mass screw fixation technique is required for C1–C2 screw fixation. The C1 lateral mass screw technique is performed by one of three methods<sup>10</sup>: (1) screw insertion inferior to the posterior arch (pedicle), (2) screw insertion partially through the pedicle (notching technique), and (3) screw insertion completely through the pedicle (→Fig. 1).

The first method has a high risk for venous plexus injury that leads to a lot of intraoperative blood loss and postoperative occipital neuralgia due to C2 nerve root injury.<sup>11</sup> The other two methods can reduce intraoperative blood loss and postoperative occipital neuralgia but the anatomy of C1 can be the limitation for these methods.

Before C1 lateral mass or pedicle screw fixation, the surgeon needs to evaluate the C1 morphology, i.e., posterior arch height, distance from the midline to the medial side of the posterior arch, distance from the midline to the medial side of the transverse foramen, entry points of the screws, angle of screw trajectory, screw length, and pedicle height. The screw entry point is the most important for intraoperative dissected C1–C2 fixation before insertion of the screws to prevent spinal cord and vertebral artery injury.

In Thai patients, knowledge on the morphology of the C1 pedicle morphometry is limited. The purpose of this study was to assess the C1 posterior arch (pedicle) entry points and morphology. The data are vital for planning screw fixation to decrease the risk of injury to the vertebral artery and spinal cord. Furthermore, this information can be used to develop screw fixation techniques or medical instruments in the future.

## Materials and Methods

The study was performed at Mukdahan Hospital from 1 September 2020 to 30 June 2021 using the INFINITT

program (INFINITT Healthcare Co., Ltd.). Data were collected in Thai patients older than 15 years who underwent a computed tomography (CT) scan of the cervical spine. The cervical spine CT scan image cuts were at a maximum of 1 mm intervals in the axial plane and at a maximum of 3 mm intervals in the sagittal plane. The information collected included demographic data (i.e., gender, age, and the parameters from the cervical spine CT images). The excluded patients were those with congenital anomalies or injuries to the C1 region or artifacts that affected the evaluation of the cortex border of the pedicle and posterior arch.

## Measurements

Measurements of the C1 parameters, which included (1) the distance from the midline to the medial edge of the posterior arch (DPA), (2) the distance from the midline to the medial edge of the transverse foramen (DTF), (3) ideal screw entry point, (4) medial safety angle of the screw projection (MAP), (5) lateral safety angle of the screw projection (LAP), (6) ideal angle of screw projection, (7) screw length, and (8) height of the posterior arch, were performed using the INFINITT program (→Fig. 2). The measurements were recorded in millimeters and degrees by a single author.

## Axial Plane

**DPA:** The measurements were performed at the widest point between the mid-portion of the C1 and medial portion of the posterior arch.

**DTF:** The measurements were performed at the narrowest point between the mid-portion of C1 and the medial portion of the transverse foramen.

**Ideal screw entry point:** The mid-point between DPA and DTF was calculated.

**MAP:** The angle was measured from the ideal entry point line at the posterior outer cortex of the posterior arch and the line from the ideal entry point at the posterior outer cortex of the posterior arch to the inner cortex of the lateral mass.

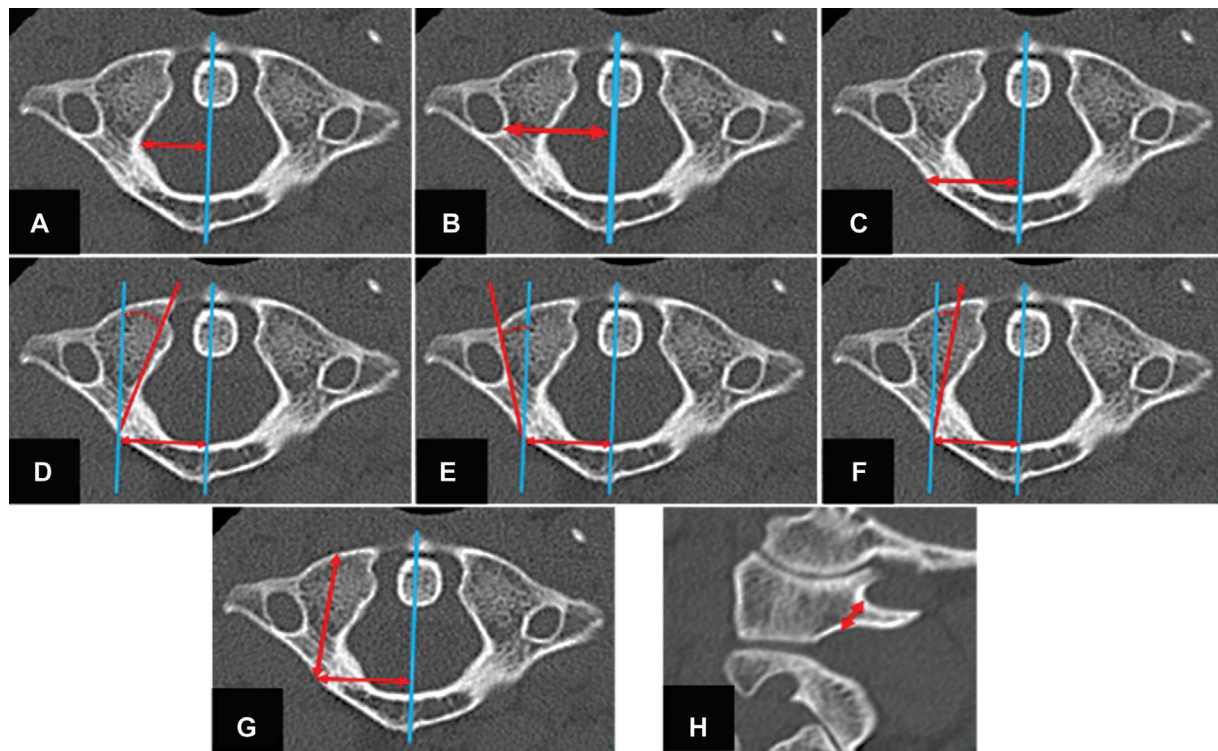
**LAP:** The angle was measured from the ideal entry point line at the posterior outer cortex of the posterior arch and the line from the ideal entry point at the posterior outer cortex of the posterior arch to the outer cortex of the lateral mass.

**Ideal angle of screw projection:** This was calculated from the mid-angle between the medial safety angle of projection and the lateral safety angle of projection.

**Screw length:** This was the length between the ideal screw entry point at the posterior outer cortex of the posterior arch and the anterior outer cortex of the lateral mass at the ideal angle of the screw projection line.

## Sagittal Plane

**Height of the posterior arch:** The height was measured from the superior to inferior outer cortex of the posterior arch at the ideal screw entry point in the axial plane.



**Fig. 2** Measurement techniques. (A) DPA (arrow line). (B) DTF (arrow line). (C) Ideal screw entry point (arrow line). (D) MAP (dashed line). (E) LAP (dashed line). (F) Ideal angle of screws projection (dashed line). (G) screws length (arrow line). (H) height of posterior arch (arrow line).

## Results

The initial number of patients was 192 taken from the records of CT C-spine examinations. After applying the inclusion and exclusion criteria, 167 patients remained in the study, which included 126 (75.4%) males and 41 (24.6%) females. The mean age of all patients was 40 years old (► **Table 1**).

The C1 DPA ranged from 11.19 to 19.70 mm with a mean  $\pm$  standard deviation (SD) of  $14.17 \pm 1.33$  mm. The C1 DTF length ranged from 18.13 to 26.44 mm with a mean  $\pm$  SD of  $22.09 \pm 1.63$  mm. The C1 ideal screw entry point ranged from 15.19 to 22.00 mm with a mean  $\pm$  SD of  $18.13 \pm 1.29$  mm (► **Table 2**).

The C1 MAP ranged from 8 to 26 degrees with a mean  $\pm$  SD of  $16.11 \pm 2.57$  degrees. The C1 LAP ranged from 4 to 20 degrees with a mean  $\pm$  SD of  $10.74 \pm 2.47$  degrees. The C1 ideal medial angulation of screw placement ranged from 0

to 7 degrees with a mean  $\pm$  SD of  $2.67 \pm 1.36$  degrees. The C1 screw length ranged from 23.21 to 33.97 mm with a mean  $\pm$  SD of  $28.71 \pm 1.89$  mm, and the C1 posterior arch height ranged from 2.68 to 7.22 mm with a mean  $\pm$  SD of  $4.77 \pm 0.74$  mm (► **Table 3**).

A subgroup analysis in gender revealed mean  $\pm$  SD values of the C1 DPA were  $14.35 \pm 1.35$  mm in males and  $13.65 \pm 1.11$  mm in females. The C1 DTF (both sides) was

**Table 1** Demographic data

Factor	
Gender	
Male, n (%)	126 (75.4)
Female, n (%)	41 (24.6)
Age (y), mean $\pm$ SD (min–max)	
< 40, n (%)	83 (49.7)
$\geq 41$ , n (%)	84 (50.3)

Abbreviation: SD, standard deviation.

**Table 2** Atlas (C1) morphology

Factor	Mean $\pm$ SD	Range (min–max)
DPA (mm)		
Right	$14.16 \pm 1.33$	11.19–19.70
Left	$14.19 \pm 1.33$	11.39–19.70
<b>Both sides</b>	<b><math>14.17 \pm 1.33</math></b>	<b>11.19–19.70</b>
DTF (mm)		
Right	$22.05 \pm 1.62$	18.59–26.40
Left	$22.13 \pm 1.63$	18.13–26.44
<b>Both sides</b>	<b><math>22.09 \pm 1.63</math></b>	<b>18.13–26.44</b>
Ideal screw entry point (mm)		
Right	$18.10 \pm 1.30$	15.50–22.00
Left	$18.16 \pm 1.28$	15.19–22.00
<b>Both sides</b>	<b><math>18.13 \pm 1.29</math></b>	<b>15.19–22.00</b>

Abbreviations: DPA, distance midline to medial edge posterior arch; DTF, distance midline to medial edge transverse foramen; SD, standard deviation.

**Table 3** Atlas (C1) morphology

Factor	Mean ± SD	Range (min–max)
MAP angle (degrees)		
Right	16.10 ± 2.58	8–26
Left	16.11 ± 2.56	10–23
<b>Both sides</b>	<b>16.11 ± 2.57</b>	<b>8–26</b>
LAP angle (degrees)		
Right	10.70 ± 2.49	4–20
Left	10.79 ± 2.45	5–18
<b>Both sides</b>	<b>10.74 ± 2.47</b>	<b>4–20</b>
IAP angle (degrees)		
Right	2.69 ± 1.39	0–6
Left	2.66 ± 1.33	0–7
<b>Both sides</b>	<b>2.67 ± 1.36</b>	<b>0–7</b>
Screw length (mm)		
Right	28.83 ± 1.85	23.41–33.80
Left	28.59 ± 1.93	23.21–33.97
<b>Both sides</b>	<b>28.71 ± 1.89</b>	<b>23.21–33.97</b>
Height of posterior arch (mm)		
Right	4.81 ± 0.73	3.17–6.88
Left	4.72 ± 0.75	2.68–7.22
<b>Both sides</b>	<b>4.77 ± 0.74</b>	<b>2.68–7.22</b>

Abbreviations: IAP, ideal angle of screw projection; LAP, lateral safety angle of screws projection; MAP, medial safety angle of screws projection; SD, standard deviation.

22.45 ± 1.56 mm in males and 20.97 ± 1.30 mm in females. The C1 ideal screw entry point (both sides) was 18.40 ± 1.25 mm in males and 17.31 ± 1.03 mm in females. The C1 screw length (both sides) was 29.05 ± 1.81 mm in males and 27.68 ± 1.75 mm in females. The C1 height of the posterior arch (both sides) was 4.87 ± 0.73 mm in males and 4.45 ± 0.67 mm in females. The mean values for both left and right C1 DPA, DTF, ideal screw entry point, screw length, and height of the posterior arch were greater in males than in females, and the differences were statistically significant (*t*-test, *p* < 0.05) (► **Table 4**).

From a total of 334 posterior arches (both sides), the height of the pedicle posterior arch was less than 4 mm in 15.26% (51/334) of arches. Forty patients (24.0%) had a pedicle posterior arch height less than 4.0 mm (bilateral 11 patients and unilateral 29 patients), which would not be safe for screw insertion completely through the pedicle (► **Fig. 3**).

## Discussion

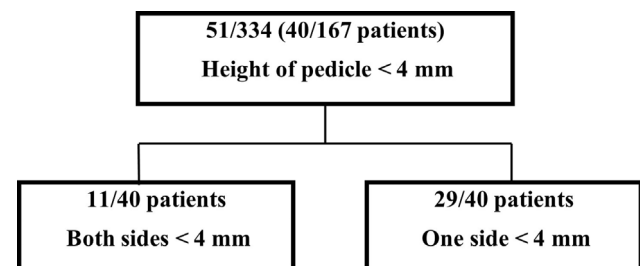
To date, a morphometric study for C1 pedicle screw placement has not been reported in the Thai population. The present study in Thai patients revealed that the mean values for C1 DPA, DTF, screw entry point, medial ideal angle screw projection, and screw length were 14.17 mm, 22.09 mm, 18.13 mm, 2.67 degrees, and 28.71 mm, respectively. The

**Table 4** Atlas (C1) morphology between males and females

Factor	Male	Female
	Mean ± SD	Mean ± SD
DPA (mm)		
Right	14.33 ± 1.39	13.65 ± 0.98
Left	14.36 ± 1.31	13.66 ± 1.23
<b>Both sides</b>	<b>14.35 ± 1.35</b>	<b>13.65 ± 1.11</b>
DTF (mm)		
Right	22.39 ± 1.58	20.10 ± 1.30
Left	22.51 ± 1.54	20.94 ± 1.31
<b>Both sides</b>	<b>22.45 ± 1.56</b>	<b>20.97 ± 1.30</b>
Ideal screws entry point (mm)		
Right	18.36 ± 1.29	17.32 ± 0.97
Left	18.44 ± 1.21	17.30 ± 1.09
<b>Both sides</b>	<b>18.40 ± 1.25</b>	<b>17.31 ± 1.03</b>
Screws length (mm)		
Right	29.12 ± 1.79	27.94 ± 1.75
Left	28.98 ± 1.84	27.41 ± 1.75
<b>Both sides</b>	<b>29.05 ± 1.81</b>	<b>27.68 ± 1.75</b>
Height of posterior arch (mm)		
Right	4.91 ± 0.72	4.50 ± 0.67
Left	4.83 ± 0.75	4.41 ± 0.67
<b>Both sides</b>	<b>4.87 ± 0.73</b>	<b>4.45 ± 0.67</b>

Abbreviations: DPA, distance from the midline to the medial edge of the posterior arch; DTF, distance from the midline to the medial edge of the transverse foramen; LAP, lateral safety angle of screws projection; MAP, medial safety angle of screw projection; SD, standard deviation.

current results were similar to those reported in a previous study in Asian people by Tan et al.<sup>12</sup> In that study, 50 patients were enrolled in the study and the mean values for DPA, DTF, screw entry point, medial ideal angle screw projection, and screw length were 12.62 mm, 24.61 mm, 19.01 mm, 0.33 degrees, and 30.07 mm. Simsek et al<sup>13</sup> reported that the C1 pedicle screw parameters including DPA, DTF, screw entry point, medial ideal angle screw projection, and screw length in 40 Turkish patients were 14.04 mm, 22.49 mm, 18.27 mm, 13.5 degrees, and 19.59 mm. Blagg et al<sup>14</sup> measure the C1 pedicle similar to our technique in New Zealand patients. The results were the same as those of the current study (► **Table 5**).

**Fig. 3** Flow chart height of the posterior arch (pedicle) data.



**Table 5** Comparison of studies on C1 measurements

Study	Country	Number of patients	DPA (mm)	DTF (mm)	Screw entry point (mm)	Medial IAP angle (°)	Screw length (mm)
Current study	Thailand	167	14.17 ± 1.33	22.09 ± 1.63	18.13 ± 1.29	2.67 ± 1.36	28.71 ± 1.89
Tan et al <sup>12</sup>	Asian	50	12.62 ± 1.22	24.61 ± 1.25	19.01 ± 1.88	0.33 ± 9.72	30.07 ± 1.66
Simsek et al <sup>13</sup>	Turkey	40	14.06 ± 1.3	22.49 ± 1.7	18.27 ± (No)	13.5 ± 1.9	19.59
Blagg et al <sup>14</sup>	New Zealand	50	14.95 ± (No)	23.62 ± (No)	20.14 ± (No)	No	No

Abbreviations: DPA, distance midline to medial edge posterior arch; DTF, distance midline-to-medial edge transverse foramen; IAP, ideal angle of screws projection; No, no data; SD, standard deviation.

**Table 6** Comparison of studies on C1 pedicle height

Study	Country	Number of patients	Height of C1 pedicle, mean ± SD (mm)	Height of C1 pedicle < 4 mm (%)
Current study	Thailand	167	4.77 ± 0.74	15.26%
Tan et al <sup>12</sup>	Asian	50	4.58 ± 0.65	8%
Srivastava et al <sup>16</sup>	Indian	42	4.48 ± 0.91	32%
Qian et al <sup>17</sup>	China	120	4.43 ± 1.18	23.3%
Christensen et al <sup>15</sup>	Western Blacks and White Caucasians	120	4.80 ± 0.93	19.2%

Abbreviation: SD, standard deviation.

The current study found C1 pedicle height was 4.77 mm, which was consistent with a study by Christensen et al<sup>15</sup> who reported a C1 pedicle height of 4.80 mm in Western Blacks and White Caucasians. The mean height of the C1 pedicle of the current study was greater than the mean heights of the Tan et al<sup>12</sup> study (4.58 mm), Srivastava et al<sup>16</sup> study (4.48 mm), and the Qian et al<sup>17</sup> study (4.43 mm). This likely occurred due to ethnic differences. Qian et al<sup>17</sup> found excellent mechanical internal fixation; however, the size of screws used was 3.5 mm and a minimum of 4 mm of bone thickness would be required. In our Thai population, 15.26% (51/334) of pedicles of either or both sides were not suitable for insertion of the C1 pedicle screws completely through the pedicle (→Table 6).

## Conclusions

The C1 pedicle screw entry point is approximately 18.13 mm from the midline. In 24.0% of Thai samples with a C1 pedicle height less than 4.0 mm, a C1 pedicle screw cannot be safely inserted completely through the pedicle. Thai patients with a C1 pedicle height less than 4 mm should receive the partially through the pedicle technique (notching technique) to reduce intraoperative blood loss and postoperative occipital neuralgia.

**Funding**  
None.

**Conflicts of Interest**  
None declared.

## References

- Gallie WE. Fractures and dislocations of cervical spine. *Am J Surg* 1939;46:495–499
- Brooks AL, Jenkins EB. Atlanto-axial arthrodesis by the wedge compression method. *J Bone Joint Surg Am* 1978;60(03):279–284
- Dickman CA, Sonntag VK, Papadopoulos SM, Hadley MN. The interspinous method of posterior atlantoaxial arthrodesis. *J Neurosurg* 1991;74(02):190–198
- Holness RO, Huestis WS, Howes WJ, Langille RA. Posterior stabilization with an interlaminar clamp in cervical injuries: technical note and review of the long term experience with the method. *Neurosurgery* 1984;14(03):318–322
- Magerl F, Seemann P. Stable posterior fusion of the atlas and axis by transarticular screw fixation. In: Kehr P, Weidner A, eds. *Cervical spine I*. New York: Springer; 1987:322–327
- Harms J, Melcher RP. Posterior C1–C2 fusion with polyaxial screw and rod fixation. *Spine* 2001;26(22):2467–2471
- Wright NM. Translaminar rigid screw fixation of the axis. Technical note. *J Neurosurg Spine* 2005;3(05):409–414
- Elliott RE, Tanweer O, Boah A, et al. Atlantoaxial fusion with transarticular screws: meta-analysis and review of the literature. *World Neurosurg* 2013;80(05):627–641
- Elliott RE, Tanweer O, Boah A, et al. Outcome comparison of atlantoaxial fusion with transarticular screws and screw-rod constructs: meta-analysis and review of literature. *J Spinal Disord Tech* 2014;27(01):11–28
- Lee MJ, Cassinelli E, Riew KD. The feasibility of inserting atlas lateral mass screws via the posterior arch. *Spine* 2006;31(24):2798–2801
- Filho NMF, Arantes R, do Nascimento AL, Herrero CFPDS. Morphometric Study of the Atlas. *Rev Bras Ortop* (Sao Paulo) 2020;55(01):62–69
- Tan M, Wang H, Wang Y, et al. Morphometric evaluation of screw fixation in atlas via posterior arch and lateral mass. *Spine* 2003;28(09):888–895

- 13 Simsek S, Yigitkanli K, Seçkin H, et al. Ideal screw entry point and projection angles for posterior lateral mass fixation of the atlas: an anatomical study. *Eur Spine J* 2009;18(09):1321–1325
- 14 Blagg SE, Don AS, Robertson PA. Anatomic determination of optimal entry point and direction for C1 lateral mass screw placement. *J Spinal Disord Tech* 2009;22(04):233–239
- 15 Christensen DM, Eastlack RK, Lynch JJ, Yaszemski MJ, Currier BL. C1 anatomy and dimensions relative to lateral mass screw placement. *Spine* 2007;32(08):844–848
- 16 Srivastava A, Mahajan R, Nanda A, et al. Morphometric study of C1 pedicle and feasibility evaluation of C1 pedicle screw placement with a novel clinically relevant radiological classification in an Indian population. *Asian Spine J* 2017;11(05):679–685
- 17 Qian LX, Hao DJ, He BR, Jiang YH. Morphology of the atlas pedicle revisited: a morphometric CT-based study on 120 patients. *Eur Spine J* 2013;22(05):1142–1146