



Preoperative Transarterial Embolization of a Large Petrotentorial Angiomatous Meningioma Using Combination of Liquid Embolic Materials: A Case Report

Prasert Iampreechakul¹ Sarunya Yuthagovit¹ Korrapak Wangtanaphat¹ Sunisa Hangsapruerk²
Punjama Lertbutsayanukul² Samasuk Thammachantha³ Somkiet Siritwimonmas⁴

¹Department of Neurosurgery, Prasat Neurological Institute, Bangkok, Thailand

²Department of Neuroradiology, Prasat Neurological Institute, Bangkok, Thailand

³Department of Pathology, Prasat Neurological Institute, Bangkok, Thailand

⁴Department of Radiology, Bumrungrad International Hospital, Bangkok, Thailand

Address for correspondence Prasert Iampreechakul, MD, Department of Neurological Surgery, Prasat Neurological Institute, 312 Ratchawithi Road, Khwaeng Thung Phaya Thai, Bangkok, 10400, Thailand (e-mail: bangruad@hotmail.com).

AJNS 2022;17:500–506.

Abstract

Intracranial angiomatous meningiomas are a rare WHO grade I histological variant of meningioma whose vascular component exceeds 50% of the total tumor area. Preoperative embolization of angiomatous meningiomas has rarely been reported previously. A 58-year-old woman was referred to our institute for a large petrotentorial hypervascular tumor presented with progressively worsening right facial paralysis and hearing loss for 6 months. Cranial computed tomography scan and magnetic resonance imaging revealed a large homogenously enhancing multilobulated mass involving middle and posterior cranial fossae with marked brainstem compression. The tumor extended into a right internal auditory canal and labyrinthine structures with destructive changes of bony structures. Magnetic resonance angiography showed hypervascularity in the tumor. Preoperative transarterial embolization using liquid embolic materials was successfully performed with resulting in almost complete devascularization of the tumor. Adequate hemostasis was achieved following gross total resection of the tumor (Simpson grade II). A histopathological examination confirmed the diagnosis of an angiomatous meningioma. Preoperative transarterial embolization of angiomatous meningioma with liquid embolic material was safe and effective in reducing perioperative blood loss and facilitating total tumor resection.

Keywords

- ▶ preoperative embolization
- ▶ brain tumor
- ▶ angiomatous meningioma

DOI <https://doi.org/10.1055/s-0042-1756626>.
ISSN 2248-9614.

© 2022. Asian Congress of Neurological Surgeons. All rights reserved.

This is an open access article published by Thieme under the terms of the Creative Commons Attribution-NonDerivative-NonCommercial-License, permitting copying and reproduction so long as the original work is given appropriate credit. Contents may not be used for commercial purposes, or adapted, remixed, transformed or built upon. (<https://creativecommons.org/licenses/by-nc-nd/4.0/>)

Thieme Medical and Scientific Publishers Pvt. Ltd., A-12, 2nd Floor, Sector 2, Noida-201301 UP, India

Introduction

Intracranial angiomatous meningiomas are a rare subtype of meningioma, which account for 2.1% of all intracranial meningiomas.¹ Most angiomatous meningiomas occur most frequently in middle-aged patients, with a slight female preponderance. These tumors occur most commonly in the cerebral convexity, and rarely in the skull base area.² Clinically, angiomatous meningiomas most commonly manifest as seizures and neurological deficits depending on the location of the tumor and mass effect.^{3,4} Due to its extremely rich blood supply, surgical resection of angiomatous meningiomas is more difficult than resection of other types of meningiomas. Preoperative embolization may be useful for the treatment of this type of meningioma.⁵ However, preoperative embolization of intracranial angiomatous meningiomas has rarely been reported previously.⁶ According to the large series of intracranial angiomatous meningiomas by Ben Nsir et al,⁷ no patient had effective preoperative embolization of these tumors, leading to hemorrhagic event during surgical resection in the majority of patients.

We reported a rare case of a petrotentorial angiomatous meningioma and described an effective preoperative transarterial embolization of this tumor using a combination of different liquid embolic materials.

Case Report

A 58-year-old woman, with a medical history of hypertension, was transferred to our institution for the resection of a large petrotentorial hypervascular tumor. The main complaints were progressively worsening right facial paralysis and hearing loss for 6 months. She also had dizziness and right-sided facial numbness. On neurological examination, there were right facial weakness (House-Brackmann grade V), sensorineural hearing loss, trigeminal sensory loss, and cerebellar signs. She had normal swallowing and no motor weakness. Computed tomography (CT) scan of the brain revealed a large homogeneously enhancing extra-axial mass involving middle and posterior cranial fossae with marked brain stem compression. The tumor had multilobulated borders and extended into a right internal auditory canal and labyrinthine structures with destructive changes of bony structures (→Fig. 1). On magnetic resonance imaging (MRI), the tumor was hypointense on T1-weighted sequence and hyperintense on T2-weighted sequence with prominent multiple flow voids within the tumor. There was mild peritumoral edema at the right temporal lobe (→Fig. 2). Magnetic resonance angiography showed hypervascularity in the tumor (→Fig. 3). Based on aggressive features on imaging findings, we made a preoperative diagnosis of hemangiopericytoma. Preoperative angiography followed

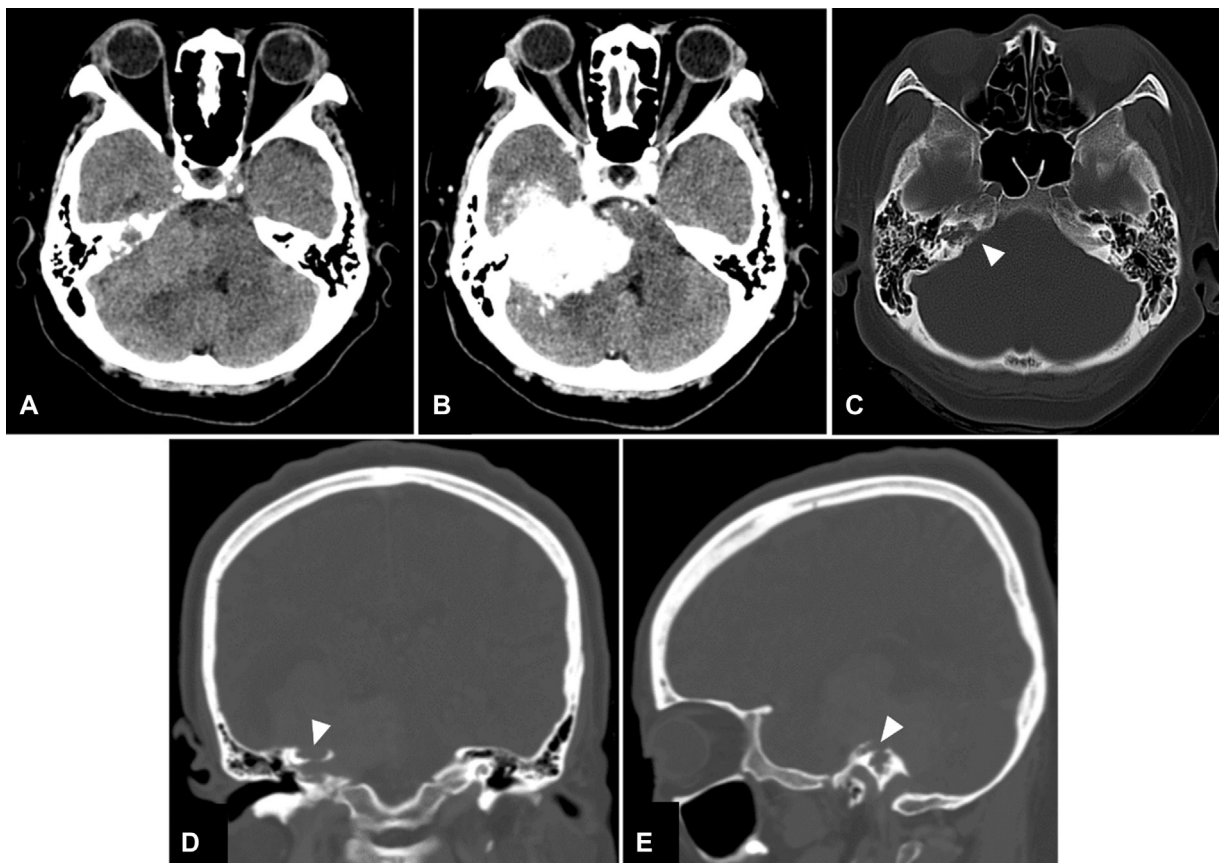


Fig. 1 Axial computed tomography (CT) scan of the brain (A) without and (B) with contrast reveal a large homogeneously enhancing extra-axial mass involving middle and posterior cranial fossae with marked brainstem compression. (C) Axial, (D) coronal, and (E) views of bone-window CT scan demonstrate destructive changes (arrowheads) of the right internal auditory canal and labyrinthine structures.

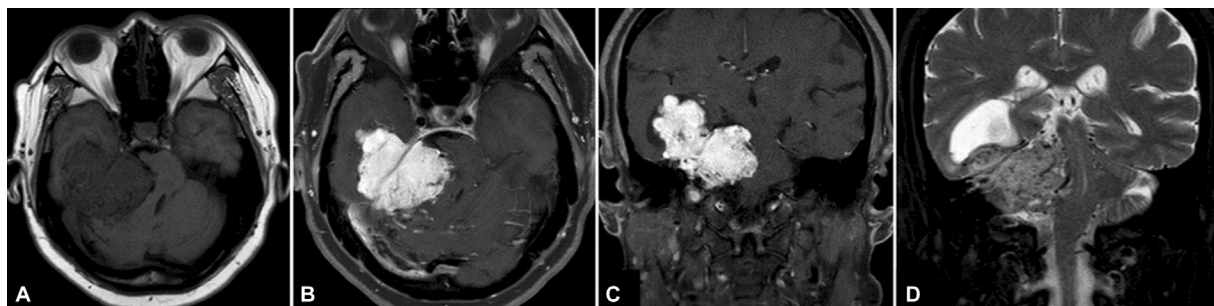


Fig. 2 (A) Axial T1-weighted, (B) axial, and (C) coronal T1-weighted gadolinium-enhanced magnetic resonance images show intense homogeneous enhancement of the large multilobulated mass, arising from the petrotentorial region involving middle and posterior cranial fossae with irregular borders and marked brainstem compression. (D) T2-weighted fat-suppressed magnetic resonance sequence reveals multiple flow voids within the tumor.

by embolization was planned to identify major arterial feeders, facilitate surgical resection, and reduce perioperative blood loss.

Under general anesthesia, cerebral angiography was performed and revealed a large prolonged-staining hypervascular tumor blush supplied by the right middle meningeal artery (MMA), occipital artery, ascending pharyngeal artery, posterior auricular artery, meningohypophyseal trunk of internal carotid artery, and pial branches of posterior cerebral artery (►Fig. 4). Initially, transarterial embolization with Squid 12 (Balt Extrusion, Montmorency, France) 3 bottles (1.5 cc/bottle) was successfully performed through the distal petrosquamosal branch of right MMA using a dimethyl sulfoxide (DMSO)-compatible and detachable-tip microcatheter, Apollo (Medtronic, Irvine, California, United States) without reflux to the tip of microcatheter (►Fig. 5A, B). Unexpectedly, we had only three bottles of Squid 12 in our stock at that moment. Control angiography showed the remaining tumor blush. We planned

to go on embolization with other liquid embolic materials. During preparing of Onyx 18, transarterial embolization with *n*-butyl cyanoacrylate (NBCA) (Histoacryl; B. Braun, Melsungen, Germany) 0.2 cc. was performed through second microcatheter, Magic 1.2 F (Balt Extrusion, Montmorency, France) (►Fig. 5C, D). Finally, another branch of the right posterior auricular artery was selected and embolization with Onyx 18 (Medtronic, Irvine, California, United States) 1.5 cc. was performed through the first Apollo microcatheter (reusable from first injection; ►Fig. 5E, F). Angiography immediately after embolization revealed nearly complete angiographic devascularization of the hypervascular tumor (►Fig. 6). During the procedure, dexamethasone sodium phosphate injection is administered initially in a dosage of 10 mg intravenously followed by 4 mg every 6 hours until the day of surgery. No immediate or delayed complications from preoperative embolization occurred in our patient.

Surgery was scheduled the following 5 days. However, we planned to set emergency surgery if the patient had neurological deterioration. Fortunately, our patient had stable condition. Follow-up cranial MRI, obtained 4 days after embolization, revealed significant devascularization of the tumor (►Fig. 7). The patient underwent a two-stage surgery in the order of retrosigmoid and subtemporal approaches with estimated blood loss 800 and 300 cc, respectively. Black embolic materials were noted within the tumor (►Fig. 8). The cranial nerves IV to VIII, brain stem, and cerebellum were safely dissected from the tumor. Adequate hemostasis was achieved following gross total resection of the tumor (Simpson grade II). The attachment of tumor was at tentorium cerebelli.

The histopathological examination revealed hypervascular meningotheelial tumor with numerous intravascular embolic materials. The tumor cells have oval nuclei with intranuclear pseudoinclusions. Mitotic figure, necrosis, and brain invasion are not seen. These findings were consistent with angiomatous meningioma, World Health Organization (WHO) grade I (►Fig. 9).

Follow-up CT scan of the brain, obtained the following day after a two-stage of surgery, confirmed total resection of the tumor (►Fig. 10). The patient had an uneventful postoperative course and was sent to neuro-ophthalmologist and physiotherapist for further management of facial nerve palsy.

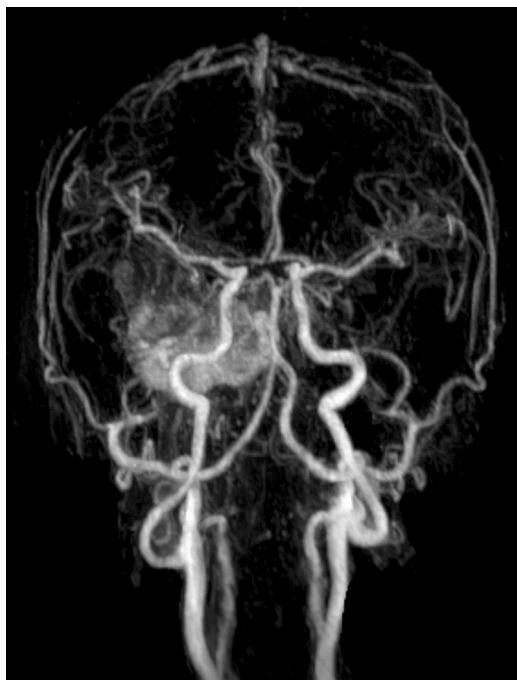


Fig. 3 Magnetic resonance angiography demonstrates hypervascularity in the tumor.

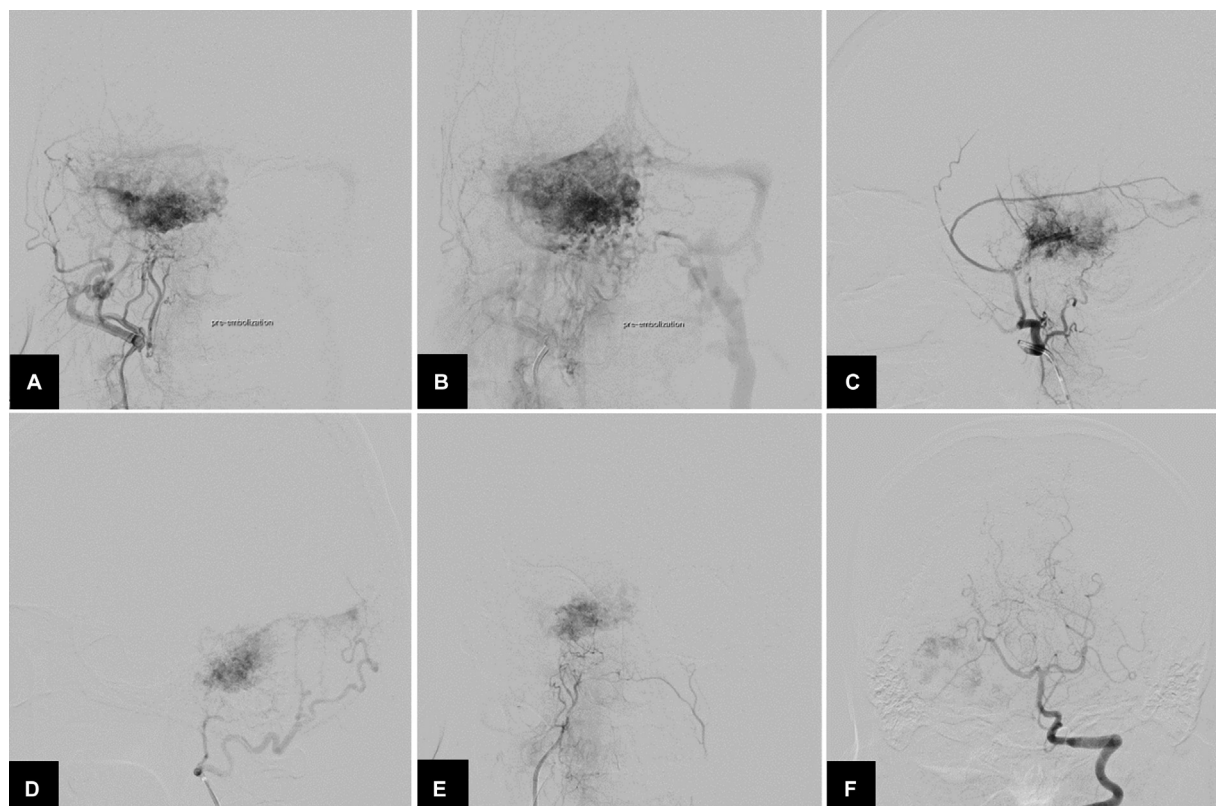


Fig. 4 Anteroposterior views of (A) arterial and (B) venous phases of the right external carotid angiography reveal prominent tumor stain with venous drainage into the right transverse sinus. Lateral views of the right (C) middle meningeal and (D) occipital arteries and anteroposterior views of (E) the right ascending pharyngeal and (F) left vertebral arteries angiography demonstrate multiple feeders supplying the tumor.

Discussion

Intracranial hemangiopericytoma and angiomatous meningioma are difficult to distinguish prior to surgery. Hemangiopericytomas tend to show aggressive features on MRI such as tumor invasion, irregular or multilobulated borders, and bone erosion.⁸ However, Meng et al⁹ studied the radiologic characters to predict hemangiopericytoma from angiomatous meningioma and found that aggressive behavior on MRI was found no difference between these tumors.

Angiomatous meningiomas are a rare WHO grade I histological variant of meningioma that features numerous blood vessels, which often constitute a greater proportion of the tumor mass than do the intermixed meningioma cells. Angiomatous meningiomas are also known as vascular meningiomas.¹⁰ These meningiomas are defined as any meningioma whose vascular component exceeds 50% of the total tumor area.¹ Intracranial angiomatous meningiomas occur most commonly in the cerebral convexity, and rarely at tentorium cerebelli and skull base area. The presence of perilesional edema is much more common than meningiomas in general. Vascular endothelial growth factor, angiogenesis, may play an important role in the formation of peritumoral brain edema.^{2,4} It is recommended that cerebral angiography should be performed before surgery to identify definite arterial feeders and preoperative embolization should be done for reduction in the risk of major bleeding

during surgical resection, especially in angiomatous meningiomas located at the skull base.^{3,5}

Over the years, polyvinyl alcohol (PVA) particles and NBCA have frequently been used as embolic agents for preoperative embolization of extra- and intracranial tumors, including meningioma.⁶ Currently, an ethylene-vinyl alcohol (EVOH) copolymer-based liquid embolic agent has been developed for meningioma embolization due to slow polymerization and nonadhesive properties providing a reduced risk of microcatheter entrapment than NBCA and prolonged embolization time during the embolization resulting in more controlled injection of the agent.^{11,12} Compared with PVA particles, liquid embolic materials, including NBCA and EVOH copolymer, can penetrate deeper into tumoral capillaries and have a permanent effect, probably resulting in tumor shrinkage and allowing easier tumor dissection. It is useful for the patient planned for delayed surgical resection, as in our case.^{6,13}

Squid, as Onyx, is composed of an EVOH copolymer with suspended micronized tantalum powder for radiopacity and DMSO solvent. Onyx has three different concentrations including Onyx 18, 20, and 34 depending on EVOH concentration in the composite 6, 6.5, and 8%, respectively. Squid has been introduced with four different formulations (18, 18 low density [LD], 12, 12 LD) depending on viscosity (18–standard viscosity and 12–low viscosity) and the percentage of dissolved tantalum powder (standard and LD).^{14,15}

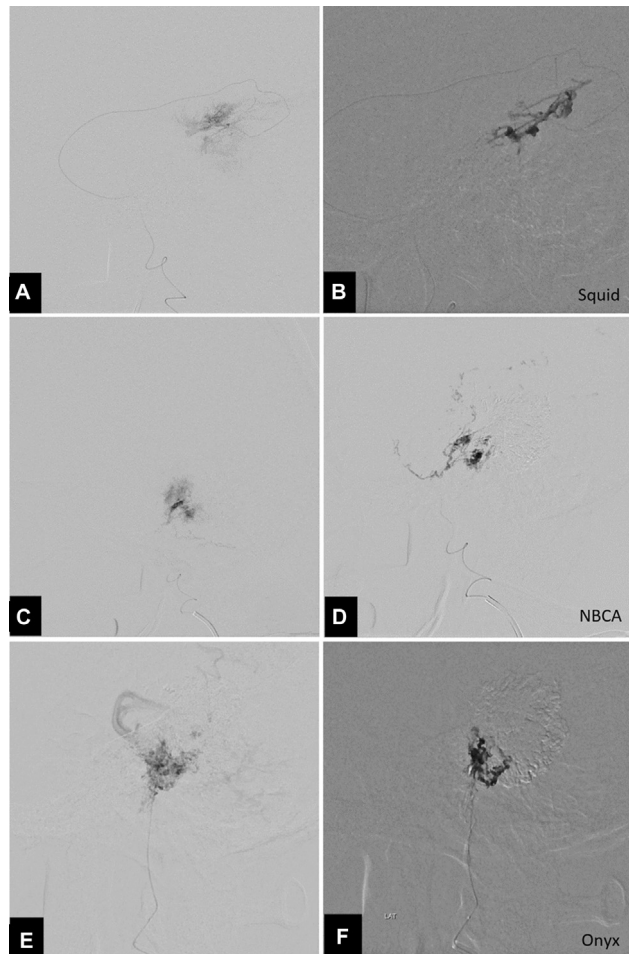


Fig. 5 Lateral views of superselective angiography of the distal petrosquamosal branch of right middle meningeal artery (A), petrosal branch of right middle meningeal artery (C), and posterior auricular artery (E) reveal tumor blushes before embolization and distribution of Squid 12 (B), *n*-butyl cyanoacrylate (D), and Onyx 18 (F) during embolization.

We preferred Squid 12 as the first choice of liquid embolic material because the lower viscosity of Squid 12 compared with Onyx 18 may allow an even deeper penetration of the tumoral capillaries.¹³ Another advantage of Squid 12 over Onyx 18 is related to the reduced percentage (30%) of tantalum that can improve vessels visualization during embolization and limit metallic artifacts at imaging follow-up.¹⁵ According to the study of preoperative embolization of intra- and extracranial tumors by lampreechakul et al.,⁶ they found that only extensive or complete angiographic devascularization of the tumor has been effective in less intraoperative blood loss. In the present study, we used the combination of embolic materials because we did not have Squid 12 enough for this tumor due to the problem of hospital policy in stocking of EVOH in our hospital. We used additional NBCA during the preparation of another EVOH, that is, Onyx. Therefore, it was possible to use only EVOH. However, we found that all Squid 12, NBCA, and Onyx 18 were successfully used for preoperative embolization of this kind of meningioma, angiomatous

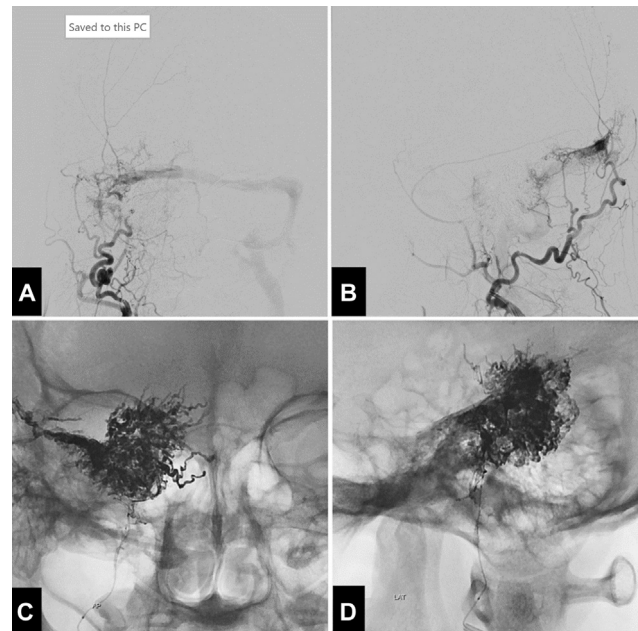


Fig. 6 (A) Anteroposterior and (B) lateral views of the right external carotid artery angiography following the embolization reveal nearly complete angiographic devascularization of the hypervascular tumor. (C) Anteroposterior and (D) lateral views of unsubtracted image illustrate dense cast of embolic materials within the tumor parenchyma.

meningioma, with excellent penetration of liquid embolic materials and almost complete angiographically obliteration was achieved without any complication. Gadolinium-enhanced brain MRI following the tumor embolization confirmed significant devascularization of angiomatous meningioma.

Due to lower viscosity of Squid 12, it can favor penetration in all vascular pedicles and their more distal branches, affecting the vasa nervorum of the facial nerve, causing facial nerve palsy after embolization.¹⁶ Our case had facial palsy and hearing loss, probably from tumor invasion, before embolization. However, the microcatheter was always navigated in the proximity of the tumor as near as possible and injected contrast for searching dangerous extracranial-intracranial anastomoses and blood vessels supplying the cranial nerves before embolization. During embolization, embolic materials were always administered with awareness of reflux into normal blood vessels.

To avoid of tumor edema after embolization, we used dexamethasone sodium phosphate injection during and after embolization. Some authors suggested that the resection of large hypervascular brain tumors should be performed immediately after embolization.¹⁷ However, we prepared emergency surgery if the patient developed any signs of the neurological deficits or brain herniation.

The optimal timing between tumor embolization and surgery has been debated. The timing to surgery after embolization depends on embolic material chosen.⁶ After embolization with PVA particles, subsequent surgery should not be delayed for more than 2 weeks.¹⁸ EVOH and NBCA are

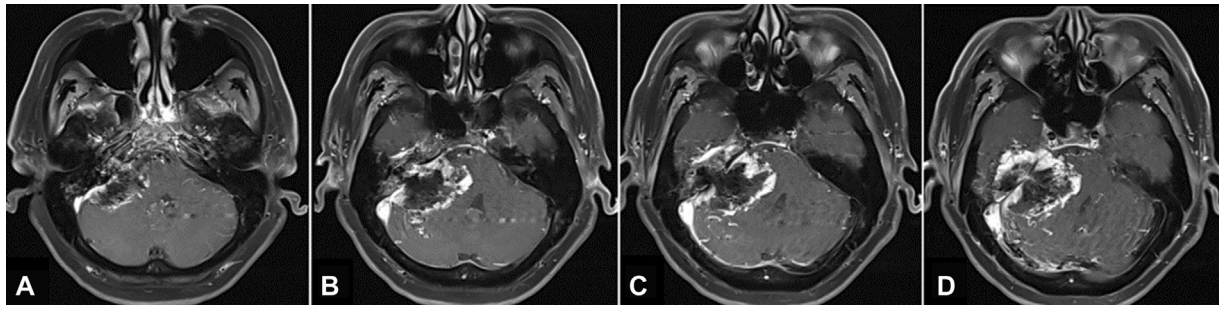


Fig. 7 (A–D) Sequential axial T1-weighted gadolinium-enhanced magnetic resonance images of the brain, obtained 4 days after embolization, demonstrate significant devascularization of the tumor.

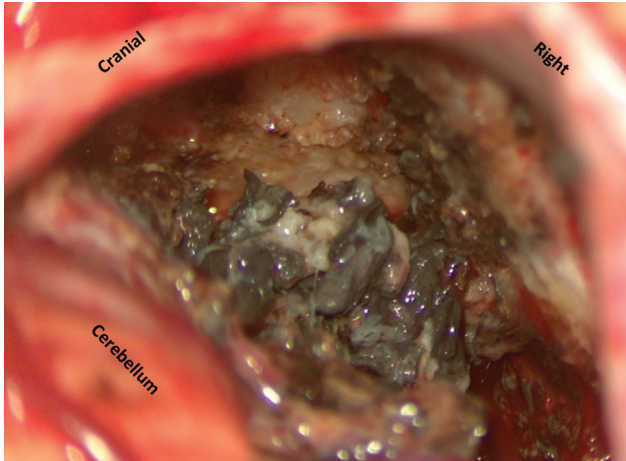


Fig. 8 Intraoperative photograph during removal of the tumor reveals the black cast of embolic materials within tumor parenchyma.

more permanent than PVA particles, and may last for weeks or months, whereas particles can degrade over time, increasing the possibility of recanalization of occluded feeding vessels.^{13,19} Shi et al¹³ waited for 10 days after embolization of three meningiomas with Onyx and suggested that it was safe to delay surgical resection after embolization with Onyx. In our case, surgery was scheduled the following 5 days. Fortunately, no complications occurred following the embolization of the large hypervascular tumor.

Gross total resection is the treatment of choice for these tumors. In addition, radiotherapy can be used for residual tumors.⁴ Angiomatous meningiomas manifest benign behavior with a satisfying clinical outcome in long-term follow-up, which makes Simpson grade II an option in case of high risk for Simpson grade I resection.²

Conclusion

We reported a rare case of a large petrotentorial angiomatous meningioma showing aggressive behaviors. Preoperative transarterial embolization of angiomatous meningioma using liquid embolic materials, including NBCA, Squid 12, or Onyx 18, was safe and effective in reducing perioperative blood loss and facilitating total tumor resection. There was no adverse reaction when different kinds of embolic materials were used in the same session in our case.

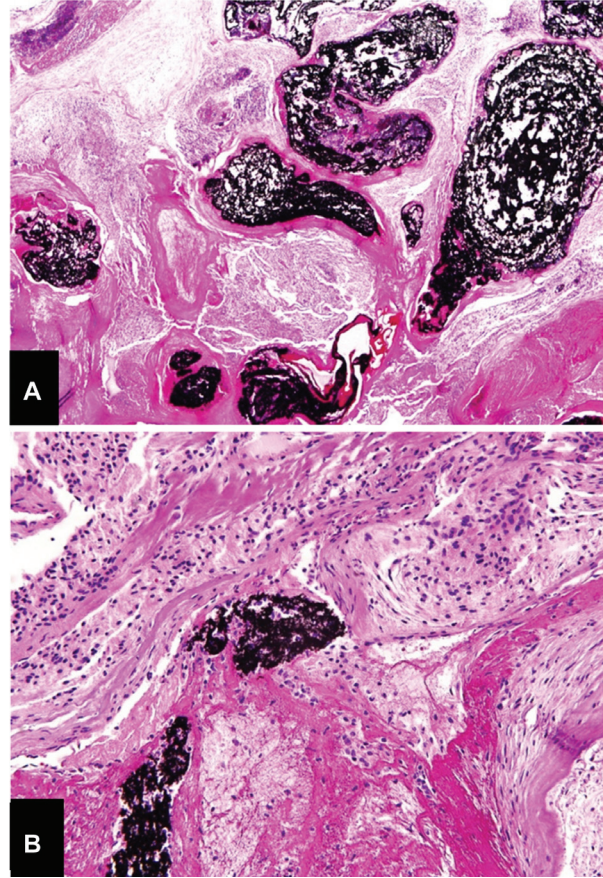


Fig. 9 The histopathological study shows meningothelial tumor with numerous large vessels. Dark embolic agents occupying the vascular lumen are observed (A, 100 \times and B, 400 \times ; hematoxylin and eosin).

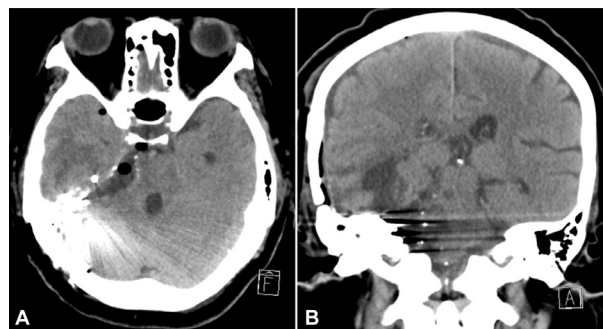


Fig. 10 (A) Axial and (B) coronal views of computed tomography of the brain, obtained the following day after a two-stage of surgery, confirm no residual tumor.

Funding

None.

Conflict of Interest

None declared.

Informed Consent

The patient has given consent to be enrolled and has her data published.

The authors certify that they have obtained all appropriate patient consent forms. In the form, the patient has given her consent for her images and other clinical information to be reported in the journal. The patient understands that name and initials will not be published, and due efforts will be made to conceal identity, but anonymity cannot be guaranteed.

References

- Hasselblatt M, Nolte KW, Paulus W. Angiomatous meningioma: a clinicopathologic study of 38 cases. *Am J Surg Pathol* 2004;28(03): 390–393
- Hua L, Luan S, Li H, et al. Angiomatous meningiomas have a very benign outcome despite frequent peritumoral edema at onset. *World Neurosurg* 2017;108:465–473
- Bashar M, Sohail W, Khan M, Yaqoob U. Angiomatous meningioma presenting with depression: a case report and literature review. *Case Rep Clin Med* 2020;9:22–28
- Liu Z, Wang C, Wang H, Wang Y, Li JY, Liu Y. Clinical characteristics and treatment of angiomatous meningiomas: a report of 27 cases. *Int J Clin Exp Pathol* 2013;6(04):695–702
- Yang L, Ren G, Tang J. Intracranial angiomatous meningioma: a clinicopathological study of 23 cases. *Int J Gen Med* 2020; 13:1653–1659
- lampreechakul P, Tirakotai W, Lertbutsayanukul P, Siriwimonmas S, Liengudom A. Pre-operative embolization of intracranial and extracranial tumors: a review of 37 cases. *J Med Assoc Thai* 2016; 99(Suppl 3):S91–S119
- Ben Nsir A, Chabaane M, Krifa H, Jeme H, Hattab N. Intracranial angiomatous meningiomas: a 15-year, multicenter study. *Clin Neurol Neurosurg* 2016;149:111–117
- Chiechi MV, Smirniotopoulos JG, Mena H. Intracranial hemangiopericytomas: MR and CT features. *AJNR Am J Neuroradiol* 1996;17 (07):1365–1371
- Meng Y, Chaohu W, Yi L, Jun P, Songtao Q. Preoperative radiologic characters to predict hemangiopericytoma from angiomatous meningioma. *Clin Neurol Neurosurg* 2015;138:78–82
- Louis DN, Perry A, Reifenberger G, et al. The 2016 World Health Organization Classification of Tumors of the Central Nervous System: a summary. *Acta Neuropathol* 2016;131(06):803–820
- Rossitti S. Preoperative embolization of lower-falx meningiomas with ethylene vinyl alcohol copolymer: technical and anatomical aspects. *Acta Radiol* 2007;48(03):321–326
- Szatmáry Z, Hillman J, Finitzis S. Meningioma embolization with the pressure cooker technique using Squid 12. *Interv Neuroradiol* 2017;23(04):441–443
- Shi ZS, Feng L, Jiang XB, Huang Q, Yang Z, Huang ZS. Therapeutic embolization of meningiomas with Onyx for delayed surgical resection. *Surg Neurol* 2008;70(05):478–481
- Akmangit I, Daglioglu E, Kaya T, et al. Preliminary experience with squid: a new liquid embolizing agent for AVM, AV fistulas and tumors. *Turk Neurosurg* 2014;24(04):565–570
- Venturini M, Lanza C, Marra P, et al. Transcatheter embolization with Squid, combined with other embolic agents or alone, in different abdominal diseases: a single-center experience in 30 patients. *CVIR Endovasc* 2019;2(01):8
- Moreno-Paredes S, Rodríguez-Alcalá L, Martín-Lagos Martínez J, et al. Facial palsy after embolization with Squid® 12. *BMC Neurol* 2021;21(01):45
- Hirohata M, Abe T, Fujimura N, Takeuchi Y, Shigemori M. Preoperative embolization of brain tumor with pial artery or dural branch of internal carotid artery as feeding artery. *Interv Neuroradiol* 2006;12(Suppl 1):246–251
- Tikkakoski T, Luotonen J, Leinonen S, et al. Preoperative embolization in the management of neck paragangliomas. *Laryngoscope* 1997;107(06):821–826
- Kim LJ, Albuquerque FC, Aziz-Sultan A, Spetzler RF, McDougall CG. Low morbidity associated with use of n-butyl cyanoacrylate liquid adhesive for preoperative transarterial embolization of central nervous system tumors. *Neurosurgery* 2006;59(01):98–104, discussion 98–104