



Transvaginal Migration of Ventriculoperitoneal Shunts in Children: Review of Literature

Shashikanth R. Ambati¹ Suzanne Barry¹ Adamo A. Matthew² Mary Edwards³

¹Department of Pediatric Critical Care, Albany Medical Center, Albany, New York, United States

²Department of Pediatric Neurosurgery, Albany Medical Center, Albany, New York, United States

³Department of Pediatric Surgery, Albany Medical Center, Albany, New York, United States

Address for correspondence Shashikanth Ambati, MBBS, Pediatric Critical Care, Albany Medical Center, 43 New Scotland Ave, A422, Albany, NY 12208, United States (e-mail: ambatis@amc.edu).

AJNS 2022;17:399–406.

Abstract

Ventriculo-peritoneal shunt placement is the most commonly performed procedure for the treatment of hydrocephalus. The complication of migration of the distal ventriculo-peritoneal shunt is one of the many complications that occur after ventriculo-peritoneal shunt placement. The migration of the ventriculo-peritoneal shunt through the vagina is infrequently reported in children. The aim of this review is to help all the providers caring for children with ventriculo-peritoneal shunts to identify issues early when encountered with this complication and thus limit morbidity and mortality. We reviewed all cases of migration of ventriculo-peritoneal shunt through the vagina in children less than 18 years of age that were published in the literature using PubMed, Google Scholar, Web of Science, and Cochrane Library. A total of 11 articles met the eligibility criteria and were included in this review among the 93 articles obtained with title and abstract screening. Previous non-shunt-related abdominal operations and shunt revisions are consistent risk factors in all cases. We did not recognize specific approaches to catheter placement or management that could have prevented this complication. Ventriculitis necessitating shunt removal and therapies requiring additional procedures and prolonged hospitalization are the major consequences identified. Awareness of this unusual complication is very important among health care providers such as emergency care health providers who are likely to be the first to encounter these children on initial presentation.

Keywords

- ▶ ventriculo-peritoneal shunt
- ▶ VP shunt migration
- ▶ children
- ▶ transvaginal migration
- ▶ fallopian tube

Key Messages

- Migration of the ventriculo-peritoneal shunt through the vagina is infrequently reported in children.
- Clear drainage through the vagina or not getting dry after urinating in a child with ventriculo-peritoneal shunt should be investigated for migration of distal shunt catheter.

- If the catheter appears to be knotted, a combined surgical and neurosurgical approach should be undertaken for effective catheter removal.

Introduction

Ventriculo-peritoneal shunt (VPS) placement is the most commonly performed procedure for the treatment of

DOI <https://doi.org/10.1055/s-0042-1757218>.
ISSN 2248-9614.

© 2022. Asian Congress of Neurological Surgeons. All rights reserved.

This is an open access article published by Thieme under the terms of the Creative Commons Attribution-NonDerivative-NonCommercial-License, permitting copying and reproduction so long as the original work is given appropriate credit. Contents may not be used for commercial purposes, or adapted, remixed, transformed or built upon. (<https://creativecommons.org/licenses/by-nc-nd/4.0/>)

Thieme Medical and Scientific Publishers Pvt. Ltd., A-12, 2nd Floor, Sector 2, Noida-201301 UP, India

hydrocephalus. Shunt malfunction occurs in more than 50% of children within years after placement, with an 80% lifetime risk.¹ Malfunction may be due to obstruction, disconnection, infection, cerebrospinal fluid (CSF) pseudocyst formation, and migration of the catheter.² The migration of the distal VPS catheter outside the peritoneal cavity is rare with most cases reported in pediatric patients and an overall incidence ranging from 1.5 to 10%.^{1,3} Distal shunt erosion into adjacent organs including the intestines, urinary bladder, scrotum, heart, and the abdominal wall is well described. Migration of the VPS through the vagina is rare with published reports in children on only 11 occasions. This review aims to explore the symptoms of presentation, etiology and risk factors, timing, the possible course of migration, management, and complications of transvaginal migration of VPS in children by a detailed review of all published cases to date.

Methods

We reviewed the existing medical literature using PubMed, Google Scholar, Web of Science, and Cochrane Library using the search terms: ventriculo-peritoneal shunt, VP shunt migration, children, transvaginal migration, fallopian tube, uterus (see ► **Appendix**). The literature search was conducted with help of a librarian in October 2020.

Study Selection

Of the cases of VPS migrations that were retrieved, only those that reported the distal VPS migration through the vagina, fallopian tube, or uterus in patients younger than 18 years old were included for review. The articles that mentioned adults, more than 18 years of age, and other genitourinary migration sites such as the anus, scrotum, urinary bladder, or perineum were excluded.

The eligibility screening for the retrieved articles was done by two independent reviewers first at the title and abstract level, and then at the full-text level if potentially relevant. The references of the included articles had been also evaluated and articles that met our criteria were included in the review (► **Fig. 1**).

Results

A total of 203 papers were identified and after the duplicate exclusion, 93 abstracts were screened. Abstracts were evaluated by the first author (SA) and 38 potentially relevant abstracts were selected for full-text review and assessed for eligibility by two authors (SA and SB). Finally, 11 articles were included in the review.

Discussion

Incidence

The overall incidence of migration of distal VPS varies from 1.5% to 10%.^{1,3} A review by Harishchandra et al of 400 cases of shunt migration in both adults and children revealed distal peritoneal catheter migration into the gastrointestinal tract

(35%), abdominal wall (14%), thoracic cavity (8%), cardiac/intravascular (7%), genitourinary system (18%), intracranial (11%), and breast (3%) with the remaining 4% in miscellaneous areas. Of the instances of genitourinary migration, the sites involved were the scrotum (14%) and the bladder or perineum (4%).⁴ A case series by Ezzat et al describes an incidence of 1.5% for the migration of the distal VPS in children less than 12 years of age with the majority migrating to the anus (40%) and scrotum (20%).¹ The most common site for VPS migration in both studies is the gastrointestinal system.^{1,4} Migration of the VPS through the vagina is exceedingly rare, reported in only 3 adult patients and 11 children to date.⁵⁻¹⁷

Etiology and Migration Course

The cause of migration of distal peritoneal catheter and perforation of visceral organs is likely multifactorial. Localized inflammatory foreign body reaction or allergic reaction between the shunt and the peritoneal membrane, pressure necrosis of the visceral organ, peristalsis of bowel loops, abdominal wall contractions, and increased intraabdominal pressure during respiration have been cited as contributing factors.¹⁸ In cases of vaginal migration, the tip of the lower end of the shunt may become adhered to the posterior vaginal wall in the pouch of Douglas due to inflammation and chronic pressure by the stiff and sharp end of the shunt tip. Over time, the continuous hammer effect of CSF pulsation could lead to perforation through the uterus or posterior vaginal wall followed by transvaginal migration.¹² Migration can also occur through the fallopian tube likely from catheter friction against the less-motile fallopian tube and gradual adherence with the formation of a fibrous tract as a result of inflammation.^{13,15} Of the cases reviewed in pediatrics, the authors have described the course of transvaginal migration in only 5 out of 11 cases (► **Table 1**).

Risk Factors

Incomplete or inconsistent data were reported among the 11 pediatric cases to uniformly compare risk factors; however, some similarities give us clues as to the risk factors that may account for the transvaginal migration of a VPS in children. Transvaginal migration of distal VPS seems to be more common in younger children. Among the pediatric cases, 63% (7/11) were less than 2 years old with a mean age of 12 months. An extensive review by Harishchandra et al of nearly 400 cases of migration of all distal VPS revealed 282 patients (71%) who belonged to the pediatric age group. Weaker musculature and smaller volume of the intraperitoneal cavity may be contributing factors explaining the increased incidence in children.

A history of previous abdominal surgeries appears to be another common denominator. Of the nine cases reporting details, 77% (7/9) had a history of one or two shunt revisions that were completed shortly prior to the episode of transvaginal migration. Two cases report nonshunt-related intra-abdominal procedures such as appendectomy and right ovarian cystectomy and laparotomy with adhesiolysis.^{12,13} In these cases, adhesions could have made the shunt tubing

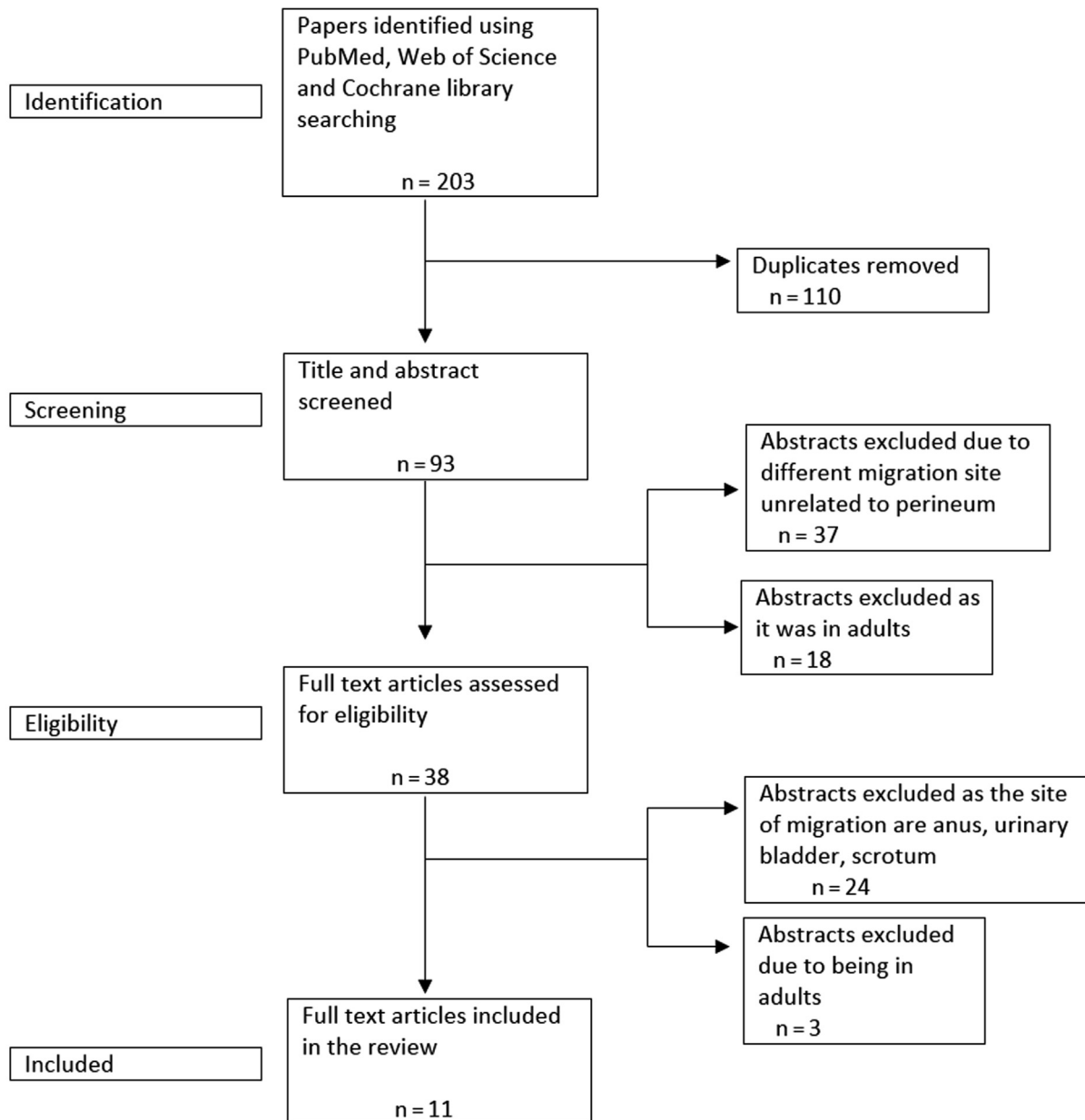


Fig. 1 Flow diagram showing the studies identification and selection

less mobile, promoting adherence to the surrounding structures. Two of the eleven reports had a history of lumbar meningocele, which may have contributed to weaker musculature in the vagina wall.^{9,11}

The type of catheter material has also been implicated in predisposing to migration and perforation in a variety of distal shunt migrations.^{19,20} In the past, Raimondi spring coiled catheters were commonly associated with perforations as reported in the case by Patel et al¹¹ but the introduction of softer and more flexible silastic silicone tubing has reduced, but not eliminated this risk.^{15,20} Rates of distal shunt migration for each type of tubing are not known.

The technique of distal catheter insertion may play a role in distal shunt migration and failure.^{21,22} A systematic

review performed by He et al looking at outcomes based on laparoscopic versus mini-laparotomy peritoneal catheter insertion of VP shunts revealed that laparoscopy-guided placements were associated with a less-frequent occurrence of distal shunt failure (distal shunt failure rate for laparoscopy vs. mini-laparotomy: 3.0% vs. 10.2%, $p = 0.0003$).²¹ No pediatric cases of transvaginal migration reported the technique of distal catheter placement. Controlling the length of the distal catheter during placement may help mitigate the overall risk of migration.²³

Clinical Presentation and Diagnosis

The migration of the distal shunt catheter typically occurs anywhere from hours to years after the placement of the shunt system with most migrations presenting in the first

Table 1 Summary of all cases of transvaginal migration in children

Cases (N = 11)	Age	Symptoms	Time of migration since the VP shunt placement	Risk factors	Possible course of migration	CSF culture	VP shunt catheter material	Technique of distal catheter placement	Complications
Patel et al 1973	11 months	Vomiting, stiff neck, and fever	4 months	Lumbar myelomeningocele One shunt revision in the past	Posterior vaginal wall	Enterococci	Raimondi Catheter	Not described	Shunt revision done in another session
Washington et al 2002	16 years	Headache, abdominal pain, clear vaginal discharge	15–18 months	Appendectomy, right ovarian cystectomy, two shunt revisions	Distal end stuck in the right fallopian tube with cystic loculation	Negative	Not reported	Not described	Laparoscopic salpingectomy and no shunt revision needed
Farrokhi et al 2007	16 months	Foreign body with VPS protruding through the vagina	6 months	Myelomeningocele One shunt infection with revision in the past	Posterior aspect of bladder down to cul-de-sac and posterior wall of vagina	Not reported	Not reported	Not described	Not reported
Atlas et al 2012	14 months	Asymptomatic VP shunt tube extruding through the vagina	2 months	Prematurity and one shunt revision in the past	Not described	Negative	Not reported	Not described	Shunt revision done in another session
Teegala et al 2012	6 months	Fever, neck, rigidity, and VP shunt tube protruding through the vagina	2 months	Dandy–Walker malformation No shunt revisions	Not described	Negative	Not reported	Not described	Required endoscopic third ventriculostomy
Poillblanc et al 2012	17 years	Recurrent watery vaginal discharge	2 months	Porencephalic cyst Cysto-peritoneal shunt Multiple shunt revisions Laparotomy with adhesion lysis 2 months prior	Perforation through the uterus	Negative	Not reported	Laparotomy	The uterine defect did not require any repair Cystoatral shunt was placed
Lofinia et al 2016	24 months	Asymptomatic VP shunt tube protruding through the vagina	21 months	One shunt revision	Not described	Negative	Not reported	Not described	Received antibiotics for one week Shunt revision done in the same session
Chugh et al 2018	6 months	Asymptomatic with shunt tube protruding through the vagina	2 months	None	Not described	Negative	Not reported	Not described	Endoscopic third ventriculostomy
Chugh et al 2018	8 months	Asymptomatic with shunt tube protruding through the vagina	3 months	None	Not described	Negative	Not reported	Not described	Revision done in another session
Korulmaz et al 2019	16 years	Vomiting and foreign body in the vagina	6 months	Colostomy for anal atresia One shunt revision in the past	Not described	Not reported	Not reported	Not described	Not reported
Lord et al 2020	6 years	White rubbery tube protruding from the vagina draining clear liquid	3 years	No shunt revisions in the past	Through the fallopian tube, uterus, and exit through the vagina	Streptococcus anginosus	Silicon (Medtronic)	Mini laparotomy	Spontaneous coiling Asymptomatic ventriculitis requiring prolonged antibiotic course Shunt revision in another session

year, beyond which the chances of migration decrease gradually.^{3,21} In this review of transvaginal migration in children, the time of migration ranged from 2 months to 3 years of last shunt revision or initial placement of VPS, with 90% (10/11) of them occurring within an average of 6.3 months.

VPS malfunction can present in a myriad of ways such as headache, fever, vomiting, and abdominal pain but can also be asymptomatic. The majority of the cases of transvaginal migration presented with no symptoms aside from the extrusion of the shunt tubing itself or leaking of clear fluid from the vagina. The diagnosis of transvaginal migration is typically straightforward when the patients present with the catheter protruding out through the vagina. Extrusion of the shunt through the vagina can be at risk of infection by the urogenital or GI flora as it is close to the perineum and can present with signs of meningitis.¹¹ In one case of asymptomatic presentation, there was culture-positive cerebrospinal fluid (CSF).¹⁵ Infectious complications must be considered in all cases of distal VP shunt migration outside the peritoneum and especially with exposure to the external environment.

If the presenting symptoms are abdominal pain and/or profuse clear vaginal discharge in a patient with VPS, a careful urogenital examination must be performed and imaging may be required with shunt malfunction as part of the differential diagnosis until malpositioning of the distal shunt has been ruled out. X-ray abdomen or shunt series can be a useful test that can demonstrate the location of the distal shunt. Failure to consider this diagnosis can result in a delay in diagnosis as seen in the case by Washington et al where the distal shunt was stuck in the omentum or surrounding structures causing leakage of CSF from the vagina but not full extrusion of the shunt itself.¹³

Lord et al described the utility of ultrasound in these situations showing the VPS catheter traversing a hypoechoic fluid-filled cavity, while Washington et al questioned the specificity of the range of ultrasound when there are several small adnexal structures obscuring the catheter tip.^{13,15} Poillblanc et al described the utility of transvaginal ultrasound for a catheter that has perforated the uterus but not extruded the vagina by identifying the tip of the catheter in the uterus.¹² Computerized tomographic imaging can help to delineate VPS location with drawbacks of radiation exposure and the possible need for sedation in young children. If an abnormal connection between the VPS and the genitourinary structures is a concern and there is no transvaginal migration, the clear vaginal discharge can be tested for β -2 transferrin, a specific protein found only in CSF.

Management

The standard method of treatment in any shunt migration would be the removal of the extruded shunt followed by shunt repositioning or other CSF diversion procedures either immediately or after controlling any infection with a course of antibiotics. In some cases, repair of a defect in the organs penetrated by the distal shunt is required.

Most children with transvaginal migration (63%) required replacement of the VPS in another session after the perito-

neal inflammation or infection subsided and none of the patients required repair of affected viscera. Two of the patients had the shunt replaced in the same session as there was no concern for infection.^{8,13} The disconnection and removal of the migrated distal catheter can be performed by pulling the shunt from the extrusion site after dividing the shunt intra-abdominally either through a laparoscopic incision or an exploratory laparotomy, followed by externalization of the proximal shunt. Blindly pulling the shunt from the extrusion site can be difficult and dangerous, especially when there is coiling or twisting of the catheter around bowel loops or other structures.^{24,25} This can be avoided by careful review of the shunt course with an abdominal X-ray to ensure sure there is no knotting or extensive looping in the abdomen prior to the surgery. If there is knotting noted on the X-ray (**Fig 2**), care should be taken to involve pediatric surgery for laparotomy or laparoscopic removal of the migrated distal shunt by relieving the knot. Removal of the entire shunt may be required in cases of positive cerebrospinal fluid cultures with the temporary placement of an external ventricular drain until the infection clears.

For high-risk or documented infections, the timing of shunt replacement is variable. Treatment time is often guided by cultures of cerebrospinal fluid, which should be negative for several days before the shunt revision is planned.²⁶ Of the documented pediatric cases, one had the shunt revised in the same session but was given prophylactic antibiotics for 1 week.⁸ Another case also had only one surgical intervention with no shunt revision required because the distal shunt was never extruded but rather was stuck in the fallopian tube.¹³ In seven of the nine cases that reported follow-up, replacement of the shunt or endoscopic third ventriculostomy was required later after a course of antibiotics. Upon replacement, a new distal site other than

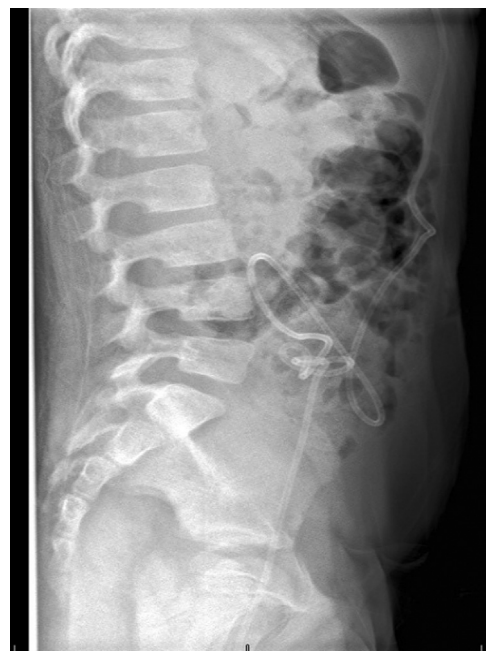

Fig. 2 X-ray lateral decubitus position showing the loop in the right side of the abdomen. Image courtesy Lord et al¹⁵.

the peritoneum should be considered depending on risk factors for recurrence (i.e., adhesions). For initial and repeat VPS placement, consideration should be given to using mini-laparotomy or other newer laparoscopic procedures to decrease the risk of distal shunt migration.²² To prevent further migration of the distal VPS in the future, endoscopic third ventriculostomy can also be considered, if possible.^{14,16}

Complications

There can be significant morbidity associated with the migration of the distal VPS due to several complications. There are no deaths reported for any of the reported cases of transvaginal distal shunt migration. However, migration of a VPS typically requires multiple operative interventions and thus multiple anesthetics. Revision of the shunt is almost always needed in cases of transvaginal migration. The majority of children in this review required the shunt to be revised or replaced and two underwent endoscopic third ventriculostomy.

Regardless of the site, any extrusion of the shunt with exposure to the external environment is associated with an approximate 50% chance of shunt infection.⁴ Among the reported pediatric cases, two of nine (with two cases not reporting culture data) reported positive CSF cultures with enterococci and *Streptococcus anginosus*. Exposure to the outside environment and being near the urogenital and GI areas likely put transvaginal migrations at a higher risk for infections. If there is a documented CSF infection, the current guidelines recommend removing the VPS until CSF cultures clear, often requiring an external ventricular drain (EVD) to manage the hydrocephalus while awaiting resolution.²⁶ To achieve this, a prolonged hospital stay is needed to control the infection with the placement of a peripherally inserted central catheter (PICC) for long-term antibiotic administration. Finally, there can be delayed peritonitis resulting in significant adhesions requiring adhesiolysis prior to shunt reinsertion.

During transvaginal migration of VPS, the distal catheter can erode into the posterior vaginal wall, uterus, or fallopian tube. Laparoscopy is usually recommended in cases of distal catheter migration to visualize the defect and determine if it requires repair. Occasionally, the defect can be left alone to close by itself such as small uterine defects due to the muscular nature of the uterine tissue.¹² If the urinary bladder wall is affected, cystoscopy must be performed with methylene blue instilled into the bladder to visualize any urine extravasation into the peritoneal cavity.

In two pediatric cases, the VPS entered the fallopian tube, and one required salpingectomy.^{13,15} It is unclear if these complications could have an effect on future fertility or create an increased risk of ectopic pregnancy. Gynecologic follow-up may be warranted for further workup and monitoring.

Conclusion

VPS placement is a well-established procedure frequently employed in the management of hydrocephalus. Although

the placement of a VPS is a common procedure and considered safe, 70 to 80% of the patients require at least 1 revision at some point in their lives. Migration of the distal shunt seems to occur more commonly in children than adults. In rare cases of transvaginal migration, we identified that previous nonshunt-related abdominal operations and shunt revisions are consistent risk factors. We did not recognize specific approaches to catheter placement or management that could have prevented this complication. Ventriculitis necessitating shunt removal and therapies requiring additional procedures and prolonged hospitalization are the major consequences identified. Awareness of this unusual complication is very important among health care providers taking care of children with VPS, especially general pediatricians and emergency care health providers who are likely to be the first to encounter these children on initial presentation. This review helps to raise awareness for early recognition and management of transvaginal migration, which could limit complications and be potentially lifesaving.

Authors' Contributions and Summary

Shashikanth R Ambati and Suzanne Barry contributed to the study conceptualization, design, definition of intellectual content, literature research, manuscript preparation, manuscript editing, and reviewing and served as the guarantor. Adamo A Matthew and Edwards Mary contributed to study conceptualization, design, the definition of intellectual content, manuscript preparation, manuscript editing and reviewing and served as the guarantor.

Shashikanth Ambati has been working in the Pediatric Critical Care unit for nearly 9 years and was taking care of postoperative neurosurgical patients with ventriculoperitoneal shunts. He has written papers and reviewed journals. Suzanne Barry has been working in the Pediatric Critical Care Unit for 7 years and had been taking care of post-operative neurosurgical patients with ventriculoperitoneal shunts. She has been very involved with resident education and publishing papers. Matthew Adamo has been working as a Pediatric neurosurgeon for more than 12 years and has operated on a variety of neurosurgery cases in children and has published very extensively in the field of pediatric neurosurgery. Mary Edwards has been working as a pediatric surgeon for more than 18 years and has taken care of many children requiring surgical procedures and had extensive expertise in pediatric trauma.

Funding

None.

Conflict of Interest

None declared.

References

- 1 Ezzat AAM, Soliman MAR, Hasanain AA, et al. Migration of the distal catheter of ventriculoperitoneal shunts in pediatric age group: case series. *World Neurosurg* 2018;119:e131–e137

- 2 Bober J, Rochlin J, Marneni S. Ventriculoperitoneal shunt complications in children: an evidence-based approach to emergency department Management. *Pediatr Emerg Med Pract* 2016;13(02):1–22, quiz 22–23
- 3 Kanojia R, Sinha SK, Rawat J, Wakhlu A, Kureel S, Tandon R. Unusual ventriculoperitoneal shunt extrusion: experience with 5 cases and review of the literature. *Pediatr Neurosurg* 2008;44(01):49–51
- 4 Harischandra LS, Sharma A, Chatterjee S. Shunt migration in ventriculoperitoneal shunting: a comprehensive review of literature. *Neurol India* 2019;67(01):85–99
- 5 Bonfield CM, Weiner GM, Bradley MS, Engh JA. Vaginal extrusion of a ventriculo-peritoneal shunt catheter in an adult. *J Neurosci Rural Pract* 2015;6(01):97–99
- 6 Houten JK, Smith S, Schwartz AY. Vaginal migration of ventriculoperitoneal shunt catheter and cerebrospinal fluid leak as a complication of hysterectomy. *World Neurosurg* 2017;104:1046.e13–1046.e14
- 7 Mazingo JR, Cauthen JC. Vaginal perforation by a Raimondi peritoneal catheter in an adult. *Surg Neurol* 1974;2(03):195–196
- 8 Lotfinia I, Tubbs S, Mahdkhah A. Vaginal extrusion of a ventriculoperitoneal shunt: a case report and review of literature. *J Pediatr Adolesc Gynecol* 2017;30(01):e23–e25
- 9 Farrokhi M, Tavallae G. Unusual migration of the distal catheter of a ventriculoperitoneal shunt into the vagina. *Iran J Med Sci* 2007;32(03):182–184
- 10 Altas M, Tutanc M, Aras M, Altas ZG, Arica V. Vaginal perforation caused by distal tip of ventriculoperitoneal shunt: report of a rare complication, in Pakistan. *Journal of Medical Sciences* 2012
- 11 Patel CD, Matloub H. Vaginal perforation as a complication of ventriculoperitoneal shunt. Case report. *J Neurosurg* 1973;38(06):761–762
- 12 Poilblanc M, Sentilhes L, Mercier P, Lefèbvre C, Descamps P. Uterine perforation by a cystoperitoneal shunt, an unusual cause of recurrent vaginal discharge. *J Obstet Gynaecol Can* 2012;34(01):63–65
- 13 Washington EC, Holmes M, Haines SJ, Ringwood JW. Ventriculoperitoneal shunt migration presenting with vaginal discharge and hydrosalpinx in a 16-year-old patient. *Pediatr Emerg Care* 2002;18(01):28–30
- 14 Teegala R, Kota LP. Unusual complications of ventriculo peritoneal shunt surgery. *J Neurosci Rural Pract* 2012;3(03):361–364
- 15 Lord S, Robinson T, Spurgas M. Ventriculoperitoneal shunt migration with vaginal extrusion via the fallopian tube. *J Pediatr Surg Case Rep* 2020;57:101468
- 16 Chugh A, Gotecha S, Amle G, Patil A, Punia P, Kotecha M. Abnormal migration and extrusion of abdominal end of ventriculoperitoneal shunt: an experience of eight cases. *J Pediatr Neurosci* 2018;13(03):317–321
- 17 Korulmaz A, Alakaya M, Kaya S, Hamzaoglu V, Tezol Ö, Arslan-köylü AE. A rare cause of vaginal foreign body: ventriculoperitoneal shunt migration. *J Pediatr Neurosci* 2019;14(02):109
- 18 Shahsavarani S, Kermani HR, Keikhosravi E, Nejat F, El Khashab M. Ventriculoperitoneal shunt migration and coiling: a report of two cases. *J Pediatr Neurosci* 2012;7(02):114–116
- 19 Soufiany I, Hijrat KA, Soufiany S, Chen L. Mechanisms and major sites of distal catheter migration in ventriculoperitoneal shunting maneuvers: a review article. *Brain Science Advances* 2018;4(02):141–155
- 20 Guthe SP, Pravin S, Darade P, Velho V. Silent migration of ventriculoperitoneal shunt per anus in a child: management and review of literature. *Asian J Neurosurg* 2018;13(02):446–448
- 21 He M, Ouyang L, Wang S, Zheng M, Liu A. Laparoscopy versus mini-laparotomy peritoneal catheter insertion of ventriculoperitoneal shunts: a systematic review and meta-analysis. *Neurosurg Focus* 2016;41(03):E7
- 22 Park YS, Park IS, Park KB, Lee CH, Hwang SH, Han JW. Laparotomy versus laparoscopic placement of distal catheter in ventriculoperitoneal shunt procedure. *J Korean Neurosurg Soc* 2010;48(04):325–329
- 23 Xu S, Sheng W, Qiu Y, Wang J. An unusual complication of ventriculoperitoneal shunt: urinary bladder stone case report and literature review. *Iran Red Crescent Med J* 2016;18(01):e26049
- 24 Borcek AO, Civi S, Golen M, Emmez H, Baykaner MK. An unusual ventriculoperitoneal shunt complication: spontaneous knot formation. *Turk Neurosurg* 2012;22(02):261–264
- 25 Starreveld Y, Poenaru D, Ellis P. Ventriculoperitoneal shunt knot: a rare cause of bowel obstruction and ischemia. *Can J Surg* 1998;41(03):239–240
- 26 Tunkel AR, Hasbun R, Bhimraj A, et al. 2017 Infectious Diseases Society of America's Clinical Practice Guidelines for healthcare-associated ventriculitis and meningitis. *Clin Infect Dis* 2017;64(06):e34–e65

Appendix

Search Strategies

• PubMed

"Ventriculoperitoneal Shunt"[Mesh] OR ventriculoperitoneal shunt OR ventriculoperitoneal shunts OR ventriculoperitoneal shunt OR ventriculo-peritoneal shunts OR VP shunt OR VP shunts

AND

migration OR migrate OR migrates

AND

transvaginal OR trans vaginal OR distal OR vagina OR vaginal OR uterus OR uterine OR fallopian

AND

child OR children OR infant OR infants OR newborn OR newborns OR neonate OR neonates OR toddler OR toddlers OR pediatric OR paediatric OR teenager OR teenagers OR adolescent OR adolescents OR adolescence OR girl OR girls OR boy OR boys

AND

English

• Web of Science

TOPIC: [ventriculoperitoneal shunt* OR ventriculo-peritoneal shunt* OR VP shunt*]

AND

TOPIC: [migrat*]

AND

TOPIC: [transvaginal OR trans vaginal OR distal OR vagina OR vaginal OR uterus OR uterine OR fallopian]

AND

TOPIC: [child* OR infant* OR newborn* OR neonat* OR toddler* OR pediatric* OR paediatric* OR teenager* OR girl* OR boy*]

Refined by: Languages: English

• Cochrane Library

ventriculoperitoneal shunt* OR ventriculo-peritoneal shunt* OR VP shunt*

AND

migrat*

AND

transvaginal OR trans vaginal OR distal OR vagina OR vaginal OR uterus OR uterine OR fallopian

AND

child* OR infant* OR newborn* OR neonat* OR toddler* OR pediatric* OR paediatric* OR teen* OR adoles* OR girl* OR boy*

There was no filter for English language

• Google Scholar

With at least one of the words – ventriculo-peritoneal shunt OR VP shunt OR migration OR vagina OR uterus OR fallopian tube OR transvaginal OR child OR Pediatric

Articles dated between – 1960-2020