



Postnatal Posterior Fossa Arachnoid Cyst: A Developmental Etiology to Be Considered

Thiynesvaran Ramachandran¹ Vijayan Valayatham² Dharmendra Ganesan¹

¹Division of Neurosurgery, Department of Surgery, University of Malaya, Kuala Lumpur, Malaysia

²Fetal Medicine Unit, Aseana O&G Specialist Clinic, Kuala Lumpur, Malaysia

Address for correspondence Dharmendra Ganesan, MS, FRCS, Division of Neurosurgery, Department of Surgery, University of Malaya, 50603 Kuala Lumpur, Malaysia (e-mail: dharmendra@um.edu.my).

AJNS 2022;17:676–679.

Abstract

Keywords

- ▶ posterior fossa arachnoid cyst
- ▶ fetal ultrasound
- ▶ arachnoid cyst
- ▶ pathogenesis
- ▶ acquired
- ▶ congenital

Intracranial arachnoid cyst is the most common cystic congenital anomaly in the brain. In this study, we discuss a pregnancy that had serial fetal ultrasound scans throughout the pregnancy and a fetal anomaly scan at 24 weeks of gestation that was normal. The child was born healthy with normal development, but 12 months onward the head began to enlarge. The magnetic resonance imaging of the brain showed a large posterior fossa arachnoid cyst with hydrocephalus. We discuss the postulation to explain this pathogenesis of the cyst. This case highlights that not all symptomatic arachnoid cysts are congenital despite the manifestation being as early as infancy.

Introduction

Intracranial arachnoid cyst is the most common cystic congenital anomaly in the brain.^{1–5} The prevalence and natural history of arachnoid cyst in children are ambiguous.^{1,3–5} With the increased use of magnetic resonance imaging (MRI) and computed tomography (CT) imaging, there has been a corresponding rise in the number of incidental discoveries of arachnoid cysts.⁶ Studies have proposed that the pediatrics population has a prevalence rate of 2.6%.⁶ In addition, a male predominance with a male to female ratio: 2:1 is noted in the pediatrics community.^{2,6,7} We describe a case of a large symptomatic posterior fossa arachnoid cyst with hydrocephalus manifesting at the age of 18 months. Incidentally, the series of antenatal ultrasound scans were normal. We intend to discuss the pathogenesis of arachnoid cyst.

Case Report

A healthy 33-year-old woman was into her first pregnancy. She was diagnosed with gestational diabetes in the third trimester managed throughout with dietary and lifestyle adjustments. Antenatally, the fetus was monitored with serial ultrasound scans that showed normal growth velocity. The serial ultrasound scans between 10 and 38 weeks of gestation demonstrated biparietal diameter corresponding to gestational age (▶ **Table 1**). She had a fetal anomaly scan at 24 weeks, 5 days that was reported normal. The central nervous system structures were visualized noted to be normal (▶ **Fig. 1**). The other systemic organs and the cerebellum and ventricles were reported to be normal (▶ **Fig. 2**).

A healthy baby boy was born via spontaneous vaginal delivery at 38 weeks of gestation with an APGAR

article published online
October 28, 2022

DOI <https://doi.org/10.1055/s-0042-1757223>.
ISSN 2248-9614.

© 2022. Asian Congress of Neurological Surgeons. All rights reserved.

This is an open access article published by Thieme under the terms of the Creative Commons Attribution-NonDerivative-NonCommercial-License, permitting copying and reproduction so long as the original work is given appropriate credit. Contents may not be used for commercial purposes, or adapted, remixed, transformed or built upon. (<https://creativecommons.org/licenses/by-nc-nd/4.0/>)

Thieme Medical and Scientific Publishers Pvt. Ltd., A-12, 2nd Floor, Sector 2, Noida-201301 UP, India

Table 1 A normal fetal growth assessed under ultrasound imaging antenatally

| Date of scan | Gestational age | Arm circumference | Corresponding value | Biparietal diameter, cm | Corresponding value | Femur length | Corresponding value |
|--------------|-----------------|-----------------------------|---------------------|-------------------------|---------------------|--------------|---------------------|
| 23/05/2019 | 10W 5D | Crown-rump length (CRU), cm | | | | | |
| | | 3.77 | | | | | |
| 07/06/2019 | 12W 4D ± 2D | 6.32 | | | | | |
| 05/07/2019 | 16W 5D | 11.30 | 17W 1D ± 12D | 3.57 | 17W 0D ± 9D | 2.19 | 16W 4D ± 10D |
| 02/08/2019 | 21W 0D | 15.74 | 20W 6D ± 15D | 5.06 | 21W 2D ± 12D | 3.24 | 20W 1D ± 13D |
| 28/09/2019 | 28W 6D | 23.62 | 28W 0D ± 16D | 7.63 | 30W 4D ± 22D | 5.26 | 28W 0D ± 15D |
| 12/10/2019 | 32W 3D | 28.09 | 32W 1D ± 21D | 8.20 | 33W 0D ± 22D | 5.86 | 30W 4D ± 21D |
| 26/10/2019 | 34W 2D | 28.68 | 32W 5D ± 21D | 8.54 | 34W 3D ± 22D | 6.20 | 32W 1D ± 21D |
| 09/11/2019 | 36W 1D | 32.25 | 36W 1D ± 21D | 8.74 | 35W 2D ± 22D | 6.97 | 35W 5D ± 21D |

Abbreviations: D, days, W, weeks.

(appearance, pulse, grimace, activity, and respiration) score of 10 at 1 and 5 minutes. The delivery was uneventful. The birth weight was 3.15 kg. The head circumference was 33 cm that was within the normal range (► **Supplementary Fig. S1**; available in the online version only). He was a healthy child and developing as per the chronological milestones. From the age of 12 months onward, he was detected to have a rapid rise in head circumference over the subsequent 6 months (► **Supplementary Fig. S1**). He had some delay in the gross motor milestone; at the age of 18 months, he could not walk independently. The eye movements were normal. There was some speech delay as at the age of 18 months, he could only manage to say some monosyllabic words example “mama” and “bye” and still uses nonverbal gestures. The hearing assessment was normal. There is no history of meningitis or any form of head injury.

An MRI brain was performed at 18 months of age. It showed a large retrocerebellar cyst with the dimension of 7.6 × 7.3 × 10.5 cm which was causing significant hydrocephalus. The vermis of the cerebellum was present (► **Fig. 3**). The radiological diagnosis was befitting a large retrocerebellar arachnoid cyst. The possible differential diagnosis to be considered includes Blake’s pouch cyst, Dandy-Walker variant, and epidermoid cyst. Mega cisterna magna typically does not cause hydrocephalus.

Given the symptomatic nature of the arachnoid cyst, the child had stereotactic endoscopic fenestration of the cyst into the right lateral ventricle via a frontal burr hole and a third ventriculostomy. The content of the cyst at fenestration was the cerebrospinal fluid. The surgery was uneventful. Three months after the surgery, the child had started to walk independently, and his speech improved with the utilization

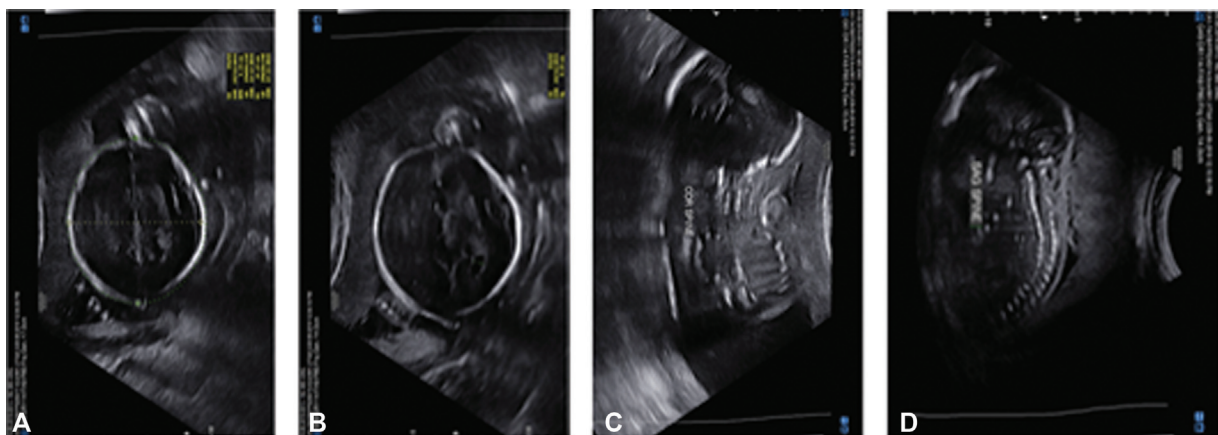


Fig. 1 The fetal anomaly ultrasound scans performed at 24 weeks of gestation showed a normally developing brain (A and B—axial view, C—coronal view, and D—sagittal view).

| | | | | | | |
|---|----|-------|---|------|-----|------------|
| Expected Gestational age by LMP/previous scan | 24 | Weeks | 5 | Days | EDD | 14.12.2019 |
| Gestational age by u/s today | 24 | Weeks | 5 | Days | EDD | 14.12.2019 |

Presentation : -
 Fetal Lie : Transverse
 Placenta location : Right Lateral
 Placenta Previa : Type II
 Liquor : Adequate

| | | | |
|--------------------|-----|-----------------------------------|-----|
| CNS SYSTEMS | | CARDIOVASCULAR & CHEST | |
| Falx | / / | 4 chamber heart | / / |
| Cavum Septum | / / | IVS | / / |
| Ventricles | / / | RVOT | / / |
| Cerebellum | / / | LVOT | / / |
| Choroid Plexus | / / | 3V VIEW | / / |
| Cisterna Magna | / / | AO ARCH | / / |
| Nuchal fold | / / | DUCTAL ARCH | / / |

| | | | |
|----------------|-----|--------------------|-----|
| ABDOMEN | | BONES | |
| Abdomen wall | / / | Spine | / / |
| Diaphragm | / / | RT Upper limbs (3) | / / |
| Stomach | / / | LT Upper limbs (3) | / / |
| Bladder | / / | Rt fingers | / / |
| Small bowel | / / | Lt fingers | / / |
| 3 vessels cord | / / | Rt Lower limbs (3) | / / |
| Cord Insertion | / / | Lt Lower limbs (3) | / / |
| Rt kidney | / / | Rt foot | / / |
| Lt kidney | / / | Lt foot | / / |

| | | | | |
|--------------|-----|------------|-------|-----|
| FACE | | Heart Rate | 154 | bpm |
| BOD | / / | AFI | 18.17 | cm |
| IOL | / / | Gender | MALE | |
| Nasal Bone | / / | | | |
| Lips | / / | | | |
| Palate & Jaw | / / | | | |

Fig. 2 The detailed ultrasound report at 24 weeks of gestation.

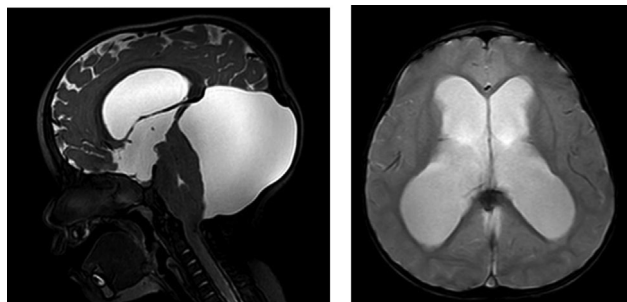


Fig. 3 Sagittal and axial magnetic resonance imaging (T2 weighted) showing the retrocerebellar arachnoid cyst (7.6 × 7.3 × 10.5 cm) with hydrocephalus.

of at least 10 words in the vocabulary. The MRI brain 3 months later showed a smaller arachnoid cyst and ventricles (– Fig. 4).

Discussion

Arachnoid cysts are mostly described as congenital lesions. Most cases are asymptomatic and are detected while performing a workup for other cranial indications, for example, headaches, developmental delay, or raised head circumference.^{1,8} There are cases detected incidentally during workup for seizure or trauma. Arachnoid cyst can be acquired secondary to head trauma, brain infection, or postcranial surgery. Retrospective studies of arachnoid cyst prevalence do not differentiate between congenital and acquired arachnoid cysts, but acquired cysts are believed to be a minority of cases.^{1,8,9} In a few studies in English literature, there were reported subjects with prior

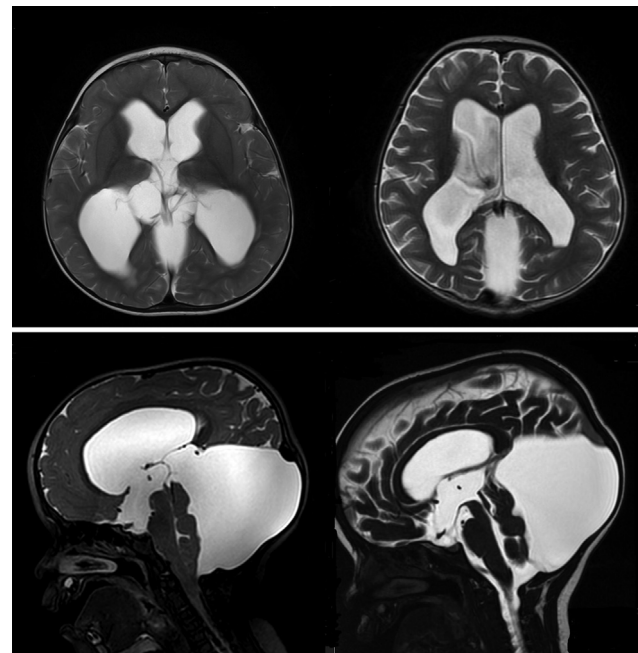


Fig. 4 The magnetic resonance imaging T2-weighted images (axial above and mid-sagittal below) showing the preoperative images on the left and the postoperative images performed 3 months after surgery on the right side for comparison. The ventricles are smaller with more prominent sulci. The floor of the third ventricle has more definition, and the aqueduct of Sylvius is open. The retrocerebellar cyst is also smaller.

normal CT brain imaging presenting later with a de novo suprasellar arachnoid cyst.^{7,10}

The long-term behavior of the cyst is variable as there are reported cases of arachnoid cysts that become larger or smaller, and, in some cases, it resolves spontaneously.^{1,11,12} Symptomatic arachnoid cysts can be surgically treated with endoscopic fenestration, craniotomy for fenestration, or shunt placement, but these surgeries are associated with potential morbidities.^{12–18} In a study on 111 patients with asymptomatic intracranial arachnoid cyst who had undergone MRI follow-up for more than 5 months without treatment, approximately 10% (11 cases) increased in size, 12% (13 cases) decreased in size, and 78% (87 cases) remained stable after 3.5 years.¹ The mean age group of the cohort is 6.4 years.¹ Symptom attributed to the enlargement of cyst only developed in three patients, and they opted for surgical treatment.¹ In another retrospective study, out of 309 patients with asymptomatic intracranial arachnoid cyst who underwent follow-up, only 6.8% (21 cases) patients developed symptoms and underwent surgical treatment.¹ The natural history of the arachnoid cyst is mostly quiescent and asymptomatic.

This case adds to the body of literature that not all arachnoid cysts detected at infancy should be categorized as congenital lesions. The series of ultrasounds from 10 to 38 weeks of gestation did not detect an abnormal change in the cranial biometric measurements. The fetal anomaly ultrasound scan at 24 weeks of gestation did not detect any hydrocephalus or cerebellar cyst. The child began to

manifest symptoms at 12 months of age, and this was monitored. However, the diagnosis of the arachnoid cyst was clinched at the age of 18 months. Therefore, this case highlights that detection of an arachnoid cyst in infancy is not synonymous with a congenital lesion. The case illustrates that the arachnoid cyst or the secondary effects of the arachnoid cyst, e.g., hydrocephalus, were not present antenatally. Therefore, two postulations can be entertained. The first postulation is a de novo formation of the arachnoid cyst after birth indicating an acquired phenomenon. The second postulation would be there could have been a small cyst that was present antenatally, but it was not visible as an anomaly during the fetal anomaly scan. This could mean the progression of the cyst to become symptomatic is a developmental process rather than a congenital manifestation. This case highlights that not all symptomatic arachnoid cyst is congenital despite the manifestation being as early as infancy.

In the context of many Asian countries, the insurance policies would not cover diseases and malformation that are deemed to have occurred during gestation (congenital). As a result, it is important to make the distinction if a cystic brain lesion is acquired or a congenital lesion. This case report shows a large cyst with secondary changes during childhood is not synonymous with a congenital lesion. A de novo formation of the cyst or developmental progression of the cyst is a possibility. By virtue of that, some of these patients should be able to make an insurance claim for surgical treatment. Therefore, the fetal anomaly scan detailing the central nervous system would potentially be an important investigation to prove whether a postnatal lesion is a congenital or acquired lesion.

Conclusion

This case report adds to the body of evidence on the pathogenesis of arachnoid cyst. It highlights that not all arachnoid cysts detected in childhood are congenital. The cyst could be a de novo formation after birth or a developmental process with the progression of a small arachnoid cyst to become symptomatic.

Funding

None.

Conflict of Interest

None declared.

References

- Al-Holou WN, Yew AY, Boomsaad ZE, Garton HJL, Muraszko KM, Maher CO. Prevalence and natural history of arachnoid cysts in children. *J Neurosurg Pediatr* 2010;5(06):578–585
- Singaravelu M, Ramakrishnan S, Gopalakrishnan L. Arachnoid cyst—institutional experience. *Indian J Neurosurg* 2019;8(01):20–24
- Schachenmayr W, Friede RL. Fine structure of arachnoid cysts. *J Neuropathol Exp Neurol* 1979;38(04):434–446
- Pathogenesis of intracranial arachnoid cysts - PubMed. Accessed July 6, 2022 December 4, 2021. <https://pubmed.ncbi.nlm.nih.gov/625699/>
- Starkman SP, Brown TC, Linell EA. Cerebral arachnoid cysts. *J Neuropathol Exp Neurol* 1958;17(03):484–500
- Al-Holou WN, Terman S, Kilburg C, Garton HJL, Muraszko KM, Maher CO. Prevalence and natural history of arachnoid cysts in adults. *J Neurosurg* 2013;118(02):222–231
- Invergo D, Tomita T. De novo suprasellar arachnoid cyst: case report and review of the literature. *Pediatr Neurosurg* 2012;48(03):199–203
- Choi JU, Kim DS. Pathogenesis of arachnoid cyst: congenital or traumatic? *Pediatr Neurosurg* 1998;29(05):260–266
- Sato K, Shimoji T, Yaguchi K, Sumie H, Kuru Y, Ishii S. Middle fossa arachnoid cyst: clinical, neuroradiological, and surgical features. *Child's brain* 1983;10(05):301–316. Doi: 10.1159/000120129
- Kumagai M, Sakai N, Yamada H, et al. Postnatal development and enlargement of primary middle cranial fossa arachnoid cyst recognized on repeat CT scans. *Child's nervous system: ChNS: official journal of the International Society for Pediatric Neurosurgery* 1986;2(04):211–215. Doi: 10.1007/BF00706815
- Oberbauer RW, Haase J, Pucher R. Arachnoid cysts in children: a European co-operative study. *Child's nervous system: ChNS: official journal of the International Society for Pediatric Neurosurgery* 1992;8(05):281–286. Doi: 10.1007/BF00300797
- Struck AF, Murphy MJ, Iskandar BJ. Spontaneous development of a de novo suprasellar arachnoid cyst. Case report. *Journal of neurosurgery* 2006;104(6 Suppl):426–428. Doi: 10.3171/PED.2006.104.6.426
- Santamarta D, Aguas J, Ferrer E. The natural history of arachnoid cysts: endoscopic and cine-mode MRI evidence of a slit-valve mechanism. *Minimally invasive neurosurgery: MIN* 1995;38(04):133–137. Doi: 10.1055/S-2008-1053473
- Weber R, Voit T, Lumenta C, Lenard HG. Spontaneous regression of a temporal arachnoid cyst. *Child's nervous system: ChNS?: official journal of the International Society for Pediatric Neurosurgery* 1991;7(07):414–415. Doi: 10.1007/BF00304210
- Caemaert J, Abdullah J, Calliauw L, Carton D, Dhooge C, van Coster R. Endoscopic treatment of suprasellar arachnoid cysts. *Acta Neurochir (Wien)* 1992;119(1–4):68–73
- Cincu R, Agrawal A, Eiras J. Intracranial arachnoid cysts: current concepts and treatment alternatives. *Clin Neurol Neurosurg* 2007;109(10):837–843
- Özek MM, Urgan K. Neuroendoscopic management of suprasellar arachnoid cysts. *World Neurosurg* 2013;79(2, Suppl):19.e13–19.e18
- Shim KW, Lee YH, Park EK, Park YS, Choi JU, Kim DS. Treatment option for arachnoid cysts. *Childs Nerv Syst* 2009;25(11):1459–1466