



# Outcome of Long-Segment Fixation versus Inclusion of the Fractured Level in Short-Segment Fixation for Thoracolumbar Junction Fractures

Eslam El Sayed El Khateeb<sup>1</sup> Ahmed G. Tammam<sup>1</sup> Ali R. Hamdan<sup>1</sup>

<sup>1</sup>Faculty of Medicine, South Valley University, Qena, Egypt

Address for correspondence Ahmed G. Tammam, MSc, Faculty of medicine, South Valley University, Qena, 83523, Egypt (e-mail: ahmed\_gamal@med.svu.edu.eg).

AJNS 2022;17:470–473.

## Abstract

**Objective** The aim of this study was to compare the radiological outcomes of long-segment fixation and short-segment fixation, including the fracture level in patients treated for thoracolumbar junction fractures.

**Methods** Data collected from records of patients with thoracolumbar junction fractures who were operated at our department. Neurological evaluation was done using American Spinal Injury Association classification score. Radiological parameters used were the Cobb's angle, vertebral body compression ratio, the anteroposterior spinal canal diameter, and the anterior and the posterior vertebral body heights. Patients were divided into two groups: group A included patients who underwent long-segment fixation and group B included patients who underwent short-segment fixation with inclusion of the fracture level.

**Results** The mean preoperative Cobb angle was 22.51 degrees in group A and 19.37 degrees in group B. Both groups showed improvement in the postoperative Cobb angle as the mean in group A was 14.17 degrees and in group B was 11.77 degrees. The mean preoperative compression ratio in group A was 82.8%, while in group B it was 76%. The postoperative mean in group A was 89.2%, while in group B, it was 84%. The mean preoperative anterior vertebral body height of the fractured vertebra in group A was 16.7 mm, while in group B, it was 15.18 mm. The mean preoperative posterior vertebral body height in group A was 16.33 mm and that of group B was 19.41 mm. The mean postoperative anterior vertebral body height in group A was 17.66 mm and that of group B was 17.10 mm. The mean postoperative posterior vertebral body height in group A was 17.11 mm and that of group B was 20.79 mm.

**Conclusion** Posterior short-segment fixation with additional screws at the fracture level provides similar—if not better—clinical and radiological outcomes to long-segment fixation in the treatment of thoracolumbar junction fractures.

## Keywords

- ▶ thoracolumbar fractures
- ▶ long-segment fixation
- ▶ inclusion of the fractured level

DOI <https://doi.org/10.1055/s-0042-1757428>.  
ISSN 2248-9614.

© 2022. Asian Congress of Neurological Surgeons. All rights reserved.

This is an open access article published by Thieme under the terms of the Creative Commons Attribution-NonDerivative-NonCommercial-License, permitting copying and reproduction so long as the original work is given appropriate credit. Contents may not be used for commercial purposes, or adapted, remixed, transformed or built upon. (<https://creativecommons.org/licenses/by-nc-nd/4.0/>)

Thieme Medical and Scientific Publishers Pvt. Ltd., A-12, 2nd Floor, Sector 2, Noida-201301 UP, India

## Key Messages

1. Thoracolumbar junction spine fractures present a dilemma for most spine surgeons.
2. Short-segment fixation with inclusion of the fractured level provides good kyphosis correction and restoration of vertebral body height that can be compared with those of traditional long-segment fixation method.

## Introduction

Thoracolumbar junction fractures are the most common fractures of the thoracolumbar region<sup>1</sup> however, there is no definite guidelines for their management.<sup>2</sup> Currently, there are numerous surgical techniques for the treatment of these fractures including anterior approach, posterior approach, minimally invasive and combined anterior and posterior approach. As there is no clear guideline on the surgical technique to be used for the treatment of each type of the thoracolumbar fractures, the choice is falls on the surgeon. Moreover, the number of levels to be instrumented to achieve adequate stability is also the surgeon's decision.<sup>3</sup>

Long-segment fixation was the traditional method for the management of unstable thoracolumbar spine fractures. This was done by posterior fixation of two or more segments above and below the fractured vertebra using transpedicular screws. Despite having low construct failure rate and superior stability compared with other methods of fixation, recent studies have reported adverse effects such as dorsalgia, implant failure, and significant reduction of vertebral mobility due to loss of motion segments.<sup>4</sup>

Short-segment fixation including the fractured level was advocated by recent studies to be a better choice than short-segment fixation alone as it prevents implant failure of the short-segment fixation and achieves good results that are comparable to long-segment fixation.<sup>5,6</sup>

In this study, we compared the results of short-segment fixation including fractured level and those of long-segment fixation.

## Patients and Methods

Data collected from records of patients with thoracolumbar junction fractures who were operated at Neurosurgery Department, Qena University Hospital, South Valley University, Qena, Egypt.

Patients selected for the study were 18 years or older, suffering from traumatic single level thoracolumbar junction fracture with no or incomplete deficit, where computed tomographic (CT) scans showed loss of vertebral body height less than 50% and retracted fragment in spinal canal less than 50% of the sagittal canal diameter with intact or unilateral fractured pedicles.

Those who had multiple spine fractures, presenting with paraplegia or with bilateral fractured pedicles on CT scans, were excluded from the study.

Clinical evaluation was done by recording the neurological status of each patient according to the American Spinal

Injury Association (ASIA) classification score in the preoperative and postoperative period.

Radiological evaluation was done using plain radiographs and CT scans of the spine to determine the kyphotic angle by measurement of the Cobb angle (from the superior endplate of the vertebra above the fracture level to the inferior endplate of the vertebra below the fracture level), anterior and posterior vertebral body heights and the vertebral body compression ratio of the fractured vertebra using the anterior/posterior vertebral body compression ratio (APCR) method (AVBH/PVBHx100).

The anteroposterior spinal canal diameter at the maximum area of retracted bone fragment was measured in each case, compared with the canal diameter of the adjacent level and correlated with the degree of neurological deficit if present.

Patients were categorized in two groups, those who underwent long-segment fixation (group A) and those who underwent short segment fixation including the fracture level (group B). Both groups were compared with each other in terms of the radiological parameters listed above.

## Surgical Method

Standard posterior spinal approach was performed in all cases. In short-segment fixation including fracture level, transpedicular screws were inserted in the normal vertebrae just above and below the fractured vertebra under image guidance, then a transpedicular screw was inserted in the fractured vertebra. In long-segment fixation, transpedicular screws were inserted in the two normal vertebrae above and the two normal vertebrae below the fracture level. Spinal canal decompression was done at the fracture level. Connecting rods were placed on either side after precontouring them according to the sagittal profile of the thoracic kyphosis and the lumbar lordosis and the bone graft collected from decompression process was stuffed laterally to enhance lateral intertransverse spinal fusion.

## Outcome Evaluation

Clinical evaluation of the neurological status using the ASIA classification score.

Radiological evaluation of the Cobb angle, the vertebral body height, and the vertebral body compression ratio was calculated on the CT scans done in the immediate postoperative period.

## Results

The study included 27 patients with thoracolumbar junction fractures. Group A included 27 patients (18 males and 9 females) and group B included 30 patients (21 males and 9 females). The mean age was similar in both groups ranging from 19 to 61 years in group A and from 18 to 63 years in group B.

The majority of cases (39) were caused by fall from height followed by road traffic accidents (12). Thirty-five patients

**Table 1** Comparison between anteroposterior canal diameters according to ASIA classification

ASIA grade	Mean AP diameter at fracture level (mm)	Mean normal AP diameter at adjacent level (mm)
E	13.27	18.32
D	7.91	19.71
C	4.2	19.22

Abbreviations: AP, anteroposterior; ASIA, American Spinal Injury Association.

had fracture L<sub>1</sub>, while L<sub>2</sub> fractures occurred in 12 cases and D<sub>12</sub> fractures were encountered in 10 cases.

Thirty-nine patients were neurologically intact (ASIA grade E), while the remaining eighteen patients had incomplete neurological injury (13 ASIA grade D and 5 grade C) (►Table 1).

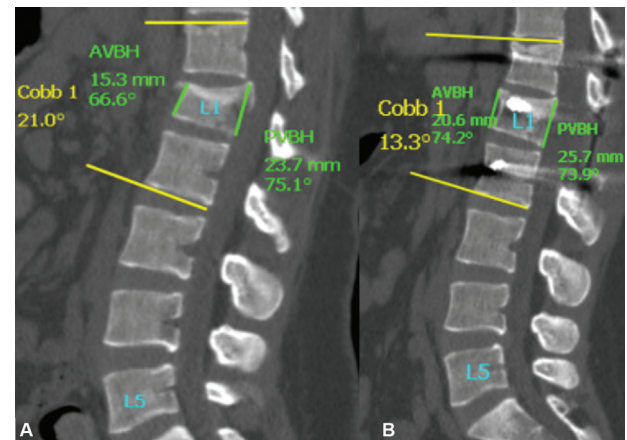
The mean preoperative Cobb angle was 22.51 degrees in group A and 19.37 degrees in group B. Both groups showed improvement in the postoperative Cobb angle as the mean in group A was 14.17 degrees and in group B 11.77 degrees.

Regarding the vertebral body compression ratio, the mean preoperative compression ratio in group A was 82.8%, while in group B, it was 76%. The postoperative mean in group A was 89.2%, while in group B it was 84%.

The mean preoperative anterior vertebral body height of the fractured vertebra in group A was 16.7 mm, while in group B, it was 15.18 mm. The mean preoperative posterior vertebral body height in group A was 16.33 mm and that of group B was 19.41 mm. The mean postoperative anterior vertebral body height in group A was 17.66 mm and that of group B was 17.10 mm. The mean postoperative posterior vertebral body height in group A was 17.11 mm and that of group B was 20.79 mm (►Fig. 1; ►Table 2).

## Discussion

The approach to thoracolumbar spine fracture management is still under much deliberation. Stable fractures can be treated in a conservative manner by immobilization; however, the same cannot be said in case of unstable fractures. These fractures—especially those with retropulsed fragments—usually require surgical intervention to decompress the neural element and perform internal fixation.<sup>7</sup>



**Fig. 1** (A) Preoperative computed tomographic (CT), sagittal view, showing L<sub>1</sub> # with measurement of Cobb angle, anterior vertebral body height (AVBH) and posterior vertebral body height (PVBH). (B) Postoperative CT, sagittal view, showing screws in place and measurement of Cobb angle, AVBH and PVBH.

Different surgical modalities have been proposed over the last century, many of which are still in use to this moment. The most commonly used surgical approach is posterior transpedicular screw fixation because it offers rigid fixation and requires less expertise compared with anterior approach. Despite being very popular, there is still controversy about how many levels should be included in the construct.<sup>8</sup>

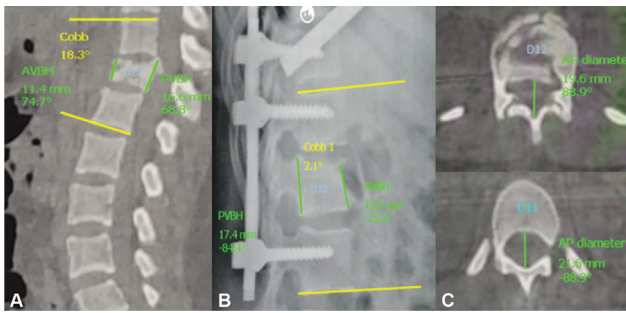
Posterior long-segment fixation has been the traditional method for stabilizing the fractured spine involved in the instrumentation of at least two vertebrae above and two vertebrae below the fractured level deliver effective stabilization and minimize the threat of posttraumatic kyphosis and implant breakage. However, this technique has many disadvantages including extensive dissection, increased operative time, intraoperative blood loss, and financial cost. It also results in a relevant reduction of the vertebral motion.<sup>5</sup>

Posterior short-segment fixation with two additional screws at the fracture level has been lately favored for the treatment of thoracolumbar spine unstable fractures claiming that the adding of pedicle screws at the fractured vertebra can considerably increase spinal stability, provide stronger fixation, and decrease the stress on the pedicle screws in the nonfractured adjacent vertebra.<sup>9</sup>

In our study, we used data collected from records of 57 patients with thoracolumbar junction fractures who were operated using both long-segment fixation and short-seg-

**Table 2** Comparison between group A and group B according to radiological parameters

Parameter	Group A		Group B	
	Preoperative	Postoperative	Preoperative	Postoperative
Cobb's angle (mean)	22.51 degrees	14.17 degrees	19.37 degrees	11.77 degrees
Anterior vertebral body height (mean)	16.7 mm	17.66 mm	15.18 mm	17.10 mm
Posterior vertebral body height (mean)	16.33 mm	17.11 mm	19.41 mm	20.79 mm
Vertebral body compression ratio (mean)	82.8%	89.2%	76%	84%



**Fig. 2** (A) Preoperative computed tomographic (CT), sagittal view, showing D<sub>12</sub> # with measurement of Cobb angle, anterior vertebral body height (AVBH) and posterior vertebral body height (PVBH). (B) Postoperative plain radiograph, lateral view, showing screws in place and measurement of Cobb angle, AVBH and PVBH. (C) Preoperative CT, axial view showing D<sub>12</sub> # and measurement of anteroposterior canal diameter of D<sub>11</sub> and D<sub>12</sub>.

ment fixation including the fracture level and compared the radiological outcome of both groups in terms of kyphotic angle, vertebral body compression ratio, and the heights of the anterior and posterior vertebral body.

To assess the relation between the canal diameter and the neurological state, we measured the anteroposterior canal diameter of the fractured level for each patient with the anteroposterior canal diameter of the adjacent vertebra and we found that the severity of canal stenosis correlates to the severity of the neurological deficit in patients with thoracolumbar spine fractures.

Both groups showed statistically significant improvement in Cobb's angle ( $p$ -value of group A = 0.004 and that of group B = 0.0002). Both groups showed improvement in the postoperative measurements of the vertebral body compression ratio compared with preoperative ones. However, group B was superior to group A showing 9.5% improvement ( $p$ -value = 0.008) compared with 7.2% for group A ( $p$ -value = 0.05). We also found that group B showed better restoration of the anterior and posterior vertebral body heights than group A. (► **Fig. 2**)

By observing these results, we can endorse the posterior short-segment fixation with inclusion of the fracture level for surgical stabilization of the thoracolumbar spine junction as it showed better correction of the radiological parameters and similar—if not better—biomechanical stability to posterior long-segment fixation.

## Conclusion

Posterior short-segment fixation with additional screws at the fracture level provides similar—if not better—radiological outcome to long-segment fixation in the treatment of thoracolumbar junction fractures.

### Conflict of Interest

None declared.

## References

- Hu R, Mustard CA, Burns C. Epidemiology of incident spinal fracture in a complete population. *Spine* 1996;21(04):492–499
- Altay M, Ozkurt B, Aktekin CN, Ozturk AM, Dogan O, Tabak AY. Treatment of unstable thoracolumbar junction burst fractures with short- or long-segment posterior fixation in Magerl type a fractures. *Eur Spine J* 2007;16(08):1145–1155
- Reinhold M, Knop C, Beisse R, et al. Operative treatment of 733 patients with acute thoracolumbar spinal injuries: comprehensive results from the second, prospective, Internet-based multicenter study of the Spine Study Group of the German Association of Trauma Surgery. *Eur Spine J* 2010;19(10):1657–1676
- Koller H, Acosta F, Hempfing A, et al. Long-term investigation of nonsurgical treatment for thoracolumbar and lumbar burst fractures: an outcome analysis in sight of spinopelvic balance. *Eur Spine J* 2008;17(08):1073–1095
- Kanna RM, Shetty AP, Rajasekaran S. Posterior fixation including the fractured vertebra for severe unstable thoracolumbar fractures. *Spine J* 2015;15(02):256–264
- Güven O, Kocaoglu B, Bezer M, Aydın N, Nalbantoglu U. The use of screw at the fracture level in the treatment of thoracolumbar burst fractures. *J Spinal Disord Tech* 2009;22(06):417–421
- Sodhi HBS, Savardekar AR, Chauhan RB, Patra DP, Singla N, Salunke P. Factors predicting long-term outcome after short-segment posterior fixation for traumatic thoracolumbar fractures. *Surg Neurol Int* 2017;8(01):233
- Wang H, Zhao Y, Mo Z, et al. Comparison of short-segment monoaxial and polyaxial pedicle screw fixation combined with intermediate screws in traumatic thoracolumbar fractures: a finite element study and clinical radiographic review. *Clinics (São Paulo)* 2017;72(10):609–617
- Bolesta MJ, Caron T, Chinthakunta SR, Vazifeh PN, Khalil S. Pedicle screw instrumentation of thoracolumbar burst fractures: biomechanical evaluation of screw configuration with pedicle screws at the level of the fracture. *Int J Spine Surg* 2012;6(01):200–205