



Endovascular Embolization with n-Butyl Cyanoacrylate for Ruptured Distal Posterior Inferior Cerebellar Artery Dissecting Aneurysm

Ryosuke Shintoku^{1,2} Aiki Marushima^{1,2} Sho Okune² Takato Hiramine² Junzo Nakao^{1,2}
Toshihide Takahashi^{1,2} Tenyu Hino² Hisayuki Hosoo^{1,2} Yoshiro Ito^{1,2} Mikito Hayakawa^{2,3}
Eiichi Ishikawa¹ Yuji Matsumaru^{1,2,3}

¹ Department of Neurosurgery, Faculty of Medicine, University of Tsukuba, Tsukuba, Japan

² Department of Stroke and Cerebrovascular Diseases, University of Tsukuba Hospital, Tsukuba, Japan

³ Division of Stroke Prevention and Treatment, Faculty of Medicine, University of Tsukuba, Tsukuba, Japan

Address for correspondence Aiki Marushima, MD, PhD, Department of Neurosurgery, Faculty of Medicine, University of Tsukuba, 1-1-1, Tennodai, Tsukuba, Ibaraki, 305-8575, Japan (e-mail: aiki.marushima@md.tsukuba.ac.jp).

Asian J Neurosurg 2023;18:651–655.

Abstract

Parent artery occlusion is a definitive treatment method for preventing rebleeding of dissecting aneurysms. We herein report a case of a ruptured distal posterior inferior cerebellar artery (PICA) dissecting aneurysm treated with internal trapping using n-butyl-2-cyanoacrylate (NBCA). A 65-year-old man visited our hospital with a complaint of headache and neck pain that began 1 week before his arrival. He had a history of spontaneous subarachnoid hemorrhage of unknown cause. Computed tomography of the brain revealed a small amount of subarachnoid hemorrhage, and distal subtraction angiogram showed a distal PICA dissecting aneurysm. We placed a guiding catheter in the left vertebral artery and an intermediate catheter in the PICA. A microcatheter was guided toward the proximal side of the aneurysm and was wedged into the parent artery. The dissecting aneurysm was treated with parent artery occlusion using 50% NBCA. The postoperative course was uneventful, and the patient was discharged 3 weeks after treatment without any neurological deficit. Parent artery occlusion with internal trapping using NBCA could be a safe and definitive treatment method for distal PICA dissecting aneurysms. Angiographical evaluation of the collateral network in the distal branch of PICA before embolization and wedged microcatheter technique in the parent artery are important for successful embolization using NBCA.

Keywords

- ▶ angiographical collateral network
- ▶ distal PICA dissecting aneurysm
- ▶ n-butyl-2-Cyanoacrylate
- ▶ parent artery occlusion
- ▶ wedged microcatheter technique

Introduction

The rebleeding rate of dissecting posterior inferior cerebellar artery (PICA) aneurysms is approximately 24% in the acute

phase; therefore, immediate surgical trapping or endovascular embolization is essential for the prevention of rebleeding.^{1–3} Coils or liquid embolization material could be used for parent artery occlusion through internal trapping.^{4–7}

article published online
September 22, 2023

DOI <https://doi.org/10.1055/s-0042-1757432>.
ISSN 2248-9614.

© 2023. Asian Congress of Neurological Surgeons. All rights reserved.

This is an open access article published by Thieme under the terms of the Creative Commons Attribution-NonDerivative-NonCommercial-License, permitting copying and reproduction so long as the original work is given appropriate credit. Contents may not be used for commercial purposes, or adapted, remixed, transformed or built upon. (<https://creativecommons.org/licenses/by-nc-nd/4.0/>)

Thieme Medical and Scientific Publishers Pvt. Ltd., A-12, 2nd Floor, Sector 2, Noida-201301 UP, India

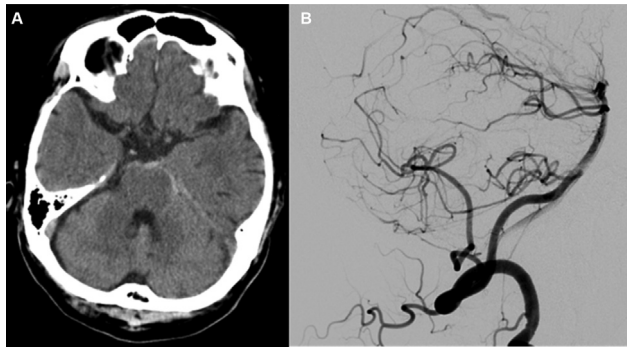


Fig. 1 (A) A computed tomographic scan, taken 3 years ago, showing the subarachnoid hemorrhage confined to the periphery of the brainstem. (B) Distal subtraction angiogram, performed 3 years ago, showing smooth vessel wall due to an unknown cause.

However, it has been reported that endovascular embolization is associated with higher rates of perioperative stroke in the distal portion of the PICA.⁸ We herein report a case of a ruptured distal PICA dissecting aneurysm successfully treated with internal trapping using n-butyl-2-cyanoacry-

late (NBCA). We have also discussed the results of angiographical evaluation before embolization and the use of a wedged microcatheter technique in the parent artery to avoid ischemic complications in the perioperative period.

Case History

A 68-year-old man visited the emergency room of our hospital with the complaint of headache and neck pain that began 1 week before his arrival to the hospital. He had a medical history of hypertension, diabetes mellitus, and subarachnoid hemorrhage of unknown cause approximately 3 years ago (►Fig. 1A,B). The consciousness level was 15, as measured on the Glasgow coma scale, and no obvious abnormal neurological findings were observed. Computed tomography of the brain revealed a small amount of subarachnoid hemorrhage in both cerebral hemispheres (►Fig. 2A). Fluid-attenuated inversion-recovery magnetic resonance imaging of the brain revealed subarachnoid hemorrhage and subacute ischemic area in the medial left cerebellar hemisphere (►Fig. 2B). Cerebral angiography

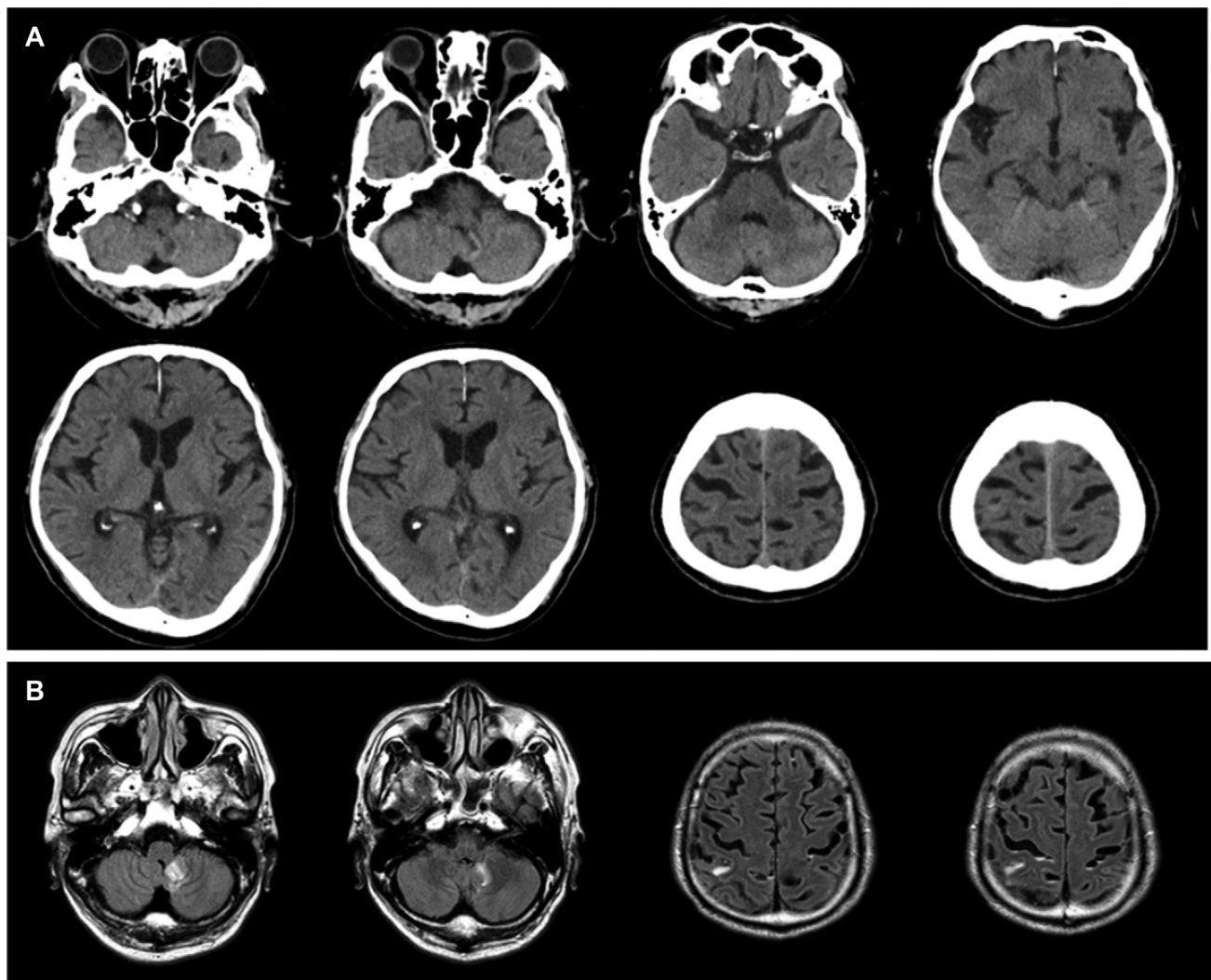


Fig. 2 Head computed tomography (A) and magnetic resonance imaging fluid attenuated inversion recovery (B) showing a small amount of subarachnoid hemorrhage in both cerebral hemispheres and a subacute ischemic area in the medial left cerebellar hemisphere.

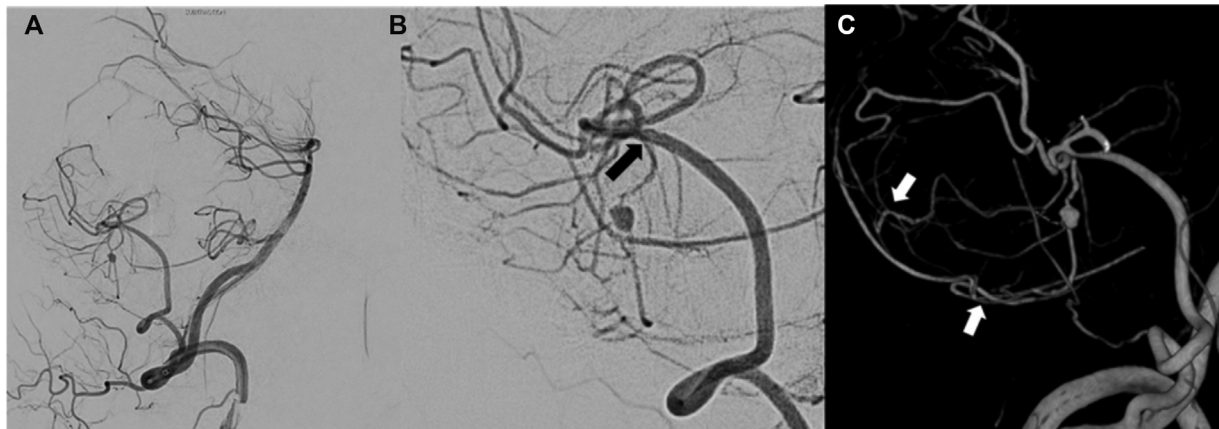


Fig. 3 (A, B) Distal subtraction angiogram showing vascular dilatation with wall irregularity in the distal portion of the left posterior inferior cerebellar artery (PICA). We considered the safety margin for glue reflux during embolization that not causing of neurological deficit is the branching of the parent artery of the aneurysm (black arrow). (C) An apparent angiographical collateral vascular network in the distal portion of the PICA (3DRA) (white arrow).

revealed an abnormal finding in the cortical segment of vermian branch of the PICA, which was suspected as a dissecting aneurysm with wall irregularity in the distal portion of the left PICA (►Fig. 3A,B). There was an apparent angiographical collateral network in the distal portion of the PICA (►Fig. 3C); hence, we decided to perform parent artery occlusion via internal trapping with coil embolization. A 5Fr. FUBUKI Dilator Kit (ASAHI.INTEC, Aichi, Japan) was inserted into the right common femoral artery to the left vertebral artery. We tried to insert 4.2Fr FUBUKI catheter (ASAHI.INTEC, Aichi, Japan) and Marathon catheter (eV3 Covidien, Irvine, California, United States) in the left PICA; however, the Marathon catheter did not reach the proximal portion of the distal PICA dissecting aneurysm (►Fig. 4A). In the second attempt, Tactics catheter (Techno-

crat Corporation, Aichi, Japan) and Headway Duo catheter (Terumo, Tokyo, Japan) were maneuvered toward the aneurysm; however, this method also failed (►Fig. 4B). Therefore, we changed the treatment strategy to parent artery occlusion using liquid embolic material. Finally, we were able to place the DeFrictor nano catheter (Medicos-Hirata, Osaka, Japan) with Tactics just proximal to the aneurysm and wedged in the parent artery (►Fig. 4C and ►Fig. 5A). We were able to perform parent artery occlusion using 50% NBCA (►Fig. 5B). The dissecting aneurysm and parent artery were occluded with NBCA, and they resolved on cerebral angiography after embolization (►Fig. 5C). There was no symptomatic ischemic complication or rebleeding during the procedure. The postoperative course was uneventful, and the patient was discharged 3 weeks after treatment without

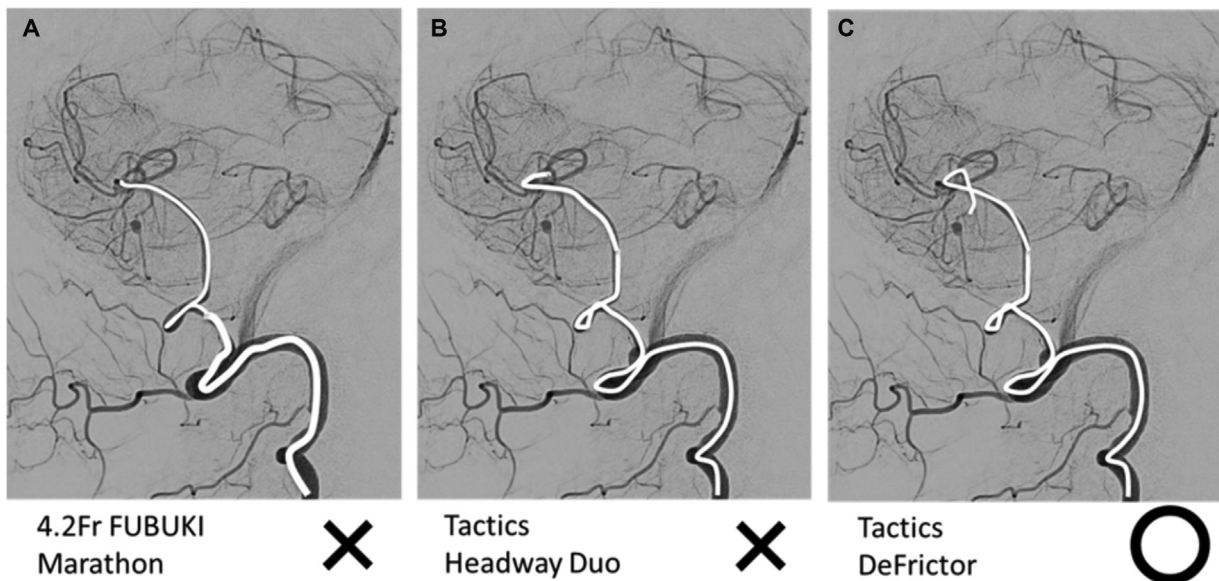


Fig. 4 (A) 4.2 Fr FUBUKI catheter (ASAHI.INTEC, Aichi, Japan) inserted into the left posterior inferior cerebellar artery (PICA), Marathon catheter (eV3 Covidien, Irvine, California, United States) inserted near the aneurysm. A micro guidewire was inserted near the aneurysm, but the Marathon catheter did not follow. (B) Tactics catheter (Technocrat Corporation, Aichi, Japan) and Headway Duo catheter (Terumo, Tokyo, Japan) near the aneurysm, but Headway Duo catheter did not follow. (C) Tactics catheter and DeFrictor nano catheter (Medicos-Hirata, Osaka) were able to reach just proximal of the aneurysm.

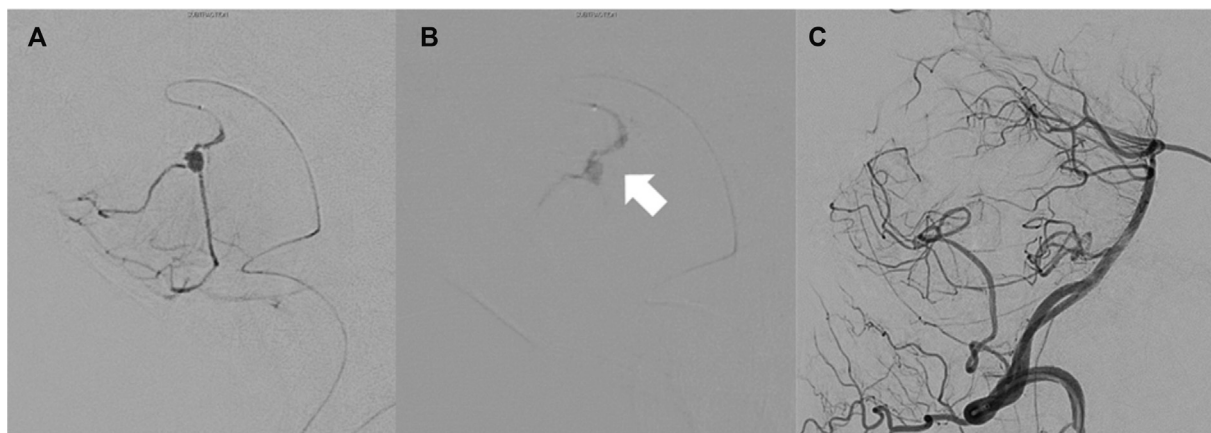


Fig. 5 (A) DeFrictor nano catheter just proximal and wedged into the aneurysm. (B) The dissecting aneurysm and parent artery were occluded with n-butyl-2-cyanoacrylate (white arrow). (C) After embolization, aneurysms and parent artery were not contrasted.

any neurological deficit. No recurrence was noted at the 1-year follow-up (►Fig. 6).

Discussion

We successfully performed parent artery occlusion of the PICA cortical segment using NBCA to preserve the collateral network. It is important to guide the microcatheter as distal as possible and wedge it into the parent artery when performing internal trapping with liquid embolic material.^{9,10} In our case, the aneurysm was located at the periphery of the PICA; therefore, it was necessary to guide the microcatheter into the narrow distant artery. On the other hand, wedging the catheter may cause the distal spread of NBCA and occlude the collateral vascular network. Therefore, the injection technique of the liquid embolic material is important to preserve the collateral vascular network. We considered the safety margin for glue reflux during embolization

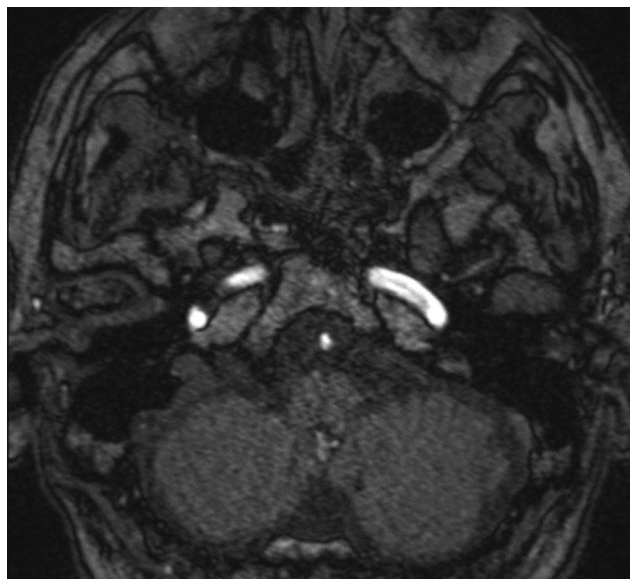


Fig. 6 Magnetic resonance imaging time-of-flight showing no recurrence at the 1-year follow-up.

that not causing of neurological deficit is the branching of the parent artery of the aneurysm (►Fig. 3B). In this case, we could finally guide the DeFrictor nano catheter to the parent artery of just proximal of the aneurysm. Therefore, we decided to inject 50% NBCA to occlude the aneurysm and short segment of the parent artery, and they were occluded successfully. Some previous studies have reported that it is possible to occlude the PICA cortical segment with internal trapping by coil embolization or liquid material.^{1,4-7} Initially, we attempted to perform internal trapping with coil embolization and guided Marathon catheter and Headway Duo catheter; however, catheterizations with 1.5 Fr outer diameter of the Marathon catheter and 1.6 Fr of Headway Duo were difficult and failed. The DeFrictor nano catheter with a 1.3-Fr outer diameter was able to reach the distal part of the PICA, which is at the proximal portion of the aneurysm. Although liquid embolic material has limitations, it has excellent flexibility and detectability and is useful for this case. A few successful cases of ruptured PICA dissecting aneurysms embolized with glue⁴ and with ONYX have been reported.^{6,7} Embolization of peripheral aneurysms with NBCA has been reported in distal anterior choroidal artery aneurysm associated with moyamoya disease,¹¹ anterior cerebral artery aneurysm combined with coil embolization,¹² and infected aneurysms associated with infective endocarditis.¹³ Performing parent artery occlusion with NBCA is quite rare in treating dissecting aneurysms. There have been no reports of embolization using DeFrictor nano catheter and Tactics, but it could be an option.

The patient reported in the present study developed subarachnoid hemorrhage of unknown source approximately 3 years ago. The subarachnoid hemorrhage was confined to the periphery of the brainstem. Multiple imaging studies were performed; however, the cause of bleeding was unknown. A previous study reported that the perimesencephalic subarachnoid hemorrhage is usually confined to the periphery of the midbrain without an angiographically apparent cause of bleeding.¹⁴ Some reports suggest that small aneurysms or dissection of the basilar artery or perforating branches may be the source of bleeding.^{15,16} The rate of

rebleeding is low at 1.1%.¹⁷ Retrospectively reviewing the DSA, the vessel wall of the aneurysm was smooth this time. Assuming that the two bleeding sources are different, this patient might have had multiple dissections at different times and places. Therefore, further follow-up magnetic resonance imaging is necessary.

Conclusion

Parent artery occlusion with internal trapping using NBCA could be a safe and definitive method for treating distal PICA dissecting aneurysms. NBCA embolization with Tactics and DeFrictor nano catheter is a valid option when performing internal trapping of peripheral vessels. Angiographical evaluation of the collateral network in the distal branch of the PICA before embolization and a wedged microcatheter technique in the parent artery are important for successful embolization using NBCA.

Conflict of Interest

None declared.

References

- 1 Lim SM, Choi IS, Hum BA, David CA. Dissecting aneurysms of the distal segment of the posterior inferior cerebellar arteries: clinical presentation and management. *AJNR Am J Neuroradiol* 2010;31(06):1118–1122
- 2 Kleinpeter G. Why are aneurysms of the posterior inferior cerebellar artery so unique? Clinical experience and review of the literature. *Minim Invasive Neurosurg* 2004;47(02):93–101
- 3 Sejkorová A, Cihlář F, Hejčl A, Lodin J, Vachata P, Sameš M. Microsurgery and endovascular treatment of posterior inferior cerebellar artery aneurysms. *Neurosurg Rev* 2016;39(01):159–168, discussion 168
- 4 Ioannidis I, Nasis N, Andreou A. Endovascular treatment of ruptured dissecting aneurysms of the posterior inferior cerebellar artery. *Interv Neuroradiol* 2012;18:442–448
- 5 Shin HS, Lee SH, Koh JS. Endovascular treatment of ruptured distal posterior inferior cerebellar artery aneurysm. Report of two exemplary cases and retrospective analysis of 11 cases. *J Neurol Surg A Cent Eur Neurosurg* 2014;75(05):343–349
- 6 Puri AS, Massari F, Hou SY, et al. Onyx embolization in distal dissecting posterior inferior cerebellar artery aneurysms. *J Neurointerv Surg* 2016;8(05):501–506
- 7 Wu Q, Wang HD, Zhang QR, Zhang X. Parent artery occlusion with Onyx for distal aneurysms of posterior inferior cerebellar artery: a single-centre experience in a series of 15 patients. *Neurol India* 2013;61(03):265–269
- 8 Petr O, Sejkorová A, Bradáč O, Brinjkji W, Lanzino G. Safety and efficacy of treatment strategies for posterior inferior cerebellar artery aneurysms: a systematic review and meta-analysis. *Acta Neurochir (Wien)* 2016;158(12):2415–2428
- 9 Marushima A, Matsumaru Y, Suzuki K, et al. Selective arterial embolization with n-butyl cyanoacrylate in the treatment of aneurysmal bone cyst of the thoracic vertebra: a case report. *Spine* 2009;34(06):E230–E234
- 10 Nelson PK, Russell SM, Woo HH, Alastra AJ, Vidovich DV. Use of a wedged microcatheter for curative transarterial embolization of complex intracranial dural arteriovenous fistulas: indications, endovascular technique, and outcome in 21 patients. *J Neurosurg* 2003;98(03):498–506
- 11 Choulakian A, Drazin D, Alexander MJ. NBCA embolization of a ruptured intraventricular distal anterior choroidal artery aneurysm in a patient with moyamoya disease. *J Neurointerv Surg* 2010;2(04):368–370
- 12 Huang Q, Shen J, Xu Y, Liu J. Endovascular treatment of ruptured distal anterior cerebral artery aneurysm. *Neurol India* 2010;58(02):259–263
- 13 Misser SK, Laloo S, Ponnusamy S. Intracranial mycotic aneurysm due to infective endocarditis—successful NBCA glue embolisation. *S Afr Med J* 2005;95(06):397–399, 403–404
- 14 van Gijn J, van Dongen KJ, Vermeulen M, Hijdra A. Perimesencephalic hemorrhage: a nonaneurysmal and benign form of subarachnoid hemorrhage. *Neurology* 1985;35(04):493–497
- 15 Matsumaru Y, Yanaka K, Muroi A, Sato H, Kamezaki T, Nose T. Significance of a small bulge on the basilar artery in patients with perimesencephalic nonaneurysmal subarachnoid hemorrhage. Report of two cases. *J Neurosurg* 2003;98(02):426–429
- 16 Park SQ, Kwon OK, Kim SH, Oh CW, Han MH. Pre-mesencephalic subarachnoid hemorrhage: rupture of tiny aneurysms of the basilar artery perforator. *Acta Neurochir (Wien)* 2009;151(12):1639–1646
- 17 Mohan M, Islam AI, Rasul FT, et al; British Neurosurgical Trainee Research Collaborative. Subarachnoid haemorrhage with negative initial neurovascular imaging: a systematic review and meta-analysis. *Acta Neurochir (Wien)* 2019;161(10):2013–2026