



# Endoscopic Cyanoacrylate Glue Injection for Duodenal Varices—A Single-Center Study

Syed Shafiq<sup>1</sup> Harshad Devarbhavi<sup>1</sup> Mallikarjun Patil<sup>1</sup>

<sup>1</sup>Department of Gastroenterology, St. John's Medical College Hospital, Bengaluru, Karnataka, India

Address for correspondence Syed Shafiq, MD, DM, Department of Gastroenterology, St. John's Medical Hospital, Sarjapur Road, Bengaluru-560034, Karnataka, India (e-mail: syed.dr.s@gmail.com).

J Digest Endosc 2022;13:218–223.

## Abstract

**Aim/Objectives** Duodenal varices (DVs), although rare, can present with massive, potentially fatal upper gastrointestinal bleeding; however, there are no randomized trials regarding management of this relatively uncommon presentation. We aim to report our experience with endoscopic cyanoacrylate glue injection in patients with DVs.

**Materials and Methods** We retrospectively evaluated the medical records of all patients with portal hypertension at our center between January 2010 and December 2021. Demographic characteristics along with the etiology, location, and effectiveness of cyanoacrylate glue injection for bleeding DVs were collected and analyzed.

**Results** A total of 5,892 patients with portal hypertension underwent endoscopy during the study period, of whom 41 patients (M:F = 29:12) with mean age of 38 years were noted to have DVs. While extrahepatic portal vein obstruction was the commonest etiology ( $n = 26$ ), the most common site of DVs was the duodenal bulb ( $n = 21$ ). Twenty-one (51%) out of these 41 patients presented primarily with DV bleeding and underwent endoscopic cyanoacrylate glue injection with successful hemostasis achieved of the index bleed; however, four of these 21 patients had rebleeding between 2 weeks and 12 months of follow-up requiring repeat endotherapy. While three patients underwent successful repeat glue injections, one patient had recurrent massive bleeds, not amenable to endotherapy and was subjected to duodenal resection with surgical shunt procedure.

**Conclusion** While the prevalence of DVs in portal hypertension patients was 0.7% (41/5892), DVs accounted for 0.42% (21/4889) of portal hypertension-related bleedings. Endotherapy with cyanoacrylate glue appears to be a safe and cost-effective treatment for acute DV bleeding in a resource-limited setting.

## Keywords

- ▶ cyanoacrylate glue
- ▶ gastrointestinal bleeding
- ▶ hemostasis
- ▶ duodenal varices
- ▶ portal hypertension

## Introduction

Ectopic varices are large portosystemic venous collaterals situated in locations other than the gastroesophageal region

and account for up to 1 to 5% of all variceal bleeding.<sup>1,2</sup> Although their exact prevalence is not known, duodenal varices (DVs) are estimated to account for 17 to 40% of all ectopic varices with a higher prevalence noted in patients

DOI <https://doi.org/10.1055/s-0042-1757469>.  
ISSN 0976-5042.

© 2022. The Author(s).

This is an open access article published by Thieme under the terms of the Creative Commons Attribution License, permitting unrestricted use, distribution, and reproduction so long as the original work is properly cited. (<https://creativecommons.org/licenses/by/4.0/>)

Thieme Medical and Scientific Publishers Pvt. Ltd., A-12, 2nd Floor, Sector 2, Noida-201301 UP, India

with extrahepatic portal hypertension (EPH) than those with intrahepatic portal hypertension (IPH).<sup>3-6</sup> Patients with DVs may present with hematemesis or massive lower gastrointestinal (GI) bleeding and should be considered in all patients with portal hypertension who present with GI bleeding particularly when both upper and lower GI endoscopies fail to identify the source of bleeding. Furthermore, management of DVs involves a multidisciplinary approach and includes medical, endoscopic, interventional radiological, and surgical modalities depending on patient's condition, the acuteness of bleeding, site of varices, and available clinical expertise. Endoscopic intervention is the initial therapeutic modality for the management of acute bleeding DVs as it is less invasive compared with interventional radiological and surgical procedures; however, given their rarity and sporadic nature, literature is limited to case reports, small case series, and reviews, with no well-established treatment guidelines regarding their management. Hence, we undertook this study to report our experience in the management of DVs at our center.

## Materials and Methods

We performed a retrospective analysis of all patients with portal hypertension who underwent endoscopy at St. John's Medical College Hospital, Bengaluru, between January 2010 and December 2021. Inclusion criteria included patients who were diagnosed to have bleeding primarily from DVs as well as those in whom DVs were diagnosed routinely on endoscopy performed as part of evaluation of portal hypertension. Medical records were reviewed from our hospital database with regard to demographic data of patients, clinical features, endoscopic and imaging findings of DVs, and endoscopic treatment of bleeding DVs. All patients presenting with suspected portal hypertension-related bleeding were admitted, and after initial resuscitation underwent esophagogastroduodenoscopy. Resuscitation included stabilization with intravenous fluids and/or administration of packed red cell transfusion, intravenous infusion of terlipressin (in the initial years 0.5–1 mg 6th hourly, followed by continuous infusion 2 mg/24 hours in the later years) and ceftriaxone injection as per guidelines.<sup>7</sup> After endoscopic confirmation, patients with DV bleeding ( $n=21$ ) received endoscopic injection of *n*-butyl-2-cyanoacrylate 1 mL undiluted injection followed by 2 mL normal saline flush, while patients with non-bleeding DVs ( $n=20$ ) were initiated on beta-blocker prophylaxis and followed at regular intervals. An informed consent was obtained from all patients before undertaking endoscopy. Patients were closely followed up for rebleeding by a combination of history and laboratory check (for drop in hemoglobin). Given the retrospective nature of the study, Institutional Ethics Review Board approval was deemed not mandatory. Although the prophylactic role of beta-blockers in patients with DVs remains debatable, all our patients with DVs were initiated on nonselective beta-blocker (propranolol) and followed up at regular intervals.

## Results

Overall, 5,892 patients underwent endoscopy for portal hypertension during the study period and we identified 41 patients with DVs, 29 of whom were males and the mean age ( $\pm$  SD [standard deviation]) of the study population was 38.1 ( $\pm$  13.7) (range: 5–75 years). DVs accounted for 0.42% (21/4889) of all portal hypertensive-related bleedings. Extrahepatic portal vein obstruction (EHPVO) was the most common etiology of DVs noted in 26 patients (63%), followed by cirrhosis in 14 patients (34%), and noncirrhotic portal fibrosis (NCPF) in 1 patient (3%). Of the total 41 DVs, 21 were in the duodenal bulb, while 17 were in the second part of duodenum and three in the third part of duodenum (**Table 1**).

Overall, 21 patients presented primarily with upper gastrointestinal (UGI) bleeding from DVs, while in 20 other patients DVs were detected on endoscopy performed for evaluation of portal hypertension. Endoscopic cyanoacrylate glue injection successfully achieved hemostasis of the index bleeding in all 21 patients with DV bleeding (**Fig. 1**). Four of these patients, however, had recurrent DV bleeding between 2 weeks and 12 months of follow-up necessitating repeat sessions of cyanoacrylate glue injections. Following repeat endotherapeutic sessions, three patients remained free of further bleedings, while one patient (female, aged 25 years with underlying EHPVO) continued to present with recurrent massive bleeding episodes, not amenable to endotherapy and ultimately underwent duodenal resection and surgical shunt procedure. A mean of 1.25 endoscopic sessions was required for near eradication of the DVs (range: 1–4).

## Discussion

DVs, although rare, can manifest as severe, life-threatening massive UGI bleeding in patients with portal hypertension, and they usually coexist with esophagogastric varices.<sup>8-12</sup> In our series, we identified a total of 41 patients with DVs of whom 21 presented primarily with DV bleeding. In the remainder ( $n=20$ ), DVs were diagnosed during routine endoscopic evaluation of portal hypertension. Our series in a fairly large number of patients demonstrates that endoscopic cyanoacrylate glue injection of DVs achieves complete and durable hemostasis in an overwhelmingly large number of patients including a small proportion of patients presenting with recurrent DV bleedings. Only one patient with recurrent episodes of massive DV bleeding was subjected to surgery after four sessions of endoscopic glue injection (**Fig. 2**). Of note, a total of three patients in our study had history of previous abdominal surgeries (**Table 1**).

In a study that enrolled a total of 169 patients with ectopic variceal bleeding, 17% of the bleeding was attributed to DVs.<sup>3</sup> This study also found that DVs were common in patients with EPH. Another study involving 173 patients reported that the mean age of patients with ectopic varices was 62.3 years and that 32.9% of patients with ectopic varices had DVs.<sup>4</sup> DVs are more prevalent in patients with portal hypertension secondary to portal or splenic vein thrombosis than in patients with

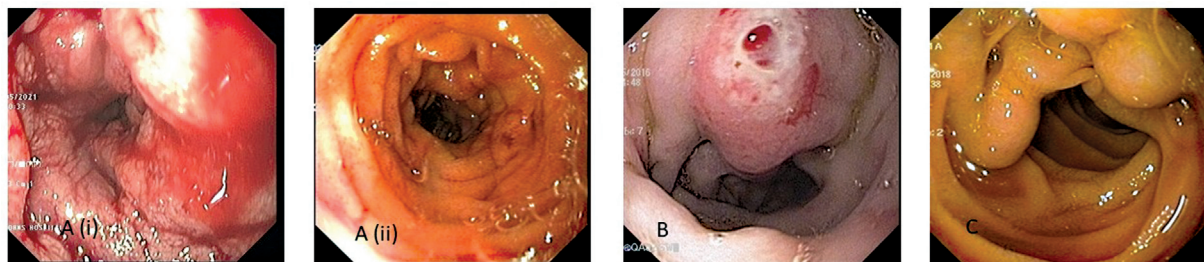
**Table 1** Clinical and endoscopic characteristic of study population

<b>Total number of patients</b>	<b>n = 41</b>
Male:female	29:12
Mean age ( $\pm$ standard deviation) (in years)	38.146 $\pm$ 13.739
<b>Etiology of duodenal varices</b>	
Extrahepatic portal vein obstruction <sup>a</sup>	26
Cirrhosis	14
a. Alcohol	7
b. Chronic hepatitis B	4
c. Nonalcoholic steatohepatitis	3
Noncirrhotic portal fibrosis	1
History of previous surgery/abdominal procedure	n = 3
Frey's procedure for chronic pain secondary to chronic calcific pancreatitis	1
Splenectomy and devascularization surgery	1
Kasai's procedure for extrahepatic biliary atresia	1
<b>Location of duodenal varices</b>	
Duodenal bulb	21
Second part of duodenum (D2)	17
Third part of duodenum (D3)	3
<b>Presence of coexistent esophagogastric varices</b>	
Esophageal varices	13
Gastric varices	2
Both esophageal and gastric varices	14
Endoscopic treatment for duodenal varices (cyanoacrylate glue)	n = 21
Control of index bleeding after endotherapy	21 (100%)
Patients with rebleeding on follow-up	4/21 (19%)
Success of endotherapy in repeat bleedings	3/4 (75%)

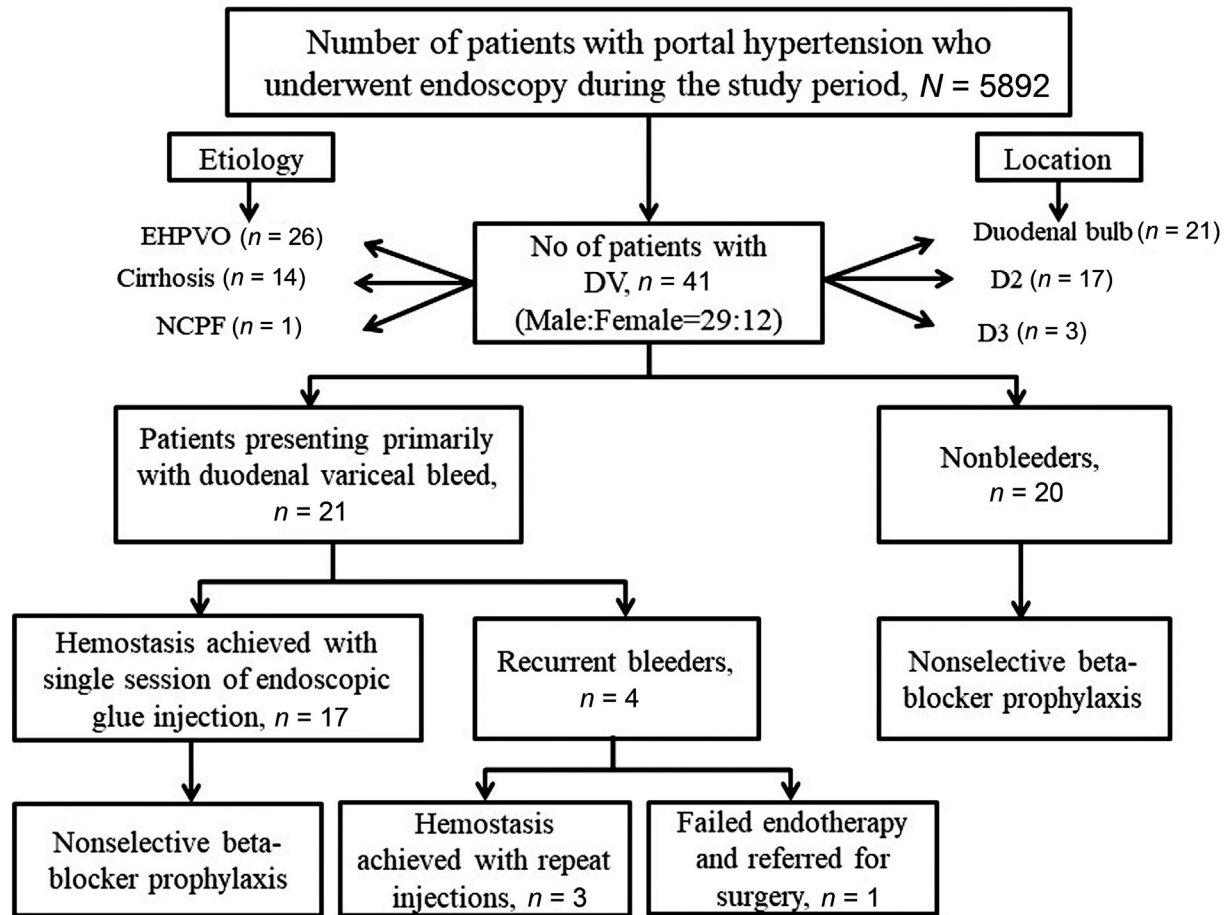
<sup>a</sup>Including three patients with chronic calcific pancreatitis.

IPH.<sup>13,14</sup> The mean ( $\pm$ SD) age of our study population was 38.14 ( $\pm$ 13.73) years that is quite younger than that noted in the above studies. This finding is because the most common underlying etiology of DVs in our study was EHPVO that was noted in 26 patients (63%), followed by cirrhosis in 14 patients (34%), and NCPF in one patient (3%). Given the regional variation in the causation of portal hypertension,

there is considerable heterogeneity in the etiology and prevalence of DVs. In the west, most bleeding from ectopic varices is usually associated with IPH as the prevalence of EPH is low.<sup>13,15</sup> EHPVO, on the other hand, is relatively common in the Indian subcontinent that is reflected in our study and these patients tend to be younger than those with portal hypertension due to other causes.<sup>16</sup> Another study



**Fig. 1** (A) i. Endoscopy showing active bleeding from the duodenal varices. ii. Repeat endoscopy after 2 weeks of glue injection in the same patient. (B) Endoscopy showing duodenal varices in second part of duodenum with stigmata of recent bleeding. (C) Large conglomerate of duodenal varices in third part of duodenum.



**Fig. 2** Flowchart depicting algorithm of our study.

that enrolled 25 patients treated with endoscopic glue injection for duodenal variceal bleeding showed that the most common cause of duodenal varix was EHPVO in 19 (76%) followed by chronic liver disease in 5 (20.0%) patients.<sup>17</sup> This study also showed that five (20.0%) patients had rebleeding after initial endotherapy, and no death was observed during the follow-up that is in concurrence with our own study. The high rate of rebleeding (19.04%) in our study could be related to the severity of underlying liver disease as patients with advanced cirrhosis are more likely to present with rebleeds.<sup>18</sup>

Western data have shown that ectopic varices are more frequently noted in the duodenal bulb, while a Japanese study reported that the most common site of occurrence of DV was the descending duodenum.<sup>4,19</sup> In our own study, DVs were most common in the duodenal bulb and were seen in 21 patients, followed by second part of duodenum in 17 patients, while 3 patients had varices in the third part of duodenum. Therefore, it is advocated that endoscopists attempt to reach as far as possible into the duodenum as most of the DVs are within the reach of a standard endoscope.<sup>13</sup> Approximately 25% of patients with DVs also have associated esophagogastric varices. While 31.7% of our patients with DVs had associated esophageal varices, 4.88% patients had associated gastric varices, and 34.14% had combined esophagogastric varices.

Varices of the small bowel and colon are commonly seen in patients with IPH who have previously undergone abdominal surgery. We had three such patients with previous history of abdominal surgeries (→ **Table 1**). Although the exact cause for this is not known, it is postulated that the postoperative inflammation impedes hepatic blood flow and in turn causes portal hypertension.<sup>20</sup>

The role of endoscopic therapy in nonbleeding DV is not clear; however, endoscopic injection of glue has been shown to be safe and effective therapeutic modality for those with bleeding DV but complications such as rebleeding or thromboembolic complications have been reported with its use.<sup>10,21</sup> A randomized controlled trial supports the use of endoscopic cyanoacrylate glue in achieving rapid hemostasis in patients with isolated gastric varices including DVs.<sup>22</sup> Apart from four patients presenting with rebleeding on follow-up, none of our patients had documented thromboembolic events following cyanoacrylate injection. Available literature supports the use of secondary interventional procedures like transjugular intrahepatic portosystemic shunting (TIPS), balloon-occluded retrograde transvenous obliteration band ligation (BRTO) with surgical procedures such as duodenectomy, and gastroduodenectomy if all other treatment measures have failed in patient with recurrent DV bleeding. Limited data from case reports and case series has shown that (TIPS) and BRTO effectively achieved hemostasis



in patients with bleeding DVs; however, apart from being more invasive, these modalities are often associated with a high risk of precipitating hepatic encephalopathy, notably with TIPS.<sup>19,23–26</sup> In addition, both modalities remain limited to hospitals with technical expertise in radiological intervention. Previous studies have demonstrated that surgical procedures are associated with a high rate of rebleeding and mortality for bleeding ectopic varices, particularly in patients with cirrhosis and portal hypertension.<sup>2,25</sup> Medication alone has limited efficacy in cases of duodenal variceal bleeding.<sup>23</sup>

Endoscopic banding has been recommended if the diameter of the varix is less than the diameter of the endoscope, and some have reported successful application of bands for ligation of DV, while others have questioned the usage of band ligation based on animal studies, which suggest a higher likelihood of perforation.<sup>3,27–29</sup> A case of fatal rebleeding after band ligation of DV has also been reported.<sup>30</sup> We achieved fair amount of success with glue injection and hence had no opportunity to fall back on banding. Endoscopic glue injection is fraught with complications such as pulmonary and systemic arterial embolization, portal and mesenteric vein thrombosis, sepsis, and variceal ulceration due to extrusion of glue.<sup>31</sup> Apart from transient abdominal discomfort noted in five patients post-endoscopic glue injection, no major adverse events or mortality was reported in our study.

Our study has limitations, one of which is the retrospective nature of the study. As the treatment of DVs was successfully achieved with endoscopic cyanoacrylate glue injection, we have no experience with other modalities of therapy to compare with. Our study strength is the fairly large number of patients with DVs who were successfully managed with glue injection. This modality can easily be applied in resource-limited settings.

## Conclusion

Bleeding DVs may be the first manifestation of underlying portal hypertension, and careful endoscopic screening of the duodenum should be performed in all patients presenting with UGI bleeding to look for DVs. Our experience suggests that early diagnosis with prompt endoscopic intervention with cyanoacrylate glue injection of the DVs is a safe and effective treatment modality when performed by experienced endoscopists in the acute setting.

### Funding

None.

### Conflict of Interest

None declared.

### Acknowledgments

We would like to thank Mrs. Edel Quinn for her technical support.

## References

- 1 Kinkhabwala M, Mousavi A, Iyer S, Adamsons R. Bleeding ileal varicosity demonstrated by transhepatic portography. *AJR Am J Roentgenol* 1977;129(03):514–516
- 2 Khouqeer F, Morrow C, Jordan P. Duodenal varices as a cause of massive upper gastrointestinal bleeding. *Surgery* 1987;102(03):548–552
- 3 Norton ID, Andrews JC, Kamath PS. Management of ectopic varices. *Hepatology* 1998;28(04):1154–1158
- 4 Watanabe N, Toyonaga A, Kojima S, et al. Current status of ectopic varices in Japan: Results of a survey by the Japan Society for Portal Hypertension. *Hepato Res* 2010;40(08):763–776
- 5 Henry ZH, Caldwell SH. Management of bleeding ectopic varices. *Tech Gastrointest Endosc* 2017;19:101–107
- 6 Helmy A, Al Kahtani K, Al Fadda M. Updates in the pathogenesis, diagnosis and management of ectopic varices. *Hepato Int* 2008;2(03):322–334
- 7 Garcia-Tsao G, Abraldes JG, Berzigotti A, Bosch J. Portal hypertensive bleeding in cirrhosis: risk stratification, diagnosis, and management: 2016 practice guidance by the American Association for the study of liver diseases. *Hepatology* 2017;65(01):310–335
- 8 Linder S, Wiechel KL. Duodenal varicose veins. *Surg Endosc* 1991;5(01):31–35
- 9 Kakizaki S, Toyoda M, Ichikawa T, et al. Clinical characteristics and treatment for patients presenting with bleeding duodenal varices. *Dig Endosc* 2010;22(04):275–281
- 10 Liu Y, Yang J, Wang J, et al. Clinical characteristics and endoscopic treatment with cyanoacrylate injection in patients with duodenal varices. *Scand J Gastroenterol* 2009;44(08):1012–1016
- 11 Matsui S, Kudo M, Ichikawa T, Okada M, Miyabe Y. The clinical characteristics, endoscopic treatment, and prognosis for patients presenting with duodenal varices. *Hepatogastroenterology* 2008;55(84):959–962
- 12 Bhasin DK, Sharma BC, Sriram PV, Makharia G, Singh K. Endoscopic management of bleeding ectopic varices with histoacryl. *HPB Surg* 1999;11(03):171–173
- 13 Lebrec D, Benhamou JP. Ectopic varices in portal hypertension. *Clin Gastroenterol* 1985;14(01):105–121
- 14 Itzchak Y, Glickman MG. Duodenal varices in extrahepatic portal obstruction. *Radiology* 1977;124(03):619–624
- 15 Tanaka T, Kato K, Taniguchi T, Takagi D, Takeyama N, Kitazawa Y. A case of ruptured duodenal varices and review of the literature. *Jpn J Surg* 1988;18(05):595–600
- 16 Khanna R, Sarin SK. Non-cirrhotic portal hypertension - diagnosis and management. *J Hepato* 2014;60(02):421–441
- 17 Chaudhari H, Tandan M, Ramchandani M, Lakhtakia S, Gupta R, Reddy DN. Clinical profile, efficacy and outcome of endoscopic management of duodenal variceal bleeding with cyanoacrylate glue injection. *Dig Endosc* 2017;29:91
- 18 Yipeng W, Cong L, Sizhe W, Chenkai H, Anjiang W, Xuan Z. Effectiveness and safety of endoscopic treatment for duodenal variceal bleeding: a systematic review. *Eur J Gastroenterol Hepatol* 2021;33(04):461–469
- 19 Jonnalagadda SS, Quason S, Smith OJ. Successful therapy of bleeding duodenal varices by TIPS after failure of sclerotherapy. *Am J Gastroenterol* 1998;93(02):272–274
- 20 Tai Y, Tong H, Wei B, Wu H. Ectopic variceal bleeding after hepatobiliary surgery: a case report. *Medicine (Baltimore)* 2021;100(09):e24975
- 21 Miyakoda K, Takedatsu H, Emori K, et al. N-butyl-2-cyanoacrylate (histoacryl) glue in the right atrium after endoscopic injection for a ruptured duodenal varix: complication of histoacryl injection. *Dig Endosc* 2012;24(03):192
- 22 Sarin SK, Jain AK, Jain M, Gupta R. A randomized controlled trial of cyanoacrylate versus alcohol injection in patients with isolated fundic varices. *Am J Gastroenterol* 2002;97(04):1010–1015

- 23 Iqbal S, Likhtshteyn M, O'Brien D, McFarlane SI, Martinez M. Duodenal varix rupture – a rare cause of fatal gastrointestinal hemorrhage: a case report and review of literature. *Am J Med Case Rep* 2019;7(04):62–66
- 24 Anand R, Ali SE, Raissi D, Frandah WM. Duodenal variceal bleeding with large spontaneous portosystemic shunt treated with transjugular intrahepatic portosystemic shunt and embolization: a case report. *World J Radiol* 2019;11(08):110–115
- 25 Wahl P, Lammer F, Conen D, Schlumpf R, Bock A. Septic complications after injection of N-butyl-2-cyanoacrylate: report of two cases and review. *Gastrointest Endosc* 2004;59(07):911–916
- 26 Oey RC, de Wit K, Moelker A, et al. Variable efficacy of TIPSS in the management of ectopic variceal bleeding: a multicentre retrospective study. *Aliment Pharmacol Ther* 2018;48(09):975–983
- 27 Schmeltzer PA, Smith MT. Duodenal variceal bleeding successfully treated with endoscopic banding (with video). *Gastrointest Endosc* 2011;74(03):716–717
- 28 Sousa HT, Gregório C, Amaro P, et al. Successful endoscopic banding after cyanoacrylate failure for active bleeding duodenal varix. *Rev Esp Enferm Dig* 2008;100(03):171–172
- 29 Kakutani H, Sasaki S, Ueda K, et al. Is it safe to perform endoscopic band ligation for the duodenum? A pilot study in ex vivo porcine models. *Minim Invasive Ther Allied Technol* 2013;22(02):80–83
- 30 Machida T, Sato K, Kojima A, et al. Ruptured duodenal varices after endoscopic ligation of esophageal varices: an autopsy case. *Gastrointest Endosc* 2006;63(02):352–354
- 31 Al-Hillawi L, Wong T, Tritto G, Berry PA. Pitfalls in histoacryl glue injection therapy for oesophageal, gastric and ectopic varices: a review. *World J Gastrointest Surg* 2016;8(11):729–734