



# Role of Interventional Inflammatory Bowel Disease (IBD) in the Management of Complex IBD: Initial Prospective Experience from a Tertiary Center in India

Partha Pal<sup>1</sup> Mohan Ramchandani<sup>1</sup> Rupa Banerjee<sup>1</sup> Pradev Inavolu<sup>1</sup> Zaheer Nabi<sup>1</sup>  
 Hardik Rughwani<sup>1</sup> Aniruddha Pratap Haripal Singh<sup>1</sup> Rajendra Patel<sup>1</sup> Polina Vijayalaxmi<sup>1</sup>  
 Jagdeesh Rampal Singh<sup>2</sup> Pradeep Rebala<sup>3</sup> Guduru Venkat Rao<sup>3</sup> D Nageshwar Reddy<sup>1</sup> Manu Tandan<sup>1</sup>

<sup>1</sup>Department of Medical Gastroenterology, Asian Institute of Gastroenterology, Hyderabad, Telangana, India

<sup>2</sup>Department of Interventional Radiology, Asian Institute of Gastroenterology, Hyderabad, Telangana, India

<sup>3</sup>Department of Surgical Gastroenterology, Asian Institute of Gastroenterology, Hyderabad, Telangana, India

Address for correspondence Partha Pal, MD, DNB, MRCP, Consultant Gastroenterologist, 6-3-661, Asian Institute of Gastroenterology, Hyderabad 500082, India (e-mail: partha0123456789@gmail.com).

J Digest Endosc 2022;13:207–217.

## Abstract

### Keywords

- ▶ interventional inflammatory bowel disease
- ▶ endoscopic balloon dilation
- ▶ endoscopic stricturotomy
- ▶ enteroscopy
- ▶ colitis-associated neoplasia
- ▶ endoscopic mucosal resection
- ▶ endoscopic submucosal dissection

**Background/Aims** With the growing multidisciplinary model of practice in the management of complex inflammatory bowel disease (IBD) and rising incidence of IBD, interventional IBD (IIBD) promises to play a key role. We aimed to evaluate current the role of IIBD in India and its short-term outcomes.

**Methods** IBD patients undergoing IIBD procedures for stricture, bleeding, colitis-associated neoplasia, therapeutic small bowel endoscopy including retained capsule retrieval and postsurgical complications were enrolled prospectively between September 2021 and May 2022. Demographic and disease details, indications, initial and redo procedure details, technical/clinical success, and complications were recorded.

**Results** IIBD procedures were performed in total 54 patients (61% males, median age: 37.5 years, range: 21–74 years, Crohn's disease [CD]: 42, ulcerative colitis [UC]: 12 between September 2021 and April 2022). Endoscopic balloon dilation (EBD) was performed in 44 patients (56 strictures, 9% anastomotic, 9% pouch) who underwent total 83 EBD procedures in 63 sessions. Short-term clinical efficacy after maximal dilation, technical success (i.e., scope passage after EBD), and complications (all mild) were noted in 95.4, 81.8, and 9.1%, respectively. Recurrent symptoms were seen in 27.3% on short-term follow-up (1–8 months, median: 5 months) for which redilation, surgery, and endoscopic stricturotomy were done in 22.7, 2.3, and 2.3% respectively. During small bowel EBD, motorized spiral enteroscopy-guided retained capsule endoscope retrieval was done in four patients. Ulcerative colitis-associated neoplasia (UCAN) was resected endoscopically in six patients (endoscopic submucosal dissection

DOI <https://doi.org/10.1055/s-0042-1757470>.  
 ISSN 0976-5042.

© 2022. The Author(s).

This is an open access article published by Thieme under the terms of the Creative Commons Attribution License, permitting unrestricted use, distribution, and reproduction so long as the original work is properly cited. (<https://creativecommons.org/licenses/by/4.0/>)

Thieme Medical and Scientific Publishers Pvt. Ltd., A-12, 2nd Floor, Sector 2, Noida-201301 UP, India

(ESD)—1, endoscopic mucosal resection (EMR)—5). High-grade dysplasia was resected in two patients (1 ESD for recurrent UCAN, 1 EMR had residual neoplasia on follow-up treated with underwater EMR). R0 resection was achieved in 83.3%. Endoscopic hemostasis was done with hemoclippping and sclerotherapy for UC-related bleeding in two, whereas a case of CD with proximal ileal bleeding was controlled with antegrade single-balloon enteroscopy-assisted hemoclippping.

**Conclusions** IIBD is a promising modality in resource-limited settings like India acting as a bridge between medical therapy and surgery. Surgery can be avoided in a significant proportion with good short-term outcomes. Long-term outcomes need to be evaluated.

## Introduction

Inflammatory bowel disease (IBD) is on the rise in India with estimated burden of disease (1.5 million) nearing that of the United States.<sup>1,2</sup> Earlier the role of endoscopy in IBD was limited to diagnosis and monitoring of IBD, dysplasia surveillance, and polypectomy for sporadic adenoma.<sup>3</sup> Later endoscopic balloon dilation (EBD) for IBD-related or postoperative strictures was performed by endoscopists with interest in IBD or IBD specialists with interest in interventional endoscopy.<sup>3</sup> Subsequently, it was shown that endoscopic stricturotomy (ES) is a better modality for treating IBD related strictures (specially short and anastomotic strictures) than EBD lowering the risk of future surgery and procedure-related perforation albeit with an increased risk of bleeding.<sup>4</sup> Endoscopic incision therapy with needle knife/insulated tip (IT) knife was shown to be not only superior to EBD but also noninferior to redo surgery in chronic pouch anastomotic sinus in ulcerative colitis (UC) and ileocolic anastomotic stricture in Crohn's disease (CD) thus reducing surgical morbidity.<sup>5,6</sup> Similarly, colectomy was indicated for any grade of dysplasia in UC/colonic CD until it was recognized that endoscopy resection (endoscopic mucosal resection/ endoscopic submucosal dissection [EMR/ESD]) for visible dysplasia including high-grade dysplasia with continued surveillance can avoid colectomy. Almost all of the pouch complications (leak, stricture, sinus, fistula, CD of pouch and floppy pouch) can be treated endoscopically along with medical therapy avoiding morbidity of redo pouch surgery or pouch excision.<sup>7,8</sup> The current indications of IIBD include strictures, fistula, sinuses, abscess, leaks, bleeding, neoplasia, and removing foreign bodies (e.g., retained video capsule endoscope). Hence, IIBD has emerged as a bridge between medical and surgical management of IBD. IIBD is not only helpful in treating disease complications (e.g., stricture, fistula, abscess, and neoplasia) and thus avoiding surgery but also can be very useful in treating postsurgical recurrence and complications (e.g., pouch strictures, leaks, and sinuses) given the chronic, disabling nature of IBD.<sup>3</sup> Although there is abundant literature from the West on IIBD and recently global IIBD group has published guidelines on the management of CD-related strictures and evaluation of altered bowel postsurgery in IBD, there is paucity of published literature from India on IIBD.<sup>8-10</sup> Hence, we planned to prospectively

evaluate the technical and clinical success and short-term outcomes of IIBD procedures in a high-volume tertiary care center with a well-established IBD clinic and registry.

## Methods

### Study Settings and Population

The study was conducted in IBD patients requiring an IIBD procedure (e.g., EBD, and ES) in a high-volume gastroenterology center in southern India with a well-established IBD registry of over 6000 patients. The research assistant or the investigator interviewed all patients to elicit clinical and disease-related details and recorded the procedural details (e.g., technical success and scope passage after EBD) and enter the anonymized data onto a web-based platform "google form" that was later exported to Microsoft Excel for data analysis. Later these patients were followed up physically or telephonically for evaluating the short-term clinical efficacy and recurrent symptoms. Redo EBD, rescue therapy, or surgical details on follow-up were also recorded and analyzed.

### Interventions

Interventional IBD (IIBD) procedures included (1) EBD or ES for IBD-related strictures (includes upper gastrointestinal (GI), small bowel, large bowel, anastomotic, and pouch stricture EBD or stricturotomy), (2) endoscopic resection of colitis-associated neoplasia (polypectomy/EMR/ESD), (3) endoscopic hemostasis in IBD (hemoclips), and (4) enteroscopic retrieval of retained capsule endoscope.

EBD procedures were done with wire-guided controlled radial expansion balloon (Boston Scientific, Marlborough, Massachusetts, United States) of various sizes based on tightness and estimated diameter of the stricture (10–12 mm, 12–15 mm, 15–18 mm, 18–20 mm) with graded dilations with inflation pressures varying from 3 to 8 atm pressure. Balloon was inflated for at least 2 minutes and slowly deflated. For mild ooze post-EBD, balloon tamponade was also done with the same balloon. At the initial session, we at least tried to dilate upto an extent so that the scope used for dilation can be passed beyond the stricture postdilation. The patients were asked for repeat intervention after 2 weeks if the dilation goal was not reached (i.e., in terms of the size of the balloon or improvement in symptoms) at the initial endoscopy. For small bowel

strictures not reachable by endoscope or colonoscope were redilated only if symptoms recur after initial dilation that is clinically successful. The endpoint for dilation was clinical (symptomatic relief) and endoscopic success (passage of scope used to dilate the stricture postdilation). EBD without fluoroscopy was done in majority of the patients requiring ileocolonic EBD and small-bowel EBD by single-balloon enteroscope with direct visualization of stricture dilation through the balloon. Fluoroscopy was used for select complicated colonic strictures, gastroduodenal strictures, and novel motorized spiral enteroscopy (NMSE)-guided balloon dilation.<sup>11</sup>

ES was done using a needle knife/insulated tip knife with Endocut Q (effect—3, cut duration—1, cut interval—3) as per by global IIBD group consensus.<sup>9</sup> Multiple radial incisions were made circumferentially to completely disrupt the stenotic rim so that scope can be passed after procedure. The incision depth was assessed using the needle-knife/IT knife length as a comparator.<sup>12,13</sup>

NMSE was done under general anesthesia after 8 hours fasting, whereas single-balloon enteroscopies were done under propofol sedation.

Resection of ulcerative colitis-associated neoplasia (UCAN) was done using standard ESD and EMR techniques. Underwater EMR was done in areas of scarring and submucosal fibrosis that helps with “floating” effects.<sup>14</sup> To overcome effects of submucosal fibrosis, traction and water pressure assistance was used for ESD.<sup>15,16</sup>

Hemostasis was achieved with different hemoclips: EZ clip (Olympus America), Resolution clip (Boston Scientific), or Medorah clip (Medorah Meditek).

### Primary and Secondary Outcome Measures

The primary aim of the study was to evaluate the short-term clinical efficacy of IIBD procedures. Technical success, recurrent symptoms requiring rescue procedures on short-term follow-up, and procedure-related adverse events were secondary outcomes. For endoscopic resection of colitis-associated neoplasia, R0 resection was the primary outcome and secondary outcome measures were en bloc resection, and residual or recurrent neoplasia and procedure-related adverse events were the secondary outcomes.

### Sampling Strategy

#### Inclusion Criteria

1. Patients with confirmed diagnosis of IBD warranting a IIBD procedure were included in the study.

#### Exclusion Criteria

1. Patients in whom IBD was ruled out or in cases where diagnostic dilemma persists (e.g., tuberculosis).
3. Pregnant or breast feeding.
4. Significant comorbidity (significant cardiac or pulmonary illness, chronic liver or kidney diseases, systemic malignancy, etc.) that precludes IIBD or surgical therapy.

5. Inflammatory and predominantly inflammatory mixed strictures, stricture with complications (fistula/abscess), and long strictures more than 5 cm.

6. Uncorrected severe anemia (<7 g/dL), low platelets count (<50,000/mm<sup>3</sup>) and ongoing anticoagulant therapy.

### Data Collection

For patients, a detailed proforma including demographic details (age, sex, IBD type), indication of IIBD procedure (stricture, neoplasia, etc.), details of treated lesion (e.g., number of strictures, location), past history of surgery or IIBD procedure, procedural details (number of EBD procedures, mode of endoscopy, caliber of dilation, technical success, scope passage after EBD/ES), clinical improvement postprocedure, complications (major or minor), histology and R0 resection rates in case of colitis-associated neoplasia, and short-term clinical improvement were recorded initially. Prior to the procedure, each case was discussed in institutional dedicated IIBD forum that consisted of IBD specialists, interventional and small bowel endoscopists, GI surgeon, and interventional radiologist for careful selection of the cases and reviewing indications and probable modality to be used. On follow-up, data on symptomatic recurrence (in case of stricture/bleed), redo procedure, or rescue surgery were also recorded.

### Definitions

Stricture was defined according to the European Crohn's and Colitis organization definition that is narrowing of the intestinal lumen. Based on cross-sectional imaging, stricture was defined as follows: a combination of a reduction in luminal narrowing more than 50%, an increase in bowel wall thickness more than 25% relative to nonaffected bowel, and prestricture dilation more than 3 cm. From the clinical perspective, for lesions detected during an endoscopic examination, an inability to pass an adult colonoscope through was considered as nonpassable stricture.<sup>17</sup> In our study, we considered symptomatic and nonpassable strictures for endoscopic therapy.

Procedural success for EBD was defined as ability to perform the EBD procedure. Technical success (scope passage after EBD/strictureotomy) was assessed as a separate outcome that was defined as passage of endoscope through the area where EBD/ES was performed. This included colonoscope for colonic/pouch strictures, endoscope for upper GI and duodenal strictures, and an enteroscope: motorized spiral or single balloon enteroscope for small bowel strictures except those in terminal ileum. Short-term clinical efficacy in EBD/ES was defined as clinical improvement in symptoms (pain/intestinal, gastric outlet, or colonic obstruction symptoms) after the procedure. Adverse events were reported as per American Society of Gastrointestinal Endoscopy (ASGE) lexicon for endoscopic adverse events.<sup>18</sup> The adverse events were initially classified as cardiovascular, pulmonary, and procedure related (perforation/bleeding). For each adverse events, qualifiers such as timing (intra-procedure, postprocedure <14 days, and delayed >14 days),

attribution (definite, probable, possible, and unlikely), and severity (mild moderate, severe, fatal) were used.<sup>18</sup> Recurrence of symptoms was defined as re-emergence of symptoms for which the procedure was initially performed. R0 resection for UCAN was defined as histologically free margin postendoscopic resection. En bloc resection was defined removal of UCAN as a whole rather than piece-meal removal.

### Statistical Analysis

All the data were exported from “google form” to Microsoft Excel and later analyzed by statistical package for social sciences (SPSS version 26, IBM Corp., Armonk, New York, United States). Continuous variables are expressed as median (range) and categorical variables were expressed as number (n) and percentage (%).

### Ethical Considerations

The study was approved by the institutional review board (AHF-RAC-09/24/2021). Written informed consent was taken from each patient and the study conformed to the 1975 Declaration of Helsinki ethical guidelines mentioning the indication of the procedure, alternative treatment modalities, and possible adverse events and their management. For all cases undergoing small bowel endoscopy with anticipated EBD, a prior informed consent was taken.

## Results

### Endoscopic Balloon Dilatation

Total 44 patients (age: 21–74 years, median: 37, 57% male, CD –41, UC–3) had 56 strictures and underwent 83 EBD procedures in 63 sessions (10 patients had 2 strictures, one patient had 3, and 10 had anastomotic strictures) (single stricture × two sessions–6, single stricture × 3 sessions–2, two strictures × two session–5, two strictures × three session–1, three strictures × two sessions–1). About 9.1% (4/44) patients had prior EBD in the same institute prior to initiation of study period (►Table 1). The appropriate endoscopy was used as discussed earlier except for two cases: two proximal jejunal strictures in a patient was dilated using pediatric colonoscope and a distal ileal stricture that was dilated using a colonoscope with deep ileal intubation. The mean caliber of balloon dilatation was less than 15 mm in pyloroduodenal strictures, whereas it was equal to or more than 15 mm colonic strictures. Two of forty-four patients (4.5%) were on biologic therapy (both infliximab). No adverse events were noted in them post-EBD. The median duration of IBD diagnosis was 36 months (range: 1–156 months) and the median duration of obstructive symptoms was 6 months (1–14 months).

Among the strictures, 35 were purely fibrotic stricture, 20 had mixed stricture (with minimal inflammatory component), and 1 had purely inflammatory stricture. EBD in two cases avoided surgery: (1) GenEBD (12 mm) in an inflammatory tight sigmoid stricture (in a newly diagnosed CD), (2) CD-related tight ileocecal stricture presenting with partial intestinal obstruction (post-antitubercular therapy for 6

months). No complications occurred in either of the procedures.

Three patients had pouch-related strictures (3 anastomotic strictures [►Fig. 1A–C], 1 pouch inlet stricture [►Fig. 1D–F], and a stricture at efferent limb). The case with pouch inlet stricture had recurrent symptom post-EBD and was redilated and later found to have CD of the pouch.

Procedural success was achieved in all cases, although technical success (scope passage after procedure) can be done in 81.8% cases. Short-term clinical efficacy improved from 88.6% after first session of dilation to 95.4% after maximal dilation. None had moderate-to-severe complications as per ASGE lexicon for endoscopic adverse events. A patient with tight rectal stricture (in long standing CD) had microperforation post-EBD and was managed conservatively and was discharged in next 2 days postprocedure after contrast study confirmed no extravasation. This patient was subjected to surgery later due to refractory, long, symptomatic stricture. Among minor complications, two patients had bleeding post-EBD—both were managed with balloon tamponade; in one case 50% dextrose was used as local hemostatic agent.<sup>9</sup> None of them required transfusion. One patient had pain postprocedure; computed tomography (CT) showed no leak and hospital stay was not prolonged.

In a short follow-up time (1–8 months, median 5 months), 27.3% patients had recurrent symptoms among which 22.7% underwent redilation; rest patients were managed with optimization of medical therapy alone. As mentioned earlier, one patient underwent surgery. One patient with recurrent symptoms after two unsuccessful EBD sessions underwent ES.

### Endoscopic Stricturectomy

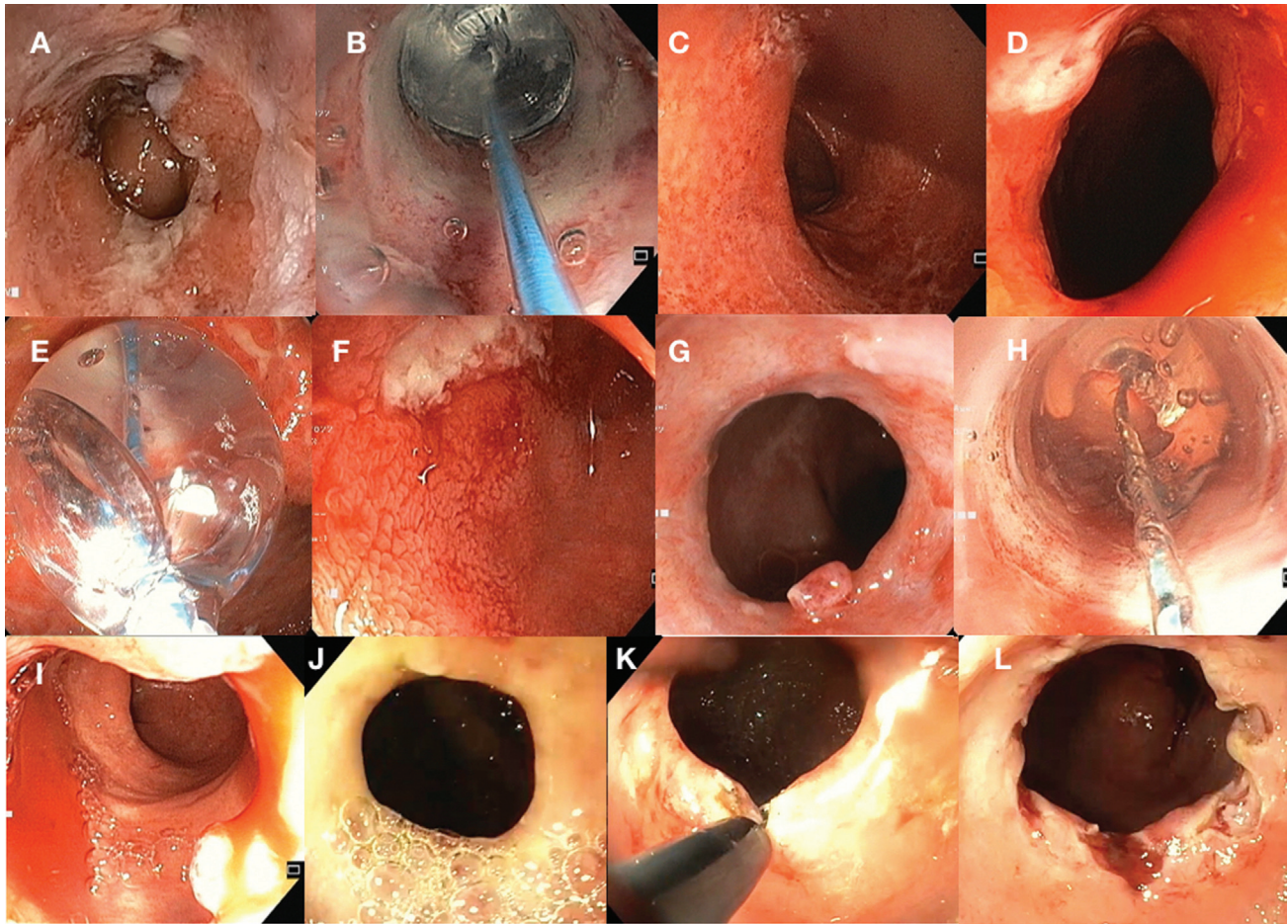
ES was done in a patient with ankylosing spondylitis with duodenal CD with one pyloric and two duodenal strictures (one in D1, another at D1-D2 junction). The case presented with symptoms of gastric outlet obstruction and failed EBD (13.5 and 15 mm) twice in spite of optimization of medical therapy. The benefit of EBD lasted for less than a month for each session of EBD. Radial incisions were made circumferentially to cut the fibrotic tissue for pyloric ring and D1 stricture (►Fig. 1J–L), whereas D1-D2 stricture dilated with balloon as stricturectomy was not feasible due to angulation. In the given case, eight radial incisions were made in the duodenal stricture, although excision of the fibrotic tissue was not performed as the culprit stricture was at the junction of first and second part of duodenum with high risk of perforation. For the pyloric ring stricture which was traversable, six incisions were enough for passing the scope without any resistance. Currently, at 6 months follow-up, the patient is asymptomatic. Clips as spacers were not applied as described by global IIBD group as endoscopic stricturectomy to prevent delayed bleeding or reapposition of cut margins in stricture.<sup>9</sup> No complications were noted postprocedure and the patient is symptom free on a follow-up of 1 month.

**Table 1** Technical and clinical details of patients undergoing endoscopic balloon dilation (EBD) as interventional inflammatory bowel disease (IIBD) procedure

	Gastroduodenal	Small bowel	Ileo-colonic	Postsurgical anastomosis	Pouch
Number of patients (n = 44)	2	15	19	5	3
Number of strictures (n = 56)	4	20	22	5	5
Total sessions of dilation	4 (1 had 3 sessions)	27 (5 had 2 sessions, 2 had 3 sessions)	21 (2 had 2 sessions)	8 (one had 2 sessions and another had 3 sessions)	6 (all had 2 sessions)
Mode of endoscopy	EGD	NMSE <sup>5</sup> /SBE <sup>10</sup> /pediatric colonoscope <sup>2</sup> /colonoscope <sup>2</sup> /EGD through ileostomy stoma <sup>1</sup>	Colonoscopy (2 postdiversion)	Colonoscopy (5 ileo-transverse, 1 ileo-rectal)	Colonoscopy (3 anal anastomosis, 1 inlet and 1 outlet)
Mean caliber of maximum dilation (mm)	13.5	16.1	15.6	16.3	16.9
Procedural success	100%				
Technical success (scope passage postdilation)	2/2 (100%)	10/15 (66.7%)	17/19 (89.4%)	4/5 (80%)	3/3 (100%)
Short term clinical success (after first session of dilation)	1/2 (50%)	13/15 (86.6%)	18/19 (94.7%)	5/5 (100%)	2/3 (66.7%)
Recurrence of symptoms	1/2 (50%)	2/15 (13.3%) (1 repeat EBD, another better with medical management)	5/19 (26.3%)	2/5 (40%)	2/3 (66.7%)
Surgery	0%	0%	1/19 (5.2%)	0%	0%
Repeat dilation	1/2 (50%)	1/15 (6.7%)	4/19 (21%)	2/5 (40%)	2/3 (66.7%)
Complications	0%	1/15 (6.7%) (minor ooze)	2/19 (10.5%) 1 micro-perforation, 1 pain	0%	1/3 (33%), mild ooze
Rescue endoscopic stricturotomy	1/2 (50%)	0%	0%	0%	0%

Abbreviations: EGD, esophagogastroduodenoscopy; NMSE, novel motorized spiral enteroscopy; SBE, single-balloon enteroscopy.





**Fig. 1** Stricture therapy in inflammatory bowel disease. (A) Postileal pouch anastomosis stricture in a case of ulcerative colitis. (B) Stricture dilated with 18 mm controlled radial expansion (CRE) balloon. (C) Pouch entered postdilation shows evidence of pouchitis. (D) Ulcerated stricture at pouch inlet. (E) Pouch inlet stricture dilated with CRE balloon up to 13.5 mm. (F) Endoscope negotiable into pouch inlet postdilation showing linear ulceration. (G) Stricture at site of rectovaginal fistula repair. (H) Stricture dilated with CRE balloon upto 18 mm. (I) Passable stricture postdilation. (J) Stricture at first part of duodenum in case of upper gastrointestinal Crohn's disease—failed balloon dilation for two sessions. (K) Endoscopic stricturotomy being performed with insulated tip knife. (L) Poststricturotomy passable stricture.

### Enteroscopy-Guided Retained Capsule Endoscopy Retrieval

All the retained capsules were in the proximal ileum as per capsule endoscopy and fluoroscopy images. NMSE was used for retrieval of retained capsules in these cases of CD. In two patients, there were strictures proximal to retained capsule that were dilated to 15 mm to allow passage of NMSE. The number of strictures were confirmed using fluoroscopy. In the other two cases, strictures were only distal to retained capsule that was removed after EBD of downstream strictures (►Fig. 2A–F; see ►Table 2).

### Endoscopic Resection of Ulcerative Colitis-Associated Neoplasia

Majority of the patients who underwent endoscopic resection for UCAN were middle aged or elderly with long-standing UC ( $\geq 8$  years) except two patients: one had symptomatic (2 cm) rectal inflammatory polyp and a case of broad-based vascular polyps in sigmoid colon. The later turned out to be low-grade dysplasia on histology (►Fig. 3G–I). Two cases had high-grade dysplasia—one was treated with

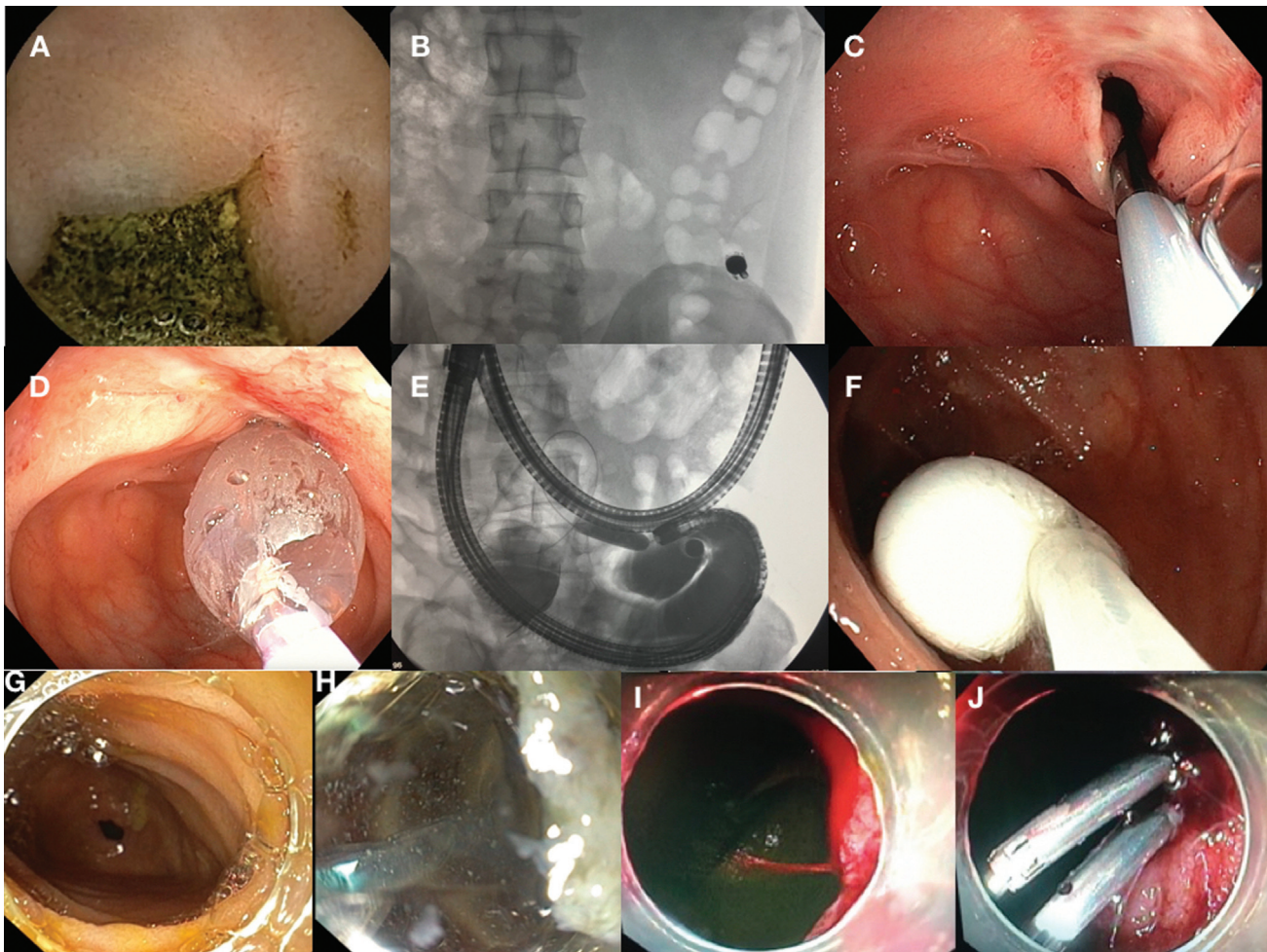
ESD (►Fig. 3A–C) and other with EMR (possibility of high-grade dysplasia not anticipated during resection as the lesion was JNET type 2A on narrow band imaging—NBI) (►Fig. 3D–F). In the later, follow-up colonoscopy showed small residual lesion at resection site that was resected using underwater EMR. R0 resection was achieved in all cases except one. The details of endoscopic resection for UCAN have been summarized in ►Table 3. All the lesions were visible on white light endoscopy, whereas case 2 (flat lesion) was better appreciated only on virtual chromoendoscopy (NBI).

### Endoscopic Hemostasis

Endoscopic hemostasis was done in three cases (►Table 4). The first case presented with a history of recurrent anemia; CT showed proximal ileal wall thickening suggestive of CD. During single-balloon enteroscopy (SBE), active spurt was noted that was controlled with hemoclips (►Fig. 2I–J). He was treated with medical therapy and on follow-up of 6 months had no recurrence of bleeding.

Second case of UC presented with bleeding per rectum, although stool frequency was under control. Sigmoidoscopy





**Fig. 2** Small bowel interventions in Crohn's disease (CD). (A) Video capsule endoscope (VCE) image showing impacted food residue impacted in proximal ileal stricture. (B) Fluoroscopy image showing position of impacted VCE. (C) Ulcerated stricture reached with novel motorized spiral enteroscopy and guidewire negotiated across stricture. (D) Controlled radial expansion (CRE) balloon dilation was done up to 12 mm given the ulcerated stricture. (E) Fluoroscopic image showing disappearance of balloon waist positioned in stricture and impacted VCE proximally. (F) Impacted VCE being retrieved with Roth net. (G) Tight proximal ileal stricture on antegrade single-balloon enteroscopy (SBE). (H) Stricture being dilated with 18 mm CRE balloon. (I) Case of CD with recurrent anemia: proximal ileal spurting vessel on SBE. (J) Two hemoclips applied to achieve hemostasis—no further rebleeding on follow-up.

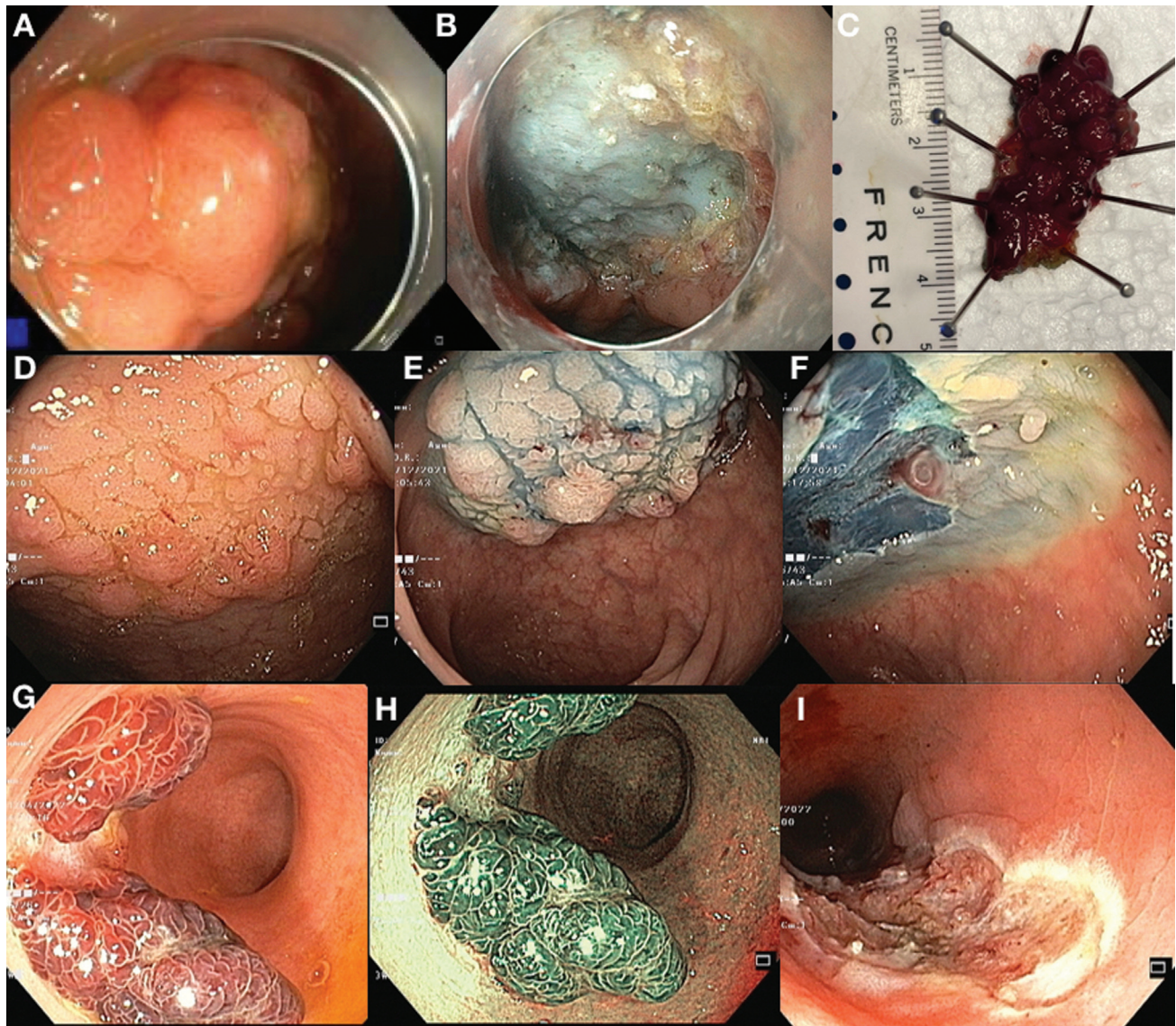
showed persistent ooze from a rectal ulcer near anal verge. Injection sclerotherapy using 3% polidocanol was successful in controlling the bleeding. Hemoclip was not used due to close proximity from anal verge. There was no recurrence of hematochezia with continued medical therapy on 4 months follow-up.

Third case had bleeding from a visible vessel in acute severe ulcerative colitis that was managed with hemoclips. However, there was rebleeding during same admission from an adjacent ulcer. However, he later responded to medical therapy (intravenous steroids) and colectomy was avoided.

**Table 2** Details of patients with Crohn's disease who underwent novel motorized spiral enteroscopy (NMSE)-guided capsule retrieval and endoscopic balloon dilation of strictures

	Age	Sex	Enteroscopy technique	Stricture upstream/downstream to retained capsule	Location	Dilation diameter (mm)
Case 1	29	Male	NMSE	Only downstream	Proximal ileum	12
Case 2	35	Male	NMSE	Upstream <sup>2</sup> + downstream	Proximal ileum	15
Case 3	25	Male	NMSE	Only downstream	Proximal ileum	12
Case 4	55	Female	NMSE	Upstream <sup>1</sup> + downstream	Proximal ileum	15





**Fig. 3** Endoscopic management of ulcerative colitis-associated neoplasia. (A) Recurrent large laterally spreading tumor rectum in case of ulcerative colitis (UC). (B) Postendoscopic submucosal dissection (ESD). (C) Specimen post en bloc resection (3 cm in size)-biopsy showed high-grade dysplasia (ESD). (D) Flat lesion in rectum in a case of UC. (E). Postsubmucosal injection. (F) Endoscopic mucosal resection (EMR) done: Biopsy showed foci of high-grade dysplasia. (G) Broad-based vascular polyps in sigmoid colon. (H) Narrow band imaging showed regular surface and vascular pattern. (I) Post-EMR site biopsy showed tubular adenoma with low-grade dysplasia.

## Discussion

In this prospective study, the first from our country of over 50 patients with IBD, endoscopic interventions were found to be useful in CD-related/anastomotic/pouch-related strictures, colitis-associated neoplasia, retained capsule retrieval due to CD-related strictures, and hemostasis for bleedings. Majority of the patients underwent EBD for strictures with excellent short-term clinical efficacy with recurrent symptoms in nearly one quarter of patients. The impact of EBD on patient management was profound as most of the patients could be salvaged from surgery. Ileostomy could be closed in all patients with strictures in diverted colon. Redo pouch surgery or pouch excision could be avoided in all patients with pouch-related strictures. Retained capsule endoscope re-

trieval was successful in all cases with additional therapeutic EBD and tissue diagnosis for CD with motorized spiral enteroscopy. Endoscopic hemostasis was feasible with acceptable rebleeding rates. Endoscopic resection (EMR/ESD) was successful in treating UCAN with 83.3% R0 resection rates. Residual lesion in a case treated subsequently with endoscopic therapy as well. The long-term results of stricture and colitis-associated neoplasia management in these patients are underway.

The main indications of IIBD include stricture, bleeding, fistula/abscess/sinuses, surgical leaks, colitis-associated neoplasia, and foreign body (e.g., retained capsule) removal.<sup>19</sup> Endoscopic stricture management can be done by EBD (>Fig. 1G–H; >Fig. 2G–H), ES, endoscopic stricturoplasty (stricturotomy with placement of clips as spacers), and stent



**Table 3** Procedural details of patients with ulcerative colitis who underwent endoscopic resection for visible colonic polypoidal lesions

	Age (years)	Sex	Duration of UC	Diagnosis	Modality of resection	Bx	En bloc resection	Ro resection	Treatment of residual or recurrent neoplasia
Case 1	54	Female	12 years	Recurrent large laterally spreading tumor rectum (3 cm) (JNET 2B)	ESD	HGD	En bloc	Yes	NA
Case 2	49	Male	10 years	Flat lesion (Paris IIb, JNET 2A) (2 cm)	EMR	Foci of HGD	Piecemeal	No, R1 resection	Underwater EMR
Case 3	66	Male	8 years	Subpedunculated lesion (Isp), JNET 2A (1 cm)	EMR	LGD	En bloc	Yes	NA
Case 4	26	Male	5 years	Broad based vascular polyps (Paris Isp) sigmoid colon (JNET 2A) (1.5–2 cm)	EMR	LGD	Piecemeal	Yes	NA
Case 5	69	Male	29 years	Sessile polyp in transverse colon (JNET 2A) (1 cm)	EMR	LGD	En bloc	Yes	NA
Case 6	62	Male	8 years	Rectum (Paris IIa, JNET 2A) (1.5 cm)	Band EMR	LGD	En bloc	Yes	NA
Case 7	25	Male	2 years	Symptomatic rectal inflammatory polyp (Paris Is, JNET 1) (1.5 cm)	EMR	Hyperplastic/inflammatory polyp	Piecemeal	Yes	NA

Abbreviations: EMR, endoscopic mucosal resection; ESD, endoscopic submucosal dissection; HGD, high-grade dysplasia; JNET, Japanese NBI (narrowband imaging) expert team classification; LGD, low-grade dysplasia; NA, not available; UC, ulcerative colitis.

placement. Endoscopic fully covered self expanding metal stent placement was shown to be inferior to EBD in a recent randomized controlled trial (RCT) with nearly half requiring reintervention at 1 year (compared with 19% in EBD arm).<sup>20</sup> Although EBD and ES have not been compared in a randomized manner, the technical success (100%) and immediate symptomatic improvement (73%) were higher with ES compared with EBD (90 and 45%, respectively,  $p = 0.25$  and  $0.08$ , respectively). No perforation occurred with ES, whereas 14% had bleeding requiring transfusion. Need for additional endoscopic therapy and surgery was lower with ES (29 and 10%, respectively) compared with EBD (34 and 60%,  $p = 0.85$  and  $0.03$ , respectively).<sup>4</sup> The reported technical success rates of EBD for gastroduodenal, small bowel, and ileocecal strictures according to meta-analysis (18 studies, 463 patients, 1189 EBDs) were 100, 95, and 90%, respectively.<sup>21</sup> Clinical success rates of EBD gastroduodenal, small bowel, and ileocecal strictures were 87, 82.3, and 80.8%, respectively. Recurrent symptoms occur in nearly 48% for small bowel and ileocecal strictures, whereas 70% for gastroduodenal strictures had recurrent symptoms. Surgery is required in close to 30% cases. Redilation rates in small bowel strictures were 38.8%. Complication rates were higher for small bowel structures (5.3%). These included studies had variable follow-up time. Roughly half had recurrent symptoms and two third required surgery.<sup>21</sup> High short-term efficacy and lower complication rates in our study could be due to careful selection of cases in IIBD forum prior to deciding on mode of therapy. Lower reprocedure rate could be attributed to very short follow-up time. The technical success rate in small bowel strictures was lower compared with clinical success as scope passage through stricture may be technically difficult in small bowel specially with large diameter motorized spiral enteroscope.

However, we performed ES in only one case refractory to EBD, although many of the endoscopists performing these procedures were expert third space endoscopists. This could be due to less experience with the procedure compared with EBD. Stricture therapy in CD is, however, moving from EBD to ES in the current era.<sup>19</sup> Results from well-designed future RCT and gaining experience with the procedure may result in higher use of this modality.

Pouch-related strictures were successfully treated in three patients along with medical management for pouchitis in three patients in our study. Among pouch-related complications, pouch strictures, floppy pouch complex, acute and chronic anastomotic leak, or sinuses were amenable to endoscopic therapy.<sup>7</sup>

The next most common indication of IIBD after strictures in our cohort was colitis-associated neoplasia. Endoscopically visible lesions with no deep submucosal invasion can be successfully resected endoscopically with EMR or ESD.<sup>22,23</sup> Resection of a nonlifting, fibrotic adenoma in descending colon using full thickness resection device has recently been reported.<sup>24</sup> Underwater EMR and traction or water pressure-assisted ESD can help in resecting UCAN in the presence of submucosal fibrosis.<sup>14–16</sup> Compared with non-UC patients, ESD in UC is associated with lower rate of R0 resection (71 vs.

**Table 4** Details of cases who underwent endoscopic hemostasis as interventional inflammatory bowel disease (IBD) procedure

	Age	Sex	Indication	Endoscope used	Hemostasis technique	Hemostasis achieved	Rebleeding
Case 1	36	Male	Crohn's disease with recurrent anemia—active ooze in proximal ileum	Single-balloon enteroscopy	Clips <sup>2</sup>	Yes	No
Case 2	34	Female	Ulcerative colitis rectal ulcer bleeding	Colonoscopy	Sclerotherapy	Yes	No
Case 3	40	Male	Acute severe ulcerative colitis with bleeding—visible vessel	Colonoscopy	Clips	Yes	Yes, mild—managed conservatively with standard of care

93%) probability due to technical difficulties arising from scarring and severe submucosal fibrosis that can be present in nearly 70% patients.<sup>25,26</sup> Similarly underwater EMR may help overcoming submucosal fibrosis by “floating” effect.<sup>14</sup> In our small series, R0 resection was noted in 83.3% cases. We did follow-up colonoscopy in only one patient who had R1 resection. Long-term effects are needed to be studied as local recurrence; metachronous tumor and additional surgery can be required post-ESD in 5, 6, and 10%, respectively, in a recent meta-analysis.<sup>26</sup> Bleeding and perforations have been reported in 8 and 6%, respectively, in the same study.<sup>26</sup> Results of ESD in UCAN are best for those with polypoidal lesion, noninvasive pit/vascular pattern without surface ulceration, distinct borders, and appropriate lifting on submucosal injection.<sup>27</sup> ESD has higher R0 resection rates than EMR for equal to or more than 11 mm lesions (94 vs. 55%) and nonpolypoidal lesions (100 vs. 55%).<sup>28</sup> We performed ESD in only one case as most of the other lesions were smaller and easily liftable on submucosal incision. As the evidences are emerging, newer guidelines and practices may change over the next few years for UCAN.

NMSE-guided retired capsule retrieval in CD-related strictures was successful in all patients with therapeutic EBD for strictures with symptomatic relief. Tissue diagnosis of CD was obtained additionally in three out of four cases in whom CD was diagnosed postcapsule endoscopy. Enteroscopy-guided biopsy was suggestive of CD in two cases (chronic inflammation with architectural distortion with or without granuloma), whereas in one case it was nonspecific. However, treatment as per probable CD based on imaging and EBD resulted in symptomatic remission in the later. NMSE has high total enteroscopy rates (nearly 70%) with ease for therapeutic intervention due to wide inner diameter of channel (3.2 mm) compared with balloon-assisted enteroscopy.<sup>29</sup> In this study, 23% patients underwent therapeutic procedures.<sup>29</sup> NMSE-assisted capsule retrieval after all bowel stricture dilation has been reported earlier.<sup>30</sup> However, we performed SBE-assisted EBD in almost all parts of small bowel (► **Table 1**). Hence, both modalities of enteroscopy may be effective for IIBD-related small bowel interventions with NMSE scoring over SBE except in cases not fit for general anesthesia, pediatric patients, or postoperative patients with adhesions that may preclude spiral enteroscopy progression.

Endoscopic hemostasis was reported in UC-related bleeding with rebleeding in a case of acute severe colitis in whom later colectomy could be avoided with continued medical therapy. SBE-guided hemostasis using hemoclips have been reported for proximal ileal bleeding. Enteroscopy-assisted hemostasis has been reported earlier.<sup>31,32</sup>

IIBD is still an evolving field and its application has several challenges. IIBD is still not widely accepted due to paucity of prospective and comparative data. The skills of an IIBD specialist should include understanding the underlying disease process and anatomy (e.g., postoperative) and advanced endoscopy skills. Training in IIBD is still not available in India. Learning curve for procedures like ES and ESD (in fibrotic colon) is high. Managing the adverse events like significant bleeding and perforation endoscopically needs advanced endoscopic skills. Moreover, surgical and interventional radiology backup to manage complications may not be present in all the centers. The lack of specific codes for IIBD procedures is another challenge that the endoscopist faces.

Our study has several important implications. IIBD can have an important role stricture management in de novo or postsurgical anastomotic strictures in CD with excellent short-term efficacy. The advantage is preservation of bowel length in CD. In UC, endoscopic resection techniques can effectively treat UCAN with high R0 resection rates avoiding colectomy. Moreover, IIBD can effectively treat pouch strictures averting need for redo surgery or pouch excision. Careful case selection with multidisciplinary IIBD team can avoid or manage complications of IIBD procedures effectively. The long-term efficacy needs to be studied in future.

There are few limitations of the current study. It is a single, tertiary center study with expert endoscopists performing IIBD procedures. So, the results may not be applicable universally. Another limitation is very short follow-up time in the cohort. The relatively small numbers limit the ability to study predictors of success of EBD. Moreover, we have not used an objective score to evaluate improvement in symptoms (e.g., CD obstruction score). However, none of earlier studies on EBD have used such scoring except for one studying effect of adalimumab on symptomatic small bowel stricture.<sup>21,33</sup>

In conclusion, IIBD has an ever-expanding role in the treatment of IBD-related complications as well as postsurgical adverse events serving as a bridge between medical and

surgical management. IIBD procedures are safe and have excellent short-term efficacy. These complex diseases and associated complications require knowledge of the disease, postsurgical anatomy, understanding of the principles, and indications of IIBD as well as the technical skills of therapeutic endoscopy. Unfortunately, there is paucity of personnel trained in IIBD as well as literature from India, where incidence of IBD is rising dramatically.

#### Conflict of Interest

None declared.

#### References

- Kedia S, Ahuja V. Epidemiology of inflammatory bowel disease in India: the great shift east. *Inflamm Intest Dis* 2017;2(02):102–115
- Furlow B. The challenge of inflammatory bowel disease in India. *Lancet Gastroenterol Hepatol* 2019;4(09):670–671
- Shen B. Interventional IBD: the role of endoscopist in the multi-disciplinary team management of IBD. *Inflamm Bowel Dis* 2018;24(02):298–309
- Lan N, Shen B. Endoscopic stricturotomy versus balloon dilation in the treatment of anastomotic strictures in Crohn's disease. *Inflamm Bowel Dis* 2018;24(04):897–907
- Lan N, Hull TL, Shen B. Endoscopic sinusotomy versus redo surgery for the treatment of chronic pouch anastomotic sinus in ulcerative colitis patients. *Gastrointest Endosc* 2019;89(01):144–156
- Lan N, Stocchi L, Delaney CP, Hull TL, Shen B. Endoscopic stricturotomy versus ileocolonic resection in the treatment of ileocolonic anastomotic strictures in Crohn's disease. *Gastrointest Endosc* 2019;90(02):259–268
- Shen B, Fleschner P, Shah SA. How do i diagnose and manage ileal pouch disorders? *Am J Gastroenterol* 2021;116(04):621–624
- Shen B, Kochhar GS, Kariv R, et al. Diagnosis and classification of ileal pouch disorders: consensus guidelines from the International Ileal Pouch Consortium. *Lancet Gastroenterol Hepatol* 2021;6(10):826–849
- Shen B, Kochhar G, Navaneethan U, et al. Practical guidelines on endoscopic treatment for Crohn's disease strictures: a consensus statement from the Global Interventional Inflammatory Bowel Disease Group. *Lancet Gastroenterol Hepatol* 2020;5(04):393–405
- Shen B, Kochhar GS, Navaneethan U, et al. Endoscopic evaluation of surgically altered bowel in inflammatory bowel disease: a consensus guideline from the Global Interventional Inflammatory Bowel Disease Group. *Lancet Gastroenterol Hepatol* 2021;6(06):482–497
- Rana SS, Bhasin DK, Chandail VS, et al. Endoscopic balloon dilatation without fluoroscopy for treating gastric outlet obstruction because of benign etiologies. *Surg Endosc* 2011;25(05):1579–1584
- Muto M, Ezoe Y, Yano T, et al. Usefulness of endoscopic radial incision and cutting method for refractory esophagogastric anastomotic stricture (with video). *Gastrointest Endosc* 2012;75(05):965–972
- Samanta J, Dhaka N, Sinha SK, Kochhar R. Endoscopic incisional therapy for benign esophageal strictures: technique and results. *World J Gastrointest Endosc* 2015;7(19):1318–1326
- Takabayashi K, Kato M, Sasaki M, et al. Underwater endoscopic mucosal resection for a sporadic adenoma located at severe longitudinal ulcer scars in ulcerative colitis. *Endoscopy* 2022;54(01):E30–E31
- Ozeki Y, Hirasawa K, Ikeda R, et al. Safety and efficacy of water pressure endoscopic submucosal dissection for colorectal tumors with submucosal fibrosis (with video). *Gastrointest Endosc* 2021;94(03):607–617.e2
- Yzet C, Lambin T, Lafeuille P, Fumery M, Pofelski J, Cotte E, Pioche M. Endoscopic submucosal dissection of high-grade dysplasia recurrence in ulcerative colitis using a multitractor technique. *Endoscopy* 2022;54(08):E433–E434
- Annese V, Daperno M, Rutter MD, et al; European Crohn's and Colitis Organisation. European evidence based consensus for endoscopy in inflammatory bowel disease. *J Crohn's Colitis* 2013;7(12):982–1018
- Cotton PB, Eisen GM, Aabakken L, et al. A lexicon for endoscopic adverse events: report of an ASGE workshop. *Gastrointest Endosc* 2010;71(03):446–454
- Shen B. Endoscopic management of inflammatory bowel disease-associated complications. *Curr Opin Gastroenterol* 2020;36(01):33–40
- Loras C, Andújar X, Gornals JB, et al; Grupo Español de Trabajo de la Enfermedad de Crohn y Colitis Ulcerosa (GETECCU) Self-expandable metal stents versus endoscopic balloon dilation for the treatment of strictures in Crohn's disease (ProtDilat study): an open-label, multicentre, randomised trial. *Lancet Gastroenterol Hepatol* 2022;7(04):332–341
- Bettenworth D, Bokemeyer A, Kou L, et al. Systematic review with meta-analysis: efficacy of balloon-assisted enteroscopy for dilation of small bowel Crohn's disease strictures. *Aliment Pharmacol Ther* 2020;52(07):1104–1116
- Smith LA, Baraza W, Tiffin N, Cross SS, Hurlstone DP. Endoscopic resection of adenoma-like mass in chronic ulcerative colitis using a combined endoscopic mucosal resection and cap assisted submucosal dissection technique. *Inflamm Bowel Dis* 2008;14(10):1380–1386
- Matsumoto K, Oka S, Tanaka S, et al. Long-term outcomes after endoscopic submucosal dissection for ulcerative colitis-associated dysplasia. *Digestion* 2021;102(02):205–215
- Baker G, Vadaketh J, Kochhar GS. Endoscopic full-thickness resection for the management of a polyp in a patient with ulcerative colitis. *Cureus* 2022;14(05):e24688
- Kasuga K, Yamada M, Shida D, et al. Treatment outcomes of endoscopic submucosal dissection and surgery for colorectal neoplasms in patients with ulcerative colitis. *United European Gastroenterol J* 2021;9(08):964–972
- Zeng QS, Zhao ZJ, Nie J, et al. Efficacy and safety of endoscopic submucosal dissection for dysplasia in ulcerative colitis patients: a systematic review and meta-analysis. *Gastroenterol Res Pract* 2022;2022:9556161
- Yang DH, Rey I. Endoscopic submucosal dissection for colitis-associated dysplasia. *Clin Endosc* 2019;52(02):120–128
- Nishio M, Hirasawa K, Ozeki Y, et al. An endoscopic treatment strategy for superficial tumors in patients with ulcerative colitis. *J Gastroenterol Hepatol* 2021;36(02):498–506
- Ramchandani M, Rughwani H, Inavolu P, et al. Diagnostic yield and therapeutic impact of novel motorized spiral enteroscopy in small-bowel disorders: a single-center, real-world experience from a tertiary care hospital (with video). *Gastrointest Endosc* 2021;93(03):616–626
- Inavolu P, Singh AP, Kanakagiri H, Reddy DN, Ramchandani M. Motorized spiral enteroscopy-assisted retrieval of video capsule in a patient with Crohn's disease. *VideoGIE* 2020;5(10):488–491
- Jovanovic I, Vormbrock K, Zimmermann L, et al. Therapeutic double-balloon enteroscopy: a binational, three-center experience. *Dig Dis* 2011;29(Suppl 1):27–31
- Rodge GA, Ramchandani M, Bharat Shah B, Afzalpurkar S, Bhageerath Raj D, Goenka MK. Hemoclips during motorized spiral enteroscopy—a unique case. *Indian J Gastroenterol* 2021;40(03):344–346
- Bouhnik Y, Carbonnel F, Laharie D, et al; GETAID CREOLE Study Group. Efficacy of adalimumab in patients with Crohn's disease and symptomatic small bowel stricture: a multicentre, prospective, observational cohort (CREOLE) study. *Gut* 2018;67(01):53–60