



Pituitary Stalk Hemangioblastoma: Complete Resection through Orbitozygomatic Approach with Extradural Anterior Clinoidectomy

Raffaella Messina¹ Giovanni Cirrottola¹ Leonello Tacconi² Jacques Guyotat³ Francesco Signorelli¹

¹ Division of Neurosurgery, Neurosciences and Sense Organs, Department of Basic Medical Sciences, “Aldo Moro” University of Bari Medical School, Bari, Italy

² Division of Neurosurgery, Azienda Sanitaria Universitaria Integrata di Trieste, University Hospital of Trieste, Trieste, Italy

³ Groupement Hospitalier Est, Hôpital Neurologique et Neurochirurgical “P. Wertheimer”, Service de Neurochirurgie D, Lyon, France

Address for correspondence Raffaella Messina, MD, Division of Neurosurgery, Neurosciences and Sense Organs, Department of Basic Medical Sciences, “Aldo Moro” University of Bari Medical School, Azienda Ospedaliero-Universitaria Policlinico Consorziato, Piazza Giulio Cesare, 11, 70124 Bari, Italy (e-mail: raffamessina@gmail.com; raffaella.messina@uniba.it).

J Neurol Surg B Skull Base 2022;83:e661–e662.

Abstract

Background Pituitary stalk hemangioblastomas (PSHBLs) are rare vascular tumors and their surgical removal is challenging due to the proximity with several fundamental anatomic structures including the pituitary stalk, third ventricle, hypothalamus, and optic pathways. To date, only few descriptions of transcranial and transsphenoidal approaches for PSHBLs have been reported in the literature and none in video, with suboptimal outcomes in terms of pituitary function preservation. Here, we describe the use of orbitozygomatic (OZ) craniotomy with extradural anterior clinoidectomy (EAC) for the removal of a PSHBL with preservation of the pituitary stalk.

Case Description A 60-year-old woman with a sporadic symptomatic HBL of the pituitary stalk, with the typical features of avid contrast enhancement on T1- and flow voids on T2-weighted magnetic resonance imaging (MRI) images, underwent a right OZ craniotomy with EAC. The choice of the approach was guided by the necessity of exposing the floor of the 3rd ventricle and infundibulum, where the origin of the pituitary stalk is better appreciated and preserved, without brain retraction. EAC was deemed important due to the necessity of widening the right carotico-oculomotor and opticocarotid triangles and gaining access to the ophthalmic segment of the internal carotid artery, origin of the superior hypophyseal artery, and the tumor supply. The postoperative MRI confirmed gross tumor removal with preservation of the pituitary stalk and no tumor recurrence after 2 years of follow-up.

Conclusion OZ craniotomy coupled with EAC facilitates surgical removal of PSHBLs thus augmenting the chances of pituitary function preservation.

The link to the video can be found at <https://youtu.be/hH65W937RGY>.

Keywords

- ▶ pituitary stalk
- ▶ hemangioblastoma
- ▶ orbitozygomatic approach
- ▶ extradural anterior clinoidectomy



www.thieme.com/skullbasevideos

www.thieme.com/jnlsbvideos

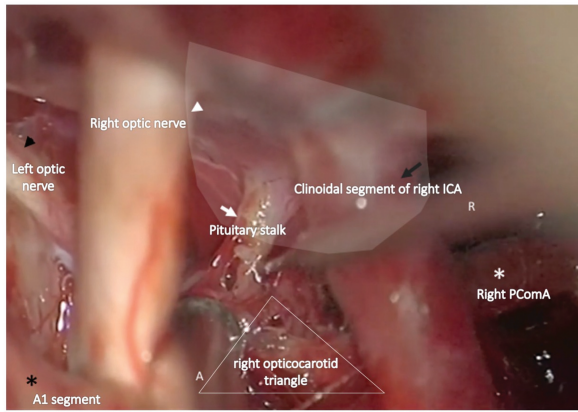
received
March 31, 2020
accepted after revision
August 31, 2022
article published online
October 7, 2022

DOI <https://doi.org/10.1055/s-0042-1757618>.
ISSN 2193-6331.

© 2022. The Author(s).

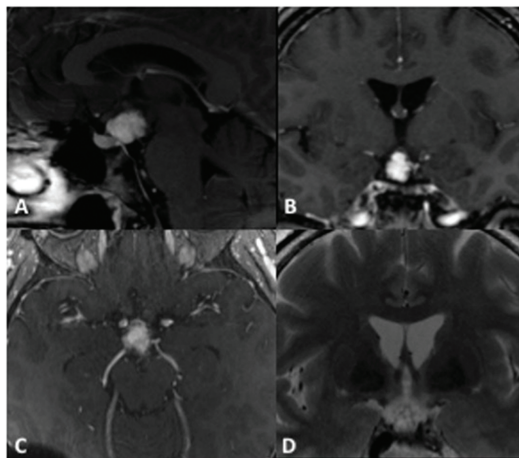
This is an open access article published by Thieme under the terms of the Creative Commons Attribution-NonDerivative-NonCommercial-License, permitting copying and reproduction so long as the original work is given appropriate credit. Contents may not be used for commercial purposes, or adapted, remixed, transformed or built upon. (<https://creativecommons.org/licenses/by-nc-nd/4.0/>)

Georg Thieme Verlag KG, Rüdigerstraße 14, 70469 Stuttgart, Germany



Conflict of Interest
None declared.

Fig. 1 Intraoperative picture, microscopic view through the R orbitozygomatic approach. Aspirator (A) and Rhoton ball-tip probe are into the R opticocarotid triangle. White arrow: pituitary stalk; black arrow: clinoidal segment of R CA; white arrowhead: R optic nerve; black arrowhead: L optic nerve; white asterisk: R PComA; black asterisk: A1 segment of R ACA; A: aspirator; R: Rhoton ball-tip probe. White-shaded area: projection of R anterior clinoid. R, right; CA, internal carotid artery; L, left; PComA, posterior communicating artery; ACA, anterior cerebral artery.



SUMMARY

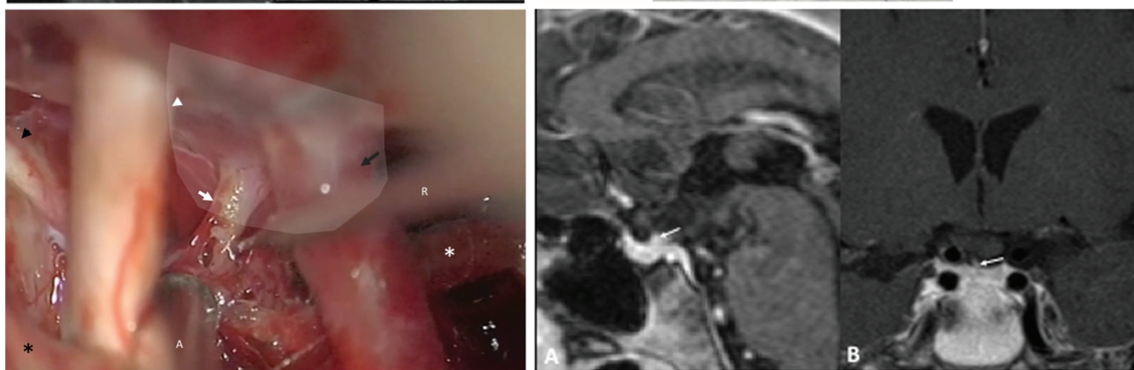
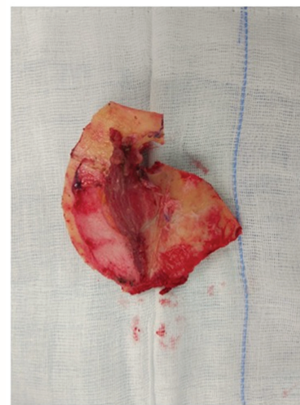


Fig. 2 From left to right: Preoperative magnetic resonance imaging (MRI); sagittal (A), coronal (B), and axial (C) T1-weighted (T1W) gadolinium enhanced and coronal T2W (D) showing an avidly enhancing lesion attached to the pituitary stalk and occupying the right basal cisterns with multiple flow voids. "Reprinted from, *Clinical Neurology Neurosurgery*, Vol. 168, Alshafai N, Maduri R, Shail M, Chirchiglia D, Meyronet D, Signorelli F, *Surgical approach for suprasellar hemangioblastomas preserving the pituitary stalk: Review of the literature and report of a further case*, Pages No. 147–152, Copyright 4314191018836 (2018), with permission from Elsevier"; Orbito-fronto-temporal bone flap; Intraoperative picture, microscopic view; postoperative MRI confirms complete tumor removal with stalk preservation (white arrow). "Reprinted from, *Clinical Neurology Neurosurgery*, Vol. 168, Alshafai N, Maduri R, Shail M, Chirchiglia D, Meyronet D, Signorelli F., *Surgical approach for suprasellar hemangioblastomas preserving the pituitary stalk: Review of the literature and report of a further case*, Pages No. 147-152, Copyright 4314191018836 (2018), with permission from Elsevier."