



# Craniocerebral Maduramycosis: Masquerading as a Tumor

Inuganti Venkata Renuka<sup>1</sup> Chitturi Ramya<sup>1</sup> Velivela Kiran Chand<sup>2</sup> Tammina Mohana Sri Vidya<sup>1</sup>  
Salumuri Premchand<sup>2</sup>

<sup>1</sup>Department of Pathology, NRI Medical College, Chinakakani, Andhra Pradesh, India

<sup>2</sup>Department of Neurosurgery, NRI Medical College, Chinakakani, Andhra Pradesh, India

Address for correspondence Inugani V. Renuka, MD, DCP, Department of Pathology, NRI Medical College, Chinnakakani, Guntur District, 522503, Andhra Pradesh, India (e-mail: repriya56@gmail.com).

AJNS 2022;17:635–637.

## Abstract

Eumycetomas of craniocerebral are rare, and we report an extraordinary case of maduramycosis involving brain and skull bone in a middle-aged male who presented with complaints of headache, behavioral abnormalities, and memory disturbances for 3 months. Imaging showed a frontal lesion. It was mistaken for a tumor clinically and radiologically. Craniocerebral eumycetoma usually presents as a mass on the scalp with sinuses. Our case presented as a brain tumor without a soft tissue mass or discharging sinuses. It is essential to keep in mind this mode of presentation, and only a biopsy will aid in diagnosis.

## Keywords

- ▶ craniocerebral
- ▶ maduramycosis
- ▶ eumycetoma

## Introduction

Maduramycosis is mostly confined to the lower extremities and hence was rightly named as “Madura foot” by John Gill in 1842, after the name of Madurai district, in the Tamil Nadu state of India.<sup>1</sup> Mycetoma is a chronic granulomatous infection mostly caused by a true fungus, *Madurella mycetomatis* (eumycotic mycetoma). Craniocerebral involvement by eumycotic mycetoma is rare in world literature and confined to few case reports only. Mycetoma commonly affects the lower extremities. It is a chronic, localized, granulomatous infection with the formation of tumor-like masses and exudates with draining sinuses and granules of the etiological agent. It is caused either by fungi (eumycotic mycetoma) or filamentous higher bacteria. There are more than 20 species of fungi and bacteria that have been identified as etiologic agents.<sup>2,3</sup>

Cerebral maduramycosis is extremely rare. Here, we report a case of cerebral maduramycosis involving the right frontal region that was clinically suspected to be a subdural osteoma

or an atypical meningioma. There was no involvement of the subcutaneous tissue and there were no draining sinuses.

## Case Report

A 51-year-old male presented with complaints of headache, behavioral abnormalities, and memory disturbances for 3 months. On evaluation, magnetic resonance imaging (MRI) showed a well-defined mass lesion of 3.3 × 3.2 × 1.8 cm arising probably from right frontal bone with mass effect on the frontal lobe and with extensive perilesional edema; the possibilities were subdural osteoma or atypical meningioma (→ **Fig. 1**).

Right frontal craniotomy with tumor excision was done upto the supraorbital margin. Intraoperatively, the mass was found to be infiltrating the dura anteriorly and with extension into the brain tissue. The lesion was hard, pinkish white, mildly vascular and infiltrating the surrounding parenchyma (→ **Fig. 2**). There were no skin lesions or draining sinuses in the head and neck region or elsewhere.

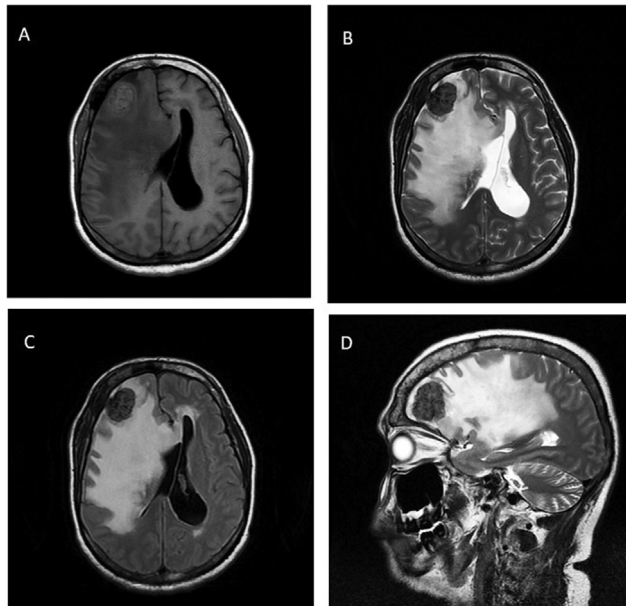
article published online  
December 14, 2022

DOI <https://doi.org/10.1055/s-0042-1757627>.  
ISSN 2248-9614.

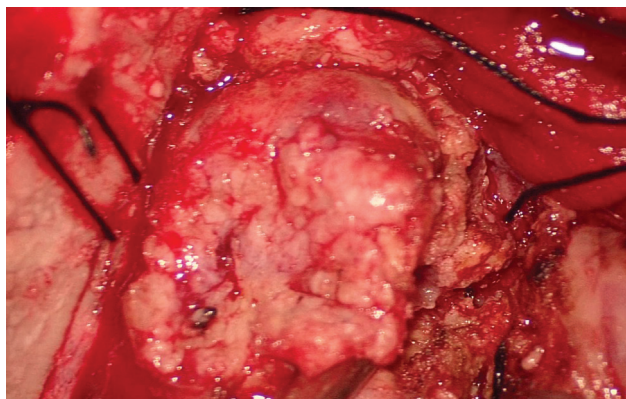
© 2022. Asian Congress of Neurological Surgeons. All rights reserved.

This is an open access article published by Thieme under the terms of the Creative Commons Attribution-NonDerivative-NonCommercial-License, permitting copying and reproduction so long as the original work is given appropriate credit. Contents may not be used for commercial purposes, or adapted, remixed, transformed or built upon. (<https://creativecommons.org/licenses/by-nc-nd/4.0/>)

Thieme Medical and Scientific Publishers Pvt. Ltd., A-12, 2nd Floor, Sector 2, Noida-201301 UP, India



**Fig. 1** Well-defined mass lesion arising from right frontal bone with significant mass effect of frontal lobe and extensive perilesional edema, possible subdural osteoma from right frontal bone/atypical meningioma. (A) T1-weighted, (B) T2-weighted, (C) T2-weighted fluid-attenuated inversion recovery, and (D) T2-weighted sagittal images.



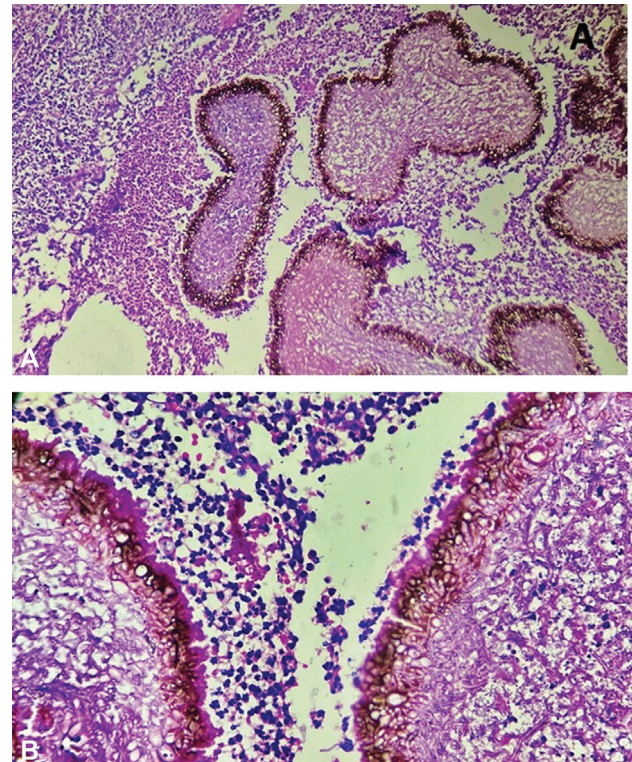
**Fig. 2** Intraoperatively lesion pinkish white, mildly vascular, and infiltrating the surrounding parenchyma.

### Gross Findings

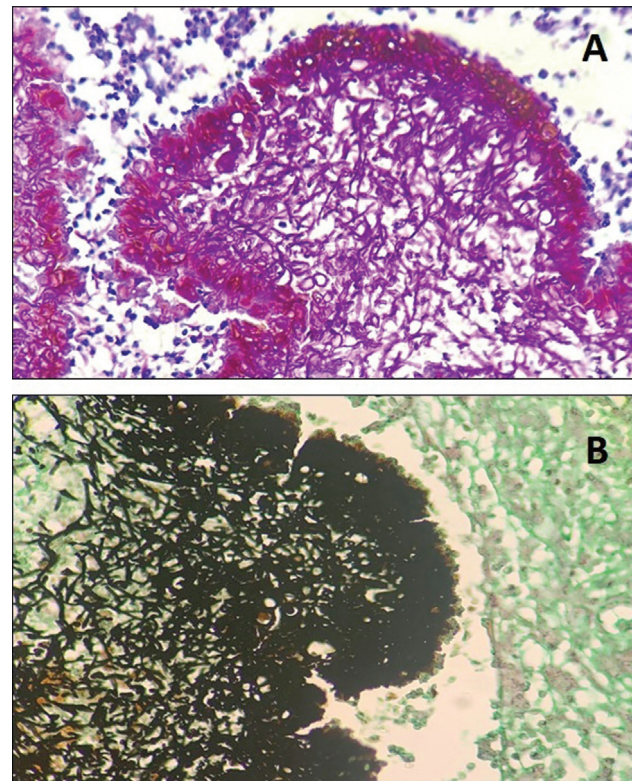
We received a gray-brown nodular mass measuring  $3.3 \times 3 \times 1$  cm which on cut section was gray-brown to tan-brown, with multiple gray-black areas of 0.4 cm each.

### Microscopy

Hematoxylin and eosin-stained sections showed small and large colonies, some round, some multilobulated, surrounded by neutrophils forming micro abscesses along with epithelioid cells, plasma cells, and multinucleated giant cells forming occasional granulomas. Some colonies were demarcated by eosinophilic hyaline-like material, Splendore-Hoeppli phenomenon ( $\rightarrow$  Fig. 3). Special stains periodic acid Schiff stain and Grocott-Gomori silver methenamine stain were done that demonstrated positivity in fungal colonies, which were composed of radially arranged, septate filamentous hyphae ( $\rightarrow$  Fig. 4).



**Fig. 3** (A and B) Maduramycosis colonies, with neutrophils, epithelioid cells, plasma cells, and multinucleated giant cells (hematoxylin and eosin, 100 $\times$  and 400 $\times$ ).



**Fig. 4** (A and B) Special stains periodic acid Schiff stain (PAS) and Grocott-Gomori silver methenamine stain (GMS) positivity in fungal colonies composed of radially arranged, septate filamentous hyphae (A: PAS, 400 $\times$ ; B: GMS, 400 $\times$ ).

## Discussion

Maduramycosis involving the cerebral cortex was first reported by Natarajan et al in India in 1975.<sup>1</sup> Craniocerebral eumycetoma usually presents as swelling and discharging sinuses. Behera et al<sup>4</sup> reported a case of cerebral eumycetoma with no swelling or discharging sinus. In our present case also, there was no swelling or discharging sinus. Potassium hydroxide mount or fungal cultures were not sent as the diagnosis of mycetoma was never suspected preoperatively or intraoperatively due to lack of purulent material or sulfur-like granules. Intraoperatively, the mass was infiltrating the dura (dural-based lesion). The patient was started on anti-fungal therapy and was doing well at 3 months follow-up. Mah Sheena et al<sup>5</sup> also reported a case of craniocerebral eumycetoma masquerading as a Meningioma. In the present case, the differential diagnosis on MRI was an osteoid osteoma with mass effect or a meningioma.

## Conclusion

We present this case of cerebral maduramycosis with no evidence of a soft tissue involvement or discharging sinuses,

which is an extremely rare occurrence. Advanced imaging like computed tomography and MRI may not always help in diagnosing these cases and histopathology alone aids in the final diagnosis.

### Conflict of Interest

None declared.

## References

- 1 Natarajan M, Balakrishnan D, Muthu AK, Arumugham K. Maduramycosis of the brain. Case report. *J Neurosurg* 1975;42(02):229–231
- 2 Sai Kiran NA, Kasliwal MK, Suri A, et al. Eumycetoma presenting as a cerebellopontine angle mass lesion. *Clin Neurol Neurosurg* 2007;109(06):516–519
- 3 Rao KV, Praveen A, Megha S, Sundaram C, Purohith AK. Atypical craniocerebral eumycetoma: a case report and review of literature. *Asian J Neurosurg* 2015;10(01):56–59
- 4 Behera BR, Mishra S, Dhir MK, Panda RN, Samantaray S. “Madura Head”—a rare case of craniocerebral maduromycosis. *Indian J Neurosurg* 2018;07(02):159–163
- 5 Mah Sheena KM, Lilly R, Kuruvila S, Kavitha KP. Craniocerebral eumycetoma: a rare masquerader of meningioma. *Int J Scientific Res Publ* 2020;10(02):217–250(IJSRP)