



# Risk of Neurovascular Injury during Screw Fixation of Tibial Tubercle Fractures in Pediatric and Adolescent Patients\*

## *Risco de lesão neurovascular durante a fixação com parafuso de fraturas da tuberosidade da tíbia em pacientes pediátricos e adolescentes*

Paula Biolatto<sup>1</sup> , Alpesh Kothari<sup>2</sup> , Javier Masquijo<sup>1</sup>

<sup>1</sup> Orthopedic Surgeon, Department of Paediatric Orthopaedics, Sanatorio Allende, Córdoba, Argentina

<sup>2</sup> Orthopedic Surgeon, Department of Paediatric Orthopaedics, Oxford University Hospitals NHS Foundation Trust, Oxford, OX3 7HE, United Kingdom

Address for correspondence Javier Masquijo, Department of Pediatric Orthopedics, Sanatorio Allende, Independencia 757, 1er piso Córdoba, Argentina (e-mail: jmasquijo@gmail.com).

Rev Bras Ortop 2023;58(6):e939–e943.

### Abstract

**Objective** To review knee magnetic resonance imaging (MRI) scans for the analysis of the location of neurovascular structures (NVSs), and to define the risk of bicortical fixation.

**Methods** Distances between the posterior cortex and the popliteal NVSs were measured on the MRI scans of 45 adolescents (50 knees) at 3 levels (C1: center of the proximal tibial epiphysis; C2: 10 mm distal to the physis; and C3: 20 mm distal to the physis). The NVSs located between 5 mm and 10 mm from the incision were considered in a zone of moderate risk for damage, while those less than 5 mm from the incision were considered in a zone of high risk for damage, and those more than 10 mm from the incision were considered to be in a zone of low risk for damage. The independent Student *t*-test was used for the comparison of the NVS distance 0with gender, skeletal maturity, and the tibial tubercle-trochlear groove (TT-TG) distance. Values of  $p < 0.05$  were regarded as statistically significant.

**Results** The path of the C1 screw posed an increased risk of damage to the popliteal artery and vein compared with other screw paths ( $p < 0.001$ ). The popliteal artery has a high risk of damage at the level of C1 ( $4.2 \pm 2.2$ mm), and a moderate risk at C2 ( $9.6 \pm 2.4$ mm), and the popliteal vein has a moderate risk at C1 ( $6.0 \pm 2.7$  mm), and a low risk at C2 and C3 ( $10.8 \pm 3.1$ mm, and  $12.05 \pm 3.1$ mm respectively). The C3 position presented the lowest risk of damage to these structures ( $p < 0.001$ ). The

### Keywords

- ▶ child
- ▶ fracture fixation, internal
- ▶ tibial fractures
- ▶ popliteal artery injury

\* Study developed at the Department of Pediatric Orthopedics, Sanatorio Allende, Córdoba, Argentina.

received  
June 4, 2022  
accepted  
September 12, 2022  
article published online  
July 31, 2023

DOI <https://doi.org/10.1055/s-0042-1757961>.  
ISSN 0102-3616.

© 2023. Sociedade Brasileira de Ortopedia e Traumatologia. All rights reserved.

This is an open access article published by Thieme under the terms of the Creative Commons Attribution-NonDerivative-NonCommercial-License, permitting copying and reproduction so long as the original work is given appropriate credit. Contents may not be used for commercial purposes, or adapted, remixed, transformed or built upon. (<https://creativecommons.org/licenses/by-nc-nd/4.0/>)

Thieme Revinter Publicações Ltda., Rua do Matoso 170, Rio de Janeiro, RJ, CEP 20270-135, Brazil

distance between the posterior tibial cortex and the posterior tibial nerve was  $< 15$  mm at the 3 levels analyzed (C1:  $11.0 \pm 3.7$  mm; C2:  $13.1 \pm 3.8$  mm; and C3:  $13 \pm 3.9$  mm).

**Conclusions** The present study clarifies that the popliteal vessels are at risk of injury during tibial tubercle screw fixation, particularly when drilling the proximal tibial epiphysis. Monocortical drilling and screw fixation are recommended for the surgical treatment of tibial tubercle fractures.

**Level of Evidence III** Diagnostic study.

## Resumo

**Objetivo** Revisar estudos de ressonância magnética (RM) do joelho para análise da localização das estruturas neurovasculares (ENVs) e definição do risco de fixação bicortical.

**Métodos** As distâncias entre o córtex posterior e as ENVs poplíteas foram medidas nas RMs de 45 adolescentes (50 joelhos) em 3 níveis (C1: centro da epífise proximal da tíbia; C2: 10 mm distalmente à fise e C3: 20 mm distalmente à fise). Considerou-se que as ENVs entre 5 mm e 10 mm da incisão estavam na zona de risco moderado de lesão, as ENVs a menos de 5 mm da incisão, na zona de alto risco de lesão, e as ENVs a mais de 10 mm da incisão, na zona de baixo risco de lesão. O teste *t* de Student independente foi usado para comparar a distância até as ENVs com o gênero, a maturidade esquelética e a distância entre a tuberosidade tibial e a garganta (fundo) da tróclea (TT-GT). Valores de  $p < 0,05$  foram considerados estatisticamente significativos.

**Resultados** A trajetória do parafuso em C1 apresentou maior risco de lesão à artéria e à veia poplíteia em comparação com outras trajetórias ( $p < 0,001$ ). A artéria poplíteia apresenta risco de lesão alto em C1 ( $4,2 \pm 2,2$  mm) e moderado em C2 ( $9,6 \pm 2,4$  mm), e a veia poplíteia tem risco moderado em C1 ( $6,0 \pm 2,7$  mm) e baixo em C2 e C3 ( $10,8 \pm 3,1$  mm e  $12,05 \pm 3,1$  mm, respectivamente). A posição C3 apresentou o menor risco de lesão dessas estruturas ( $p < 0,001$ ). A distância entre o córtex tibial posterior e o nervo tibial posterior foi inferior a 15 mm nos 3 níveis analisados (C1:  $11,0 \pm 3,7$  mm; C2:  $13,1 \pm 3,8$  mm; e C3:  $13 \pm 3,9$  mm).

**Conclusões** Este estudo esclarece que os vasos poplíteos correm risco de lesão durante a fixação do parafuso na tuberosidade tibial, principalmente durante a perfuração da epífise proximal da tíbia. A perfuração monocortical e a fixação com parafusos são recomendadas para o tratamento cirúrgico das fraturas da tuberosidade tibial.

**Nível de Evidência III** Estudo diagnóstico.

## Palavras-chave

- ▶ criança
- ▶ fixação interna de fraturas
- ▶ fraturas da tíbia
- ▶ lesão da artéria poplíteia

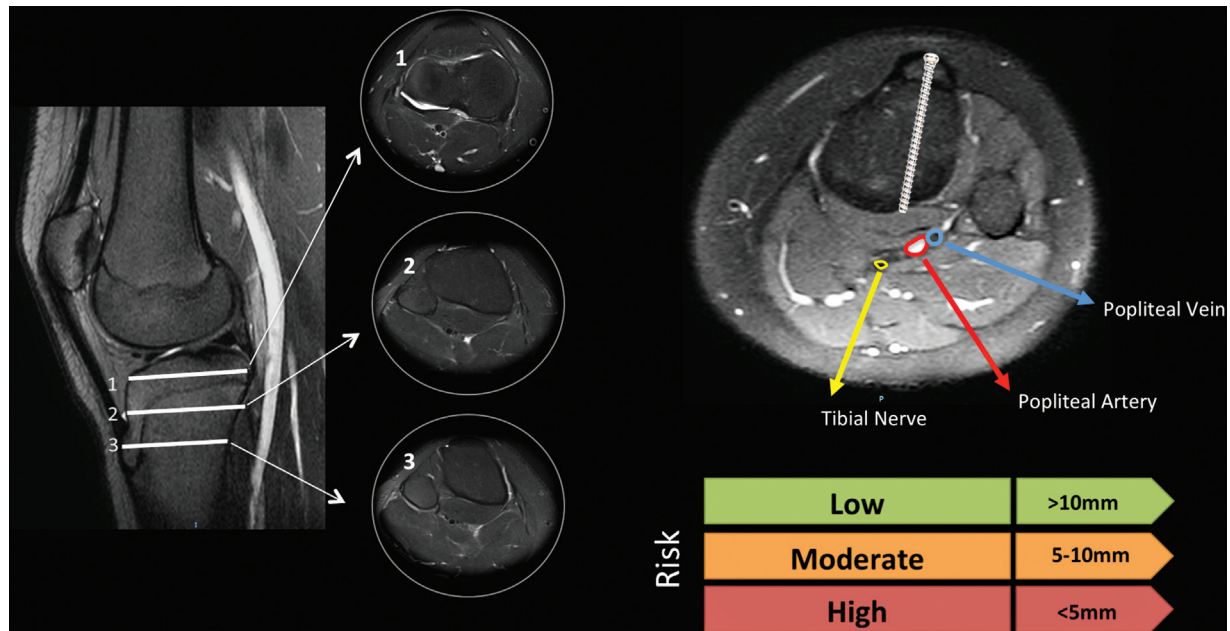
## Introduction

Avulsion fractures of the tibial tubercle typically occur in adolescent athletic boys during jumping activities.<sup>1,2</sup> These injuries are the result of a violent knee flexion against a tightly-contracting quadriceps, as in landing from a jump, or a violent quadriceps contraction against a fixed foot, as in jumping.<sup>3,4</sup> The proximal tibial physis closes distally toward the tubercle apophysis during normal development, creating a mechanically vulnerable period in adolescence that predisposes the tubercle to a potential avulsion injury.<sup>5</sup>

These fractures can present with marked displacement of the apophysis, with or without intra-articular extension, and variable associated soft-tissue injury.<sup>6</sup> This injury usually requires open reduction and internal fixation to restore the extensor mechanism and the congruency of the knee joint.

This is usually achieved with anterior to posterior cannulated screw fixation along the tibial tubercle.<sup>7</sup> Several previous publications<sup>8-12</sup> have reported excellent results with this technique, regardless of the type of fracture. However, the surgical treatment for tibial tubercle fractures is not devoid of risks. Complications such as wound infections, arthrofibrosis, physeal arrest (angular deformity/leg length discrepancy), hardware failure, refracture, compartment syndrome or iatrogenic vascular injury have been reported.<sup>5,8-19</sup> A recent systematic review<sup>20</sup> of the literature reported a complication rate of 28.3%. Damage to the popliteal neurovascular structures (NVSs) during screw drilling for tibial tuberosity fixation is particularly concerning as a potential devastating complication.

While there have been a few studies<sup>21,22</sup> evaluating the relationships involving the NVSs of the popliteal region in the



**Fig. 1** Measuring technique on axial magnetic resonance imaging. The distance between the exit point at the posterior tibial cortex and the neurovascular structures (artery, vein, and nerve) was measured at 3 levels. C1: center of the proximal tibial epiphysis; C2: 10 mm distal to the physis; and C3: 20 mm distal to the physis.

adults, to our knowledge, there are no comparable studies conducted with adolescents. Understanding of the anatomy can help guide surgeons during surgery to avoid preventable complications. Therefore, the purpose of the present study was to review knee magnetic resonance imaging (MRI) scans to assess the location of NVSs and define the risk for bicortical fixation.

## Methods

### Study Design and Population

Permission was obtained from the institutional review board to review the patient imaging scans. A retrospective review of the database of a tertiary care hospital was performed to identify adolescent patients who had undergone an MRI for different indications. Patients with a history of fractures, tumors, knee deformities, or previous orthopedic or vascular surgical procedures were excluded. Patient demographics at the time of the MRI were obtained from the medical records.

### MRI Technique and Measurements

The MRI scans were performed on an 8-channel Philips Healthcare (Andover, MA, United States) 1.5-T scanner. All images were obtained with the knee fully extended. The parameters for the MRI scans were as follows: proton density (PD) fat saturation (FAT-SAT) axial coronal sequence – thickness of the cut: 3 mm; repetition time (RT): 3080 ms; echo time (ET) 36 ms. Sagittal PD – thickness of the cut: 3 mm; TR: 4,700 ms; TE: 71 ms. Coronal PD: thickness of the cut: 3 mm; TR: 2,730 ms; TE: 23 ms. Sagittal T1 and T2: thickness of the cut: 3 mm; TR: 540 ms; TE: 12 ms. Contrast was not used in any of the cases.

The distances between the posterior cortex and the popliteal NVSs were measured at 3 levels (C1: center of

the proximal tibial epiphysis; C2: 10 mm distal to the physis; and C3: 20 mm distal to the physis) (→ Fig. 1). On axial images, we drew at each level a line perpendicular to the growth plate of the anterior tibial tubercle (ATT) to the posterior cortex. The distance between the exit point at the posterior tibial cortex and the NVSs (artery, vein, and nerve) was measured. This would represent the screw in a position that can be perfectly perpendicular to the fracture plane. The NVSs between 5 mm and 10 mm from the cut were considered in a zone of moderate risk for damage, while those less than 5 mm from the cut were considered in a zone of high risk for damage, and those more than 10 mm from the cut were considered in a zone of low risk.

### Data Analysis

The exit point for each simulated screw path was measured and initially categorized as either low, moderate or high risk for NVS damage. For the analysis of the objective of the study, the risk for NVS damage was dichotomized into low or moderate/high risk categories by screw entry point, and 3 separate  $3 \times 2$  contingency tables were made. These were then analyzed using a standard Chi-Squared test with subsequent post-hoc analysis of the adjusted standardized residuals of each category with appropriate Bonferroni correction ( $\alpha = 0.008$ ). The alpha was adjusted to 0.005. The data were normally distributed with no significant kurtosis. The statistical analyses were performed using the Statistical Package for the Social Sciences software (IBM SPSS Statistics for Windows, IBM Corp., Armonk, NY, United States), version 22.0.

## Results

A total of 50 knee MRIs of 45 patients (28 of them male) were included for evaluation. The mean age at the time of the MRI

**Table 1** Distance from the posterior cortex to the neurovascular structures

Location	Artery			Vein			Nerve		
	1	2	3	1	2	3	1	2	3
Mean (in mm)	4.3	9.7	11.1	6.1	10.9	12.2	10.9	13.1	14.1
Standard deviation (in mm)	±2.3	±2.4	±2.3	±2.7	±3	±3.1	±3.6	±3.8	±3.9

**Table 2** Theoretical risk of neurovascular injury by screw position

Artery	Risk		Low	Moderate/High	Significance (p)
	Position	C1	1 (2%)	49 (98%)	< 0.001
	C2	20 (40%)	30 (60%)	0.782	
	C3	33 (66%)	17 (34%)	< 0.001	
Vein	Risk		Low	Moderate/High	Significance (p)
	Position	C1	3 (6%)	47 (94%)	< 0.001
	C2	29 (58%)	21 (42%)	0.056	
	C3	34 (68%)	16 (32%)	< 0.001	
Nerve	Risk		Low	Moderate/High	Significance (p)
	Position	C1	28 (56%)	22 (44%)	0.056
	C2	34 (68%)	16 (32%)	0.995	
	C3	41 (82%)	9 (18%)	0.044	

was of  $14.1 \pm 2.2$  years. The mean distance from the posterior cortex to the NVSs is presented in ► **Table 1**. The theoretical risk of NVS injury by screw position is summarized in ► **Table 2**.

The post-hoc analysis of the Chi-Squared test demonstrated that the path of the C1 screw posed an increased risk of damage to the popliteal artery and vein compared with other screw paths ( $p < 0.001$ ), and, indeed, the C3 position presented the lowest risk of damage to these structures ( $p < 0.001$ ). There were no significant differences between the observed and expected frequencies of risk of damage to the tibial nerve for different screw paths.

## Discussion

The most important finding of the present study was that the popliteal artery is at a high risk of injury during tibial tubercle screw fixation, particularly when drilling the proximal tibial epiphysis. Although the risk of injury is inferior for the popliteal vein and nerve, the distance between the posterior tibial cortex and the NVSs was  $< 15$  mm at the three levels analyzed. In studies with adults,<sup>23</sup> when the distance between the posterior tibial cortex and the NVSs was of 10 mm, this was considered at risk, when the distance was shorter than 5 mm, this risk was considered high. As the overall dimensions of a pediatric and adolescent knee are smaller, the proximity of the NVSs may place them at a greater risk during screw drilling.

Although damage to the surrounding NVSs appears to be rare,<sup>24</sup> it represents a potentially devastating complication of

surgery around the knee. Previous studies<sup>21,22</sup> with adults in the literature have focused primarily on the associated risk to the popliteal artery and how to prevent its injury during proximal tibial tubercle osteotomy, but there is a paucity of literature regarding neurovascular risks in the pediatric and adolescent population. A biomechanical study<sup>25</sup> has shown that the strength of the unicortical fixation seems to be inferior to that of bicortical screws for tibial the fixation of tubercle osteotomy. However, a recent clinical comparative study<sup>26</sup> demonstrated that bicortical fixation provides no significant mechanical advantage for the treatment of tibial tubercle fractures. Arkader et al.<sup>26</sup> evaluated a series of 86 patients (90 fractures) treated with either unicortical or bicortical fixation. The treatment outcomes were excellent in both groups, with all patients achieving radiographic union at the last follow-up, and with low rates of complications.

Several limitations should be considered when interpreting the results of the present study. Most importantly, the MRIs were performed with the knee extended and the distance measured from the posterior cortex to the NVSs could vary with different degrees of flexion such as those used during surgery. Second, variations in the branching patterns of the popliteal artery are not uncommon (they occur in 10% to 15% of the cases), and several variations have been reported.<sup>27,28</sup> This may have been underrepresented in the present study due to the sample size, and it warrants further investigations to limit the risk of injury in this patient population. A further limitation is that the screw direction was only analyzed in a single position

(perfectly perpendicular to the theoretical fracture plane). As in a recent study<sup>29</sup> that evaluates the risk of NVS injury during lateral meniscal repair, we wished to conduct a study with a “worst-case” scenario; however, if the direction of the screw is angled and directed more medially in the transverse plane toward the medial aspect of the metaphysis, this would likely decrease the risk to the NVSs.

## Conclusion

In conclusion, the present study clarifies that the popliteal vessels are at risk of injury during fixation of the tibial tubercle screw, particularly when drilling the proximal tibial epiphysis. Based on our findings and previous clinical studies, we recommend monocortical drilling and screw fixation for the surgical treatment of tibial tubercle fractures. If bicortical fixation is required, the drill could be aimed more medially in the transverse plane toward the medial aspect of the metaphysis, and potentially minimize the risk of vascular damage.

### Authors' Contributions

Each author contributed individually and significantly to the development of the present article: Biolatto P: measurements, manuscript preparation. Kothari A: study design, statistical analysis, manuscript review. Masquijo JJ: study design, measurements, manuscript preparation.

### Financial Support

The authors declare that they have received no financial support from public, commercial, or non-profit sources.

### Conflict of Interests

The authors have no conflict of interests to declare.

## References

- Mosier SM, Stanitski CL. Acute tibial tubercle avulsion fractures. *J Pediatr Orthop* 2004;24(02):181–184
- McKoy BE, Stanitski CL. Acute tibial tubercle avulsion fractures. *Orthop Clin North Am* 2003;34(03):397–403
- Ogden JA, Tross RB, Murphy MJ. Fractures of the tibial tuberosity in adolescents. *J Bone Joint Surg Am* 1980;62(02):205–215
- Levi JH, Coleman CR. Fracture of the tibial tubercle. *Am J Sports Med* 1976;4(06):254–263
- Mirbey J, Besancenot J, Chambers RT, Durey A, Vichard P. Avulsion fractures of the tibial tuberosity in the adolescent athlete. Risk factors, mechanism of injury, and treatment. *Am J Sports Med* 1988;16(04):336–340
- Frey S, Hosalkar H, Cameron DB, Heath A, David Horn B, Ganley TJ. Tibial tuberosity fractures in adolescents. *J Child Orthop* 2008;2(06):469–474
- Pace JL, McCulloch PC, Momoh EO, Nasreddine AY, Kocher MS. Operatively treated type IV tibial tubercle apophyseal fractures. *J Pediatr Orthop* 2013;33(08):791–796
- Chow SP, Lam JJ, Leong JC. Fracture of the tibial tubercle in the adolescent. *J Bone Joint Surg Br* 1990;72(02):231–234
- Shelton WR, Canale ST. Fractures of the tibia through the proximal tibial epiphyseal cartilage. *J Bone Joint Surg Am* 1979;61(02):167–173
- Wiss DA, Schilz JL, Zions L. Type III fractures of the tibial tubercle in adolescents. *J Orthop Trauma* 1991;5(04):475–479
- Balmat P, Vichard P, Pem R. The treatment of avulsion fractures of the tibial tuberosity in adolescent athletes. *Sports Med* 1990;9(05):311–316
- Bolesta MJ, Fitch RD. Tibial tubercle avulsions. *J Pediatr Orthop* 1986;6(02):186–192
- Brey JM, Conoley J, Canale ST, et al. Tibial tuberosity fractures in adolescents: is a posterior metaphyseal fracture component a predictor of complications? *J Pediatr Orthop* 2012;32(06):561–566
- Buhari SA, Singh S, Wong HP, Low YP. Tibial tuberosity fractures in adolescents. *Singapore Med J* 1993;34(05):421–424
- Christie MJ, Dvonch VM. Tibial tuberosity avulsion fracture in adolescents. *J Pediatr Orthop* 1981;1(04):391–394
- Hajdu S, Kaltenecker G, Schwendenwein E, Vécsei V. Apophyseal injuries of the proximal tibial tubercle. *Int Orthop* 2000;24(05):279–281
- Howarth WR, Gottschalk HP, Hosalkar HS. Tibial tubercle fractures in children with intra-articular involvement: surgical tips for technical ease. *J Child Orthop* 2011;5(06):465–470
- Jakoi A, Freidl M, Old A, Javandel M, Tom J, Realyvasquez J. Tibial tubercle avulsion fractures in adolescent basketball players. *Orthopedics* 2012;35(08):692–696
- Nikiforidis PA, Babis GC, Triantafillopoulos IK, Themistocleous GS, Nikolopoulos K. Avulsion fractures of the tibial tuberosity in adolescent athletes treated by internal fixation and tension band wiring. *Knee Surg Sports Traumatol Arthrosc* 2004;12(04):271–276
- Pretell-Mazzini J, Kelly DM, Sawyer JR, et al. Outcomes and Complications of Tibial Tubercle Fractures in Pediatric Patients: A Systematic Review of the Literature. *J Pediatr Orthop* 2016;36(05):440–446
- Hernigou J, Chahidi E, Kashi M, et al. Risk of vascular injury when screw drilling for tibial tuberosity transfer. *Int Orthop* 2018;42(05):1165–1174
- Kline AJ, Gonzales J, Beach WR, Miller MD. Vascular risk associated with bicortical tibial drilling during anteromedial tibial tubercle transfer. *Am J Orthop* 2006;35(01):30–32
- Bisicchia S, Rosso F, Pizzimenti MA, Rungprai C, Goetz JE, Amendola A. Injury risk to extraosseous knee vasculature during osteotomies: a cadaveric study with CT and dissection analysis. *Clin Orthop Relat Res* 2015;473(03):1030–1039
- Pandya NK, Edmonds EW, Roocroft JH, Mubarak SJ. Tibial tubercle fractures: complications, classification, and the need for intra-articular assessment. *J Pediatr Orthop* 2012;32(08):749–759
- Davis K, Caldwell P, Wayne J, Jiranek WA. Mechanical comparison of fixation techniques for the tibial tubercle osteotomy. *Clin Orthop Relat Res* 2000;(380):241–249
- Arkader A, Schur M, Refakis C, Capraro A, Woon R, Choi P. Unicortical Fixation is Sufficient for Surgical Treatment of Tibial Tubercle Avulsion Fractures in Children. *J Pediatr Orthop* 2019;39(01):e18–e22
- Bardsley JL, Staple TW. Variations in branching of the popliteal artery. *Radiology* 1970;94(03):581–587
- Day CP, Orme R. Popliteal artery branching patterns – an angiographic study. *Clin Radiol* 2006;61(08):696–699
- Yen YM, Fabricant PD, Richmond CG, et al. Proximity of the neurovascular structures during all-inside lateral meniscal repair in children: a cadaveric study. *J Exp Orthop* 2018;5(01):50