



Primary Hydatid Cyst of Lumbar Paravertebral Muscle

Özge Selahi^{1,*} Pinar Kuru Bektaşoğlu^{2,*} Adnan Somay³ Erhan Çelikoğlu¹ Bora Güner^{1,4}

¹ Department of Neurosurgery, Fatih Sultan Mehmet Education and Research Hospital, University of Health Sciences, Istanbul, Türkiye

² Department of Neurosurgery, Sivas Numune Hospital, Sivas, Türkiye

³ Department of Pathology, Fatih Sultan Mehmet Education and Research Hospital, University of Health Sciences, Istanbul, Türkiye

⁴ Department of Neurosurgery, İstinye University School of Medicine, Istanbul, Türkiye

Address for correspondence Pinar Kuru Bektaşoğlu, MD, PhD, Department of Neurosurgery, Sivas Numune Hospital, Sivas 58050, Türkiye (e-mail: pnr.kuru@gmail.com).

AJNS 2022;17:661–663.

Abstract

Hydatid cyst disease as a zoonosis usually infests the liver and lungs, and it rarely affects muscles. Here, we presented a 36-year-old female patient with low back pain. Radiological evaluation revealed a soft tissue lesion located at the left paravertebral region without vertebral invasion. Surgical exploration and removal of the cyst were performed. The pathological diagnosis was hydatid cyst. After the surgery, the patient was treated with albendazole which is used to decrease the consequences of spillage and the possibility of recurrence. Hydatid cyst disease is rarely seen in paravertebral muscle tissue and needs to be correctly managed. Primary muscle involvement of hydatid cyst must be kept in mind for differential diagnosis of paravertebral cystic mass lesions.

Key Words

- ▶ Hydatid cyst
- ▶ paravertebral muscle
- ▶ surgical removal

Introduction

Hydatid cyst disease is a parasitosis caused by *Echinococcus granulosus*, which is endemic in Eastern Mediterranean countries and South America.¹ The portal system delivers the eggs to the liver after consuming foods contaminated with the eggs of the parasite.² Most affected organs are highly vascularized parenchymal tissues such as liver (50–70%) and lungs (20–30%).¹ Muscle localization for hydatidosis is occasional (0.7–0.9%).³ Till today, only six cases with primary lumbar paravertebral muscle involvement had been reported.⁴ The disease can be difficultly diagnosed and managed because of complicated differential diagnosis from other soft tissue pathologies.³ Gold standard treatment is

curative surgical removal of the cysts without any spillage and also medical therapy before and after the surgery is necessary.

Case Report

A 36-year-old woman presented with complaints of increasing back pain for the last 3 months, which has been going on for 2 years. She has no history of trauma. Complete blood count was normal without eosinophilia. Computed tomography (CT) of the lumbar spine revealed left-sided cystic paravertebral lesion at the L5 level, without any sign of bony involvement (▶ Fig. 1). CT scan of abdomen and thorax did not reveal any visceral involvement. Magnetic resonance imaging (MRI) of the lumbar spine revealed well-capsulated, multiloculated cystic lesion in the left paravertebral muscles at the L5 level (▶ Fig. 2).

* These authors contributed equally to the research and retain the first authorship.

article published online
December 10, 2022

DOI <https://doi.org/10.1055/s-0042-1758845>.
ISSN 2248-9614.

© 2022. Asian Congress of Neurological Surgeons. All rights reserved.

This is an open access article published by Thieme under the terms of the Creative Commons Attribution-NonDerivative-NonCommercial-License, permitting copying and reproduction so long as the original work is given appropriate credit. Contents may not be used for commercial purposes, or adapted, remixed, transformed or built upon. (<https://creativecommons.org/licenses/by-nc-nd/4.0/>)

Thieme Medical and Scientific Publishers Pvt. Ltd., A-12, 2nd Floor, Sector 2, Noida-201301 UP, India

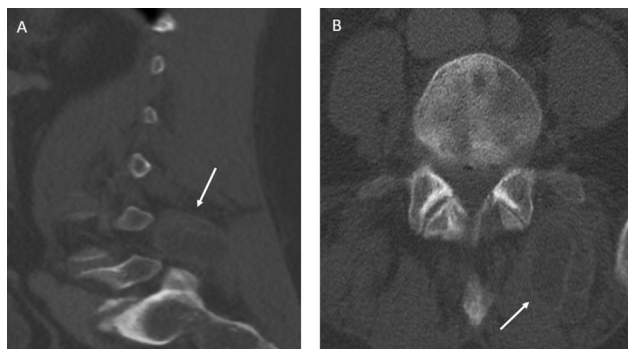


Fig. 1 Noncontrast enhanced computed tomography (CT) revealed paravertebral hydatid cyst without eroding bony structure at level L4 and L5. (A) Sagittal view, cyst contour pointed with *white arrow*. (B) Axial view, cyst contour pointed with *white arrow*.

With the diagnosis of paravertebral cystic mass lesion, patient underwent surgical excision. After skin incision, cyst was perforated during muscle retraction accidentally. Hypertonic saline solution (20% NaCl) was used to irrigate the paravertebral muscle region. After the surgery, albendazole treatment (400 mg, twice daily) was administered. Histopathological examination of surgical material was compatible with hydatid cyst, in which the cyst wall was hyalinized, and cuticular membrane and scolex were observed (→ **Fig. 3**). Indirect fluorescent antibody and indirect hemagglutination tests for cyst hydatid were negative. Albendazole treatment was continued for 8 months. On follow-up, the patient was asymptomatic, without clinical and imaging recurrence 1 year after the surgery.

Discussion

Hydatid cyst disease is a parasitic infection caused by *E. granulosus*.⁵ This endemic disease has been generally seen in the Mediterranean countries, Middle East region,

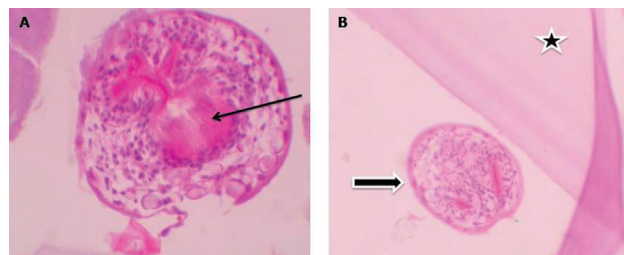


Fig. 3 Pathologic specimen of paravertebral muscle biopsy. Microscopic examination with hematoxylin and eosin (H&E) staining revealed hydatid cyst specimen. (A) Protoscolex and hooklets (*arrow*). (B) Cuticle membrane (*star*) and scolex (*arrow*) (H&E, 100 ×).

South America, and Africa.¹ Liver and lungs are the most affected organs due to the transport to the liver by the portal system.² Treatment of hydatidosis is challenging because of the high recurrence rates, unclear pathological mechanism, and long treatment protocols.

Muscle hydatidosis had been reported in the chest wall muscles, sartorius, and gluteal muscles.² Till today, only six cases had been reported with primary lumbar paravertebral muscle involvement of hydatid cyst.⁵ Muscle hydatid cyst disease mostly behaves as a soft tissue tumor which has slow-growing pattern and enlarges radially. The signs and symptoms of hydatid cyst disease depend on the site of location, involved organs, and complications due to rupture of the cyst wall. History, physical examination, serological tests (enzyme-linked immunosorbent assay, Western blotting, indirect hemagglutination tests, and polymerase chain reaction), and radiological imaging modalities such as CT and MRI are helpful but not solely adequate for confirmation of diagnosis of hydatid cyst disease.

In the cystic lesions located at lumbar paravertebral muscle, hydatid cysts should be considered in the differential diagnosis. Musculoskeletal tumors myositis or a calcified hematoma as also aneurysmal bone cysts, giant cell tumors,

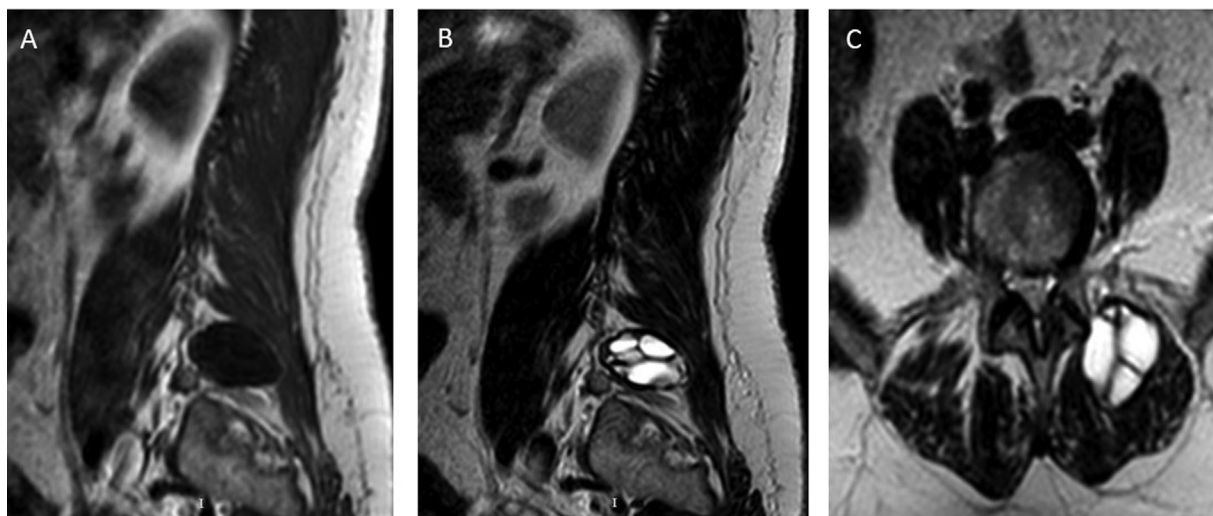


Fig. 2 Preoperative magnetic resonance (MR) imaging of the patient. (A) Sagittal T1-weighted images showing cystic lesion in paravertebral muscles at level L5. (B) Sagittal T2-weighted image showing cystic lesion with high signal intensity. (C) Axial T2-weighted image of the cystic lesion in the left paravertebral muscle.

arachnoid cysts, neurofibromatosis, and tuberculosis should also be kept in mind due to the rare presentation of the hydatid cyst.⁶

Common treatment pattern of hydatidosis is curative surgical removal of the cysts. Radical excision of hydatid cysts without being ruptured is essential because of the high recurrence rates if the spillage occurs. Oral and parenteral therapy with albendazole or mebendazole is effective and reduces the systemic spread. Before the resection and also after the removal of the cysts sterile hypertonic saline or silver nitrate (5%) is used for the irrigation of the tissues contaminated by cyst fluid.⁶ After the surgery and medical treatment, routine radiologic and clinical follow-up is necessary. In our case albendazole treatment began after surgical removal and continued for 8 months after the surgery.

In conclusion, the paravertebral muscle involvement in hydatid cysts is extremely rarely seen. Hydatid cyst should be considered in the differential diagnosis of paravertebral muscle lesions. Due to the possibility of cyst rupture, the surgery should be planned carefully for total surgical excision.

Conflict of Interest

None declared.

References

- 1 Salduz A, Koyuncu LO, Dikici F, Talu U. Long-term result of treatment for paraspinal and extradural hydatid cyst: a case report [in Turkish]. *Acta Orthop Traumatol Turc* 2009;43(03): 267-271
- 2 Alimehmeti R, Seferi A, Rroji A, Alimehmeti M. Saphenous neuropathy due to large hydatid cyst within long adductor muscle: case report and literature review. *J Infect Dev Ctries* 2012;6(06): 531-535
- 3 Tekin R, Avci A, Tekin RC, Gem M, Cevik R. Hydatid cysts in muscles: clinical manifestations, diagnosis, and management of this atypical presentation. *Rev Soc Bras Med Trop* 2015;48(05): 594-598
- 4 Sadeghian H, Motiei-Langroudi R. Hydatid cyst in the lumbar paravertebral muscle: a case report. *Cureus* 2019;11(08):e5353
- 5 Braithwaite PA, Lees RF. Vertebral hydatid disease: radiological assessment. *Radiology* 1981;140(03):763-766
- 6 Singh S, Sardhara J, Singh AK, et al. Spinal intradural hydatid cyst causing arachnoiditis: a rare etiology of cauda equina syndrome. *J Craniovertebr Junction Spine* 2016;7(04):282-284