



# Outcome of Surgical Treatment for Metastatic Spinal Cord Compression: A Single-Center Retrospective Study

Syed Muhammad Maroof Hashmi<sup>1</sup> Ibrahim Hammoud<sup>1</sup> Pranaw Kumar<sup>1</sup> Afaq Ali Sartaj<sup>1</sup>  
Kaushik Ghosh<sup>1</sup> Arupratan Ray<sup>1</sup> Aprajay Golash<sup>1</sup>

<sup>1</sup>Department of Neurosurgery, Royal Preston Hospital, Lancashire, United Kingdom

Address for correspondence Syed Muhammad Maroof Hashmi, MBBS, MRCSd, FRCSEd, Department of Neurosurgery, Royal Preston Hospital, Lancashire PR2 9HT, United Kingdom (e-mail: maroof\_hashmi@hotmail.com).

AJNS 2022;17:577–583.

## Abstract

**Objective** The spinal column is one of the most prevalent regions for metastasis, with an increasing frequency of spinal metastases. Spinal cord metastatic tumor damages the vertebral body, weakens the spinal support, and exerts mass effect on the spinal cord. Overzealous surgical intervention does not provide any additional benefit in most of the spinal metastasis due to shorter life expectancy. The principal goal of this study is to analyze the outcome of various surgical treatments offered to patients with metastatic spinal cord compression (MSCC).

**Methods** Retrospective cohort study including all patients that underwent surgical intervention for MSCC from March 2013 to March 2020.

**Results** A total of 198 patients were included, 113 males and 85 females; the mean age was 62 years. The most common primary cancer was prostate (21.71%) followed by hematological (20.07%) and lung (16.66%). At 6-month postsurgery, 68.68% of patients were Frankel grade D or E (vs. 23.23% preoperatively), 16.6% were grade C (vs. 57% preoperatively), and 14.64% were grade A or B (vs. 19.69% preoperatively). Pain on numeric rating scale was decreased from  $6.38 \pm 3.08$  to  $3.39 \pm 0.73$  at 24 hours postsurgery and  $1.94 \pm 0.67$  at 6 months.

**Conclusion** This study found that the majority of patients, undergoing minimally invasive spinal stabilization and decompression for metastatic spinal tumors, have better quality of life, analgesia, and mobility. In conclusion, treatment for spinal metastases should be individualized and a multidisciplinary approach is needed.

## Keywords

- ▶ metastatic spinal cord compression (MSCC)
- ▶ spinal metastasis
- ▶ spinal cord metastatic tumor
- ▶ minimally invasive spine (MIS) surgery

## Introduction

The spinal column is one of the most common location for metastasis, with an increasing frequency of spinal metastases.<sup>1,2</sup> Spinal cord metastatic tumor damages the vertebral

body, weakens the spinal support, and exerts mass effect on the spinal cord and cauda equina, resulting in pain, neurological deficits, and hindering of daily activities.<sup>3</sup> Bone metastasis is diagnosed in more than 60% of cancer patients in their lifetime.<sup>2</sup> Most of these patients have reduced life

article published online  
December 10, 2022

DOI <https://doi.org/10.1055/s-0042-1758846>.  
ISSN 2248-9614.

© 2022. Asian Congress of Neurological Surgeons. All rights reserved.

This is an open access article published by Thieme under the terms of the Creative Commons Attribution-NonDerivative-NonCommercial-License, permitting copying and reproduction so long as the original work is given appropriate credit. Contents may not be used for commercial purposes, or adapted, remixed, transformed or built upon. (<https://creativecommons.org/licenses/by-nc-nd/4.0/>)

Thieme Medical and Scientific Publishers Pvt. Ltd., A-12, 2nd Floor, Sector 2, Noida-201301 UP, India

expectancy. Hence, the fundamental aim of management is to enhance their quality of life in terms of mobility and analgesia. Historically, radiotherapy (RT) has been aimed toward spinal metastases. However, most recent studies have shown that surgery combined with RT was superior to RT alone, when comparing mobility and mortality.<sup>4</sup> The standard care for these patients is poorly delineated. Nevertheless, spinal intervention in the form of tumor debulking, spinal cord decompression, and stabilization has shown favorable outcome for patients with neurological deficits.<sup>5</sup> There is no defined treatment plan for asymptomatic patients or for those who present with pain only but are neurologically intact. Current literature suggests that RT is favored for stable spinal metastases. However, early surgery is preferred for patients with symptomatic epidural spinal cord compression with or without spinal instability.<sup>6</sup> Most of these patients have poor prognosis, therefore minimally invasive surgery should be opted to alleviate surgical damage. Although vertebroplasty and kyphoplasty are considered as minimally invasive operations for spinal stabilization, they are associated with relative damage to the posterior vertebral body or with pathological fractures. The manifestation of symptomatic spinal metastasis is a significant breakthrough in the disease advancement. However, due to advent of modern oncology treatment, progression-free survival and overall survival has improved notably, especially with targeted therapies.<sup>7,8</sup> Minimally invasive surgical approaches have been used alongside these targeted oncological therapies allowing the probability of less destructive techniques, with a view to early start or restart of adjuvant treatments.<sup>9,10</sup> Modern literature has limited the scope of treatment to focus on conservation of functional independence and maintain the remaining quality of life with better analgesia and shorter hospital stays.<sup>11,12</sup> Overzealous surgical intervention does not provide any additional benefit in most of the spinal metastasis patients due to shorter life expectancy. Remaining lifespan and quality of life are important considerations when comparing pros and cons of surgical intervention.<sup>13</sup> There are multiple scoring systems for spinal metastases, which ranges from prognostic scoring systems to treatment guiding tools, but they are not well suited to recent technical advancement. The scoring system, although used in this study, do not allow uniformity of practice in making surgical decisions.<sup>14–19</sup> The principal goal of this study is to analyze the outcome of various surgical treatments offered to patients with metastatic spinal cord compression (MSCC).

## Materials and Methods

All the patients who underwent surgical intervention for MSCC at Royal Preston Hospital, Lancashire, United Kingdom from March 2013 to March 2020 were included in this study. Patient's data, operation notes, and clinical details including intraoperative and postoperative complications were collected retrospectively from patient notes and our online database.

Inclusion criteria were patients above 18 years of age with a clinical and radiological diagnosis of secondary spine

tumor irrespective of the status of primary tumor (whether known or not) who underwent surgical intervention.

Exclusion criteria were (1) surgical contraindication, (2) lesions in the occipital area, (3) life expectancy less than 6 months and responsive to narcotic analgesics or markedly responsive to RT, and (4) poor baseline functional status; Karnofsky performance status of 4 or less.

Data collected included the patient's age, sex, comorbidities, weight and height, type of primary cancer, and level of metastasis. Pain, neurological status, and functional independence were assessed using different scoring systems. Preoperative pain was assessed with: numeric rating scale (NRS) and short-form McGill Pain Questionnaire (SF-MPQ). Preoperative neurological status was scored using the Frankel grade.<sup>20</sup> Walking ability was scored using four categories—normal walking, altered walking without assistance, walking with a stick/walking frame, and unable to walk. The same variables were reassessed at 6 months postoperatively.

Simultaneously, prognosis was evaluated using the Karnofsky scale<sup>21</sup> which assesses the patient's physical ability, and the Tokuhashi score<sup>17</sup> which is used to guide the surgical treatment according to the patient's life expectancy. The spinal instability neoplastic score (SINS)<sup>22</sup> is used to establish the spinal stability of patients with metastases, which declares the spine as “stable,” “potentially unstable,” or “unstable.”

Region of spinal metastasis were grouped into seven categories: (1) cervical C1-C7, (2) cervicothoracic C7-T1, (3) thoracic T2-T11, (4) thoracolumbar T12-L1, (5) lumbar L2-L4, (6) lumbosacral L5S1, and (7) sacral sacrum apart from S1.

All the pedicle screws were placed under two X-rays guidance, using the standard technique for percutaneous pedicle screw placement. All the surgeries were performed by neurosurgeons with spinal surgical expertise. Depending on the type of surgery performed, the procedures were categorized as: (1) minimally invasive spine (MIS) fixation surgery with decompression, (2) MIS fixation surgery alone, and (3) posterior decompression alone.

The length of stay in hospital was calculated in days from the day of admission to the date of discharge from the neurosurgical unit. All patients who were transferred to oncology unit, spinal rehabilitation, or were repatriated to the local hospital were considered as discharged. Outpatient follow-up was conducted at 6 months after surgery in the majority of patients. Additionally, duration of surgery, intraoperative blood loss, and timing of surgical decompression from diagnosis were recorded. During the follow-up period, surgical complications and general perioperative complications were recorded, along with the duration of hospital stay.

## Results

### Demographics and Basic Data

The study population consisted of 198 patients: 113 males (57.07%) and 85 female (42.92%) with a median age of 62 years with age range of 23 to 89 years. There was no known primary lesion in 30 (15.15%), and spinal metastasis

**Table 1** Types of primary cancer with spinal metastasis

Primary cancer	Incidence
Lung	33
Breast	13
Prostate	43
Renal	16
Colorectal	11
Hematological	41
Others/Unknown	36
Thyroid	5

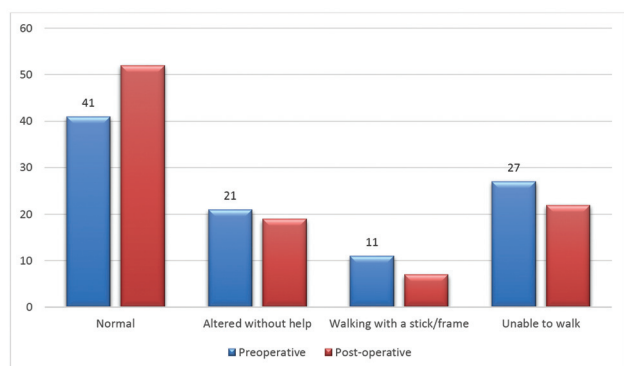
**Table 2** Levels of metastatic disease

	Level of metastatic disease
Cervical	7
Cervicothoracic	2
Thoracic	130
Thoracolumbar	23
Lumbar	28
Lumbosacral	7
Sacral	1

was the first sign of malignancy. Discovery of a metastasis was the first sign of cancer in 43 patients (21.17%). The mean time elapsed between the diagnosis and the spinal metastasis was 37 months. The most common types of primary cancer (►Table 1) were prostate (21.71%) followed by hematological (20.07%) and lung (16.66%). The spinal disease was the first region of metastasis in 77.77% (154) of patients, most common site of metastases was thoracic spine in 65.65% (130) (►Table 2).

### Preoperative Findings

The mean preoperative pain on NRS was 6.38/10, and the mean SF-MPQ was 2.9 (►Tables 3 and 4). Walking: 62% of patients could walk without assistance, 11% required help, and 27% were unable to walk (►Fig. 1). Neurological deficits: 8% of patients were Frankel grade E, majority (57%) of the

**Fig. 1** Comparison of preoperative and postoperative walking ability.**Table 3** Preoperative numeric rating scale (NRS) for pain

Visual Analogue Scale (VAS)	Numeric rating scale
0 to 3	17%
4 to 6	28%
7 to 10	55%

**Table 4** Preoperative short-form McGill Pain Questionnaire (SF-MPQ)

Preoperative short-form McGill Pain Questionnaire (SF-MPQ)	
0	9%
1	13%
2	25%
3	53%

patients were grade C, and 20% were grade A or B (►Table 5). Performance status: 58% of patients were 80 (►Table 6); according to the Tokuhashi score, only 3% of patients had life expectancy of less than 6 months (score 0–8). On the other hand, 34% had a survival prognosis of more than 12 months (score 12–15) (►Table 7). SINS score identified 71% as potentially unstable while 15% were declared as unstable (►Table 8). Pain was the sole reason for surgical fixation in 7% of the patients.

**Table 5** Preoperative neurological deficits as per Frankel grade

Preoperative Frankel grade	
A	7
B	13
C	57
D	15
E	8

**Table 6** Preoperative Karnofsky performance status

Karnofsky performance status	
40–70	83
80–100	115

**Table 7** Preoperative Tokuhashi score

Tokuhashi score	
0–8 (survival < 6 mo)	3%
9–11 (survival 6–12 mo)	63%
12–15 (survival > 12 mo)	34%

**Table 8** Preoperative spinal instability neoplastic score (SINS), %

Spinal instability neoplastic score (SINS), %	
0–6 (stable)	13
7–12 (potentially unstable)	71
13–18 (unstable)	15

**Table 9** Types of intervention

Surgical procedures (n)	
MIS fixation alone	55
MIS fixation and decompression	88
Posterior decompression alone	13

Abbreviation: MIS, minimally invasive spine.

### Operative and Postoperative Data

More than 80% (160) were discussed in multidisciplinary team (MDT) preoperatively, while the other 38 patients had emergency oncology consultation for prognostication and surgical decision. The surgery was performed within 31 hours ( $\pm$  26) after diagnosis. Posterior decompression with MIS fixation was the most common procedure which was performed in 88 (44.44%) patients, while 55 patients underwent MIS fixation alone ( $\rightarrow$  **Table 9**). The overall complication rate was 22.24% (48), postoperative wound infection was 6% (12), postoperative hematoma was seen in 4.5% (9) all of which required reexploration and evacuation of hematoma, spinal cord contusion was recorded in 2% (4), implant failure was noticed in 2.5% (5), and screw malposition was recorded in 1.5% (3) all of which were revised ( $\rightarrow$  **Table 10**).

Six-month postoperative data was collected for similar variables. Note that 5.5% (11) did not survive the 6-month follow-up time. Most common primary type of cancer among them were lung followed by renal. A total of 112 patients (51.5%) could walk independently, 44 (22.22%) patients were unable to walk, whereas 52 (26.26%) either had altered walking or were able to walk with aids ( $\rightarrow$  **Fig. 1**). At 6 months postoperatively, 68.68% of patients were Frankel grade D or E (vs. 23.23% preoperatively), 16.6% were grade C (vs. 57% preoperatively), and 14.64% were grade A or B (vs. 19.69% preoperatively) ( $\rightarrow$  **Table 11**).

The mean operative time for MIS pedicle screw fixation only was  $119 \pm 41$  minutes, mean operative time for MIS pedicle screw fixation with decompression was  $176 \pm 59$  minutes, and mean length of hospital stay was  $8.2 \pm 3.9$  days. Mean intraoperative blood loss for MIS pedicle screw

**Table 11** Comparison of pre- and postoperative Frankel grading

Frankel grading	A	B	C	D	E
Preop	14	25	113	30	16
Postop	11	18	33	95	41

**Table 10** Types of complications in number of patients

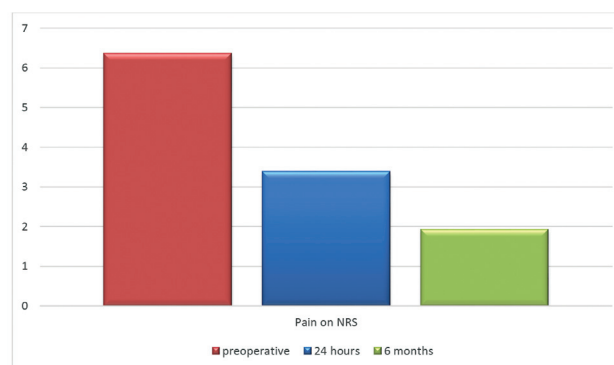
Complications	
Infection	12
Spinal cord contusion	4
Implant failure	5
Pneumonia	8
Urinary tract infection	7
Postoperative hematoma	9
Implant malposition	3

fixation only was  $103.4 \pm 39.3$  mL. There was significant improvement in pain score. Pain on NRS decreased from  $6.38 \pm 3.08$  to  $3.39 \pm 0.73$  at 24 hours postoperatively and  $1.94 \pm 0.67$  at 6 months ( $\rightarrow$  **Fig. 2**).

### Discussion

This single-center study is a review of the surgical approaches used at Royal Preston Hospital for spinal metastases. Our analysis discloses the uniformity in surgical planning for spinal metastasis. More than 90% (179) of cases were discussed in a MDT meeting preoperatively, while the remaining 10% (19) required urgent surgical intervention out of hours. Nonetheless, they were eventually discussed in the MDT postoperatively.

It is challenging and demanding to anticipate a preoperative prognosis for patients with metastatic spinal tumor.<sup>23–27</sup> The use of surgery as a palliative measure is disputed in patients with short survival. The mean revised Tokuhashi scores in our patients were 7.8 and 9.1 in those treated with and without decompression, respectively. Attention should be paid to surgical risks, complications, and intended benefits and cost of treatment when offering a palliative procedure for the patients with limited life expectancy.<sup>23,26</sup> It is strongly viewed that surgical intervention should be offered as it increases the likelihood of patients to undergoing adjuvant treatment, thus, prolonging survival. The objective is predominantly palliative rather than curative in the management of metastatic spinal tumors. The aims of surgical

**Fig. 2** Comparison of pain score as per numeric rating scale at preoperative, at 24 hours, and at 6 months.

interventions are analgesia, maintenance of mobility or improvement of weakness, and improving quality of remaining life.<sup>28</sup>

Surgical intervention is an important means of stabilizing the spine and for spinal cord decompression. Another advantage of minimal invasive surgery is that chemotherapy and RT can be started earlier when compared with traditional open posterior approach.<sup>29</sup> Furthermore, MIS surgery can be effective in patients with poor functional baseline who experience mechanical pain and worsening mobility secondary to spinal instability. Our study revealed a low mortality rate at 6 months, which was lower than other published studies.<sup>8,14,16</sup> It is important to note that the Tokuhashi score, for preoperative assessment of metastatic spinal tumor prognosis, indicated that 77.77% (154) of the cohort had a life expectancy of more than 6 months. Only 5.5% (11) of the total patients died within 6 months. There is very low number of patients lost to follow-up due to close network between the neurosurgical and oncology teams. Considering that the majority of the 10% of the patients who were operated on emergently without MDT discussion had poor prognosis as per Tokuhashi scoring system, 7% survived for more than 6 months. This led us to express our concerns for the effectiveness of the Tokuhashi scoring system, which was introduced in 1990 and revised later,<sup>10,17,18,30</sup> despite the results of Eap et al.<sup>31</sup> We believe that the modern adjuvant therapy and hence, the improved prognosis resulted in the discrepancy of this historical scoring system. Our findings raise concerns regarding the authority of the various scores used to determine life expectancy. These scoring systems are also used to support the decision to perform surgery on patients with metastatic spinal cancer. There are other elements such as American Society of Anesthesiologists grade, Karnofsky index, and the type of the primary tumor which can be utilized as an alternative to assess the prognosis of patients with spinal metastases.<sup>14,16</sup>

The regional control of metastatic lesions banks on postoperative RT or systemic chemotherapy. In a normal individual, the vertebral body supports 80% of the axial load,<sup>32,33</sup> whereas in spinal metastases the tumor encroaches the vertebral body in 70% of the cases. For this reason, the risk of pathological fractures, mechanical instability, and pain is increased. It has been proven that short-segment fixation is inferior to long-segment fixation due to dissipated stress.<sup>34,35</sup> There is significant evidence that surgery plays an important role in pain relief as demonstrated by this study. All the patients had a pain score less than 3 on NRS 6 months postoperatively, which explains the role of surgery in pain control. Another important finding in our study was regarding the neurological outcome. At 6 months postoperatively more than 75% of patients could walk independently versus 53.5% preoperatively. Out of these and 11%, more patients improved to Frankel grade E at 6 months postoperatively in comparison to the literature already available.

In our study, we found that MIS pedicle screw fixation is superior to open pedicle screw fixation in terms of operative time ( $119 \pm 41$  minutes) and blood loss ( $103.4 \pm 39.3$  mL) when comparing results with open pedicle screw fixation

performed for any indication. Hospital stay in our study was 8.2 days. Improvement in walking ability and neurological function emphasize on importance of timely minimally invasive surgery in these patients with limited life expectancy. It is important to note that findings of our study are comparable to published data from centers around the world. For instance, in the study by Bilsky et al, the mean intraoperative blood loss to be 1,700 mL (200–4,000 mL) as recorded while performing open circumferential decompression and fusion using a single-stage posterolateral transpedicular approach in 33 patients with MSCC.<sup>22</sup> Bilsky et al also reported that the mean operating time was 7 hours. The mean hospital stay was 11 days.<sup>22</sup> Furthermore, Bilsky et al also focused on separation surgery especially in cases of extensive spinal metastases. The extent of posterior spinal decompression is thus, directed by disease prognosis and suitability to undergo spinal stereotactic surgery.

Neurological improvement, analgesia, and mobility are the criteria of functionality and applicability of surgical treatment for patients with spinal metastasis.<sup>1,12,36</sup> In our study, the rate of intraoperative and postoperative complications was commensurate to that of existing complex spine surgery studies with instrumentation for indications other than metastasis. Overall complications in our study were 36.1% versus 50% in studies of instrumented spine surgery.<sup>37–39</sup> We believe that surgical care is favorable for these patients, when minimally invasive surgery is used as it is obvious from improved pain score, early hospital discharge, limited blood loss, minimum duration of surgery, and low complication rates. Furthermore, the continued evolution in minimally invasive techniques, for the treatment of tumors in the cervical, thoracic, or thoracolumbar spine, are expected to play a significant role in minimizing the risks and surgical complications.<sup>9,11,40</sup>

The strength of our study is the high number of patients and operations when compared with other publications available in the literature. The limiting factors of the study are its retrospective nature, absence of a comparison cohort, and lack of comparison with nonsurgical management techniques. We included patients that were already discussed in MDT and are surgical candidates, and second, we did not collect data regarding open pedicle screw fixation for spinal epidural metastasis that were declared unstable.

## Conclusion

In conclusion, treatment for spinal metastases should be individualized and a multidisciplinary approach is warranted. Patients treated with minimally invasive spinal surgery had a shorter operation time, less blood loss, a higher rate of discharge back to their homes as opposed to a rehabilitation unit, and lower in-hospital mortality, indicating a procedure with lower invasiveness and better outcome.

### Authors' Contributions

S.M.M.H., I.H., P.K., and A.A.S. conceived and designed the study. K.G., A.R., and A.G. were involved in planning and supervised the work. S.M.M.H., I.H., and A.A.S. collected



the data, and S.M.M.H., I.H., P.K., and A.A.S. performed the analysis, drafted the manuscript, and designed the figures. P.K. and A.A.S. aided in interpreting the results and S.M.M.H. and I.H. worked on the manuscript. All authors discussed the results and commented on the manuscript and approved the version to be published.

#### Ethical Approval

This research study was conducted retrospectively from data obtained for clinical purposes. This retrospective was in accordance with the ethical standards of the institutional and national research committee and with the 1964 Helsinki Declaration and its later amendments or comparable ethical standards.

#### Conflict of Interest

None declared.

#### Acknowledgment

We would like to thank Col. Joanne Eccles (MBE) for the help with data collection and logistics.

#### References

- Yang J, Jia Q, Peng D, et al. Surgical treatment of upper cervical spine metastases: a retrospective study of 39 cases. *World J Surg Oncol* 2017;15(01):21
- Choi D, Bilsky M, Fehlings M, Fisher C, Gokaslan Z. Spine oncology-metastatic spine tumors. *Neurosurgery* 2017;80(3S):S131-S137
- Rosen LS, Gordon D, Kaminski M, et al. Long-term efficacy and safety of zoledronic acid compared with pamidronate disodium in the treatment of skeletal complications in patients with advanced multiple myeloma or breast carcinoma: a randomized, double-blind, multicenter, comparative trial. *Cancer* 2003;98(08):1735-1744
- Lutz S, Lo SS, Chow E, Sahgal A, Hoskin P. Radiotherapy for metastatic bone disease: current standards and future prospectus. *Expert Rev Anticancer Ther* 2010;10(05):683-695
- Patchell RA, Tibbs PA, Regine WF, et al. Direct decompressive surgical resection in the treatment of spinal cord compression caused by metastatic cancer: a randomised trial. *Lancet* 2005;366(9486):643-648
- Cunha MV, Al-Omair A, Atenafu EG, et al. Vertebral compression fracture (VCF) after spine stereotactic body radiation therapy (SBRT): analysis of predictive factors. *Int J Radiat Oncol Biol Phys* 2012;84(03):e343-e349
- Chamberlain MC, Sloan A, Vronis FCancer Care Ontario Practice Guidelines Initiative's Neuro-Oncology Disease Site Group. Systematic review of the diagnosis and management of malignant extradural spine cord compression: the Cancer Care Ontario Practice Guidelines Initiative's Neuro-Oncology Disease Site Group. *J Clin Oncol* 2005;23(30):7750-7751, author reply 7751-7752
- Tabouret E, Gravis G, Cauvin C, Loundou A, Adetchessi T, Fuentes S. Long-term survivors after surgical management of metastatic spinal cord compression. *Eur Spine J* 2015;24(01):209-215
- Hamad A, Vachtsevanos L, Cattell A, Ockendon M, Balain B. Minimally invasive spinal surgery for the management of symptomatic spinal metastasis. *Br J Neurosurg* 2017;31(05):526-530
- Toquart A, Graillon T, Mansouri N, Adetchessi T, Blondel B, Fuentes S. Management of spinal metastasis by minimal invasive surgery technique: surgical principles, indications: a literature review [in French]. *Neurochirurgie* 2016;62(03):157-164
- Bernard F, Lemée J-M, Lucas O, Menei P. Postoperative quality-of-life assessment in patients with spine metastases treated with long-segment pedicle-screw fixation. *J Neurosurg Spine* 2017;26(06):725-735
- de Ruyter GCW, Nogarede CO, Wolfs JFC, Arts MP. Quality of life after different surgical procedures for the treatment of spinal metastases: results of a single-center prospective case series. *Neurosurg Focus* 2017;42(01):E17
- Boriani S, Bandiera S, Donthineni R, et al. Morbidity of en bloc resections in the spine. *Eur Spine J* 2010;19(02):231-241
- Papastefanou S, Alpantaki K, Akra G, Katonis P. Predictive value of Tokuhashi and Tomita scores in patients with metastatic spine disease. *Acta Orthop Traumatol Turc* 2012;46(01):50-56
- Pointillart V, Vital J-M, Salmi R, Diallo A, Quan GM. Survival prognostic factors and clinical outcomes in patients with spinal metastases. *J Cancer Res Clin Oncol* 2011;137(05):849-856
- Tabouret E, Cauvin C, Fuentes S, et al. Reassessment of scoring systems and prognostic factors for metastatic spinal cord compression. *Spine J* 2015;15(05):944-950
- Tokuhashi Y, Matsuzaki H, Oda H, Oshima M, Ryu J. A revised scoring system for preoperative evaluation of metastatic spine tumor prognosis. *Spine* 2005;30(19):2186-2191
- Tokuhashi Y, Matsuzaki H, Toriyama S, Kawano H, Ohsaka S. Scoring system for the preoperative evaluation of metastatic spine tumor prognosis. *Spine* 1990;15(11):1110-1113
- Ulmar B, Richter M, Cakir B, Muche R, Puhl W, Huch K. The Tokuhashi score: significant predictive value for the life expectancy of patients with breast cancer with spinal metastases. *Spine* 2005;30(19):2222-2226
- Frankel HL, Hancock DO, Hyslop G, et al. The value of postural reduction in the initial management of closed injuries of the spine with paraplegia and tetraplegia. I. Paraplegia 1969;7(03):179-192
- Karnofsky DA, Burchenal JH. Present status of clinical cancer chemotherapy. *Am J Med* 1950;8(06):767-788
- Bilsky MH, Boland P, Lis E, Raizer JJ, Healey JH. Single-stage posterolateral transpedicle approach for spondylectomy, epidural decompression, and circumferential fusion of spinal metastases. *Spine* 2000;25(17):2240-2249, discussion 250
- Faul F, Erdfelder E, Lang A-G, Buchner A. G\*Power 3: a flexible statistical power analysis program for the social, behavioral, and biomedical sciences. *Behav Res Methods* 2007;39(02):175-191
- Tokuhashi Y, Ajiro Y, Umezawa N. Outcome of treatment for spinal metastases using scoring system for preoperative evaluation of prognosis. *Spine* 2009;34(01):69-73
- Uei H, Tokuhashi Y, Maseda M. Treatment outcome of metastatic spine tumor in lung cancer patients: did the treatments improve their outcomes? *Spine* 2017;42(24):E1446-E1451
- Verlaan JJ, Choi D, Versteeg A, et al. Characteristics of patients who survived < 3 months or > 2 years after surgery for spinal metastases: can we avoid inappropriate patient selection? *J Clin Oncol* 2016;34(25):3054-3061
- Zairi F, Arikat A, Allaoui M, Marinho P, Assaker R. Minimally invasive decompression and stabilization for the management of thoracolumbar spine metastasis. *J Neurosurg Spine* 2012;17(01):19-23
- Moussazadeh N, Rubin DG, McLaughlin L, Lis E, Bilsky MH, Laufer I. Short-segment percutaneous pedicle screw fixation with cement augmentation for tumor-induced spinal instability. *Spine J* 2015;15(07):1609-1617
- Fisher CG, Schouten R, Versteeg AL, et al. Reliability of the Spinal Instability Neoplastic Score (SINS) among radiation oncologists: an assessment of instability secondary to spinal metastases. *Radiat Oncol* 2014;9:69
- Uei H, Tokuhashi Y, Oshima M, et al. Clinical results of minimally invasive spine stabilization for spinal metastases. *Orthopedics* 2017;40(04):e693-e698

- 31 Eap C, Tardieux E, Goasgen O, et al. Tokuhashi score and other prognostic factors in 260 patients with surgery for vertebral metastases. *Orthop Traumatol Surg Res* 2015;101(04):483–488
- 32 Filis AK, Aghayev KV, Doulgeris JJ, Gonzalez-Blohm SA, Vrionis FD. Spinal neoplastic instability: biomechanics and current management options. *Cancer Contr* 2014;21(02):144–150
- 33 Schwab JH, Gasbarrini A, Cappuccio M, et al. Minimally invasive posterior stabilization improved ambulation and pain scores in patients with plasmacytomas and/or metastases of the spine. *Int J Surg Oncol* 2011;2011:239230
- 34 Tancioni F, Navarria P, Pessina F, et al. Assessment of prognostic factors in patients with metastatic epidural spinal cord compression (MESCC) from solid tumor after surgery plus radiotherapy: a single institution experience. *Eur Spine J* 2012;21(Suppl 1):S146–S148
- 35 Zairi F, Marinho P, Bouras A, Allaoui M, Assaker R. Recent concepts in the management of thoracolumbar spine metastasis. *J Neurosurg Sci* 2013;57(01):45–54
- 36 Rao PJ, Thayaparan GK, Fairhall JM, Mobbs RJ. Minimally invasive percutaneous fixation techniques for metastatic spinal disease. *Orthop Surg* 2014;6(03):187–195
- 37 Campbell PG, Yadla S, Malone J, et al. Complications related to instrumentation in spine surgery: a prospective analysis. *Neurosurg Focus* 2011;31(04):E10
- 38 Kwan MK, Lee CK, Chan CY. Minimally invasive spinal stabilization using fluoroscopic-guided percutaneous screws as a form of palliative surgery in patients with spinal metastasis. *Asian Spine J* 2016;10(01):99–110
- 39 Smith JS, Klineberg E, Lafage V, et al; International Spine Study Group. Prospective multicenter assessment of perioperative and minimum 2-year postoperative complication rates associated with adult spinal deformity surgery. *J Neurosurg Spine* 2016;25(01):1–14
- 40 Gu Y, Dong J, Jiang X, Wang Y. Minimally invasive pedicle screws fixation and percutaneous vertebroplasty for the surgical treatment of thoracic metastatic tumors with neurologic compression. *Spine* 2016;41(Suppl 19):B14–B22