



Radiation-Induced Papillary Meningioma: A Case Report

Manoj Kumar Manivel¹ Visweswaran Vivek¹ Krishnamurthy Ganesh¹

¹Department of Neurosurgery, Sri Ramachandra Institute of Higher Education and Research, Chennai, Tamil Nadu, India

Address for correspondence Manoj Kumar Manivel, MBBS, No. 42, Sakthi nagar, 4th Avenue, Nolambur, Mogappair west, Chennai, 600095, Tamil Nadu, India (e-mail: manoj14kumar@yahoo.com).

AJNS 2022;17:664–667.

Abstract

Keywords

- ▶ radiation-induced meningioma
- ▶ spontaneous meningioma
- ▶ pituitary adenoma
- ▶ fungal sinusitis

Meningiomas are the most common tumors that develop following cranial radiotherapy. They have a shorter latency period and an aggressive behavior when compared with spontaneously occurring meningiomas. We report a 69-year-old male who underwent high-dose radiotherapy for recurrent pituitary adenoma and later developed temporal high-grade meningioma which was excised. Patient developed tumor bed bleed twice in the postoperative period and succumbed subsequently to the disease. After a thorough review of literature, this may be the second case of radiation-induced grade III papillary meningioma which has been reported.

Introduction

The evolution of radiotherapy and radiosurgery has greatly reduced the radiation exposure of nontarget tissues. But radiation-induced tumors remain an important complication of this treatment modality. The overall cumulative risks for patients to develop radiation-induced cranial neoplasms are 2.0% at 5 years and 8.9% at 10 years,^{1,2} of which meningiomas are the most common.²

We present a case of grade III papillary meningioma following high-dose cranial radiotherapy for recurrent pituitary adenoma. To the best of our knowledge, this is the second case in the literature of radiation-induced grade III papillary meningioma.²

Case History

A 69-year-old male presented with clinical features of pituitary adenoma and was operated twice for the same. Postoperative cranial stereotactic radiotherapy (SRT) was given. He subsequently developed a temporal meningioma, which was excised. The sequence of events is as follows.

1. Patient presented in January 2015 with generalized fatigue, bitemporal hemianopia, and panhypopituitar-

ism secondary to pituitary macroadenoma which was excised by endoscopic transnasal transsphenoidal approach (▶**Fig. 1**). Histopathological examination (HPE) confirmed a gonadotroph adenoma positive for follicle-stimulating hormone (FSH) and luteinizing hormone. Patient's vision improved significantly after surgery.

2. In May 2016, he presented with bitemporal hemianopia. Magnetic resonance imaging (MRI) revealed a recurrent pituitary macroadenoma. Reoperation through transnasal approach revealed frank pus in the sphenoid sinus, hence tumor surgery was abandoned (▶**Fig. 2**). Pus for culture and sensitivity grew *Klebsiella pneumoniae* and was treated with susceptible antibiotics. Six weeks later patient underwent functional endoscopic sinus surgery (FESS) with posterior septectomy. Tissue in sphenoid sinus on HPE showed aspergilloma. He was treated with antifungal (Itraconazole).

Three months after FESS, in October 2016, patient presented with deterioration in vision. He could perceive only hand movements in both eyes in bilateral inferior nasal field. Color vision was impaired to red and green. This time the tumor was approached through a right pterional craniotomy and internal decompression of recurrent pituitary macroadenoma was done.

article published online
December 14, 2022

DOI <https://doi.org/10.1055/s-0042-1758847>.
ISSN 2248-9614.

© 2022. Asian Congress of Neurological Surgeons. All rights reserved.

This is an open access article published by Thieme under the terms of the Creative Commons Attribution-NonDerivative-NonCommercial-License, permitting copying and reproduction so long as the original work is given appropriate credit. Contents may not be used for commercial purposes, or adapted, remixed, transformed or built upon. (<https://creativecommons.org/licenses/by-nc-nd/4.0/>)

Thieme Medical and Scientific Publishers Pvt. Ltd., A-12, 2nd Floor, Sector 2, Noida-201301 UP, India

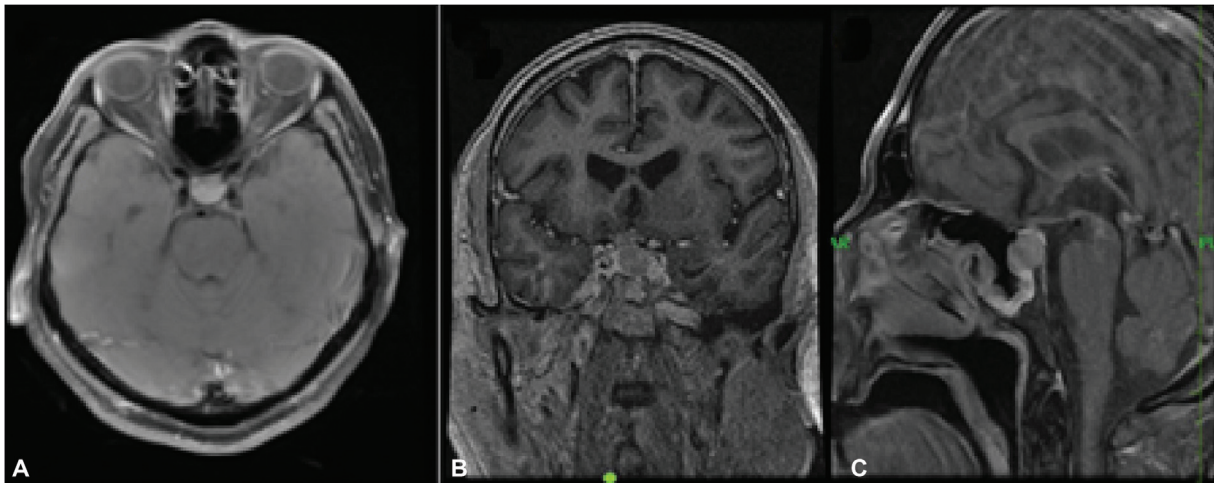


Fig. 1 Magnetic resonance imaging (MRI) brain contrast pituitary macroadenoma with suprasellar extension.

Postoperatively, patient's vision improved. HPE of the tumor was gonadotroph adenoma, positive for FSH. Postoperatively, he underwent external beam radiotherapy for the residual lesion by SRT technique—6 MV photons to a dose of 54 Gy in 30 fractions at 1.8 Gy/fraction, 5 days/week, completed in December 2016. MRI done in October 2018 showed a static small residual pituitary adenoma. No other lesion was noted (→ **Fig. 3**).

3. In December 2020 patient presented with 4 months' duration of progressively worsening speech, memory disturbances, and right-sided weakness. Patient had poor attention span, global dysphasia, and right hemiparesis with 4/5 power. MRI brain revealed a left temporoparietal convexity dural-based, irregular, heterogeneously enhancing space-occupying lesion ($4.9 \times 4.5 \times 4.3$ cm) with disproportionate perilesional edema and significant midline shift to right. A small residual pituitary adenoma was also noted with no

interval change (→ **Fig. 4**). Left temporoparietal craniotomy and Simpson's grade I excision of the lesion was done. The tumor was extra-axial, dura-based, reddish in color, soft to firm in consistency, moderately vascular, had multiple nubbins and pial breach noted at multiple places. Postoperatively, patient's sensorium improved significantly. HPE showed tumor composed of meningothelial cells arranged in sheets, nests, and pseudopapillary pattern, increased nuclear cytoplasmic ratio with atypical mitosis 6/10 high power fields, Ki67 index 20%, epithelial membrane antigen negative, vimentin not contributory, suggestive of papillary meningioma World Health Organization grade III (→ **Fig. 5**).

4. The following day (postoperative day [POD] 1), patient became drowsy. CT brain revealed acute subdural hematoma and extradural hematoma in left temporoparietal region with significant mass effect and midline shift. Recraniotomy and evacuation of hematomas and

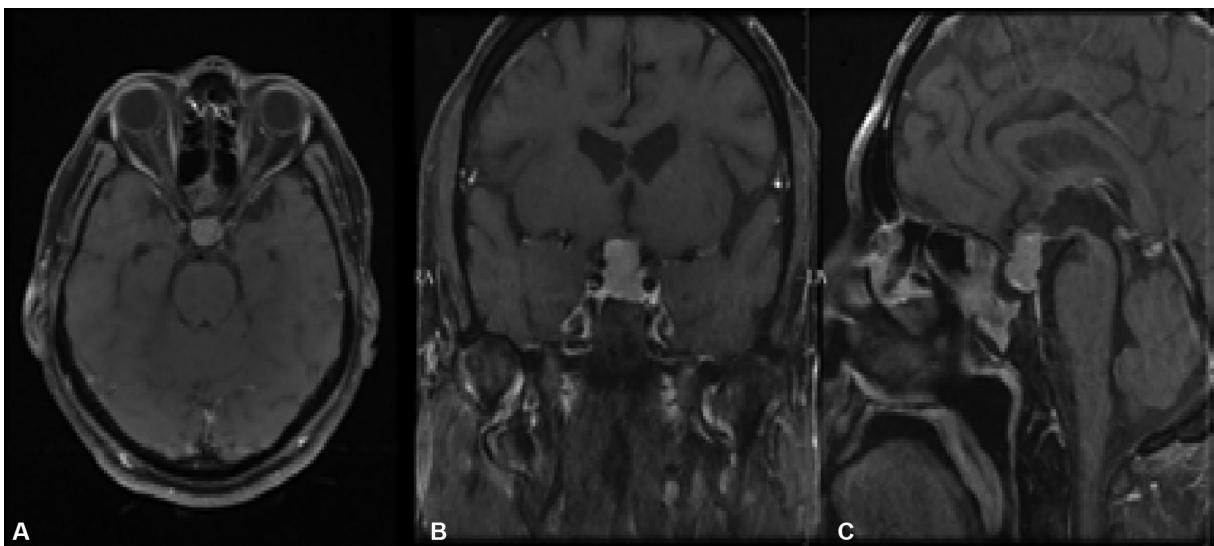


Fig. 2 Magnetic resonance imaging (MRI) brain contrast in April 2016 recurrence of pituitary macroadenoma and hyperintensity in sphenoid sinus suggestive of sinusitis.

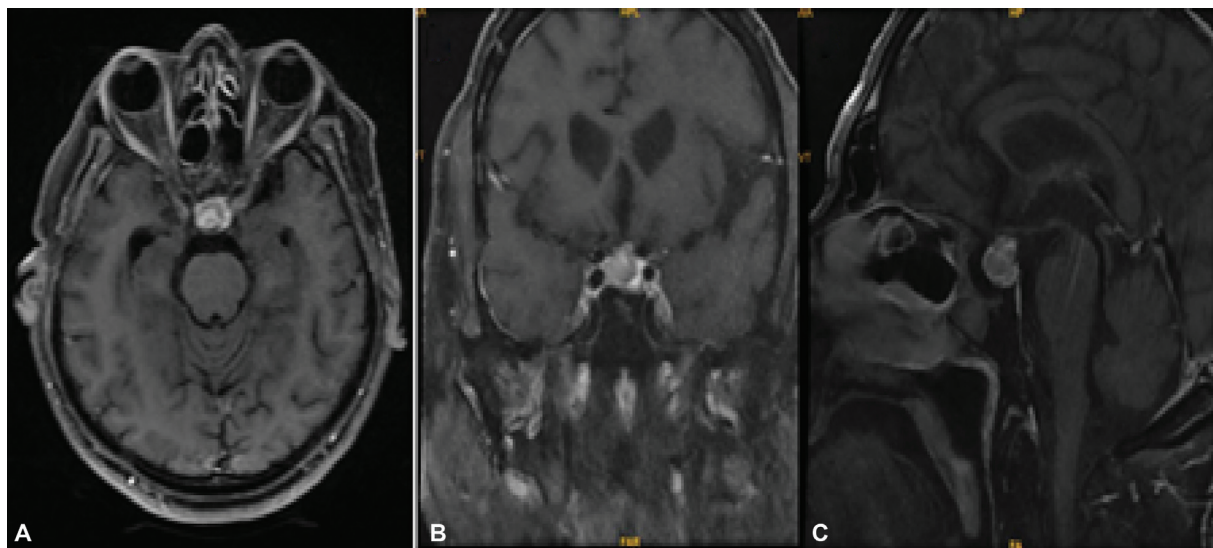


Fig. 3 Magnetic resonance imaging (MRI) brain contrast in October 2018 residual pituitary adenoma with no other lesion noted.

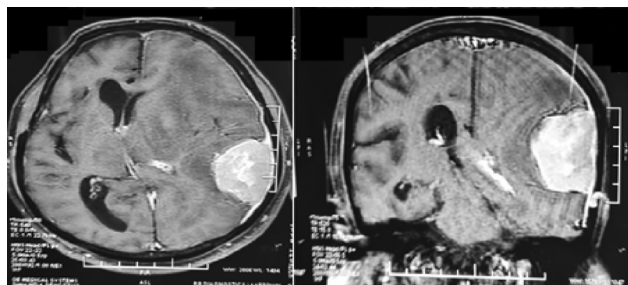


Fig. 4 Magnetic resonance imaging (MRI) brain contrast in November 2020 left temporal convexity meningioma with midline shift to right.

bony decompression was done. Intraoperatively, there was no active source of bleed from the tumor bed and following evacuation of hematoma the brain became lax. Postoperatively, he was electively ventilated. CT brain showed significant reduction in midline shift, hence patient was extubated on POD-2. On POD-3, patient's sensorium improved. He started verbalizing, recognizing relatives, moving all four limbs, and was gradually made ambulant. He tolerated oral feeds. Repeat CT brain done on POD-10 showed postop changes with no fresh tumor bed bleed or infarcts.

- On POD-11, patient developed fever, one episode of right focal seizure involving face only and rapid deterioration in sensorium. CT brain showed fresh tumor bed bleed with edema and significant midline shift. The coagulation profile, platelet count, bleeding time, and clotting time were within normal limits. Emergency evacuation of tumor bed bleed was done. No source of bleed was noted in tumor bed. Following the surgery patient became hemodynamically unstable, continued to deteriorate, and succumbed to the disease on POD-14.

Discussion

The most common brain neoplasm caused by ionizing radiation is radiation induced meningioma (RIM).² Harrison et al have divided RIMs into three groups based on dose of

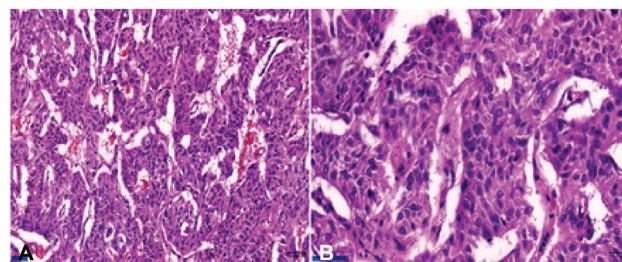


Fig. 5 Histopathological examination (HPE). (A) On low power lesion showing papillary structures, surrounding fibrovascular core appears cellular with nuclear atypia. (B) On high power atypical cells with focal meningothelial features suggestive of papillary meningioma.

radiation exposure: those due to low-dose (< 10 Gy), intermediate-dose (10–20 Gy), and high-dose (> 20 Gy) radiation.³ Our patient falls in the high-dose radiation exposure group.

Criteria for diagnosis of radiation-induced brain tumors was established by Cahan et al based on the following parameters: (1) the tumor must occur within the irradiated field; (2) a sufficient latency period must exist between irradiation and tumor development; (3) the radiation-induced tumor must be proven to be of a different histological type than the original neoplasm; and (4) the patient must not have any pathology favoring the development of tumors such as von Recklinghausen's disease, Li-Fraumeni disease, tuberous sclerosis, xeroderma pigmentosum, retinoblastoma, or neurofibromatosis.⁴

The latency period from radiotherapy to the development of meningioma was shorter in the high-dose radiation group than in the low-dose radiation group. The mean overall latency period between radiation exposure and diagnosis of meningioma is 36.3 years (range 34–48 years).⁵ In one of the recent studies, exposure to higher doses of radiation shortens the length of the latency period to a mean of 19.5 years (range 4–50 years).⁵

Our patient satisfies the above criteria as he developed a temporal meningioma after a sufficient latency period of 4 years after radiation to recurrent pituitary macroadenoma and did not have any phakomatoses.

In RIM, the males were more commonly affected or at least the female predominance was lesser when compared with spontaneous meningioma (SM).^{2,5}

There is a higher incidence of calvarial meningiomas in radiation-induced group when compared with the SM which may be related to the higher dose delivered to the calvaria.²

On histological grading, RIMs have a higher incidence of grade II and III meningiomas than in those with SMs.^{2,5} Yamanaka et al in their extensive literature search had reported an incidence of 13.3% grade II and III RIM following irradiation for pituitary adenomas⁶ and also reported 33.9% of aggressive meningiomas (atypical 21 cases, anaplastic 9 cases, and papillary meningioma 1 case) in the high-dose radiation group than in the low-dose group.² To the best of our knowledge, this is the second case in the literature of radiation-induced grade III meningioma.

On the whole Louis et al had concluded that aggressive meningiomas with high proliferation indices, or atypical, or multifocal tumors are more frequent in the radiation-induced group than SMs.⁷

Because of the invasive nature of aggressive RIM, radical excision may not be always possible and thus adjuvant treatment and clinical long-term follow-up are required.

Management

The main treatment modality for most cases of RIM is surgical excision.

In RIM, in view of higher incidence of calvarial meningiomas, parasagittal and falx meningiomas, assessment of superior sagittal sinus is needed preoperatively. In few cases, the tumor's vascular anatomy may be visualized by preoperative angiography and preoperative embolization may be helpful in highly vascular tumors.⁸

Complete surgical resection is an important component of treatment of RIM. For aggressive RIM involving dura matter wide resection margin is vital to prevent recurrence.⁸ Also, radical removal of the tumor involving the under- or overlying bone is significant in determining the tumor recurrence.⁸ However, for tumors which involve a major cranial sinus or skull base, it becomes difficult to excise with wide resection margin and hence higher recurrence rates have been reported.^{8,9}

Despite the radiation-related origin of these tumors, stereotactic radiosurgery or fractionated stereotactic radiosurgery can provide as an alternative or adjunctive treatment option in some patients.^{8,9}

Despite radical surgery and radiotherapy treatment for RIMs, they have a higher recurrence rates than SM due to their aggressive clinical behavior.¹⁰

In our reported case, following the first surgical excision of pituitary adenoma patient's vision improved. As he developed a recurrence with visual deterioration he was reoperated. Fearing further recurrence cranial radiotherapy

was advised for residual pituitary tumor after second surgery.

We could not explain the reason for repeated postoperative hematoma which occurred after 10 days and resulted in poor outcome. We feel bleeding from the fragile pial vasculature may be the cause for the postoperative hematoma.

Conclusion

RIM is the most common secondary cranial tumor caused by ionizing radiation exposure to brain. The incidence of higher-grade lesions is more common in the RIM group, especially in patients exposed to higher dose of radiation. RIMs have a clinically aggressive behavior and are difficult to treat. The treatment modality of choice is surgical resection with wide resection margin. Radiotherapy can be given to residual/recurrence of tumor. Despite aggressive treatment provided for RIMs, there are high recurrence rates and higher risks of morbidity and mortality.

Informed Consent

Informed consent was obtained from the patient and his guardian.

Conflict of Interest

None declared.

References

- 1 Vinchon M, Leblond P, Caron S, Delestret I, Baroncini M, Coche B. Radiation-induced tumors in children irradiated for brain tumor: a longitudinal study. *Childs Nerv Syst* 2011;27(03):445–453
- 2 Yamanaka R, Hayano A, Kanayama T. Radiation-induced meningiomas: an exhaustive review of the literature. *World Neurosurg* 2017;97:635–644.e8
- 3 Harrison MJ, Wolfe DE, Lau TS, Mitnick RJ, Sachdev VP. Radiation-induced meningiomas: experience at the Mount Sinai Hospital and review of the literature. *J Neurosurg* 1991;75(04):564–574
- 4 Cahan WG, Woodard HQ, Higinbotham NL, Stewart FW, Coley BL. Sarcoma arising in irradiated bone: report of eleven cases. *Cancer* 1998;82(01):8–34
- 5 Sadetzki S, Flint-Richter P, Ben-Tal T, Nass D. Radiation-induced meningioma: a descriptive study of 253 cases. *J Neurosurg* 2002;97(05):1078–1082
- 6 Yamanaka R, Abe E, Sato T, Hayano A, Takashima Y. Secondary intracranial tumors following radiotherapy for pituitary adenomas: a systematic review. *Cancers (Basel)* 2017;9(08):103
- 7 Louis DN, Scheithauer BW, Budka H, von Deimling A, Kepes JJ. Meningiomas. In: Kleihues P, Cavenee WK, eds. *World Health Organization Classification of Tumours. Pathology and Genetics: Tumors of the Nervous System*. Lyon: International Agency for Research on Cancer Press; 2000
- 8 Umansky F, Shoshan Y, Rosenthal G, Fraifeld S, Spektor S. Radiation-induced meningioma. *Neurosurg Focus* 2008;24(05):E7
- 9 Al-Mefty O, Topsakal C, Pravdenkova S, Sawyer JR, Harrison MJ. Radiation-induced meningiomas: clinical, pathological, cytogenetic, and cytogenetic characteristics. *J Neurosurg* 2004;100(06):1002–1013
- 10 De Tommasi A, Occhiogrosso M, De Tommasi C, Cimmino A, Sanguedolce F, Vailati G. Radiation-induced intracranial meningiomas: review of six operated cases. *Neurosurg Rev* 2005;28(02):104–114