




# Building Confident Smiles Using Aesthetic Crown Lengthening Procedures with Gingivectomy: A Report of Two Cases

Ivaturi Sri Sai Meghana<sup>1</sup> Amitha Ramesh Bhat<sup>1</sup> Biju Thomas<sup>1</sup> Rahul Bhandary<sup>1</sup> Nina Shenoy<sup>1</sup> 

<sup>1</sup>Department of Periodontology, A B Shetty Memorial Institute of Dental Sciences, Nitte (Deemed to be University), Mangalore, Karnataka, India

Address for correspondence Amitha Ramesh Bhat, Department of Periodontics, A B Shetty Memorial Institute of Dental Sciences, Nitte (Deemed to be University), Mangalore-575018, Karnataka, India (e-mail: dramitharamesh@nitte.edu.in).

J Health Allied Sci<sup>NU</sup> 2023;13:581–586.

## Abstract

We live in a society that appreciates beauty. More than just restoring the teeth, naturally attractive, confident smiles mean restoring and increasing overall quality of life. Making efforts to improve one's physical appearance is now regarded as an investment in one's health and well-being. Superior periodontal health is the cornerstone for an individual's aesthetic regeneration. As an outcome, perio-aesthetics is a comprehensive strategy that improves the appearance of the smile while maintaining long-term dental health. Hence, getting the ideal aesthetic effect is both difficult and gratifying. Crown lengthening is a feasible option for improving aesthetic appearance or aiding restorative therapy. Yet, before planning a crown lengthening operation, the patient's overall periodontal status and cleanliness habits should be assessed. Furthermore, for enhanced, conservative, and predictable results in aesthetic areas, a precise diagnostic and interdisciplinary strategy is essential. This article attempts to discuss guidelines for treating individuals with excessive gingival display, as well as treatment options, using two case reports as examples.

## Keywords

- ▶ aesthetic crown lengthening
- ▶ biologic width
- ▶ bone sounding
- ▶ Nitte (Deemed to be University)
- ▶ gingivectomy
- ▶ gummy smile
- ▶ resective therapy
- ▶ smile line

## Introduction

Dentists in contemporary dentistry confront clinical decisions on a regular basis with dentition damaged by extensive caries or subgingival fractures. Aesthetics is an integral aspect of modern dentistry care and has had varied degrees of influence on the management of oral diseases for many years. Patients' expectations and awareness have recently increased to the point where less-than-ideal appearances are no longer acceptable.<sup>1</sup> Crown lengthening surgery is classified as either cosmetic or functional. The phrase functional refers to the exposure of fracture or subgingival caries or both. The subject of crown lengthening in anterior sextants is frequently described in the context of

cosmetic surgery.<sup>2</sup> While passive eruption is delayed, excessive gingival show might result in the appearance of short clinical crowns. This condition is more apparent in the presence of a medium or high lipline. If the patient requests a more normal-length anterior dentition, resective therapy that uncovers the anatomical crowns may be appropriate.<sup>3</sup>

Healthy, inflammation-free periodontal tissues are required for an excellent anterior aesthetics. A few authors have questioned the need for this therapy, claiming that if the biologic width is invaded, the body will eventually reestablish the required proportions on its own over time.<sup>4</sup> Crown lengthening surgery, on the other hand, is widely regarded to help physically transport the crest of the alveolus at a suitable apical position to allow room for optimal crown

article published online  
December 30, 2022

DOI <https://doi.org/10.1055/s-0042-1759492>.  
ISSN 2582-4287.

© 2022. The Author(s).

This is an open access article published by Thieme under the terms of the Creative Commons Attribution License, permitting unrestricted use, distribution, and reproduction so long as the original work is properly cited. (<https://creativecommons.org/licenses/by/4.0/>)

Thieme Medical and Scientific Publishers Pvt. Ltd., A-12, 2nd Floor, Sector 2, Noida-201301 UP, India

preparation and reattachment of the epithelium and connective tissue.<sup>5</sup> Also, by adjusting the mesio-distal width and incisio-gingival length of the periodontal tissues in the anterior maxillary region, crown lengthening can provide a more harmonious appearance and promote tissue symmetry.<sup>6</sup> To achieve the best results with crown lengthening surgery, effective communication between the restorative dentist and the periodontist is essential, especially in aesthetically challenging cases. The periodontist recontours and relocates the gingival margin and alveolar crest based on these projections to create an appearance that is both aesthetically attractive and periodontally healthy. The following case reports illustrate these concepts.

## Anatomical Considerations

Aesthetic crown lengthening necessitates meticulous treatment planning, including determining the optimum gingival border and bone level. Diagnostic casts offer an aesthetic overview while also assisting in the recording of the intended gingival/bone placement and guiding the surgeon in determining the exact location and degree of gingivectomy indicated. It is a crucial communication tool between the patient and the periodontist.

## Biologic Width

The principle of biologic width is extensively used as a clinical guideline when assessing periodontal-restorative interactions.<sup>7,8</sup> The biologic width is defined as the dimension of the soft tissue, which is attached to the portion of the tooth coronal to the crest of the alveolar bone. This term was based on the work of Gargiulo et al, who described the dimensions and relationship of the dento-gingival junction in humans.<sup>9</sup> Measurements made from the dento-gingival components of 287 individual teeth from 30 autopsy specimens established that there is a definite proportional relationship between the alveolar crest, the connective tissue attachment, the epithelial attachment, and the sulcus depth. They reported the following mean dimensions: a sulcus depth of 0.69 mm, an epithelial attachment of 0.97 mm, and a connective tissue attachment of 1.07 mm. Based on this work, the biologic width is commonly stated to be 2.04 mm, which represents the sum of the epithelial and connective tissue measurements. One must realize, however, that significant variations in dimensions are observed, particularly in the epithelial attachment, which ranged from 1.0 to 9.0 mm. The connective tissue attachment, on the other hand, is relatively constant.<sup>9</sup>

Similar biologic width dimensions were also reported by Vacek et al in 1994, evaluating 171 cadaver tooth surfaces; they observed mean measurements of 1.34 mm for sulcus depth, 1.14 mm for epithelial attachment, and 0.77 mm for connective tissue attachment. This group also found that the connective tissue attachment was the most consistent measurement.<sup>7</sup> Allen reported that wherever biologic width is violated, there is a reaction by the periodontium. Alveolar bone will resorb inconsistently in an attempt to provide space for a new connective tissue attachment, which will

result in an increase in probing depth.<sup>10</sup> Cohen proposed that interproximal biologic width is similar to that of the facial surface but the total dento-gingival complex is different.<sup>11</sup> According to Kois, the dento-gingival complex is 3.0 mm facially and 4.5 to 5.5 mm interproximally.<sup>12</sup>

## Bone

Prior to considering cosmetic crown lengthening, the level of the alveolar crest must be assessed. The practicality, surgical features, and treatment sequence will be determined by the degree of clinical crown elongation in relation to the position of the alveolar bone. During the planning stages of various surgical interventions, it is used to measure the proximity of the alveolar bone and the width of the soft tissue layer.<sup>13</sup> A measurement device is used to puncture and penetrate the mucosa until contact is made with the underlying bone after a local anesthetic has been administered. Bone sounding is used during this periodontal evaluation to determine the level of the alveolar crest and thus the requirement for osseous contouring.<sup>14</sup>

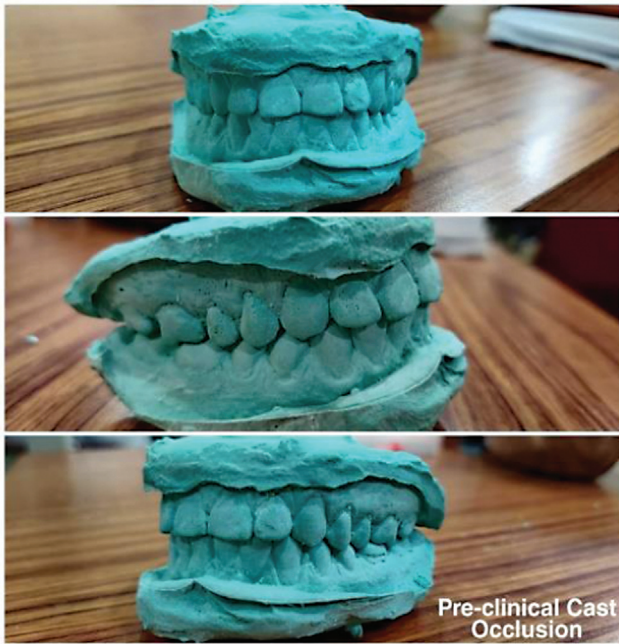Bone sounding is a technique used to establish the location of the alveolar crest, particularly on the labial side but also in the proximal portions, for the purpose of cosmetic crown lengthening.<sup>15</sup>

## Attached Gingiva

Interfering with periodontal and gingival structures may have an impact on the amount of attached gingiva. Several studies have demonstrated that a 2 to 3 mm band of connected gingiva is preferable for properly retaining the restored tooth.<sup>16</sup> When planning surgical crown lengthening, it is critical to analyze and quantify the attached gingiva. Due to the sheer resecting nature of this technique, the width of attached gingiva may be reduced.

## Case Report 1

A 44-year-old female patient with enhanced gum display in the upper front tooth region presented to the department of periodontics. As according to patient history, more gum displaying emerged since childhood. There was no substantial family history as well. There seems to be no systemic troubles in the patient. Extraorally, the patient presents a high smile line, concave profile, with gross abnormalities detected on the face. Intraoral gingival examination reveals pink color, firm consistency, thick gingival biotype and marginal gingiva positioned coronally. They revealed maxillary anterior teeth with short clinical crowns (►Fig. 1A). No periapical radiolucency at radiographic examination was detected, the periodontal ligament was within normal limit, and crown-to-root ratio was approximately 1:3. At clinical examination, attached gingiva band was 6 to 7 mm in width (►Fig. 1B) and periodontal pocket depth was 3 mm or less (►Fig. 2A–C). The primary treatment plan proposed to the patient disagreed with this modality due to the wide duration time and functional burden. Therefore, the treatment plan realized was crown lengthening of 13, 12, 11, 21, 22, and 23 regions. The patient was informed about the treatment and written consent was obtained.



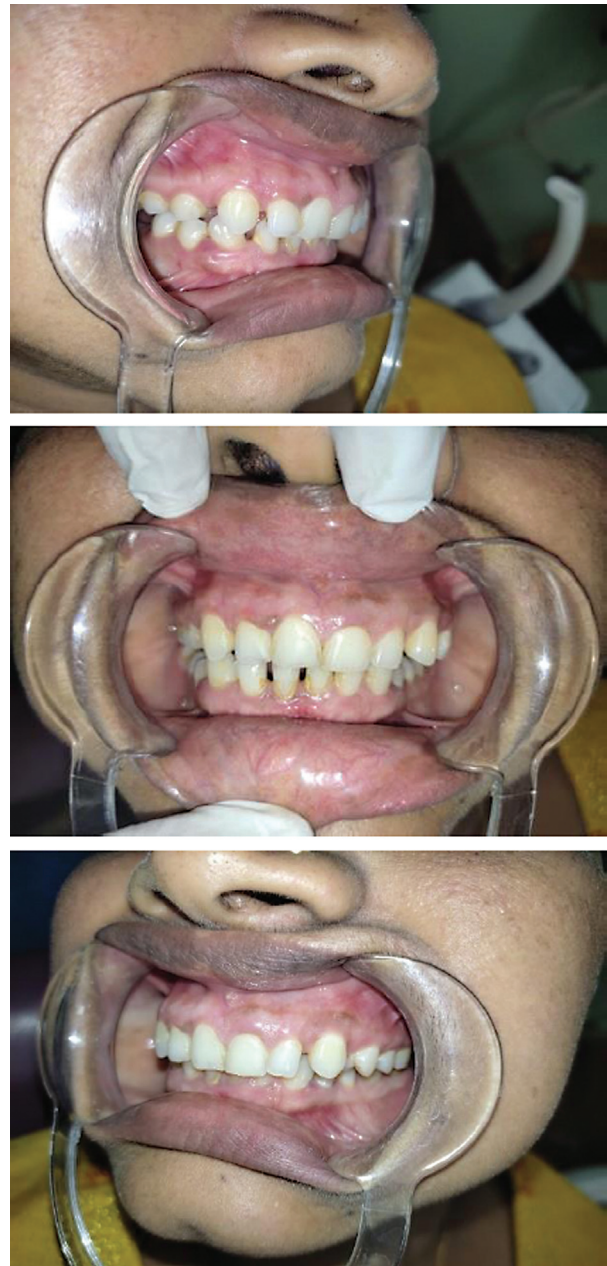**Fig. 1** Dental cast prior to treatment in a 44-year-old female patient presenting with enhanced gum display in the upper front teeth region.

Preoperatively, transgingival probing was performed to determine the level of alveolar crest and as it was more than 2 mm, gingivectomy without osseous surgery was performed.

1. Using a #15 blade, external bevel incision was made on the labial aspect of the tooth to outline the new tooth length and gingival curvature.
2. The incision begins at the mesial and distal line angles of each tooth, forming a crescent-shaped piece of soft tissue on the labial aspect of each tooth (► **Fig. 3**).
3. Saline irrigation was done.
4. Medications prescribed.
5. Patient recalled to the department after 2 weeks and healing was satisfactory (► **Fig. 4**).

## Case Report 2

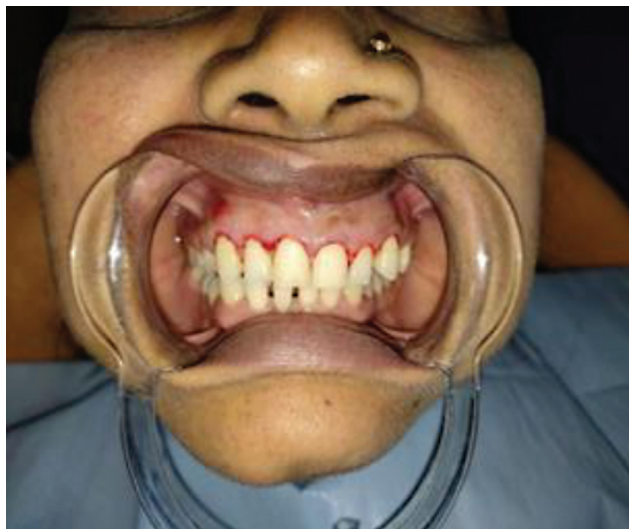A 34-year-old female patient reported to the department of periodontics with the demand for cosmetic correction and “gummy smile.” Clinical examination revealed the extent of attached gingiva (► **Fig. 5B**); she had an excessive display of gingiva. A complete medical history and blood investigations were performed to rule out any systemic contraindications for surgery. The initial examination verified the presence of short teeth in relation to the gingival margin, absence of inflammation, and growth of the gingiva (► **Fig. 5A**). To evaluate the periodontal condition, probing depth, periodontal attachment loss, gingival bleeding, and suppuration examinations were performed. The periodontal examination verified the presence of healthy gingival biotype (► **Fig. 6A–C**). After determining the problem, the surgical technique was determined as crown



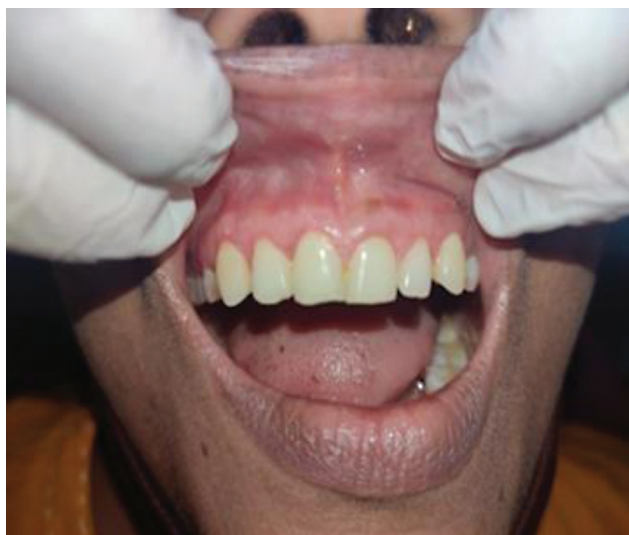**Fig. 2** Preoperative clinical pictures with enhanced gum display and shorter clinical crowns.

lengthening without bone resection in 13, 12, 11, 21, 22, and 23 regions.

1. Gingivectomy was performed by #15 surgical blade to make an external bevel incision.
2. The incision is angulated at 45° toward the long axis of tooth with an apico-coronal direction.
3. Soft tissue was excised without any bone resection (► **Fig. 7**) followed by saline irrigation and placement of periodontal pack.
4. Medications were prescribed.
5. Patient returned to the department after 2 weeks and healing was satisfactory (► **Fig. 8**).



**Fig. 3** Gingivectomy.

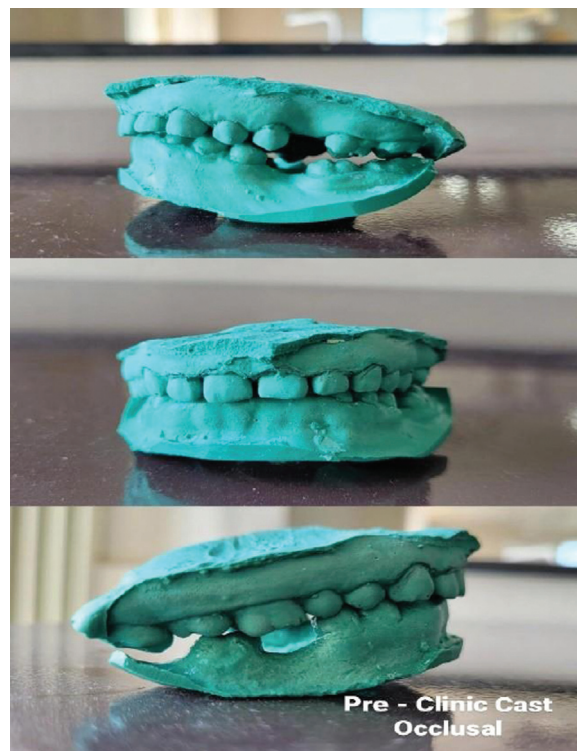


**Fig. 4** Postoperative clinical pictures with longer and aesthetic clinical crowns.

## Cast Reading

### Healing after Crown Lengthening

Restoring procedures must be delayed until new gingival crevice develops after periodontal surgery. In nonaesthetic areas, the site should be reevaluated at least 6 weeks post-surgically prior to final restorative procedures. In aesthetic areas, a longer healing period is recommended to prevent recession. Wise recommends 21 weeks for soft tissue gingival margin stability.<sup>17</sup> Therefore, restorative treatment should be initiated after 4 to 6 months. The margin of the provisional restoration should not hinder healing before the biologic width is established by surgical procedures.<sup>18</sup> Shobha et al, in a study on clinical evaluation of crown lengthening procedure, had concluded that the biologic width can be reestablished to its original vertical dimension along with 2 mm gain of coronal tooth structure at the end of 6 months.<sup>19</sup>



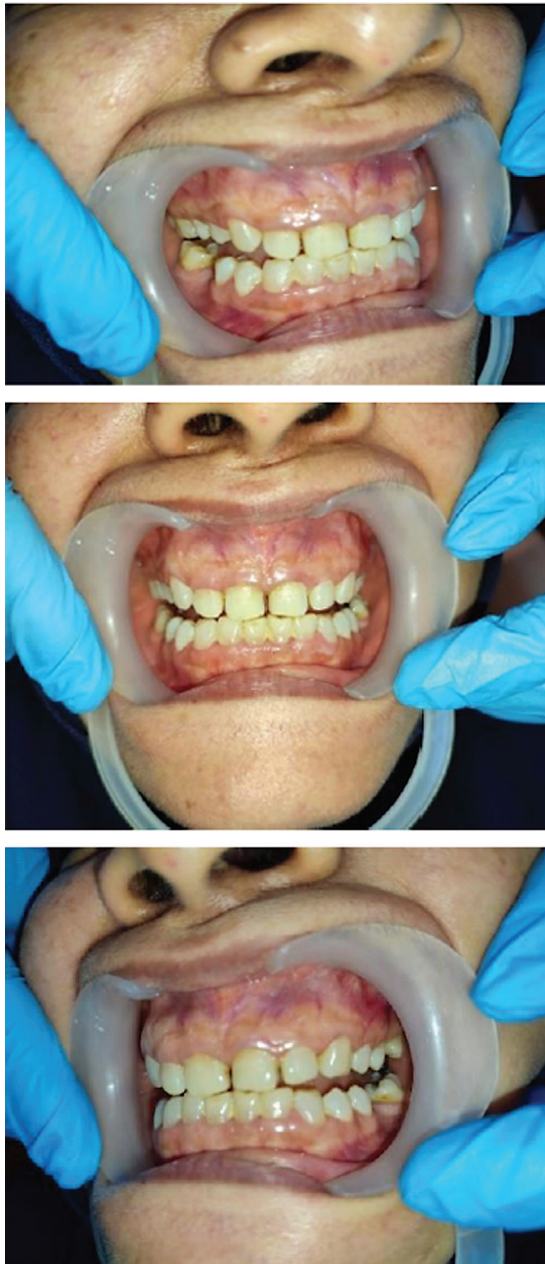**Fig. 5** Dental cast prior to treatment in a 34-year-old female patient presenting 'gummy smile'.

## Discussion

Considering aesthetic crown lengthening surgeries are elective treatments aimed at improving the appearance of the teeth and gums; candidates should only undergo such treatment if they believe that such a change will make them content.<sup>19</sup> Nevertheless, such patients' expectations must be realistic. The practitioner should make it clear that crown lengthening surgery for healthy teeth has a maximum tooth length that cannot be surpassed.<sup>20</sup> Sometimes extensive gingival displays caused by a very high lipline cannot be corrected with crown lengthening and may require lip repositioning surgery or perhaps orthognathic surgery.<sup>21</sup> Another factor to consider while removing bone is the crown-to-root ratio; excessive osseous resection or attachment loss may jeopardize the tooth's attachment, particularly in teeth with periapical apicectomy.<sup>22</sup>

The aesthetic crown lengthening requires gingivectomy procedures to expose the needed additional tooth structure, therefore a minimum of 2 to 5 mm of keratinized tissue is necessary to ensure the gingival health.<sup>23</sup> A study conducted by Roshna and Nandakumar in 2005 reported the cosmetic correction of black gums and gummy smile. Periodontal plastic surgery was performed combined with gingival depigmentation and aesthetic crown lengthening using a scalpel surgical technique. One-year follow-up showed adequate crown length without any demonstration toward relapse.<sup>24</sup>

A case report by Rao et al in 2010 demonstrated aesthetic crown lengthening performed in patients with excessive gingival display along with gingival depigmentation using scalpel technique. Good aesthetics was achieved with

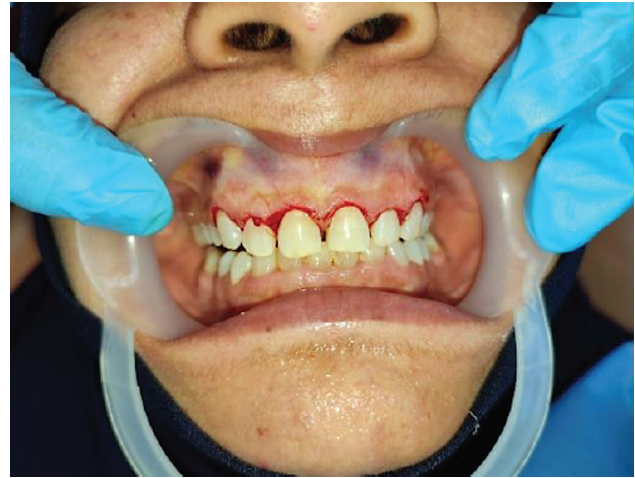

**Fig. 6** Preoperative clinical pictures indicating a gummy smile.

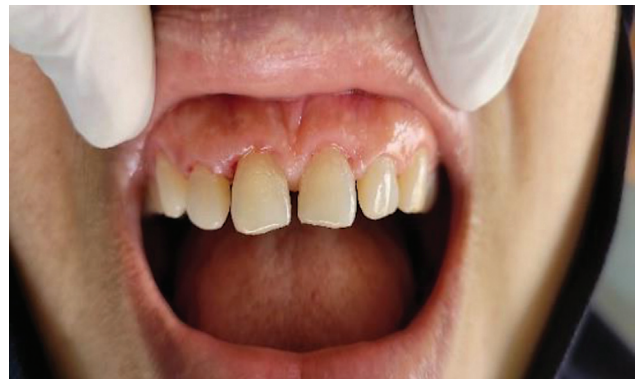increased and ideal crown length with patient-satisfying results in both the cases at 15 days, 1 month, and 6 months of follow-up.<sup>25</sup>

In 2015, Pinto et al reported a case that required crown lengthening as treatment for altered passive eruption. After evaluation of periodontal and aesthetic aspects, gingivectomy was performed without osseous reduction. The patient was satisfied with the final result, and 3-year follow-up did not show any relapse.<sup>26</sup>

However, in a study conducted by Nethravathy et al in 2013, they compared three different surgical techniques of crown lengthening like gingivectomy, apically repositioned flap, and the surgical extrusion technique, which showed several advantages over the other conventional surgical techniques such as preservation of the interproximal papilla,



**Fig. 7** Intraoperative picture.



**Fig. 8** Postoperative clinical pictures with enhanced aesthetics in the upper front teeth region.

gingival margin position, and no marginal bone loss especially in the anterior region, where aesthetics is of great concern.<sup>27</sup>

A study conducted by Primasari in 2022 reported a case where aesthetic crown lengthening was performed by gingivectomy. Using scalpel no. 11, gingivectomy was performed in 21 to 23 regions to create an alignment with tooth in 11 to 13 regions. The patient reported no complaints at 1-week follow-up and the gingival margin looked symmetrical 1 month postsurgery.<sup>28</sup>

An aesthetic blueprint can also be generated that effectively defines the morphological parameters to be achieved with the definite restoration. This can only be accomplished with techniques that allow in vivo testing so that all the aesthetic and functional objectives desired in the definitive restoration are achieved. Nevertheless, a thorough understanding of the anatomical structures involved and the biologic width concept is essential for the appropriate assessment.

If performed with care and consideration to precision, crown lengthening surgery can offer patients with enhanced smiles and predictable outcomes. A thorough understanding of the etiology and the many approaches available is

essential for the surgeon to ensure that the patient receives the best care possible. As with any patient, optimal outcomes are contingent on an accurate diagnosis based on a comprehensive history and clinical examination, as well as meticulous planning tailored to the individual. Further studies may be necessary to determine the long-term stability of the gingival margin position following aesthetic crown lengthening procedures as well as the potential variables introduced by different periodontal biotypes.

## Conclusion

Crown lengthening in the aesthetic zone is a periodontally designed and surgically performed procedure that should be viewed only after careful restorative and surgical treatment planning, which includes radiographic and clinical evaluation of the quality of soft and hard tissues, a detailed smile analysis, and choice of the most appropriate approach for every individual case. Also, recognition of the advantages and disadvantages of each technique should increase predictability and success in interdisciplinary smile enhancement therapy.

### Conflict of Interest

None declared.

## References

- Allen EP. Surgical crown lengthening for function and esthetics. *Dent Clin North Am* 1993;37(02):163–179
- Zucchelli G, Mounssif I. Periodontal plastic surgery. *Periodontol* 2000 2015;68(01):333–368
- Hempton TJ, Esrason F. Crown lengthening to facilitate restorative treatment in the presence of incomplete passive eruption. *J Calif Dent Assoc* 2000;28(04):290–291, 294–296, 298
- Burch JG. Periodontal considerations in operative dentistry. *J Prosthet Dent* 1975;34(02):156–163
- Carnevale G, Sterrantino SF, Di Febo G. Soft and hard tissue wound healing following tooth preparation to the alveolar crest. *Int J Periodontics Restorative Dent* 1983;3(06):36–53
- Lai JY, Silvestri L, Girard B. Anterior esthetic crown-lengthening surgery: a case report. *J Can Dent Assoc* 2001;67(10):600–603
- Vacek JS, Gher ME, Assad DA, Richardson AC, Giambarresi LI. The dimensions of the human dentogingival junction. *Int J Periodontics Restorative Dent* 1994;14(02):154–165
- Rosenberg ES, Garber DA, Evian CI. Tooth lengthening procedures. *Comp Contin Educ Gen Dent* 1980;1(03):161–172
- Gargiulo AW, Wentz FM, Orban B. Mitotic activity of human oral epithelium exposed to 30 per cent hydrogen peroxide. *Oral Surg Oral Med Oral Pathol* 1961;14:474–492
- Allen EP. Use of mucogingival surgical procedures to enhance esthetics. *Dent Clin North Am* 1988;32(02):307–330
- Cohen ES. *Atlas of Cosmetic and Reconstructive Periodontal Surgery*. USA: People's Medical Publishing House; 2007
- Kois JC. The restorative-periodontal interface: biological parameters. *Periodontol* 2000 1996;11:29–38
- Ingber JS, Rose LF, Coslet JG. The "biologic width"—a concept in periodontics and restorative dentistry. *Alpha Omegan* 1977;70(03):62–65
- Oakley E, Rhyu IC, Karatzas S, Gandini-Santiago L, Nevins M, Caton J. Formation of the biologic width following crown lengthening in nonhuman primates. *Int J Periodontics Restorative Dent* 1999;19(06):529–541
- Kois JC. Altering gingival levels: the restorative connection part I: biologic variables. *J Esthet Restor Dent* 1994;6(01):3–7
- Becker W, Ochsenbein C, Becker BE. Crown lengthening: the periodontal-restorative connection. *Compend Contin Educ Dent* 1998;19(03):239–240, 242, 244–246 passim, quiz 256
- Wise MD. Stability of gingival crest after surgery and before anterior crown placement. *J Prosthet Dent* 1985;53(01):20–23
- Robbins JW. Tissue management in restorative dentistry. *Funct Esthet Restor Dent*. 2007;1:40–43
- Shobha KS, Mahantesha, Seshan H, Mani R, Kranti K. Clinical evaluation of the biological width following surgical crown-lengthening procedure: a prospective study. *J Indian Soc Periodontol* 2010;14(03):160–167
- Magne P, Gallucci GO, Belser UC. Anatomic crown width/length ratios of unworn and worn maxillary teeth in white subjects. *J Prosthet Dent* 2003;89(05):453–461
- Sheth T, Shah S, Shah M, Shah E. Lip reposition surgery: a new call in periodontics. *Contemp Clin Dent* 2013;4(03):378–381
- Padbury A Jr, Eber R, Wang HL. Interactions between the gingiva and the margin of restorations. *J Clin Periodontol* 2003;30(05):379–385
- Lang NP, Löe H. The relationship between the width of keratinized gingiva and gingival health. *J Periodontol* 1972;43(10):623–627
- Roshna T, Nandakumar K. Anterior esthetic gingival depigmentation and crown lengthening: report of a case. *J Contemp Dent Pract* 2005;6(03):139–147
- Rao KVP, Reddy N, Anitha B. Aesthetic crown lengthening. *Annals Essences Dentistry*. 2010;16:124–128
- Pinto SC, Higashi C, Bonafé E, Pilatti GL, Santos FA, Tonetto MR. Crown lengthening as treatment for altered passive eruption: review and case report. *WORLD* 2015;6(03):178–183
- Nethravathy R, Vinoth SK, Thomas AV. Three different surgical techniques of crown lengthening: a comparative study. *J Pharm Bioallied Sci* 2013;5(Suppl 1):S14–S16
- Primasari VS. Crown lengthening surgery for treating asymmetric gingiva: a case report. *KNE Medicine* 2022;x:9–14. Doi: 10.18502/kme.v2i1.10832