



A Prospective Multicenter Randomized Controlled Trial to Evaluate the Efficacy of Chitosan Hydrogel Paste in Comparison to Commercial Hydroactive Gel as a Wound Bed Preparation

Nur Azida Mohd Nasir¹, Arman Zaharil Mat Saad^{1,2}, Nor Sa'adah Bachok³, Ahmad Hazri Ab Rashid⁴,
Zanariah Ujang⁴, Kartini Noorsal⁴, Norimah Yusof⁵, Kamaruddin Hashim⁵, Fatimah Mohd Nor⁶,
Farrah-Hani Imran⁷, Nazri Mohd Yusof⁸, Mohd Ariff Sharifudin⁹, Ahmad Sukari Halim^{1,2}

¹Reconstructive Sciences Unit, School of Medical Sciences, Health Campus, Universiti Sains Malaysia, Kelantan, Malaysia

²Reconstructive Sciences Department, Hospital Universiti Sains Malaysia, Kubang Kerian, Kelantan, Malaysia

³Biostatistic and Research Methodology Unit, School of Medical Sciences, Universiti Sains Malaysia, Kelantan Malaysia

⁴SIRIM Industrial Research, SIRIM Berhad, Shah Alam, Selangor, Malaysia

⁵Nuclear Malaysia Agency, Kajang, Selangor, Malaysia

⁶Plastic and Reconstructive Surgery, Kuala Lumpur Hospital, Jalan Pahang, Kuala Lumpur, Malaysia

Address for correspondence Ahmad Sukari Halim, FCCP, Reconstructive Sciences Unit, School of Medical Sciences, Health Campus, Universiti Sains Malaysia, 16150 Kubang Kerian, Kelantan, Malaysia (e-mail: ashlim@usm.my).

⁷Department of Surgery, Faculty of Medicine, Universiti Kebangsaan Malaysia Medical Center, Kuala Lumpur, Malaysia

⁸Orthopaedic Department, Kulliyah of Medicine, International Islamic University Malaysia, Kuantan, Pahang, Malaysia

⁹Faculty of Medicine, Universiti Sultan Zainal Abidin, Kuala Terengganu

Indian J Plast Surg 2023;56:44–52.

Abstract

Background This clinical trial aimed to evaluate the clinical efficacy of chitosan derivative hydrogel paste (CDHP) as a wound bed preparation for wounds with cavities.

Methods This study enrolled 287 patients, with 143 patients randomized into the CDHP group (treatment) and 144 patients randomized into the commercial hydroactive gel (CHG) group (control). The granulation tissue, necrotic tissue, patient comfort, clinical signs, symptoms, and patient convenience during the application and removal of the dressing were assessed.

Results The study was completed by 111 and 105 patients from the treatment and control groups, respectively. Both groups showed an increasing mean percentage of wound granulation over time when the initial wound size and comorbidity were adjusted ($F(10,198) = 4.61$; $p < 0.001$), but no significant difference was found between the groups ($F(1,207) = 0.043$; $p = 0.953$). The adjusted mean percentage of necrotic tissue of both groups showed a significant decrease over time ($F(10,235) = 5.65$; $p < 0.001$), but no significant differences were found between the groups ($F(1,244) = 0.487$; $p = 0.486$).

Conclusion CDHP is equivalent to CHG and is an alternative in wound management and wound bed preparation for wounds with cavities.

Keywords

- ▶ chitosan dressing
- ▶ full-thickness wound
- ▶ cavity wounds
- ▶ granulation

article published online
December 22, 2022

DOI <https://doi.org/10.1055/s-0042-1759503>.
ISSN 0970-0358.

© 2022. Association of Plastic Surgeons of India. All rights reserved.
This is an open access article published by Thieme under the terms of the Creative Commons Attribution-NonDerivative-NonCommercial-License, permitting copying and reproduction so long as the original work is given appropriate credit. Contents may not be used for commercial purposes, or adapted, remixed, transformed or built upon. (<https://creativecommons.org/licenses/by-nc-nd/4.0/>)
Thieme Medical and Scientific Publishers Pvt. Ltd., A-12, 2nd Floor, Sector 2, Noida-201301 UP, India

Introduction

Chitosan is a biodegradable, nontoxic, complex carbohydrate derivative of chitin (poly-N-acetyl-D-glucosamine),^{1,2} a naturally occurring material found in crustacean exoskeletons (such as crabs and shrimp) and the cell walls of fungi.²⁻⁴

Chitosan possesses various biological properties, such as hemostasis⁵⁻⁸ and acesodyne activity (analgesic), wound healing properties,^{9,10} scar reduction, bacteriostasis,^{11,12} biocompatibility, and biodegradability.¹³⁻¹⁷ These properties make chitosan a suitable candidate as a prospective material for wound dressings.

Chitosan is water insoluble but can be made water soluble either through derivatization of its functional groups or hydrolysis of the long polymeric chains into shorter chain length chitosan products called oligochitosan.¹⁸ One such derivative is N,O-CMC, a water-soluble chitosan derivative bearing carboxymethyl substituents at some of both amine and 6-hydroxyl sites of glucosamine units. Moisture retention, gel performance capability, low toxicity, and good biocompatibility are a few of the physical and biological features that make chitosan a promising biomaterial.¹⁹

Various dressings are available, indicating that no single dressing material can be considered the gold standard and suitable for all wound types.^{20,21} Ideally, wound dressings should be selected based on their ability to enhance re-epithelialization as well as angiogenesis and extracellular matrix (ECM) synthesis. To enhance blood flow for angiogenesis, the ideal dressing must be sufficiently permeable to allow gas exchange while maintaining tissue temperature.²²

Furthermore, the dressing must be nonadherent and easy to remove, preventing damage to the new epithelialized and granulation tissues, and the dressing must provide a debridement factor for easy removal of necrotic tissue.^{20,21,23,24} Wound dressings are generally classified as passive, interactive, or bioactive (advance)^{25,26} products that contain an active compound that aids wound healing.

Gel dressings are widely used as a wound treatment. The most common hydroactive gels include Intrasite, Hydrosorb, Purilon, and DuoDERM hydroactive gels. Commercial hydroactive gel (CHG) is a viscous hydrogel that is preservative-free and transparent. It has been recommended for partial and full-thickness wounds, and as a filler for dry cavity wounds to generate a moist healing environment.

This clinical trial is aimed to compare the clinical efficacy of biomedical grade chitosan derivative hydrogel paste (CDHP) in a clinical setting compared with CHG for wound bed preparation.

Patients and Methods

This prospective, multicenter, randomized controlled clinical trial involved patients at our study centers with full-thickness wounds with a cavity that required wound bed preparation for a subsequent surgery/procedure to close the wound at a later stage.

Selection of Patients

Patients of both sexes, aged 16 to 70 years, who presented with a full-thickness wound with a cavity at the four medical centers in Malaysia were screened for the study. Patients with severely contaminated or infected wounds, allergies to seafood, uncontrolled diabetes (random blood glucose >10 mmol/L), noncompliance, pregnancy, and any skin pathology (such as eczema) were excluded from the study. Patients who fulfilled the inclusion criteria were enrolled in the study after providing signed consent and were randomized into either the treatment groups with CDHP dressings or control group with commercially available CHG dressings. Randomization was conducted using web-based software (<http://www.randomization.com>).

Preparation of CDHP Dressing

This dressing was manufactured in a good manufacturing practice-compliant pilot plant facility by our collaborator, Standard and Industrial Research Institute Malaysia (SIRIM Malaysia). This product was granted a Malaysian patent with grant no. MY-145085-A on 30 December 2011 under the Intellectual Property Corporation of Malaysia (MyIPO).

Hydroactive Dressing

The hydroactive gel dressing was purchased from our local supplier.

Dressing Application

Wound toilets were treated with 0.9% normal saline and 0.5% chlorhexidine aqueous solution until clean and free of dirt or foreign bodies. The dressing material, either CDHP or CHG, was applied to the wound, and a secondary dressing was applied using an Opsite Flexigrid with gauze on top and secured with a bandage. The dressing was changed every 1 to 3 days based on the wound condition that was decided by the treating surgeon/physician. The wounds were photographed during wound inspection and before a new dressing was applied (► Fig. 1).

Measurement Outcomes

The patient details and all clinical characteristics were recorded on a case report form by our trained research assistants (staff nurses/medical assistants). The time until the wound bed is ready, granulation tissue, necrotic tissue, patient comfort (pain and itching), clinical appearance (wound drainage, erythema, localized warmth, and edema), convenience during application and removal of the dressings, such as pain following removal, exudate, adherence, ease of removal, and odor, were all noted. Additionally, notes were made regarding allergies and complications caused by the dressings.

The formation of granulation tissue (percentage of area), quality of granulation tissue, wound contraction (percentage of area), and exudates and pain were evaluated using a scale of 0 to 3 (where 0 denotes nil/none and 3 denotes maximum).²⁷ Patient comfort (pain and itching) and pain following removal of the dressings were assessed using a visual analog scale of 0 to 10 (where 0 denotes nil/none and 10 denotes maximum).

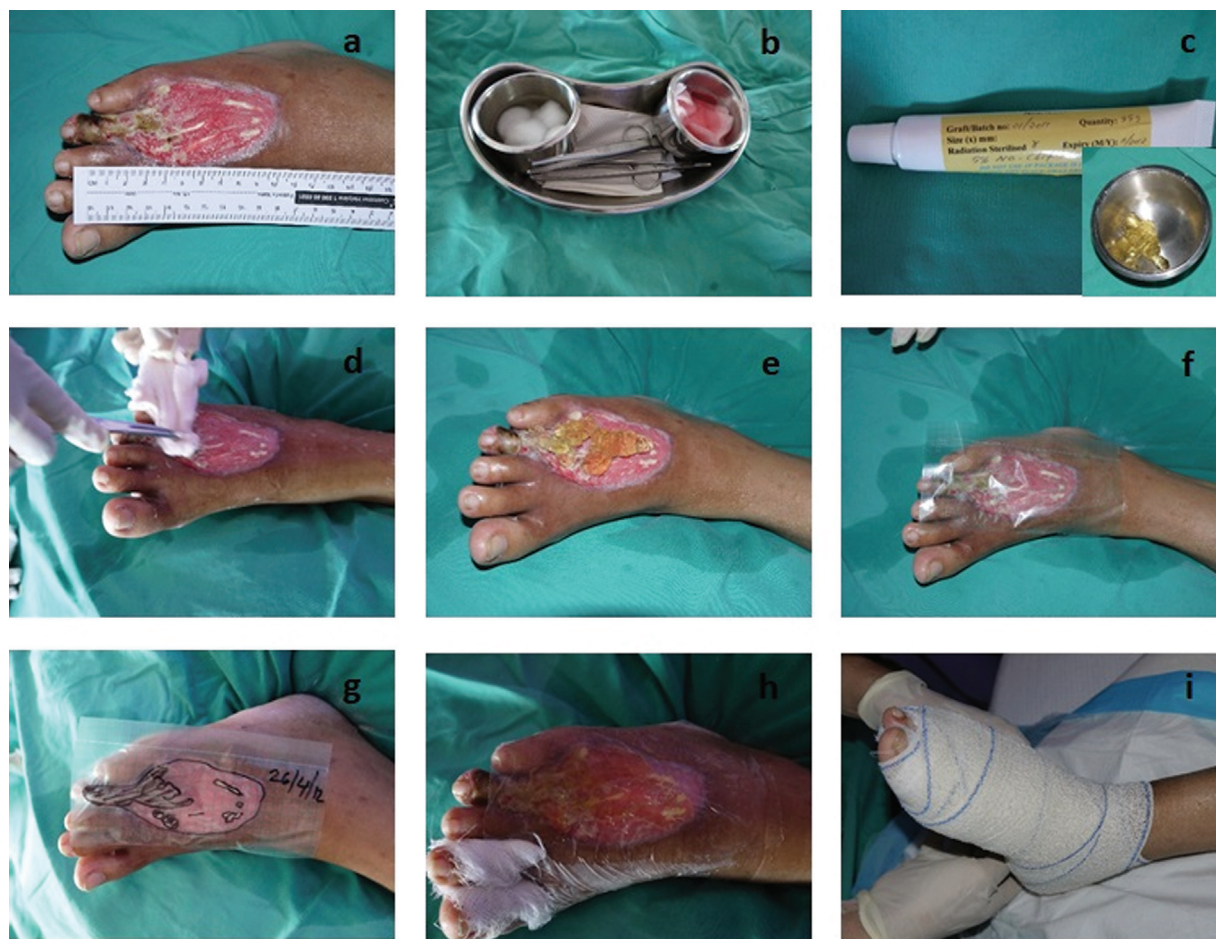

Fig. 1 Wound toilet preparation and dressing application. The wound was photographed with a disposable ruler (a), wound dressing set; 0.9% normal saline and 0.5% CHD solution (b), Chitosan gel (c), wound toilet cleaning (d), Chitosan hydrogel gel on wound bed (e), wound was covered with Opsite flexigrid and traces using marker pen (f–g) the grid layer of Opsite flexigrid was removed (h), a bandage was applied as a secondary dressing (i).

Statistical Methods

The data were analyzed using IBM SPSS Statistic version 24. Numerical variables were summarized as means and standard deviations, and categorical variables were presented as frequencies and percentages. Baseline comparisons of variables were performed using Pearson's chi-squared test, independent *t*-test, and one-way analysis of variance. Differences in scores between groups at any time point were analyzed using independent *t*-test. Repeated measures analysis of covariance was used to analyze the time effect, treatment effect, time–treatment interaction effect for the granulation, necrotic tissue percentages, the assessments of wound characteristics, dressing, granulation tissue, and complications. All analyses were adjusted for initial wound size and diabetes comorbidity. The level of significance was set at a *p*-value of 0.05.

Results

A total of 287 patients were included during the study period from April 2012 until May 2019. Of these, 143 patients were randomized into the treatment group, and 144 patients were randomized into the control group. One hundred eleven and

105 patients from the treatment and control groups, respectively, completed the study, while 58 patients (25 and 33 from the treatment and control groups, respectively) were discontinued for various reasons.

A comparison of the patients' background characteristics and baseline data is shown in ▶Table 1. Both groups were comparable except for the days to complete the study (healing duration) ($p = 0.032$) and initial wound size ($p = 0.025$). Because of the higher initial wound size, the duration of healing in the treatment group was longer time than that of the control group.

When the healing duration was compared further, significant mean differences were observed in the healing duration among the age group, diabetes, and wound etiology (▶Table 2). The younger group and nondiabetic patients healed faster than the other groups. Those with motor vehicle accidents and trauma healed faster than those with infection and surgical complications.

The wounds were located at various parts of the body, and most were at the lower limbs for both groups with number of wounds are 95 and 76, respectively (▶Fig. 2A). ▶Fig. 2B compares the healing times of different types of wound edges. Most of the wounds had sloping edges. Although the punch-out

Table 1 The distribution of background and baseline parameters of treatment and control groups

	Frequency (%) / mean (SD)		p-Value
	Treatment (n = 136)	Control (n = 140)	
Age (y)	49.61 (16.71)	47.71 (15.11)	0.320 ^a
Sex			
Male	79 (52.3)	72 (47.7)	0.266 ^b
Female	57 (45.6)	68 (54.4)	
Race			
Malays	123 (50.6)	120 (49.4)	NA
Chinese	6 (40.0)	9 (60.0)	
Indian	4 (36.4)	7 (63.6)	
Others	3 (42.9)	4 (57.1)	
Comorbidity			
None	22 (44.0)	28 (56.0)	NA
Recent surgical procedure	26 (40.6)	38 (59.4)	
Recent trauma	15 (42.9)	20 (40.4)	
Diabetes mellitus	62 (59.6)	42 (40.4)	
Peripheral vascular disease	1 (100)	0	
Days to complete the study	12.97 (10.24)	10.41 (9.56)	0.032 ^a
Initial wound size (cm ²)	59.54 (100.72)	37.17 (57.44)	0.025 ^a

Abbreviations: NA, not applicable; SD, standard deviation.

^aIndependent t-test.

^bChi-squared test.

Table 2 Comparison of means of healing time (day) between variables

	Healing time (d) Mean (SD)	p-Value
Age group (y)		
< 40	7.43 (7.72)	<0.001 ^a
40–60	12.84 (10.35)	
> 60	14.12 (10.07)	
Diabetes		
Yes	15.55 (10.26)	<0.001 ^b
No	8.13 (8.25)	
Recent surgical procedure		
Yes	15.55 (10.26)	0.721 ^b
No	8.13 (8.25)	
Wound etiology		
Infection	12.73 (10.57)	0.004
Motor vehicle accidents	7.23 (7.64)	
Surgical complications	14.00 (7.82)	
Trauma	7.00 (5.41)	
Others	13.67 (8.31)	

Abbreviations: ANOVA, analysis of variance; SD, standard deviation.

^aOne-way ANOVA.

^bIndependent t-test.

wound took longer to heal, no significant mean differences were found between the groups ($p = 0.087$).

A significant time effect was observed on the percentage of granulation when the initial wound area and comorbidity were adjusted (F stat (10, 198) = 4.61; $p < 0.001$). However, no statistical significance was observed regarding the effect of treatment (F stat (1, 207) = 0.043; $p = 0.836$). A significant interaction effect was observed between treatments and time when other variables were adjusted (F stat (10, 198) = 2.17; $p = 0.021$). Both the treatment and control groups showed an increasing mean percentage of wound granulation at the respective time points (► Fig. 2C). The granulation tissue formation was evident in the wound healing progress (► Fig. 3).

► Fig. 2D shows a significant time effect on the percentage of necrotic tissue when the initial wound area and comorbidity were adjusted (F stat (10, 235) = 5.65; $p < 0.001$). However, no significant effects of the treatments (F stat (1, 244) = 0.487; $p = 0.486$) or interaction effects, F stat (10, 235) = 1.44, $p = 0.162$ were noted. Both groups showed a decreasing mean percentage of necrotic tissue at the respective time points.

Both the treatment and control groups had significantly decreased means in wound drainage and erythema over time. However, no significant differences were found between the groups and time-treatment interaction in all clinical signs and symptoms of the wound (► Table 3).

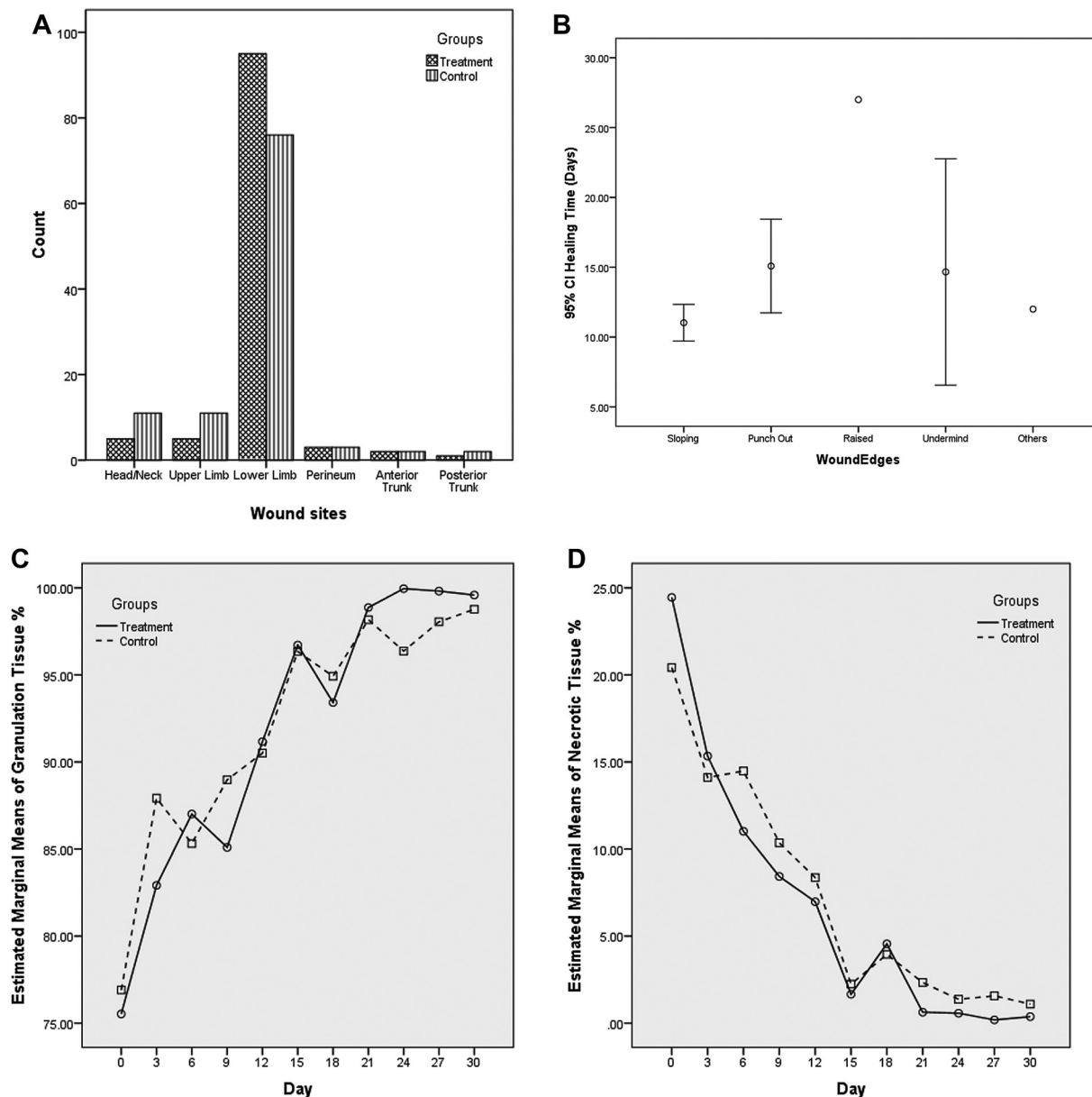


Fig. 2 Distribution of wound sites. (A) Comparison of the healing time between different types of wound edges. (B) Effect of treatments on the percentage of wound granulation tissue over time. (C) Effect of treatments on the percentage of necrotic tissue over time points (D).

Regarding the ease of removal and odor of the dressings, both groups had significant mean differences over time. The ease of dressing removal improved significantly over time, but the odor in both groups was significantly increased on day 21. At all-time points, the treatment group had significantly less pain following removal than the control group. No significant interaction time-treatment was found in any dressing assessment (► **Table 3**).

Both groups showed a significant decrease in the mean scores regarding color, thickness, and consistency of the granulation tissue over time. No significant treatment or interaction effects were observed in any granulation tissue assessment (► **Table 3**).

The mean scores for local and systemic complications decreased significantly for both groups over time. However,

no significant treatment or interaction effects were found for complication assessments (► **Table 3**).

Discussion

This study showed the effectiveness of CDHP compared with conventional CHG dressings for wound bed preparation. The use of a CDHP dressing on full-thickness wounds with cavities was supported by previous studies.^{2,10,28-31} This dressing can keep the wound moist and enhance granulation tissue. This clinical trial demonstrated the effectiveness of CDHP dressings in wound bed preparation concerning granulation and removal of necrotic tissue from cavitation wounds.

However, proving that one material was superior to the other in terms of wound healing was challenging. The reason

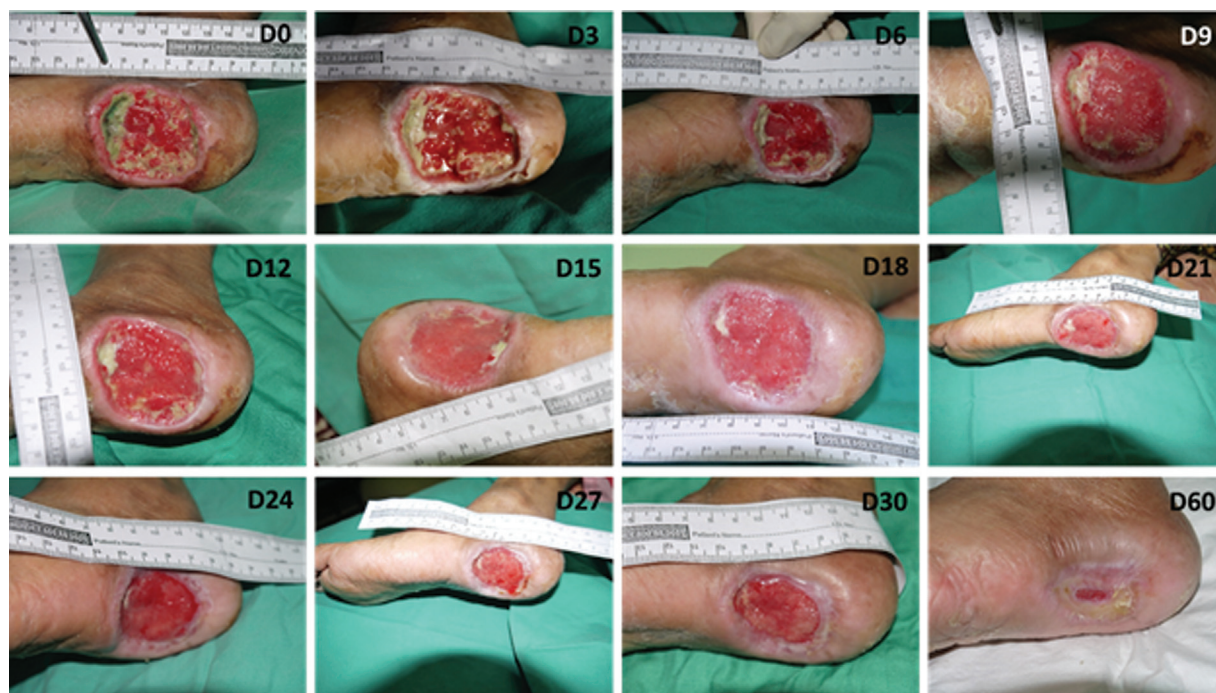


Fig. 3 Wound healing progress. Wound assessment was done every 3 days until the wound bed was prepared for secondary wound closure with a split skin graft. By day 24, the wound was ready for secondary wound closure using a split skin graft.

is that full-thickness wounds with cavities (large in size) will take a longer time for primary wound closure. Hence, this study demonstrated the use of CDHP for wound bed preparation before the secondary intention of wound closure. Almost all wounds demonstrated new granulation tissue and less necrotic tissue in the wound bed over the time points.

Although randomization of the treatment group was performed, the initial wound area was significantly larger in the CDHP group than in the control group, likely causing delayed healing. However, the difference in the baseline wound size was adjusted by conducting repeated measure analysis of covariance. Most of the wound beds were prepared and ready for the secondary intention of wound closure between days 10 and 12 in both groups.

Granulation is crucial in cavity/full-thickness wound healing. During the proliferative phase, macrophages actuate fibroblasts to release growth factors from the ECM,³² migrate to the wound via a fibrin–fibronectin matrix network^{33,34}, synthesize, and secrete the ECM.^{35,36} The primary composition of the initial wound matrix is fibrin, glycosaminoglycan (GAG), and hyaluronic acid.^{37,38} The GAG scaffold holds type I and III collagen. At this stage, the wound bed contains a dense capillary network clinically known as neoangiogenesis, giving the granulation tissue a pink, soft, and granular appearance.^{32,39–41} Hence, the wound must be covered with an effective dressing to prevent contamination and secure the process of granulation.

In our study, granulation gradually increased at the respective time points in both groups and decreased in necrotic tissue development across the time points. Thus, both dressings enhanced wound repair while providing

moisture and protection to the wound via properties such as antibacterial⁴² and angiogenic properties.^{11,12,43–45} Another study showed that chitosan gel augmented the synthesis levels of collagen, an endogenous antioxidant, and prevented free radical-mediated tissue injury.^{46,47} This endogenous antioxidant may indicate that chitosan prevents the development of necrotic tissue.

Chitosan gel with a higher molecular weight and a higher degree of deacetylation accelerates wound healing. This result also suggests that chitosan accelerates the reformation of connective tissue.⁴⁸

This study also aims to determine the patient's comfort and facilitate the application and removal of the dressings. Because the wounds were treated with paste and gel form dressings, leakage was observed as the paste/gel was diluted by wound exudates at the early time points of the study. The CDHP used in this trial was slightly more solid than the CHG. However, the paste was eventually liquified by exudates. Erythema was also observed during the early time points of the study because most of the wounds were from diabetic patients and might have been caused by inflammation from the prior surgical procedure. Other assessments of signs and symptoms of wound infection, such as localized warmth, pain, tenderness, edema, induration, suggested that the wounds were healthy and stable during the treatment course.

Regarding patient convenience during application and removal of the dressings, this study found that removing the CDHP was slightly more difficult than removing the CHG because it was stickier. Additionally, patients treated with CDHP experienced less pain likely because CDHP has an analgesic effect.^{17,49} Because infection was ruled out, the

Table 3 Comparison between treatment and control groups for the assessments of wound, dressing and granulation tissue, and complications

Assessment	p-Value ^a		
	Time effect	Treatment effect	Time-treatment interaction effect
Wound			
Drainage	< 0.001 ^b	0.767	0.162
Itchiness	0.938	0.162	0.639
Erythema	< 0.001 ^b	0.365	0.368
Localized warmth	0.994	0.655	0.206
Pain/tenderness	0.585	0.162	0.071
Edema/induration	0.926	0.850	0.162
Dressing			
Pain upon removal	0.466	0.019 [‡]	0.893
Exudate	0.066	0.533	0.646
Adherence	0.936	0.682	0.843
Ease of removal	< 0.001 ^b	0.850	0.140
Odor	0.020 ^c	0.231	0.637
Granulation tissue			
Color	< 0.001 ^b	0.487	0.115
Thickness	< 0.001 ^b	0.263	0.940
Consistency	< 0.001 ^b	0.188	0.199
Complications			
Local	< 0.001 ^b	0.354	0.596
Systemic	< 0.001 ^b	0.223	0.439

Abbreviation: ANCOVA, analysis of covariance.

^aRepeated measure of ANCOVA.

^bSignificant at $p < 0.001$.

^cSignificant at $p < 0.05$.

increase in odor over time is likely attributed to the interaction of new granulation tissue, exudate, the dressing time with CDHP and CHG itself.

Regardless of the dressing employed, the color, thickness, and consistency of granulation tissue exhibited a decrease in the mean score. The reason may be subjective assessment by different operators with different perceptions of the color and texture of the granulation tissues. No local or systemic problems were noted during the trial period.

Although no complications were reported, this CDHP should not be used on a patient allergic to chitosan or its derivatives, and it is not recommended for high exudate wounds or infected wounds.

Conclusion

This prospective randomized controlled study showed that a CDHP dressing manufactured from a deacetylated chitosan bioderivative is comparable to CHG in terms of granulation tissue formation and necrotic tissue removal. CDHP caused less pain in the patients during dressing removal. These attributes represent the positive potential of this new dressing made of natural materials.

Authors' Contributions

Nur Azida Mohd Nasir was involved in writing original draft, investigation, data curation, and visualization. Ahmad Sukari Halim contributed to conceptualization, validation, investigation, resources, writing and review, supervision, project administration and acquisition. Arman Zaharil Mat Saad (USM) contributed to project administration, methodology, investigation, writing and review, supervision. Fatimah Mohd Noor (HKL and MOH) and Farrah-Hani Imran (HUKM & MOH) were involved in project administration, investigation, writing and review, and supervision. Mohd Nazri Yusof (IIUM) supervised and wrote and reviewed the manuscript. Ariff Sarifudin (IIUM) did the project administration and wrote and reviewed the manuscript. Nor Sa'adah Bachok was involved in methodology, formal analysis, and writing and review. Zanariah Ujang, Ahamd Hazri Ab Rashid, Kartini Norsal, Kamaruddin Hashim, and Norimah Yusof contributed to validation, resources, writing and review.

Compliance with Ethics Requirements

All procedures followed were in accordance with the ethical standards of the responsible committee on human

experimentation (institutional and national) and with the Helsinki Declaration of 1975, as revised in 2008 (5). Informed consent was obtained from all patients for being included in the study.

All procedures followed were in accordance with the ethical standards of the responsible committee on human experimentation from The Research Ethics Committee (Human) of Universiti Sains Malaysia (FWA Reg. No. 00007718; IRB Reg. No: 00004494) and Research Ethics Committee of Universiti Kebangsaan Malaysia (JEPUKM) (No: FF-285-2012). This study was also approved by Medical Research and Ethic Committee, Ministry of Health Malaysia (NMRR-11-948-10565) and with the Helsinki Declaration of 1975, as revised in 2008 (5). Informed consent was obtained from all patients for being included in the study.

Clinical Trial Registration
NMRR-11-948-10565.

Funding

This work was supported by a grant (No.: (304/PPSP/6150110/s105) from the Ministry of Science, Technology and Innovation (MOSTI) of Malaysia combined with SIRIM to support the pilot production of wound management products from water-soluble chitosan derivatives for pre-clinical and market evaluation. The funding sources played no role in the design, conduct, analysis, interpretation, reporting, writing of the study, or decision to submit for publication.

Conflict of Interest
None declared.

References

- de Alvarenga ES. Characterization and properties of chitosan. In: Elnashar M, ed. *Biotechnology of Biopolymers*. United Kingdom: InTech; 2011:91-108
- Muxika A, Etxabide A, Uranga J, Guerrero P, de la Caba K. Chitosan as a bioactive polymer: processing, properties and applications. *Int J Biol Macromol* 2017;105(Pt 2):1358-1368
- Rinaudo M. Chitin and chitosan—properties and applications. *ChemInform* 2007;63:20-31
- Younes I, Rinaudo M. Chitin and chitosan preparation from marine sources. Structure, properties and applications. *Mar Drugs* 2015;13(03):1133-1174
- Croisier F, Jérôme C. Chitosan-based biomaterials for tissue engineering. *Eur Polym J* 2013;49(04):780-792
- Stricker-Krongrad A-H, Alikhassy Z, Matsangos N, et al. Efficacy of chitosan-based dressing for control of bleeding in excisional wounds. *Eplasty* 2018;18(18):e14-e14
- Yang J, Tian F, Wang Z, Wang Q, Zeng YJ, Chen SQ. Effect of chitosan molecular weight and deacetylation degree on hemostasis. *J Biomed Mater Res B Appl Biomater* 2008;84(01):131-137
- Zhao D, Yu S, Sun B, Gao S, Guo S, Zhao K. Biomedical applications of chitosan and its derivative nanoparticles. *Polymers (Basel)* 2018;10(04):462-478
- Halim AS, Nor FM, Mat Saad AZ, Mohd Nasir NA, Norsaadah B, Ujang Z. Efficacy of chitosan derivative films versus hydrocolloid dressing on superficial wounds. *J Taibah Univ Med Sci* 2018;13(06):512-520
- Huang X, Zhang Y, Zhang X, Xu L, Chen X, Wei S. Influence of radiation crosslinked carboxymethyl-chitosan/gelatin hydrogel on cutaneous wound healing. *Mater Sci Eng C* 2013;33(08):4816-4824
- Burkatovskaya M, Tegos GP, Swietlik E, Demidova TNP, Castano A, Hamblin MR. Use of chitosan bandage to prevent fatal infections developing from highly contaminated wounds in mice. *Biomaterials* 2006;27(22):4157-4164
- Dai T, Tegos GP, Burkatovskaya M, Castano AP, Hamblin MR. Chitosan acetate bandage as a topical antimicrobial dressing for infected burns. *Antimicrob Agents Chemother* 2009;53(02):393-400
- Halim AS, Keong LC, Zainol I, Rashid AHA. Biocompatibility and biodegradation of chitosan and derivatives. In: Sarmiento B, Neves DJ, eds. *Chitosan-Based Systems for Biopharmaceuticals: Delivery, Targeting and Polymer Therapeutics*. Hoboken, NJ: John Wiley & Sons; 2012:57-73
- Lim CK, Halim AS, Lau HY, Ujang Z, Hazri A. In vitro cytotoxicology model of oligo-chitosan and n, o-carboxymethyl chitosan using primary normal human epidermal keratinocyte cultures. *J Appl Biomater Biomech* 2007;5(02):82-87
- Lim CK, Yaacob NS, Ismail Z, Halim AS. In vitro biocompatibility of chitosan porous skin regenerating templates (PSRTs) using primary human skin keratinocytes. *Toxicol In Vitro* 2010;24(03):721-727
- Sukari A, Keong C. Biomedical-grade chitosan in wound management and its biocompatibility in vitro. In: Elnashar M, ed. *Biopolymers*. United Kingdom: InTech; 2010:19-36
- Deng CM, He LZ, Zhao M, Yang D, Liu Y. Biological properties of the chitosan-gelatin sponge wound dressing. *Carbohydr Polym* 2007;69(03):583-589
- Sashiwa H, Kawasaki N, Nakayama A, Muraki E, Yamamoto N, Aiba S. Chemical modification of chitosan. 14:(1) Synthesis of water-soluble chitosan derivatives by simple acetylation. *Biomacromolecules* 2002;3(05):1126-1128
- Chen Y-L, Chou C-C. Factors affecting the susceptibility of staphylococcus aureus ccr 12657 to water soluble lactose chitosan derivative. *Food Microbiol* 2005;22(01):29-35
- Dabiri G, Damstetter E, Phillips T. Choosing a wound dressing based on common wound characteristics. *Adv Wound Care (New Rochelle)* 2016;5(01):32-41
- Rezvani Ghomi E, Khalili S, Nouri Khorasani S, Esmaeeli Neisiany R, Ramakrishna S. Wound dressings: current advances and future directions. *J Appl Polym Sci* 2019;136(27):47738-47738
- Heyer K, Augustin M, Protz K, Herberger K, Spehr C, Rustenbach SJ. Effectiveness of advanced versus conventional wound dressings on healing of chronic wounds: systematic review and meta-analysis. *Dermatology* 2013;226(02):172-184
- Dhivya S, Padma VV, Santhini E. Wound Dressings - A Review. *BioMedicine (Taipei)* 2015;5(04):22
- Gethin G. The importance of continuous wound measuring. *Clinical practice development. Wounds* 2006;2(02):60-68
- Gil J, Natesan S, Li J, et al. A PEGylated fibrin hydrogel-based antimicrobial wound dressing controls infection without impeding wound healing. *Int Wound J* 2017;14(06):1248-1257
- Shi C, Wang C, Liu H, et al. Selection of appropriate wound dressing for various wounds. *Front Bioengineer Biotechnol* 2020;8:182
- Akita S, Akino K, Imaizumi T, et al. The quality of pediatric burn scars is improved by early administration of basic fibroblast growth factor. *J Burn Care Res* 2006;27(03):333-338
- Conti B, Giunchedi P, Genta I, Conte U. The preparation and in vivo evaluation of the wound-healing properties of chitosan microspheres. *STP Pharma Sciences* 2000;10(01):101-104
- Janahmadi Z, Motlagh MR, Zaeri S. Enhancing rat full-thickness skin wounds with a mixed aloe/chitosan gel. *Formosan J Surg* 2019;52(03):84-91

- 30 Lin YH, Lin JH, Li TS, et al. Dressing with epigallocatechin gallate nanoparticles for wound regeneration. *Wound Repair Regen* 2016;24(02):287–301
- 31 Zaid A, Sharshar A, Gaber M, AbdelRahman H. Effect of chitosan gel on wound healing: Experimental study in donkeys. *Alex J Vet Sci* 2017;53(01):63–71
- 32 Mahdavian Delavary B, van der Veer WM, van Egmond M, Niessen FB, Beelen RHJ. Macrophages in skin injury and repair. *Immunobiology* 2011;216(07):753–762
- 33 Martin P. Wound healing—aiming for perfect skin regeneration. *Science* 1997;276(5309):75–81
- 34 Stunova A, Vistejnova L. Dermal fibroblasts—a heterogeneous population with regulatory function in wound healing. *Cytokine Growth Factor Rev* 2018;39:137–150
- 35 Singh S, Young A, McNaught CE. The physiology of wound healing. *Surgery (United Kingdom)* 2017;35(09):473–477
- 36 Thulabandu V, Chen D, Atit RP. Dermal fibroblast in cutaneous development and healing. *Wiley Interdiscip Rev Dev Biol* 2018;7(02):. Doi: 10.1002/wdev.307
- 37 Olczyk P, Mencner Ł, Komosinska-Vassev K. The role of the extracellular matrix components in cutaneous wound healing. *BioMed Res Int* 2014;2014:747584
- 38 Singer AJ, Clark RA. Cutaneous wound healing. *N Engl J Med* 1999; 341(10):738–746
- 39 Gonzalez ACDO, Costa TF, Andrade ZA, Medrado ARAP. Wound healing - a literature review. *An Bras Dermatol* 2016;91(05): 614–620
- 40 Janis JE, Kwon RK, Lalonde DH. A practical guide to wound healing. *Plast Reconstr Surg* 2010;125(06):230e–244e
- 41 Jones V, Grey JE, Harding KG. Wound dressings. *BMJ* 2006;332 (7544):777–780
- 42 Campa-Siqueiros P, Madera-Santana TJ, Ayala-Zavala JF, López-Cervantes J, Castillo-Ortega MM, Herrera-Franco PJ. Nanofibers of gelatin and polyvinyl-alcohol-chitosan for wound dressing application: Fabrication and characterization. *Polímeros* 2020;30(01):
- 43 Ahmed S, Ikram S. Chitosan based scaffolds and their applications in wound healing. *Achieve Life Sci* 2016;10(01):27–37
- 44 López-Cervantes J, Escárcega-Galaz AA, Sánchez-Machado DI, De La Cruz-Mercado JL, Pérez-Gómez LE, Ornelas-Aguirre JM. Characterization and efficacy of chitosan membranes in the treatment of skin ulcers. *Egypt J Basic Applied Sci* 2019;6(01):195–205
- 45 Nguyen TD, Nguyen TT, Ly KL, et al. In vivo study of the antibacterial chitosan/polyvinyl alcohol loaded with silver nanoparticle hydrogel for wound healing applications. *Int J Polym Sci* 2019; 2019:10–10
- 46 Chhabra P, Mehra L, Mittal G, Kumar A. A comparative study on the efficacy of chitosan gel formulation and conventional silver sulfadiazine treatment in healing burn wound injury at molecular level. *Asian J Pharm* 2017;11(03):6–7
- 47 Yang W, Fortunati E, Bertoglio F, et al. Polyvinyl alcohol/chitosan hydrogels with enhanced antioxidant and antibacterial properties induced by lignin nanoparticles. *Carbohydr Polym* 2018; 181:275–284
- 48 Alsarra IA. Chitosan topical gel formulation in the management of burn wounds. *Int J Biol Macromol* 2009;45(01):16–21
- 49 Jayakumar R, Prabakaran M, Nair SV, Tamura H. Novel chitin and chitosan nanofibers in biomedical applications. *Biotechnol Adv* 2010;28(01):142–150