



Imaging Recommendations for Diagnosis, Staging, and Management of Pediatric Solid Tumors

Vasundhara Smriti¹ Akshay D. Baheti¹ Sneha Shah³ Sajid S. Qureshi⁴ Nanadan Shetty⁵
Kunal Gala² Suyash Kulkarni² Abhijit Raut⁶ Veenita Kamble⁶ Girish Chinnaswamy⁷
Maya Prasad⁷ Badira C. P.⁷ Mukta Ramadwar⁸ Suryaveer Singh¹ Anuradha Shukla¹
Hirenkumar Panwala⁹ Arpita Sahu¹ Laskar Siddharth¹⁰ Tejas Kapadia¹¹

¹ Department of Radiodiagnosis and Imaging, Homi Bhabha National Institute, Tata Memorial Hospital, Mumbai, Maharashtra, India

² Department of Intervention Radiology, Homi Bhabha National Institute, Tata Memorial Hospital, Mumbai, Maharashtra, India

³ Department of Nuclear Medicine and molecular imaging, Homi Bhabha National Institute, Tata Memorial Hospital, Mumbai, Maharashtra, India

⁴ Division of Pediatric Surgical Oncology, Department of Surgical Oncology, Homi Bhabha National Institute, Tata Memorial Hospital, Mumbai, Maharashtra, India

⁵ Department of Ophthalmology, Homi Bhabha National Institute, Tata Memorial Hospital, Mumbai, Maharashtra, India

⁶ Department of Radiodiagnosis, Kokilaben Dhirubhai Ambani Hospital, Mumbai, Maharashtra, India

⁷ Department of Pediatric Oncology, Homi Bhabha National Institute, Tata Memorial Hospital, Mumbai, Maharashtra, India

Address for correspondence Tejas Kapadia, DNB, FRCR, MMed, Children's X-ray Department/Academic Unit of Paediatric Radiology, Oxford Road, M13 9WL Manchester, United Kingdom (e-mail: tejasKap@gmail.com).

⁸ Department of Pathology, Homi Bhabha National Institute, Tata Memorial Hospital, Mumbai, Maharashtra, India

⁹ Department of Radiodiagnosis, SRCC Children's Hospital, Mumbai, Maharashtra, India

¹⁰ Department of Radiation Oncology, Homi Bhabha National Institute, Tata Memorial Hospital, Mumbai, Maharashtra, India

¹¹ Children's X-ray Department/Academic Unit of Paediatric Radiology, Royal Manchester Children's Hospital, Manchester, United Kingdom

Ind J Med Paediatr Oncol 2023;44:138–148.

Abstract

Keywords

- ▶ hepatoblastoma
- ▶ imaging guidelines
- ▶ neuroblastoma
- ▶ pediatric oncology
- ▶ pediatric solid tumors
- ▶ Wilm's tumor

Paediatric extra-cranial solid tumours are one of the common causes for paediatric malignancies. Lack of appropriate imaging at presentation, staging and for follow-up is a major challenge for paediatric solid tumours. We have reviewed the paediatric solid tumour imaging protocols suggested by the major oncological societies/groups around the world (mainly the SIOP – Society International Pediatric Oncology, and the COG – Children's Oncology Group). We have adapted some of those protocols to develop imaging recommendations for the diagnosis, staging and management of extra-cranial solid tumours based on the treatment protocols followed in India.

Childhood cancer accounts for nearly 1% of all cancers diagnosed worldwide across all age groups.^{1,2} Great improvement has been made in the last few decades in the treatment of childhood cancers, achieving successful treatment in up to 80% of cases.¹ This dramatic success is a result of decades of collaborative effort by various study groups across the globe. Collaborative consensus guidelines have been developed by these groups for imaging and management of pediatric tumors.

This article aims to provide imaging guidelines for the common pediatric extracranial solid tumors based on the

recommendations of various pediatric groups across the world and treatment protocols followed in India.

Clinical Presentation

Pediatric tumors present with nonspecific symptoms and requires high index of suspicion to investigate for the possibility of cancer. Pediatric abdominal malignancies present most commonly as abdominal distension or a palpable abdominal mass. It may be an incidentally detected mass or present with abdominal pain, hematuria, features of

DOI <https://doi.org/10.1055/s-0042-1759507>.
ISSN 0971-5851.

© 2023. The Author(s).

This is an open access article published by Thieme under the terms of the Creative Commons Attribution License, permitting unrestricted use, distribution, and reproduction so long as the original work is properly cited. (<https://creativecommons.org/licenses/by/4.0/>)

Thieme Medical and Scientific Publishers Pvt. Ltd., A-12, 2nd Floor, Sector 2, Noida-201301 UP, India

bowel or bladder obstruction, or may present with constitutional symptoms such as fatigue, loss of appetite or fever. Renal and suprarenal tumors may present with hypertension or paraneoplastic symptoms such as opsoclonus-myoclonus.^{3,4} Occasionally, they may present with precocious puberty/virilization, more so in adreno-cortical carcinomas, and rarely in hepatoblastoma and germ cell tumors.⁵

Soft tissue tumors may present with swelling or bone pain. Spinal extension of the tumor like in neuroblastoma or germ cell tumors may cause focal neurological deficits or bowel/bladder related symptoms.

Imaging Guidelines for Pediatric Abdominal Masses

Ultrasound

Ultrasound is the ideal screening tool in cases of suspected abdominal mass in children as there is no ionizing radiation or sedation involved.

Role of ultrasound is to confirm the presence of mass and determine its organ of origin. Further investigations would be based on the ultrasound findings (► Fig. 1).

Relook ultrasound after cross sectional study, along with Doppler might be useful to evaluate subtle vascular invasion or thrombosis in cases of doubt, e.g., tumor thrombus in hepatoblastoma or Wilm's tumor. It is a problem solving tool in cases of complex findings on cross-sectional imaging, e.g.,

suspected focal lesions in hepatoblastomas and lesions in contralateral kidney in cases of Wilm's tumor. In cases of suspected tumor rupture, ultrasound has a role in evaluating the tumor margin integrity and detecting echoes in the abdominal free fluid. USG-guided biopsy of solid pediatric tumors is a widely acceptable technique and again avoids unnecessary radiation (compared with CT scan).

Magnetic Resonance Imaging

MRI is the modality of choice for pediatric abdominal masses.⁶ It provides better soft tissue contrast and does not expose to any ionizing radiation. However, sedation risk should be considered against radiation risk and CT scan can be performed for cases with contraindication to MRI or difficult anesthesia or no availability.⁷ MRI field strength of 1.5 to 3 T and acquisition with the smallest suitable coil (e.g., head coil or flexible phased-array body coil) is recommended with breath holding and gated sequences. Study may be performed under sedation or general anesthesia if needed, depending on the age and weight of child.

CT Scan

A contrast-enhanced CT scan for hepatic or renal masses is the alternative imaging modality to MRI as per institute preference, or if MRI is contraindicated or anesthesia is not available. Care should be taken to use the lowest possible

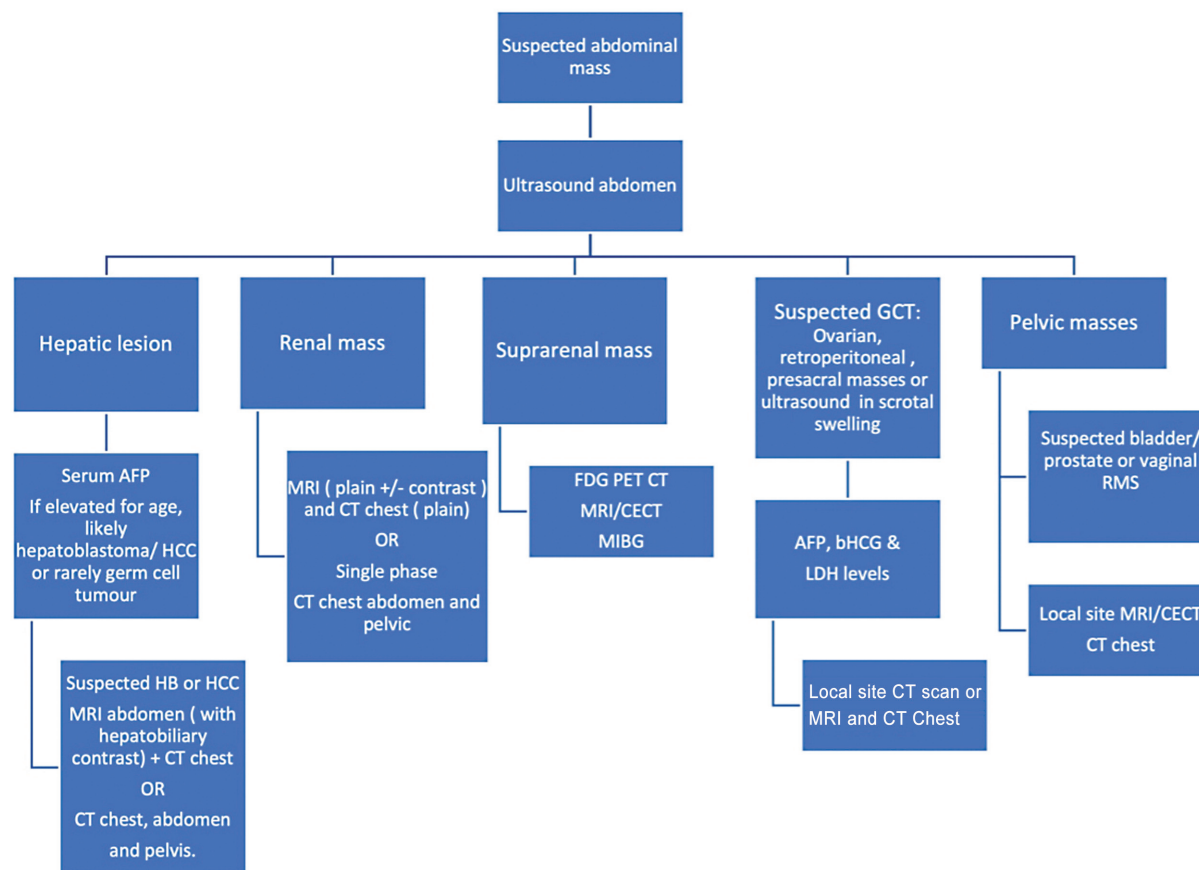


Fig. 1 Diagnostic pathways based on ultrasound findings.

radiation dose with adequate image quality. Single-phase imaging is recommended if sufficient to provide necessary information. Just a non-contrast CT scan is usually avoided. The imaging protocols are further tailored as per the organ of origin of the mass and will be discussed subsequently.

A CT chest is a mandatory diagnostic procedure for all patients of liver and renal masses and protocol is described in the respective sections.

Pediatric Liver Tumors

Pediatric liver tumors are rare and ~two-thirds of them are malignant, hepatoblastoma being the most common, (~37%) followed by hepatocellular carcinoma (HCC; 21%), and sarcoma (8%).⁸ Benign tumors such as hemangioma, hemangioendothelioma, focal nodular hyperplasia, and mesenchymal hamartomas form the rest of the spectrum.

Risk Factors, Etiopathogenesis, and Clinical Presentation

Hepatoblastoma are mostly sporadic, but may be associated with genetic abnormalities and familial cancer syndromes, such as the Beckwith–Wiedemann syndrome and familial adenomatous polyposis.⁹ Premature birth and very low birth weight are known to be associated with increased incidence of hepatoblastoma.¹⁰

The most common presenting symptom is abdominal distension or a palpable abdominal mass. It may be associated with non-specific symptoms such as abdominal discomfort, fatigue, and loss of appetite, and the child may appear pale due to anemia, especially in HCC and liver sarcomas

Imaging Guidelines for Pediatric Liver Lesions

Ultrasonography

USG is the ideal screening modality for suspected liver mass/abdominal lump.^{6,11}

Contrast-enhanced USG can be performed for the initial assessment of lesion to help classify as benign or malignant. USG may be useful to evaluate hepatic veins, IVC, portal vein, and focal liver lesions and for suspected cases of tumor rupture.

Magnetic Resonance Imaging

Both MRI and CECT are the modality of choice for pediatric liver masses such as hepatoblastoma and HCC.

Respiratory gated sequences should be used. Unlike adults, breath holding is usually not possible for hepatoblastoma evaluation as these scans are generally performed under sedation or GA. The recommended MRI sequences are presented in ►Table 1.

MRI with contrast is also the modality of choice for post chemotherapy response evaluation, detection of metastatic liver lesions in non-hepatic primary tumor and in the follow up of patient with resected tumor.

CT Scan

Contrast-enhanced CT scan is the alternative imaging modality of choice as per the institute preference, or if there is contraindication for MRI, anesthesia is not available for MRI or separate anesthesia is needed for CT chest and MRI.

A single-sequence baseline CECT abdomen can be performed that includes both arterial and venous phases (►Table 2). Alternatively, dual-phase CT with late arterial phase for abdomen and portal-venous phase for the

Table 1 Imaging recommendations for pediatric abdominal tumors

MRI sequence	Plane	Thickness	Sequence coverage
T2 STIR	Coronal	5 mm	Above diaphragm to below iliac crests
T1 TSE FS	Coronal	2 mm	Above diaphragm to below iliac crests
T1 TSE FS	Axial	2 mm	Above diaphragm to below iliac crests
T2W volume sequence (SPACE/VISTA)	Coronal	0.9 mm–1.1 mm	Above diaphragm to below iliac crests
T2W STIR	Axial	5 mm	To include area of interest
T1W IP and OP	Axial	5 mm	To include area of interest
DWI/ADC (b = 0,100,500,1000)	Axial	6 mm	To include area of interest
Post-contrast			
T1W FS immediate (VIBE)	Axial	2 mm	Above diaphragm to below iliac crests
T1W FS 30 s arterial (VIBE)	Axial	2 mm	Above diaphragm to below iliac crests
T1W FS 60 s venous (VIBE)	Axial	2 mm	Above diaphragm to below iliac crests
T1W FS 2 min (VIBE)	Axial	2 mm	Above diaphragm to below iliac crests
T1W FS 5 min (VIBE)	Axial	2 mm	Above diaphragm to below iliac crests
T1W FS 10 min (VIBE)	Axial	2 mm	Above diaphragm to below iliac crests
T1W TSE FS	Axial	5 mm	Above diaphragm to below iliac crests
T1W FS 20 min (VIBE)	Coronal	2 mm	Above diaphragm to below iliac crests
T1W FS 25 min (vibe)	Axial	2 mm	Above diaphragm to below iliac crests

Note: Please note the number of slices, field of view, and TR/TE for the sequences will be variable depending on if it is a young child/old child

Table 2 Single phase CECT abdomen protocol for pediatric abdominal tumors

Imaging recommendation	Protocol	Contrast dose	Reconstructions
CT Abdomen ± Chest	-To include lung apices to lesser trochanter -Inject two-thirds of contrast bolus @ 0.5 mL per sec and one-third @ 1 mL per second -Scan after 10 seconds post injection Slice thickness – 0.6 mm Increment – 0.6 mm Pitch – 0	2 mL/kg (dose recommendations for Iohexol 300)*	Lung window: - Axial 1 mm - Cor 3 mm - Sag 3 mm Soft tissue window (chest and abdomen): - Axial 1 mm - Cor 3 mm - Sag 3 mm Bone window: - Cor 2 mm - Sag 2 mm

*Contrast type and dose used can be variable as per local department policies.

abdomen and pelvis should be performed in the evaluation of suspected hepatoblastoma. A triphasic CT with an additional delayed phase can be performed for suspected HCC. A CT scan of the chest is recommended in all patients of hepatoblastoma for the evaluation of lung metastasis.

Intervention

Recommendations for biopsy: Serum α fetoprotein (AFP) level is the most important clinical tumor marker for hepatoblastoma and is elevated in 90% of cases. Biopsy is not mandatory in cases with elevated serum AFP levels, and when imaging features are in favor of hepatoblastoma. In cases with uncertain diagnosis, low AFP levels or age of the patient <6 month or >3 years, a biopsy can be performed after a multidisciplinary discussion.

Reporting

The PRETEXT staging system should be used as a consensus classification for pre-treatment extent of pediatric liver tumors. Each PRETEXT annotation factor should be evaluated during reporting as the presence of any of the annotation factors upgrades the tumor from standard risk to high risk and can change the chemotherapy regime. The imaging reassessed after chemotherapy should be classified using the POST-TEXT staging system.¹¹ The future liver remnant (FLR) should be considered before surgery to avoid decompensation in the post-operative period.

Management

Hepatoblastoma: The tumor should be classified as high risk or standard risk based on the risk stratification system followed by the institution. Upfront surgery can be performed in cases such as PRETEXT 1 and small PRETEXT 2 tumors. Neoadjuvant chemotherapy is needed in cases with high tumor burden followed by complete surgical resection.

Liver transplant is indicated in the PRETEXT IV multifocal/solitary POST-TEXT IV/portal vein involvement/all three hepatic veins involved/central hepatoblastomas with insufficient tumor regression/unsuccesful resection/recurrence cases.¹²

HCC: Only 20% of pediatric HCC are upfront resectable. Patients with upfront unresectable HCC are treated with

neoadjuvant chemotherapy on the same lines as hepatoblastoma and reassessed for surgery.

Pediatric Renal Tumors

Introduction and Epidemiology

Wilm's tumor is by far the most common renal tumor of childhood, comprising up to 90% of all renal masses in children.¹³ Children between the age of 1 and 5 years are the most commonly affected, and the peak incidence is at 3 years. Wilm's tumor is extremely uncommon after the age of 15 years. Bilateral Wilm's tumor are seen in up to 5 to 8% of patients.¹⁴

Risk Factors, Etiopathogenesis, and Clinical Presentation

Majority of the Wilms tumor are sporadic, but 10% may be associated with genetic abnormalities such as aniridia, genitourinary defects, hemihypertrophy or syndromes such as WAGR (Wilm's tumor, aniridia, genitourinary abnormalities and mental retardation/intellectual disability) syndrome, Denys-Drash syndrome, and Beckwith-Wiedemann. Mutation of the Wilms Tumor 1 gene (*WT1*), on the short arm of chromosome 11 (11p13) are associated with congenital anomalies.¹⁵

Imaging Guidelines for Pediatric Renal Lesion

USG is usually the first imaging modality that confirms the renal origin of the suspected abdominal mass. Cross-sectional imaging (CT/MRI) is needed for further characterization and determination of the extent as well as for local staging (→ **Supplementary Table S1**, available online only). Evaluating the other kidney is of paramount importance as it upstages the disease and also rules out congenital anomalies that affect the management. USG Doppler in addition to cross-sectional imaging may help in the evaluation of IVC and renal vein thrombus.

Cross-sectional study for further evaluation (→ **Supplementary Table S1**, available online only). As per the institute, preference could be

1. MRI of the abdomen with CT scan of the chest
OR
2. Contrast-enhanced CT scan of the chest, abdomen, and pelvis

MRI Abdomen

Contrast MRI of the abdomen is preferred on a MRI field strength of 1.5 or 3 Tesla. Recommended MRI sequences (check the general abdominal MRI protocol) are large FOV STIR coronal and axial sequences for an overview of the abdomen. T2 non-fat saturated high-resolution sequence for both the kidneys, the name for it differs between different vendors (SPACE/VISTA). Pre-contrast axial T1W sequence. Diffusion-weighted images should be included with at least three b-values ($b=0$, $b=500$, and $b=1000$). Post contrast sequences should include multiple contrast phases to cover arterial, venous, and delayed phases. MRI is the modality of choice to identify nephrogenic rests, which are better appreciated on post contrast images in the background of enhancing parenchyma and also seen well on DWI as areas of restricted diffusion.

CT Scan

CT scan of the abdomen and pelvis is still the preferred modality in many institutes. A single post contrast acquisition in the portal-venous phase should be performed for tumor assessment. CT scan of the chest is also mandatory. A plain CT chest is sufficient if MRI of the abdomen is performed; however, contrast CT chest is recommended if an IVC tumor thrombus is suspected. However, if contrast-enhanced CT scan of the abdomen and pelvis is the cross-sectional diagnostic procedure performed, a contrast-enhanced CT chest should be performed in the same setting.

Management of Pediatric Renal Tumors

The management of pediatric malignant renal masses and timing of surgery varies in different groups. In India, the renal tumor size is usually large at presentation. A customized approach is recommended based on the baseline imaging considering the risk of rupture or incomplete resection if upfront surgery is performed as described in **Fig. 2**.¹⁶ Biopsy is recommended before starting chemotherapy if upfront surgery is not possible.

Radical nephroureterectomy and lymph node sampling is the surgical procedure of choice¹⁷ Clearance of the thrombus, if present, is performed and either cavotomy or partial cavectomy may be required depending on the extent of tumor thrombus.¹⁸ As Wilm's tumor is highly chemo-sensitive, post-operative chemotherapy is recommended for every patient, and the dosage regimen is decided based on the histology and tumor stage (**Supplementary Table S2**, available online only). Except for stage 1 and 2 tumors with favorable histology, post-operative radiotherapy is indicated for primary tumor bed and metastatic disease.^{16,19}

Upfront surgery is contraindicated in bilateral renal disease and in cases with solitary or horseshoe kidney.^{16,20} For patients with bilateral Wilm's tumors, neoadjuvant chemotherapy is initiated, followed by delayed surgery in the form of bilateral partial nephrectomy or total nephrectomy on the worse side and partial nephrectomy on the opposite side. Patients with tumor spillage/rupture, or

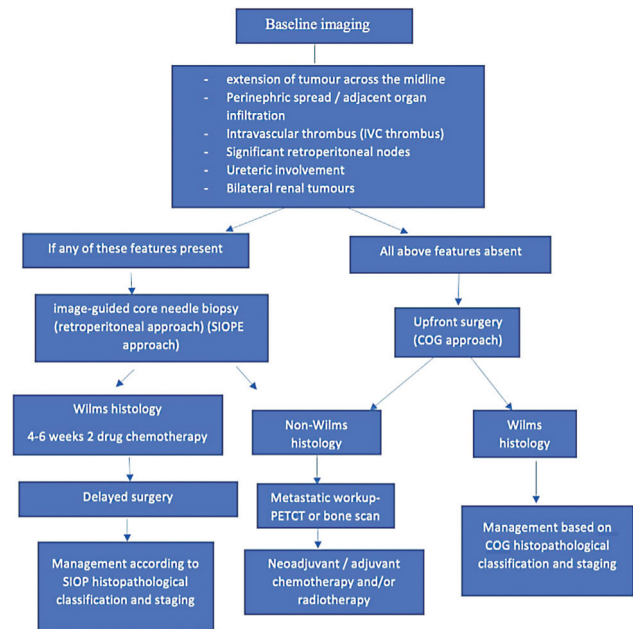


Fig. 2 Guidelines for the imaging and management of pediatric renal tumors.

regional lymph node metastasis are upstaged to stage III, and should receive abdominal radiotherapy and appropriate chemotherapy.^{19,21}

Follow-up of patients: Done with USG of the abdomen and pelvis along with chest radiograph (**Supplementary Table S2**, available online only).¹¹

Extracranial Germ Cell Tumors (Pediatric)

Malignant germ cell tumors (GCT) account for 3% of pediatric cancer with bimodal age distribution.^{22,23} Sites are divided as intracranial or extracranial, the later as gonadal and extragonadal. The extragonadal sites comprise sacrococcygeal, mediastinal, retroperitoneal, and other para-axial locations. Histologically, the germ cell tumors are classified as germinoma (dysgerminoma and seminoma), and non-germinomatous tumors such as endodermal sinus (yolk sac tumor), embryonal carcinoma and choriocarcinoma, or mixed type where more than one histology co-exist.

Risk Factors, Etiopathogenesis, and Clinical Presentation

Cryptorchidism and gonadal dysgenesis are associated with an increased risk of the development of gonadal GCT.²⁴ Some GCTs are more frequently seen with sex-linked chromosomal disorders; mediastinal GCT in Klinefelter's syndrome, germinomas in Turner's syndrome, and Swyer's syndrome.

Clinical features are variable and the presentation depends on the site of the extracranial GCT.²⁴ Sacrococcygeal GCT usually present as an external palpable mass in perinatal period. Testicular GCT may present as a painless swelling. Ovarian and abdominal or retroperitoneal GCT present with gradual abdominal distension and discomfort. Rarely ovarian GCT may present as acute abdomen due to torsion, rupture, or intralesional hemorrhage. Mediastinal GCT causes

symptoms due to mass effects such as airway compression, superior vena cava obstruction, or heart failure.

Diagnostic Work-up of Germ Cell Tumors

Tumor markers important for the diagnosis of GCT are α fetoprotein (aFP) secreted by yolk sac tumors and β human chorionic gonadotropin (b-hCG) secreted by choriocarcinoma. LDH is a non-specific marker of tumor burden.²⁵ The imaging recommended at baseline and for follow-up is summarized in **– Supplementary Table S3**, available online only.

USG

USG is the modality of choice for the evaluation of suspected testicular pathology. Trans-scrotal USG using a linear high-frequency probe has more than 90% sensitivity and specificity in detection of testicular malignancies. In adjunct to gray scale and color Doppler, elastography provides an added value.²⁶ USG is usually the initial imaging modality for abdominal and pelvic GCT.

Cross-sectional Imaging

Primary site evaluation can be performed with CT scan or MRI based on the site involved and local institutional policy.

CT Scan

Contrast-enhanced single venous phase CT scan of the chest, abdomen, and pelvis is suggested for initial staging of abdominal GCT.^{25,27} It is a sensitive modality for assessing retroperitoneal nodes. Noncontrast CT scan of the chest is recommended for the evaluation of lung metastasis

MRI Scan

MRI is used as an adjunct tool to USG, in cases of testicular mass with diagnostic dilemma on ultrasound. MRI abdomen and pelvis may be used instead of CT for both baseline evaluation and post treatment reassessment. MRI may particularly be used for initial workup in patients with deranged renal profile or in cases with suspicious intraspinal extension.

Contrast CT or MRI of the head should be performed if brain metastasis is suspected and in all patients with metastatic choriocarcinoma.

Recommendations for Biopsy: Biopsy is performed if AFP is not elevated and neoadjuvant chemotherapy is planned. Biopsy is not recommended for upfront resection or in testicular tumors where high orchidectomy is planned. Biopsy is performed when tumor markers are normal and/or there is a clinicoradiological mismatch.²⁷

Management

A multi-modality customized strategy is needed for the treatment of GCT depending on the site, stage, and tumor

biology. The COG staging for testicular, ovarian, and extragonadal germ cell tumors is recommended. GCTs are stratified into low-, intermediate-, and high-risk categories.

Surgery is the mainstay of management and first treatment option if feasible. A biopsy with neoadjuvant chemotherapy is otherwise recommended.

Neuroblastoma

Neuroblastoma (NB) is a neuroectodermal tumor arising from the sympathetic ganglion cells and is the commonest extracranial solid tumor in children.²⁸ This tumor commonly arises in the adrenal gland and can also occur at multiple locations including the extraadrenal abdomen, thorax, neck, and pelvis along the course of sympathetic nervous system.²⁹ Patients usually present with symptoms caused due to its mass effect on the surrounding organs, mostly presenting as a large abdominal mass.

Imaging Guidelines and Principles of Management

The treatment and outcome of NB are dependent on risk assessment and stage of the disease. The international Neuroblastoma Risk Group (INRG) task force puts forth a preoperative staging called International Neuroblastoma Risk Group Staging System (INRGSS), which is dependent on cross-sectional imaging (CECT or MRI) of the tumor site using Imaging defined risk factors (IDRF) (**– Supplementary Tables S4 and S5**, available online only). A metastatic workup includes an iodine-labeled MIBG scan (radionuclide 123/124 or 131 iodine is used; however, in India, only 131 iodine is available) to look for sites of metastatic disease, especially bone lesions, a bone marrow biopsy, and aspirate for marrow disease.^{29,30} The IDRFs on cross-sectional imaging help categorize the patients into L1 (non-infiltrative/operable tumor) or L2 (infiltrative or disease-encasing important structures) (**– Supplementary Table S6**, available online only).²⁹ Combining the outcome of these tests with other pathological and molecular criteria, and age of the patient help make decisions for management plan.

Data are emerging for the potential role of FDG PET-CT in the evaluation of neuroblastoma. In the Indian set-up, due to the unavailability of I-123 for MIBG scans, I-131 MIBG is performed. For the MIBG non-avid NB lesions, PET-CT is preferred modality for metastatic work-up. The utility of PET-CT for all NB patients work-up is debatable as there are some studies that have shown higher sensitivity of PET-CT compared with I-123 MIBG scans for stage 1 or 2 disease, but MIBG has performed better for higher stages of NB.³¹

Patients are treated with surgery alone in L1, low-risk disease or initially with chemotherapy followed by surgery, which could be a complete resection or an incomplete resection in patients with intermediate risk disease (patients having an unfavorable histology or infantile age group with metastasis receiving additional cycles of chemotherapy). Patients with high-risk neuroblastoma undergo bone marrow transplant after initial intensive chemotherapy and

surgery followed by radiotherapy and administration of differentiation agents and immunotherapy if available.

MRI/CT and MIBG scan along with bone marrow biopsy are done pre-surgically to look for residual disease, as this may alter the management of the disease.

Rhabdomyosarcoma

Introduction

Rhabdomyosarcoma (RMS) is the most common childhood soft tissue sarcoma and accounts for 3 to 5% of all pediatric malignancies. It is the third most common soft tissue tumor in children after neuroblastoma and Wilm's tumor.³² RMS in children has two main histological subtypes, embryonal and alveolar. Further refinement of prognosis has occurred over the years with the incorporation of molecular fusion status for PAX 3/7-FOXO1 with fusion-positive tumors faring worse than fusion-negative ones. The embryonal type (nearly 75% of RMS cases), which is mostly fusion negative, is more common in younger children (<10 years of age), has better prognosis, and occurs in the head and neck region, followed by genitourinary tract and retroperitoneum. The alveolar variant, which is usually fusion positive, is the more aggressive type (~16% of RMS cases) and commonly occurs in the trunk and extremities.

Risk Factors and Etiopathogenesis and Clinical Presentation

There are no clear risk factors for RMS. Higher risk of developing RMS has been shown in children who have the following rare, inherited conditions: Li-Fraumeni syndrome, Beckwith-Wiedemann syndrome, neurofibromatosis, DICER 1, cardio-facio-cutaneous syndrome, Costello syndrome.³³

There are no clear signs or symptoms for RMS and the presentation is largely dependent on the location of the lesion. RMS is known to have metastasis at presentation in 15 to 20% of cases, and the common sites for metastasis are lungs, bone marrow, bones, and distant lymph nodes.³⁴ Tumor biopsy is routinely performed as part of the main tumor work-up and at least one bone marrow aspirate and

trephine performed for evaluating bone marrow involvement. The metastatic work-up includes lymph node biopsy, bilateral bone marrow aspirates, and CSF examination when LN, bone marrow, or neurological metastasis is suspected.

The RMS cases are risk stratified into low-risk, intermediate-risk, high-risk or very high-risk category based on age, tumor size, regional nodal status, tumor site, histology, PAX-FOXO1 status, and Intergroup Rhabdomyosarcoma Study (IRS) post-surgical stage. Treatment for RMS cases is multi-modality and in low/intermediate risk categories, the approach is chemotherapy in combination with radiotherapy and/or surgery with additional maintenance chemotherapy in high risk cases. Localized radiotherapy for metastatic disease can be used. In spite of recent advancements, multi-center trials and significantly improved treatment protocols, the 5-year overall survival for pediatric RMS stands at 75% for cases with localized disease, dropping to just 30% for cases with metastatic disease.^{35,36}

Imaging Guidelines

Imaging the primary tumor should include loco-regional lymph node sites and also cover the regional extent of the tumor including the neuro-vascular structures. Evaluation for metastasis should include chest CT scan and bone scan or PET-CT for complete staging. Complete imaging and staging should be performed before biopsy is performed. All the imaging should be planned and reported by a pediatric radiologist with oncology experience and a nuclear medicine physician for hybrid imaging. Imaging reports should clearly describe the lesion location, size, lesion characteristics, extent and status of surrounding structures including regional lymph nodes.

MRI

MRI is the imaging modality of choice for both initial imaging of the tumor and subsequent follow-up examinations (► **Table 3**). The MRI protocol should include DWI/ADC and post-contrast imaging. Lesions with diffusion restriction and lower ADC values have shown to correlate with poor outcome and higher incidence of recurrence.³⁷ Post-contrast

Table 3 MRI imaging protocol recommendations for pediatric rhabdomyosarcoma

MRI sequence	Plane	Thickness	Sequence coverage
T2 STIR	Sag	5 mm	Pelvic lesion only (below liver to symphysis pubis)
T1 TSE	Axial	5 mm	Above diaphragm to below symphysis pubis
T1 TSE FS	Axial	2 mm	Above diaphragm to below symphysis pubis
T2W volume sequence (SPACE/VISTA)	Coronal	0.9 mm–1.1 mm	Above diaphragm to below symphysis pubis
T2W STIR	Axial	5 mm	To include area of interest
DWI/ADC (b = 0,100,500,1000)	Axial	6 mm	To include area of interest
Post-contrast			
T1W FS (VIBE) 1	Axial	2 mm	Above diaphragm to below symphysis pubis
T1W FS (VIBE)	Coronal/Sag	2 mm	Above diaphragm to below symphysis pubis
T1W FS (VIBE) 2	Axial	2 mm	Above diaphragm to below symphysis pubis

Note: Please note, the number of slices, field of view and TR/TE for the sequences will be variable depending on if it is a young child/old child.

tumor enhancement helps to map tumor response and also study neurovascular spread (for head and neck RMS). The MRI field of view should include areas of loco-regional lymph nodes.

CT Scan

Only in circumstances where MRI cannot be performed for the primary tumor site, a contrast CT scan (ideally single phase) should be done (→ **Table 2**). A single-phase contrast CT scan is sufficient to evaluate both the soft tissue and bones. Intravenous contrast medium should be given at a dose of 2 mL/kg patient body weight followed by saline bolus, and images should be acquired at 65 to 70 seconds post-injection. CT can be done in addition to MRI to evaluate for skull base involvement or to look for bone erosions. Metastatic work-up should include a good inspiratory phase chest CT scan with 1 mm thin lung window reconstructions (non-contrast scan to be done when paired with PET-CT).

PET-CT/PET-MRI

A hybrid nuclear scan is mandatory for complete RMS staging before commencing treatment. Smaller lesions, nodal metastasis, and bone metastasis are better seen on PET-CT/PET-MRI compared with conventional scans. A modified Deauville score can be used to for visual assessment of suspicious lymph nodes comparing the activity with background activity in the adjacent normal tissue. Lymph nodes < 10 mm are considered non-pathological and > 15 mm are pathological. Lymph nodes < 15 mm with FDG activity should be considered suspicious. Although not validated, PERCIST (PET response criteria in solid tumors) can be used for quantitative measurements using standardized uptake values (SUV).³⁸ In future, whole body MRI with DWI/ADC sequence can prove to be a promising alternative to PET scans; however, it is still a subject of research and widespread adaptability for pediatric MRI protocols.

Response Assessment

Timing

The current EBM guidelines³⁹ and the EpSSG protocols use multidrug chemotherapy. Induction chemotherapy is combined with radiotherapy and/or surgery with additional maintenance therapy extending for 6 months to 24 months depending on randomized group for high-risk and very high-risk groups (according to early results from the ongoing FaR-RMS trial). The timing for follow-up imaging is summarized in → **Supplementary Table S7**, available online only adapted from the EpSSG, ESPR oncology taskforce and CWS recommendations.³⁷ The IRS-IV trial recommendations by the intergroup Rhabdomyosarcoma Study Group (IRSG) are widely followed. They recommend neoadjuvant chemotherapy, response assessment at 10 to 12 weeks, and local treatment with surgery if possible and radiotherapy to the primary as well as to the metastasis depending on the site.^{40,41}

Retinoblastoma

Retinoblastoma is the most prevalent intraocular tumor in children and represents ~2.5 to 4% of all pediatric cancers.^{42,43} According to the National Cancer Registry program, the pooled crude incidence rate of retinoblastoma in 0 to 14 age group is 3.5 per million and the pooled age standardized incidence rate is ~4.4 per million.⁴⁴ The disease is curable if confined to the globe.

Types, Risk Factors, Etiopathogenesis, and Clinical Presentation

Retinoblastoma clinically presents in two distinct forms:

- (1) Bilateral form (25% cases)-Caused by germline mutations of the *RB1* gene, localized on chromosome 13q14, and presents as congenital disease or early in life by 1 year. It could be hereditary or occur de novo.⁴³
- (2) Unilateral form (75% cases)-Random *Rb* gene mutation is the causative factor for most unilateral forms; however, 10% of cases are due to germline mutation. The mean age of presentation is ~2 years.⁴³
- (3) Trilateral retinoblastoma-Bilateral retinoblastoma with an asynchronous intracranial tumor, usually in the pineal region (pineoblastoma) and rarely in the suprasellar or parasellar location.

Clinical presentation: The common presentation is leukocoria. Other presentations are squint, nystagmus, change in visual status or loss of vision, and proptosis in extraocular disease. Advanced presentations with proptosis and bone marrow and CNS involvement are more commonly seen in developing countries.

Guidelines for Retinoblastoma Evaluation

Diagnosis is established by an ophthalmologist following examination under anesthesia and intratumoral calcifications detected in the lesion (usually by ultrasound).

Clinical examination:

1. Ocular examination in the clinic: For visual acuity assessment, anterior segment and posterior segment examination.
2. Examination under general anesthesia (EUA): for detailed evaluation including tumor laterality, number, location, size and vitreous/subretinal seedings. Anterior segment is also evaluated using a hand held slit lamp. Intraocular pressure is recorded using a tonometer.

Ultrasound

B-scan is performed using a 7.5 to 10 MHz high-frequency linear probe. Study can be performed without anesthesia or under sedation. Color Doppler may assist in differentiating tumor from echogenic effusions and persistent hyperplastic primary vitreous. Ultrasound is user dependent and this is the major disadvantage in response assessment.

Table 4 MRI imaging protocol for retinoblastoma

MRI sequence	Plane	Thickness	Sequence coverage
Essential sequences			
T2 W FSE/TSE (TE \geq 120 ms) Fat-saturated	Axial	\leq 2 mm	Both orbits
T1 W TSE/FSE	Axial	\leq 2 mm	Both orbits
T2W TSE/FSE	Sagittal oblique	\leq 2 mm	Both orbits
T2W fat-saturated/STIR	Coronal	\leq 2 mm	Both orbits
Post contrast (PC)			
PC T1W SE FS/nonFS	Axial	\leq 2 mm	Both orbits
PC T1W SE FS/nonFS	Coronal	\leq 2 mm	Both orbits
PC T1W 2D or (3D GRE \leq 1 mm)	Axial	\leq 3 mm	Brain
Optional sequences			
3D T2W (CISS/SPACE/FIESTA/ DRIVE)	Axial	<1 mm isotropic voxel	Both orbits
PC whole brain T1W 3D MPR	Axial	<1 mm	
PC whole Spine T1W	Sagittal	<3 mm	Required if there is optic nerve meningeal sheath involvement

Magnetic Resonance Imaging

High-resolution MRI of the orbit and screening of the brain is the examination of choice for pre-treatment assessment of the tumor (**►Table 4**). It detects the extent of disease (mainly involvement of the optic nerve and extra-scleral disease), its size, presence of meningeal spread, or associated intracranial primitive neuroectodermal tumor (trilateral retinoblastoma).

MRI field strength of 3 Tesla with head coil or 1.5 with dedicated orbit/small surface coil is recommended. Study should be performed under sedation or general anesthesia (GA) to obtain high-resolution images without eye movements.

To obtain high spatial resolution images, section thickness of \leq 2 mm and in-plane pixel size of \leq 0.5×0.5 mm is recommended. The image in axial and sagittal oblique plane should be aligned with the distal 1 cm end of the optic nerve (just posterior to the lamina cribrosa).

CT scan: CT is not a preferred modality due to the risk of ionizing radiation especially in cases with germline mutation. It can be used as an optional modality to detect calcification if there is diagnostic dilemma or MRI is not available.

Staging: CSF and bone marrow studies should be performed in extraocular disease/ optic nerve involvement.

Management and Follow-up Imaging (F/U)

Management and F/U imaging is based on staging.⁴⁵

Intra-ocular Retinoblastoma Grouping/Staging

- Group A: Small tumors (<3 mm) confined to the retina and located at least 3 mm from foveola and 1.5 mm from optic nerve
- Group B: All tumors confined to retina and not in group A; subretinal fluid < 3 mm from tumor base
- Group C: Local vitreous or subretinal seeding (<3 mm from tumor)
- Group D: Diffuse vitreous or subretinal seeding (>3 mm from tumor)
- Group E: Presence of at least one of the poor prognosis factors (anterior segment/ciliary body involvement; tumor involving > two-thirds of the globe; iris neo-vascularization; glaucoma; opaque media from hemorrhage; phthisis bulbi; aseptic orbital cellulitis due to tumor necrosis)

Treatment Guidelines for Retinoblastoma

For bilateral Rb, systemic therapy along with focal treatment (trans-scleral cryotherapy, diode laser transpupillary thermotherapy) is the initial treatment. In case of poor or inadequate response, targeted chemotherapy such as intra-arterial chemotherapy and/or intravitreal chemotherapy is utilized.

For unilateral intraocular Rb, enucleation is the choice in Group E tumors. Intraarterial chemotherapy (ophthalmic artery chemo-infusion) is preferred, especially for group D and select group E eyes. Intravitreal chemotherapy is delivered in persistent vitreous seeds. Intravenous chemotherapy is administered in Groups C and D and in select Group E eyes (if buphthalmos is present) where upfront intra-arterial

therapy is unavailable. Patients who have upfront enucleation also receive chemotherapy if histopathological risk factors are present in the resected specimens.

Extraocular disease is treated with chemotherapy, surgery (enucleation/exenteration) based on the response and radiotherapy. Patients with bone marrow involvement require high-dose chemotherapy with stem cell rescue for cure.

Imaging wise, in case of both unilateral and bilateral Rb, an ocular USG, MRI, and EUA is recommended at baseline.¹⁹ Follow-up is done with USG and EUA, and for extra-ocular disease, MRI is also performed.

Note

The article is not under consideration for publication elsewhere. Each author participated sufficiently for the work to be submitted. Publication is approved by all authors.

Conflict of Interest

None declared.

References

- Bhakta N, Force LM, Allemani C, et al. Childhood cancer burden: a review of global estimates. *Lancet Oncol* 2019;20(01):e42–e53
- Johnston WT, Erdmann F, Newton R, Steliarova-Foucher E, Schüz J, Roman E. Childhood cancer: Estimating regional and global incidence. *Cancer Epidemiol* 2021;71(Pt B):101662
- Kushner BH, Khakoo Y. Enigmatic entities: opsoclonus myoclonus ataxia syndrome linked to neuroblastoma. *Lancet Child Adolesc Health* 2018;2(01):3–5
- Maas MH, Cransberg K, van Grotel M, Pieters R, van den Heuvel-Eibrink MM. Renin-induced hypertension in Wilms tumor patients. *Pediatr Blood Cancer* 2007;48(05):500–503
- Yoshu E, Lone YA, Mahajan JK, Singh UB. Hepatoblastoma with precocious puberty. *J Indian Assoc Pediatr Surg* 2019;24(01):68–71
- Schooler GR, Squires JH, Alazraki A, et al. Pediatric hepatoblastoma, hepatocellular carcinoma, and other hepatic neoplasms: Consensus Imaging Recommendations from American College of Radiology Pediatric Liver Reporting and Data System (LI-RADS) Working Group. *Radiology* 2020;296(03):493–497
- Callahan MJ, Cravero JP. Should I irradiate with computed tomography or sedate for magnetic resonance imaging? *Pediatr Radiol* 2022;52(02):340–344
- Ng K, Mogul DB. Pediatric liver tumors. *Clin Liver Dis* 2018;22(04):753–772
- Czuderna P, Lopez-Terrada D, Hiyama E, Häberle B, Malogolowkin MH, Meyers RL. Hepatoblastoma state of the art: pathology, genetics, risk stratification, and chemotherapy. *Curr Opin Pediatr* 2014;26(01):19–28
- Spector LG, Birch J. The epidemiology of hepatoblastoma. *Pediatr Blood Cancer* 2012;59(05):776–779
- Towbin AJ, Meyers RL, Woodley H, et al. 2017 PRETEXT: radiologic staging system for primary hepatic malignancies of childhood revised for the Paediatric Hepatic International Tumour Trial (PHITT). *Pediatr Radiol* 2018;48(04):536–554
- Agarwala S, Gupta A, Bansal D, et al. Management of hepatoblastoma: ICMR consensus document. *Indian J Pediatr* 2017;84(06):456–464
- Cunningham ME, Klug TD, Nuchtern JG, et al. Global disparities in Wilms tumor. *J Surg Res* 2020;247:34–51
- Charlton J, Irtan S, Bergeron C, Pritchard-Jones K. Bilateral Wilms tumour: a review of clinical and molecular features. *Expert Rev Mol Med* 2017;19:e8
- Nelson MV, van den Heuvel-Eibrink MM, Graf N, Dome JS. New approaches to risk stratification for Wilms tumor. *Curr Opin Pediatr* 2021;33(01):40–48
- Kembhavi SA, Qureshi SS, Bhagat M, et al. Customized approach for upfront or delayed resection using radiological criteria in unilateral, nonmetastatic pediatric renal tumors: a prospective study. *Pediatr Blood Cancer* 2019;66(Suppl 3):e27815
- Qureshi SS, Bhagat M, Kazi M, et al. Standardizing lymph nodal sampling for Wilms tumor: a feasibility study with outcomes. *J Pediatr Surg* 2020;55(12):2668–2675
- Qureshi SS, Bhagat M, Smriti V, et al. Intravascular extension of Wilms tumor: Characteristics of tumor thrombus and their impact on outcomes. *J Pediatr Urol* 2021;17(01):69.e1–69.e8
- NCG guidelines 2020. Paediatric hematolymphoid and solid tumours. Accessed November 07, 2022, at: <https://tmc.gov.in/ngc/index.php/107-guidelines>
- Kembhavi SA, Qureshi S, Vora T, et al. Understanding the principles in management of Wilms' tumour: can imaging assist in patient selection? *Clin Radiol* 2013;68(07):646–653
- Prasad M, Vora T, Agarwala S, et al. Management of Wilms tumor: ICMR consensus document. *Indian J Pediatr* 2017;84(06):437–445
- Shaikh F, Murray MJ, Amatruda JF, et al. Paediatric extracranial germ-cell tumours. *Lancet Oncol* 2016;17(04):e149–e162
- Faure-Conter C, Rocourt N, Sudour-Bonnange H, et al. [Pediatric germ cell tumours]. *Bull Cancer* 2013;100(04):381–391
- Horton Z, Schlatter M, Schultz S. Pediatric germ cell tumors. *Surg Oncol* 2007;16(03):205–213
- Agarwala S, Mitra A, Bansal D, et al. Management of pediatric malignant germ cell tumors: ICMR consensus document. *Indian J Pediatr* 2017;84(06):465–472
- Dieckmann KP, Frey U, Lock G. Contemporary diagnostic work-up of testicular germ cell tumours. *Nat Rev Urol* 2013;10(12):703–712
- Feldman DR. State-of-the-art management of germ cell tumors. *Am Soc Clin Oncol Educ Book* 2018;38(38):319–323
- Matthay KK, Shulkin B, Ladenstein R, et al. Criteria for evaluation of disease extent by (123)I-metaiodobenzylguanidine scans in neuroblastoma: a report for the International Neuroblastoma Risk Group (INRG) Task Force. *Br J Cancer* 2010;102(09):1319–1326
- Monclair T, Brodeur GM, Ambros PF, et al; INRG Task Force. The International Neuroblastoma Risk Group (INRG) staging system: an INRG Task Force report. *J Clin Oncol* 2009;27(02):298–303
- Kembhavi SA, Shah S, Rangarajan V, Qureshi S, Popat P, Kurkure P. Imaging in neuroblastoma: An update. *Indian J Radiol Imaging* 2015;25(02):129–136
- Sharp SE, Shulkin BL, Gelfand MJ, Salisbury S, Furman WL. 123I-MIBG scintigraphy and 18F-FDG PET in neuroblastoma. *J Nucl Med* 2009;50(08):1237–1243
- Ward E, DeSantis C, Robbins A, Kohler B, Jemal A. Childhood and adolescent cancer statistics, 2014. *CA Cancer J Clin* 2014;64(02):83–103
- Ripperger T, Bielack SS, Borkhardt A, et al. Childhood cancer predisposition syndromes—A concise review and recommendations by the Cancer Predisposition Working Group of the Society for Pediatric Oncology and Hematology. *Am J Med Genet A* 2017;173(04):1017–1037
- Skapek SX, Ferrari A, Gupta AA, et al. Rhabdomyosarcoma. *Nat Rev Dis Primers* 2019;5(01):1
- Arndt CAS, Bisogno G, Koscielniak E. Fifty years of rhabdomyosarcoma studies on both sides of the pond and lessons learned. *Cancer Treat Rev* 2018;68:94–101
- Hibbitts E, Chi YY, Hawkins DS, et al. Refinement of risk stratification for childhood rhabdomyosarcoma using FOXO1 fusion status in addition to established clinical outcome predictors: a report from the Children's Oncology Group. *Cancer Med* 2019;8(14):6437–6448

- 37 van Ewijk R, Schoot RA, Sparber-Sauer M, et al; Cooperative Weichteilsarkom Studiengruppe Imaging Group, the European Society of Paediatric Radiology Oncology Task Force and the European Paediatric Soft Tissue Sarcoma Study Group Imaging Committee. European guideline for imaging in paediatric and adolescent rhabdomyosarcoma - joint statement by the European Paediatric Soft Tissue Sarcoma Study Group, the Cooperative Weichteilsarkom Studiengruppe and the Oncology Task Force of the European Society of Paediatric Radiology. *Pediatr Radiol* 2021;51(10):1940–1951
- 38 O JH, Lodge MA, Wahl RLO JH. Practical PERCIST: a simplified guide to PET response criteria in solid tumors 1.0. *Radiology* 2016; 280(02):576–584
- 39 Accessed November 07, 2022, at: <https://tmc.gov.in/tmh/pdf/EBM%202018-Guidelines%20for%20Paediatric%20Solid%20Tumours.pdf>
- 40 Crist WM, Anderson JR, Meza JL, et al. Intergroup rhabdomyosarcoma study-IV: results for patients with nonmetastatic disease. *J Clin Oncol* 2001;19(12):3091–3102
- 41 Raney RB, Walterhouse DO, Meza JL, et al. Results of the Intergroup Rhabdomyosarcoma Study Group D9602 protocol, using vincristine and dactinomycin with or without cyclophosphamide and radiation therapy, for newly diagnosed patients with low-risk embryonal rhabdomyosarcoma: a report from the Soft Tissue Sarcoma Committee of the Children's Oncology Group. *J Clin Oncol* 2011;29(10):1312–1318
- 42 Kivelä T The epidemiological challenge of the most frequent eye cancer: retinoblastoma, an issue of birth and death. *Br J Ophthalmol* 2009;93(09):1129–1131
- 43 Rodriguez-Galindo C, Orbach DB, VanderVeen D. Retinoblastoma. *Pediatr Clin North Am* 2015;62(01):201–223
- 44 Rangamani S, SathishKumar K, Manoharan N, et al. Paediatric retinoblastoma in India: evidence from the National Cancer Registry Programme. *Asian Pac J Cancer Prev* 2015;16(10):4193–4198
- 45 Stathopoulos C, Lumbroso-Le Rouic L, Moll AC, et al. Current indications of secondary enucleation in retinoblastoma management: a position paper on behalf of the European Retinoblastoma Group (EURbG). *Cancers (Basel)* 2021;13(14):3392