



# Gastrointestinal Bleeding Caused by Atrioesophageal Fistula Secondary to Atrial Fibrillation Ablation

Laura Tejerizo-García<sup>1</sup> Ana Menéndez-Ramos<sup>1</sup> Carmen Villar-Lucas<sup>1</sup> Antonio Velasco-Guardado<sup>1,2</sup>

<sup>1</sup>Department of Digestive Diseases, University Hospital of Salamanca, Salamanca, Spain

<sup>2</sup>Digestive System Research Group of Salamanca, Institute for Biomedical Research of Salamanca (IBSAL), Salamanca, Spain

Address for correspondence Antonio Velasco Guardado, MD, PhD, University Hospital of Salamanca, Paseo de la Transición Española s/n, 37007 Salamanca, Spain (e-mail: ajvelasco@saludcastillayleon.es).

J Digest Endosc 2023;14:62–63.

## Abstract

### Keywords

- ▶ endoscopy
- ▶ gastrointestinal bleeding
- ▶ atrioesophageal fistula

We present the case of a patient with upper gastrointestinal bleeding caused by an atrioesophageal fistula secondary to radiofrequency ablation for the treatment of refractory atrial fibrillation. Atrioesophageal fistula is a rare but serious complication. The endoscopic treatment is not established in the case of vascular-enteric fistulas and is still a challenge for endoscopists, which requires in most cases a multidisciplinary approach.

## Case Report

The patient is a 66-year-old woman with a history of pulmonary vein ablation 4 weeks earlier caused by persistent atrial fibrillation. She was admitted as an emergency with an episode of hematemesis. She reported fever spikes and melanic stools for 4 days.

Emergency endoscopy revealed a protruding fistulous orifice with ooze at 28 cm from dental arcade (→Fig. 1A). After unsuccessful hemoclip placement caused worsening of bleeding (→Fig. 1B), a fully covered esophageal stent, 105 mm × 20 mm (Cook Medical) was placed covering the orifice and fixated with two hemoclips.

Emergency computerized tomography angiography and an echocardiogram were normal (→Fig. 1C).

Given the history of prior ablation, the possibility of an atrioesophageal fistula (AEF) was considered, and a multidisciplinary committee decided to perform surgery.

During the procedure, a transmural lesion, 2 × 0.5 cm in diameter, was observed after accessing the left auricle on the posterior wall, in close contact with the esophageal stent (→Fig. 1D). The lesion was repaired with suture.

The esophageal stent was removed 19 days after it had been placed. In a gastroscopy 2 months later, complete healing of the fistulous orifice was observed (→Fig. 1E). The patient was discharged 43 days after admission.

The most common symptoms of AEF are fever, thoracic pain, and neurological deficiencies caused by the intracranial embolism of air, saliva, and bacteria. Bleeding is thought to appear in a “low” percentage of patients because the shunt between the esophagus and the atrium is generally unidirectional.<sup>1</sup> Neurological manifestations and gastrointestinal bleeding are associated with a higher mortality rate<sup>2</sup> and surgery is the only definitive treatment for AEF.<sup>3</sup> Reducing the radiofrequency power when ablating the left atrial posterior wall, monitoring the esophageal temperature, moving the left atrial posterior line to the roof, and esophageal cooling with a cooled water-irrigated intraesophageal balloon might reduce the risk of AEF.<sup>4</sup>

AEF requires a high level of suspicion to prevent morbidity and mortality secondary to a delay or a diagnostic error.<sup>5</sup>

It is difficult to establish a protocol for exceptional situations with a potentially lethal course, but endoscopy and placement of fully covered stent can be a bridge to stabilize the patient.

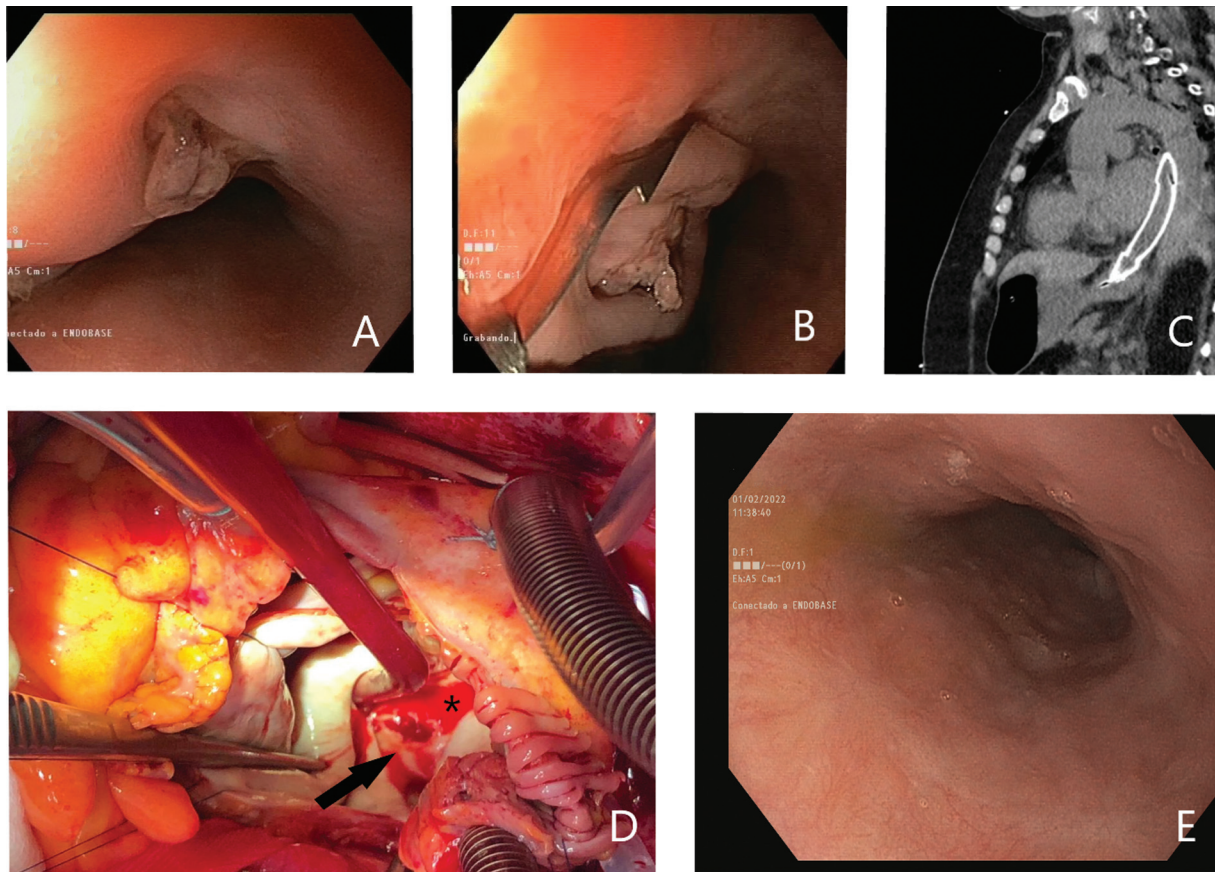
article published online  
December 23, 2022

DOI <https://doi.org/10.1055/s-0042-1759509>.  
ISSN 0976-5042.

© 2022. The Author(s).

This is an open access article published by Thieme under the terms of the Creative Commons Attribution License, permitting unrestricted use, distribution, and reproduction so long as the original work is properly cited. (<https://creativecommons.org/licenses/by/4.0/>)

Thieme Medical and Scientific Publishers Pvt. Ltd., A-12, 2nd Floor, Sector 2, Noida-201301 UP, India



**Fig. 1** (A) Gastroscopy with a protruding fistulous orifice. (B) Attempted clipping. (C) CT image showing the fully covered metal stent in contact with the left auricle. (D) Black arrow: a transmural lesion,  $2 \times 0.5$  cm in diameter, was observed during surgical intervention. \*Left auricle on the posterior wall. (E) Complete healing of the fistulous orifice.

#### Authors' Contributions

TGL and MRA wrote the article and processed the images. VLC and VGA performed the endoscopies. VGA supervised all writing process.

#### Author Listed as the Article Guarantor

Dr. Antonio Velasco Guardado.

#### Patient Consent

The informed patient consent was obtained for publication of the case details.

#### Conflict of Interest

None declared.

#### Funding

None.

#### References

- 1 Della Rocca DG, Magnocavallo M, Natale VN, et al. Clinical presentation, diagnosis, and treatment of atrioesophageal fistula resulting from atrial fibrillation ablation. *J Cardiovasc Electro-physiol* 2021;32(09):2441–2450
- 2 Han HC, Ha FJ, Sanders P, et al. Atrioesophageal fistula: clinical presentation, procedural characteristics, diagnostic investigations, and treatment outcomes. *Circ Arrhythm Electrophysiol* 2017;10(11):e005579
- 3 Jehaludi A, Heist EK, Giveans MR, Anand R. Retrospective review of 65 atrioesophageal fistulas post atrial fibrillation ablation. *Indian Pacing Electrophysiol J* 2018;18(03): 100–107
- 4 Nair GM, Nery PB, Redpath CJ, Lam BK, Birnie DH. Atrioesophageal fistula in the era of atrial fibrillation ablation: a review. *Can J Cardiol* 2014;30(04):388–395
- 5 Baker MJ, Panchal PC, Allenby PA. Life-threatening GI hemorrhage caused by atrioesophageal fistula: a rare complication after catheter ablation for atrial fibrillation. *Gastrointest Endosc* 2010;72(04):887–889