

Current Utilization and Acceptance of Multiparametric MRI in the Diagnosis of Prostate Cancer. A Regional Survey

Gegenwärtige Nutzung und Akzeptanz der multiparametrischen MRT in der Prostatakarzinomdiagnostik: Eine regionale Erfassung

Authors

Tim Ullrich¹, Lars Schimmöller¹, Mathias Oymanns¹, Dirk Blondin¹, Frederic Dietzel¹, Julian Kirchner¹, Christian Arsov², Robert Rabenalt², Peter Albers², Gerald Antoch¹, Michael Quentin¹

Affiliation

- 1 University Dusseldorf, Medical Faculty, Department of Diagnostic and Interventional Radiology, Dusseldorf, Germany
- 2 University Dusseldorf, Medical Faculty, Department of Urology, Dusseldorf, Germany

Key words

prostate cancer, multiparametric MRI, MRI-guided biopsy, questionnaire survey

received 27.11.2016

accepted 25.07.2017

Bibliography

DOI <https://doi.org/10.1055/s-0043-118128>

Published online: 21.9.2017

Fortschr Röntgenstr 2018; 190: 419–426

© Georg Thieme Verlag KG, Stuttgart · New York

ISSN 1438-9029

Correspondence

Priv.-Doz. Dr. Lars Schimmöller

Institut für Diagnostische und Interventionelle Radiologie, Universitätsklinikum Düsseldorf, Moorenstraße 5, 40225 Düsseldorf, Germany

Tel.: ++49/2 11/8 11 77 54

Fax: ++49/2 11/8 11 61 45

lars.schimmoller@med.uni-duesseldorf.de

ABSTRACT

Purpose To assess the current regional acceptance, valuation, and clinical role of multiparametric MRI (mp-MRI) in prostate cancer diagnostics by patients and physicians.

Materials and Methods Of 482 distributed standardized questionnaires, 328 patient and 31 physician questionnaires (urological and general practitioners in and around Düsseldorf) were analyzed over a period of 11 months. Questions were asked concerning general knowledge about prostate cancer, current diagnostic procedures, and knowledge about mp-MRI and MRI-guided biopsy.

Results 70% of the patients regarded accurate and exact diagnostics of prostate carcinomas as very important and 68% considered MP-MRI a useful technique. 28% of the patients with elevated PSA levels and negative transrectal ultrasound-guided biopsy (TRUS-GB) received MP-MRI as a secondary diagnostic. More than half of the patients estimated their overall knowledge about prostate cancer mediocre or worse and wished for more information about MR diagnostics. The majority of physicians (55%) ordered MP-MRI studies of the prostate and 68% saw their basic role in secondary diagnostics.

Conclusion In this regional assessment mp-MRI of the prostate was considered useful by patients and practitioners. Currently, there still is a considerable discrepancy between recommended and the actual number of conducted MP-MRI studies, particularly in patients after previous negative TRUS-GB, although practitioners already see the benefit in this patient collective. Even though the use of prostate MRI is frequently more established than suggested in the current German S3-guideline, its full potential has not yet been exploited. More comprehensive information about the applications and diagnostic benefits of prostate MRI is needed and desired among patients and physicians.

Key Points

- The use of prostate MRI is frequently more established than suggested in the current German S3-guideline (12/2016)
- The full potential of mp-MRI of the prostate has not been exploited
- More information about the clinical benefit and potential of prostate MRI is necessary and desired by patients and clinicians

Citation Format

- Ullrich T, Schimmöller L, Oymanns M et al. Current Utilization and Acceptance of Multiparametric MRI in the Diagnosis of Prostate Cancer. A Regional Survey. Fortschr Röntgenstr 2018; 190: 419–426

ZUSAMMENFASSUNG

Ziel Evaluation der regionalen Akzeptanz und des Stellenwertes der multiparametrischen MRT (mp-MRT) der Prostata bei Patienten und zuweisenden Ärzten.

Material und Methoden Von 482 ausgeteilten, standardisierten Fragebogen konnten über einen Zeitraum von 11 Monaten 328 Patientenfragebogen (251 Klinikpatienten; 77 Patienten regionaler urologischer Praxen im Raum Düsseldorf) und 31 Ärzfragebogen (regionale Urologen und Allgemeinmediziner) analysiert werden. Die Fragen umfassten den allgemeinen Kenntnisstand über das Prostatakarzinom, die aktuelle diagnostische Vorgehensweise, die Kenntnisse und Einordnung der mp-MRT sowie der gezielten MRT-geführten Biopsie.

Ergebnisse 70 % der 328 Patienten hielten eine sorgfältige und exakte Diagnostik des Prostatakarzinoms für sehr wichtig und 68 % beurteilten die mp-MRT als hierfür hilfreiche Methode. Demgegenüber kannten 35 % der Patienten weder die Untersuchung der Prostata mittels MRT, noch die Möglichkeit der MRT-geführten Biopsie. 28 % der Patienten mit erhöhten PSA-Werten erhielten nach negativer transrektaler ultraschall-

gesteuerter Biopsie (TRUS-PE) eine mp-MRT in der Sekundärindikation. Über die Hälfte der Patienten schätzten Ihren Wissenstand bezüglich des Prostatakarzinoms mittelmäßig bis schlecht ein und wünschten sich mehr Informationen über die Diagnostik. Die Mehrheit der 31 Ärzte gab an, Patienten eine mp-MRT der Prostata zu empfehlen (55 %) und sah zu 68 % aktuell die Hauptrolle der MRT in der Sekundärindikation.

Schlussfolgerung Die multiparametrische MRT der Prostata wurde von Patienten und Ärzten als sinnvoll erachtet. Jedoch besteht aktuell eine große Diskrepanz zu den tatsächlich durchgeführten MRT-Untersuchungen. Insbesondere bei Patienten nach negativer TRUS-PE erfolgte laut unserer Umfrage nur in einem geringen Anteil eine MRT-Untersuchung, obwohl von Ärzten hier eine der größten Vorteile der Methode gesehen wurde. Auch wenn die aktuelle Praxis der Anwendung der MRT in der Prostatakarzinomdiagnostik bereits über die deutsche S3-Leitlinie hinausgeht, wird das Potenzial der mp-MRT derzeit nicht ausgenutzt. Detailliertere Informationen über Anwendungsmöglichkeiten und Vorteile der mp-MRT sind somit notwendig und von Patienten und Ärzten gewünscht.

Introduction

In Europe, prostate cancer (PCa) is the most frequently-occurring malignant tumor in men, and is in third place in the mortality statistics of tumor diseases of men [1]. The current guideline-based diagnostics of PCa (as of 12/2016) relies on the digital-rectal examination (DRE), determination of protein-specific antigen (PSA) and transrectal ultrasound-guided prostate biopsy (TRUS-GB). Compared to the non-specific traditional procedure, multiparametric magnetic resonance imaging (mp-MRI) to detect prostate cancer provides greater value in the diagnosis of cancer [2]. As the currently most accurate imaging method, mp-MRI in combination with an MRI-guided prostate biopsy, especially after negative TRUS-GB, increases the tumor detection rate and can play a central role in tumor localization as well as in local staging [3–10]. In addition, there is a growing interest in MRI of the prostate prior to biopsy, in particular with slightly increased PSA values (< 10 ng/ml), as well as within the scope of active surveillance [11].

In 2015 in the course of increasing standardization of MRI of the prostate, a collaboration of the American College of Radiology (ACR), the European Society of Urogenital Radiology (ESUR) and the Adme Tech Foundation published joint recommendations for performing MP-MRI of the prostate as well as standardized reporting (Prostate Imaging – Reporting and Data System Version 2 – PI-RADS v2) [12].

In the latest revision of the German S3 guideline on prostate cancer dated December 2016 and valid until September 30, 2017, MRI of the prostate plays a rather subordinate role. MRI of the prostate is currently not recommended in biopsy naive patients and can be considered as complementary diagnostic tool after negative TRUS-GB. Patients with tumor category cT1 and low-risk tumors should not receive an imaging examination for

staging. According to the S3 guideline, MRI is currently not used for active surveillance [13]. Unlike Germany, in the UK, the National Institute for Health and Care Excellence Guideline as well as the European guideline for prostate cancer (European Association of Urology Guideline) recommend an MRI of the prostate for patients with a negative biopsy, and that in the case of a negative MRI, a repeat biopsy should be ruled out. An MRI of the prostate in combination with or instead of a repeat biopsy can be used for patients for whom there are ambiguous PSA results or if there are clinical changes in the course of active surveillance [14–16]. Comprehensive clinical guidelines based on solid evidence-based expertise over a long period of time and providing recommendations based on recent scientific evidence show a certain latency before such recommendations are integrated into clinical practice.

A country-wide survey of German physicians in 2015 determined that MP-MRI was a widely-available examination procedure in Germany; however, there were complaints regarding the underdeveloped quality control-related diagnostic and feedback mechanisms [17]. The current survey is intended to go beyond a population survey and evaluate the acceptance and assessment of the importance of MP-MRI among patients and physicians in the diagnosis of prostate cancer. Finally, it should assess whether there is an interest and a need for more information about the potential of MRI in the diagnosis of prostate cancer.

Materials and Methods

Study Design

Two different standardized questionnaires for patients and physicians were designed with questions regarding knowledge, current

application and evaluation of the value of MP-MRI. Over the course of 11 months (September 2014 to July 2015), 100 questionnaires were given out to male patients of 38 urological practices and 26 general medical or internal medical practices in Düsseldorf and the vicinity (Krefeld, Mönchengladbach, Neuss, Region Viersen, Kempen, Willich, Nettetal, Region Hilden, Monheim, Langenfeld, Ratingen; postal code region: 40, 41 und 47). These patients had presented with prostate issues. Likewise 300 questionnaires were given out to patients who had received an MRI examination of the prostate in the University Hospital of Düsseldorf. Other hospital departments were not included. The questionnaires addressed to physicians were given out to established practitioners (n = 82) of the above-named practices (► Fig. 1).

The anonymous survey was voluntary and approved by the ethics commission of the medical faculty of the Heinrich-Heine-University of Düsseldorf. All participants were informed via separate study information regarding the purpose of the study as well as legal clarification regarding anonymity and data protection. Written consent forms of all those surveyed were archived separately from the anonymous questionnaires.

Patient Questionnaire

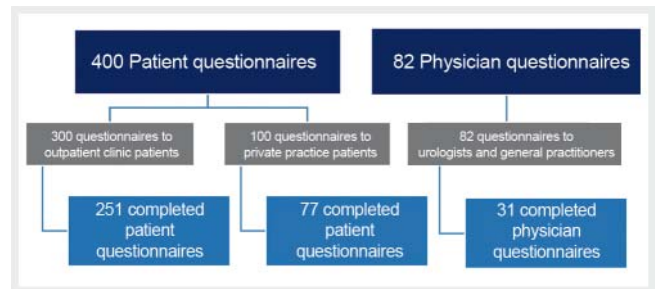
The patient questionnaire (Attachment 1) contained 15 groups of questions which could be answered using either free text, with up to 7 predetermined distinct response options, or using a scale of 1 to 5. Following demographic queries, the questions were directed toward the patient's own history regarding prostate cancer, PSA value and presence of clinical symptoms. Additional questions addressed the patient's general knowledge regarding prostate cancer and its related diagnosis, the preferred medical resource, regarding TRUS-GB and tolerance of further biopsies, and finally regarding knowledge and experience with MRI of the prostate and MRI-guided prostate biopsies.

Physician Questionnaire

The physician questionnaire (Attachment 2) contained 15 groups of questions which could mainly be answered using either free text, with up to 8 predetermined distinct response options (some with possible multiple selections) or answered using a scale of 1 to 5. First, the respondent's medical specialty was queried. Subsequently, the questions addressed the usual clinical procedure in prostate carcinoma diagnosis; the application of, or referral to, MRI of the prostate; experience with, and performance of, TRUS-GB. Finally the survey queried the assessment of the clinical relevance and the experiences with MP-MRI of the prostate and MRI-guided prostate biopsies.

Statistics

The data were recorded and statistically analyzed using MS Excel (Microsoft, Redmond, WA, USA) and SPSS version 22 (IBM). Continuous and categorical values were expressed as absolute values, percentages, mean values with standard deviation, or medians with interquartile range (IQR) between the upper (75%) and lower (25%) quartiles.



► Fig. 1 Study participants of 400 distributed patient and 82 physician questionnaires.

Results

Patient Cohort

On the whole, of the 400 questionnaires given out to patients, 328 could be evaluated. Of these, 77 questionnaires (23%) were from patients of the above-named urological and general medical practices, and 251 (77%) were answered by patients who had undergone MRI of the prostate at the University Hospital of Düsseldorf (UKD) (► Fig. 1). Patient profiles are shown in ► Table 1. Of 82 surveys distributed to physicians at the above-named practices, 31 were evaluated. Of these, 22 (71%) responses were provided by urological specialists; 8 GPs/internists (26%) responded, as well as one physician of the 31 respondents who held a dual specialty in general medicine and urology.

Patient Questionnaire

Patient History

Of the 328 assessable questionnaires, 45 (14%) indicated that they had identifiable PCa (Practice: 11/77; UKD: 34/251). Forty (12%) stated that a close relative (father, brother, son) suffered from PCa. In the majority of patients (237/328; 72%) the PSA value was initially determined in the course of a routine examination. Urination problems were reported by 68 patients (21%); 19 (6%) had sexual difficulties/erection problems; 7 complained of blood in urine, and 8 reported blood in their ejaculate.

Knowledge regarding PCa Diagnosis and MRI of the Prostate

On a scale of 1 (excellent) to 5 (very poor), 54% of those surveyed (177/328) rated their general knowledge regarding prostate cancer as average (3) or poor (► Fig. 2). Among surveyed patients in a practice, this assessment was 59% (46/77) and 52% (131/251) among outpatient clinic patients. The limited subpopulation of patients with identified prostate cancer (n = 45) showed a greater median knowledge: mean 2 (IQR 1 – 2) vs. 3 (IQR 2 – 3). Regarding the assessment of the general aggressiveness of PCa on a 5-point scale ranging from less aggressive (1) to highly-aggressive (5), the majority of those surveyed (94/328; 29%) regarded PCa as moderately aggressive (3) (1: 11%; 2: 16.5%; 3: 29%; 4: 13.5%; 5: 11%; no response: 19%). With a median assessment of 3 (IQR 2 – 4), patients in a private practice considered PCa to be more aggressive compared to those in an outpatient clinic practice,

► **Table 1** Baseline patient characteristics.

	total	private practice	clinic
number of patients	328	77 (23.5 %)	251 (76.5 %)
age [a]	64 ± 9.3; n = 312	68 ± 11; n = 72	64 ± 8.4; n = 240
size [cm]	178 ± 7.2; n = 315	177.0 ± 7.1; n = 74	179 ± 7.1; n = 241
weight [kg]	85 ± 14; n = 317	84 ± 12; n = 74	86 ± 14; n = 243
smoker	37; n = 309 (12 %)	11; n = 64 (15 %)	26; n = 234 (11 %)
country of origin	D: 262 (80 %) PL: 6 (2 %); TR: 4 (1 %), I: 3 (1 %)	D: 56 (73 %); TR: 2 (3 %), I: 2 (3 %)	D: 206 (82 %) PL: 6 (2 %); TR: 2 (1 %)
current PSA	8.3 ± 5.6; n = 263	4.4 ± 6.4; n = 31	8.8 ± 5.3; n = 232
initial PSA [ng/ml]	–	–	5.5 ± 4.6; n = 180

D = Germany, PL = Poland, TR = Turkey, I = Italy, H = Hungary. Outpatient mean initial PSA value could not be determined due to insufficient data.

who reported a median score of 2 (IQR 1 – 3). Regarding prostate cancer, 254/328 (77 %) responses indicated a urologist as their primary resource (personal physician: 10%; internist: 2%; other: 1%; no response or multiple responses: 10%). The majority of respondents (228; 70%) considered a good diagnosis of PCa as highly-relevant (1) on a 5-point scale, whereby 5 is rated as “Not relevant” (2: 14.5%; 3: 6.5%; 4: 1%; 5: 1%; no response: 7.5%).

Multiple responses were possible for the question regarding suitable methods of PCa diagnosis. The majority of respondents considered PSA screening (63%) and MRI (68%) to be useful. Fewer considered a digital rectal examination (49%), ultrasound (42%) or biopsies (47%) to be of use. Computed tomography (CT) and positron emission tomography (PET) were less favored, with 7% and 5%, respectively. Thirty-five percent of respondents stated that they did not know that the prostate can be examined using MRI, although 61% of the patients were aware of this (no response: 4%). At the time of the survey, 95 of the 328 respondents (29%) had already received an MP-MRI of the prostate (no response: 6.5%). Exact diagnosis was associated with MRI by 256 of the respondents (78%); 89 (27%) experienced the MRI as constricting; 84 (26%) considered it loud; 64 (20%) thought it was too expensive, and 51 (16%) felt the examination was time-consuming (no response: 10%; multiple selections were possible). The majority (193; 59%) desired more information regarding diagnosing prostate cancer (no response: 18%).

Prostate Biopsy Experiences

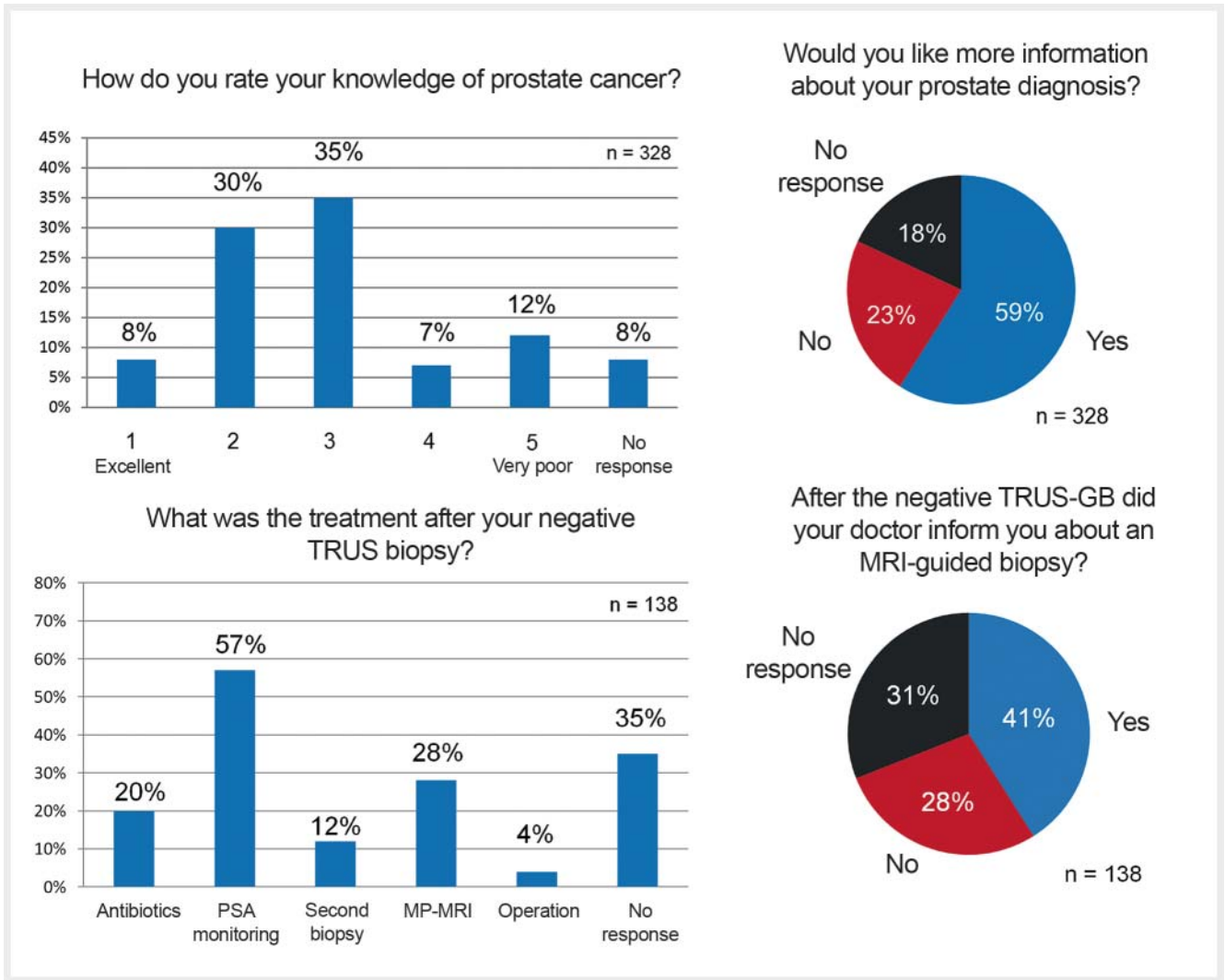
Of the 328 assessed patients, 132 indicated that they had already undergone one or more prostate biopsies. Seventy-one patients reported one biopsy, 38 (12%) had experienced two biopsies; 12 (4%) indicated three biopsies, and more than three biopsies had been performed on 11 respondents (no biopsy: 98; no response: 98). Prostate cancer was indicated by 45 patients (14%) as the result of their biopsy (negative: 138; no response 145). Twenty-eight patients reported complications during or after an ultrasound biopsy. In response to whether they would undergo

another biopsy, 13 (4%) answered “Absolutely not”; 42 indicated “Rather not”; 7 (2%) were “Indifferent”; 121 (37%) stated “If necessary” and 21 (6%) replied “Doesn’t bother me” (no response: 124/328). Relative to patients who had indicated a negative ultrasound biopsy (n = 138), 27 (20%) reported receiving an adjunct antibiotic treatment; 78 (57%) reported further PSA monitoring; 16 (12%) underwent further biopsy; 39 (28%) had an MRI examination; 6 reported surgery (multiple selections were possible; no response 48/138, 35%) (► **Fig. 2**). Of the 138 patients indicating a negative ultrasound-guided biopsy, 56 were informed by their physician regarding the option of an MRI-guided biopsy (39 not informed; no response: 43/138).

Physician Questionnaire

Current Standard Diagnosis of Prostate Cancer

Taking into account all physicians submitting assessable questionnaires with respect to standard examination methods to diagnose prostate cancer, 100% of the 31 responding physicians indicated monitoring PSA progression; 97% employed digital-rectal examination; 71% used ultrasound procedures (TRUS, elastography or contrast-supported ultrasound); 77% performed TRUS-GB procedures; 61% ordered prostate MRIs; 48% relied on MRI-guided prostate biopsies (MR/US fusion biopsy, MRI in-bore biopsy); 16% indicated PET CT or PET MRI. Typically, 15 of the 31 physicians (48%) saw 1 – 10 patients per week with a raised PSA value (> 4 ng/ml); 10 (32%) saw between 11 and 20 patients with a pathological PSA value; one saw 21 – 30 patients; 3 (10%) saw more than 30 patients (no patients: 6%). The majority of surveyed physicians (22/31; 71%) recommended TRUS-GB in cases of “conspicuous” PSA progression (e. g. raised/increasing PSA values); 31% recommended the procedure if the PSA value was above 4 ng/ml; 48% in the event of positive palpation; 29% in cases of “suspicious” MRI; 16% for “noticeable” clinical symptoms (no response: 6%). Eighteen doctors (58%) performed 1 – 20 TRUS-GBs per month; 11/31 (35%) indicated that they did not perform this procedure. None of the respondents performed more than 20



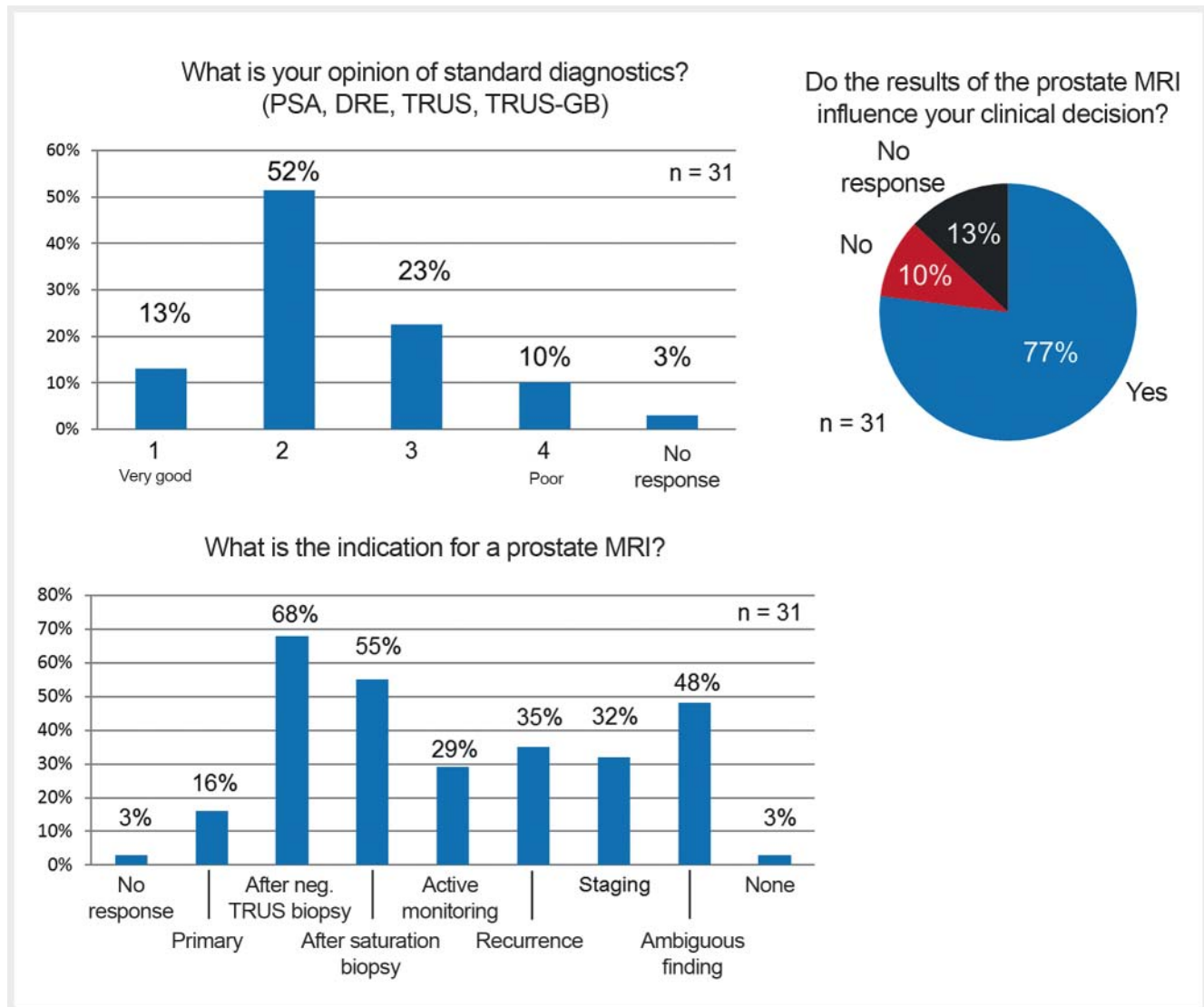
► Fig. 2 Analysis of patient questionnaires.

biopsies per week (no response: 6%). When performing a TRUS-GB, 15 physicians (48%) obtained 12 cores (<6 cores: 6%; 8–10 cores: 6%; 14–16 cores: 3%; >16 cores: 13%; no response 23%). On a scale of 1–5, where 1 is “Very good” and 5 represents “Insufficient”, the majority of physicians (16; 52%) rated the standard diagnostic method as “Good” (2), (► Fig. 3).

Value of MRI Diagnosis of the Prostate

In response to the question whether they generally recommend MRI examination of the prostate, 55% answered “Yes” (“No”: 29%; no response: 16%). The majority of the respondents considered the indication of a prostate MRI a secondary diagnostic procedure (21; 68%) after a negative systematic biopsy (► Fig. 3). Based on a five-point scale used to rate the significance of prostate MRI, where 1 represents “Very high”, and 5 is “Insufficient”, the majority (15/31; 48%) evaluated the procedure with “3” (1: 3%; 2: 26%; 4: 13%; 5: 0%; no response: 10%). In response to the question regarding the parameters an MRI of the prostate should include, 15 (48%) indicated “Anatomical sequences”; 11

(35%) stated “Diffusion”; one respondent (3%) answered “Spectroscopy”; 15 stated “Radiologist decides” and 3 replied “Prostate MRI is a standardized examination; (no response: 13%). Thirteen of the respondents (42%) considered an endorectal coil to be necessary for a prostate MRI (“Not necessary”: 39%; no response 19%). Decisions of the majority of the responding physicians (24; 77%) were influenced by the results of the prostate MRI (► Fig. 3). Eighteen of the respondents (58%) were not familiar with the PI-RADS classification for the evaluation of suspicious lesions in prostate MRI (“Familiar”: 32%; no response: 10%). In their clinical routine, 17 (55%) of the physicians did not use a standardized localization method to assign regions within the prostate (e.g. PI-RADS v1/v2 localization scheme) (“Yes”: 19%; no response: 26%) The majority (17; 55%) had attended continuing education on prostate MRI (“No”: 39%; no response: 6%). Twenty-four (77%) replied “No” to the question whether they perform MRI-guided biopsies (MR/US fusion biopsy; MRI in-bore-biopsy) (“Yes”: 23%). Regarding MRI-guided biopsies, on a five-point scale, where 1 is “Very good” and 5 represents “Insufficient” one of 31 (3%) rated the procedure as “Very good”; 11 (35%) graded it “2”; 12 (39%)



► Fig. 3 Analysis of physician questionnaires.

gave it “3”, and 2 (6%) rated it as “4” (“Insufficient”: 0%; no response: 16%).

Discussion

A significant majority of patients considered mp-MRI a useful method to obtain an exact diagnosis of prostate cancer. On the whole, the level of knowledge of the surveyed patients about this diagnostic procedure was low. In the clinical routine, after a negative transrectal ultrasound-guided biopsy (TRUS-GB) 28% of patients with elevated PSA values underwent an mp-MRI (in secondary indication), although 68% of surveyed doctors considered MRI particularly useful in this situation. Recent studies have shown that multiparametric MRI (mp-MRI) of the prostate provides a significant improvement in the detection, staging and active monitoring of prostate cancer [7, 9, 18–21]

Our study demonstrates that the majority of the responding physicians were influenced by the results of the prostate MRI. Paradoxically, the majority of physicians considered the meaningfulness of the prostate MRI as only moderate or poor. One reason for this may be that there is so far no national standard based on which the urologist or treating physician can estimate the reliability of an MRI finding [17]. Studies of experienced centers show high detection rates and negative predictive values with standardized execution and evaluation of the MP-MRI [22, 23]. To date, however, there has been a lack of qualitative reproducibility that would make a prostate MRI finding more reliable for the referring physician [24]. The joint recommendations of the American College of Radiology (ACR), the European Society of Urogenital Radiology (ESUR) and the AdmeTech Foundation regarding performance of MP-MRI of the prostate as well as standardized findings (PI-RADS v2) are an important step towards an international standard which can strengthen the trust of the referring physicians in the method [12]. In the German-speaking realm, one

step in this direction includes, among other things, current standardized implementation and protocol recommendations for prostate MRI [25]. Individual studies which continue to promote the use of their own Likert scales suggest that uniform, standardized diagnosis must be further developed [26].

The majority of physicians surveyed considered the current standard diagnosis of PCa as good or better and saw the greatest benefit of MP-MRI in secondary diagnosis and / or after negative (saturation) biopsy. More than one-third of the physicians saw indications of MRI which went beyond the recommendations of the current S3 guideline and were thus oriented more toward international guidelines [14 – 16]. However, attending physicians must be provided with a deeper understanding of MRI findings in order to make full use of the diagnostic potential of prostate MRI and to make the method overall more cost-effective [18, 27]. The 2015 survey of German physicians criticized inadequate feedback from attending physicians to radiologists after prostate MRI [17]. This survey revealed that the majority of respondents were unaware of the PI-RADS classification and that no standardized localization scheme was used to document and explain findings. In contrast, the majority had already pursued continuing education regarding prostate MRI; thus there appears to be a strong interest in this method.

The surveyed patients demonstrated great interest in up-to-date information regarding prostate cancer. Only 41 % of respondents were advised by their physician about the possibility of an MRI and MRI-guided biopsy after a negative TRUS biopsy, despite higher detection rates, reduced histological upgrading, and the possibility to rule out clinically significant tumors; in comparison to TRUS-GB, no increased side effects or complications have been demonstrated, and patients have shown good acceptance of the procedure [28, 29].

This study does have some limitations. First of all, it deals with a regional survey that cannot be directly applied to all of Germany. Estimation of the value and utilization of MP-MRI of the prostate can vary due to different factors. The survey is representative of 20 % of the queried immigrant patient population, both with respect to the Federal Republic of Germany (21 %) as well as the Düsseldorf metropolitan area (17 %) [30]. In addition, there is an imbalance between the proportionally larger group of outpatient clinic patients and the smaller number of private practice patients within this study; thus a separate evaluation would be interesting in future surveys.

In summary, both the patient and physician urgently require more detailed information on the potential applications and advantages of MP-MRI in order to provide the necessary confidence in the method and fully utilize its diagnostic potential. Physicians have hitherto seen the greatest advantage of the method in secondary diagnosis in combination with an MRI-guided biopsy after negative TRUS-guided biopsy. More than two-thirds of the surveyed physicians indicated that they used MP-MRI for patients after negative TRUS biopsy and that their clinical decisions were influenced by the outcome of the MRI. However, only 28 % of the patients surveyed actually received an MRI of the prostate after a negative systematic TRUS biopsy.

Conflict of Interest

The authors declare that they have no conflict of interest.

References

- [1] Ferlay J, Soerjomataram I, Ervik M et al. GLOBOCAN 2012: estimated cancer incidence, mortality and prevalence worldwide in 2012; 2013; International Agency for Research on Cancer website
- [2] Murphy G, Haider M, Ghai S et al. The expanding role of MRI in prostate cancer. *Am J Roentgenol* 2013; 201: 1229 – 1238
- [3] Panebianco V, Barchetti F, Sciarra A et al. Multiparametric magnetic resonance imaging vs. standard care in men being evaluated for prostate cancer: a randomized study. *Urol Oncol* 2015; 33: 17.e1 – 17.e7
- [4] Park BK, Park JW, Park SY et al. Prospective evaluation of 3T MRI performed before initial transrectal ultrasound-guided prostate biopsy in patients with high prostate-specific antigen and no previous biopsy. *Am J Roentgenol* 2011; 197: W876 – W881
- [5] Arsov C, Rabenalt R, Blondin D et al. Prospective randomized trial comparing magnetic resonance imaging (MRI)-guided in-bore biopsy to MRI-ultrasound fusion and transrectal ultrasound-guided prostate biopsy in patients with prior negative biopsies. *Eur Urol* 2015; 68: 713 – 720
- [6] Hambrock T, Somford DM, Hoeks C et al. Magnetic resonance imaging guided prostate biopsy in men with repeat negative biopsies and increased prostate specific antigen. *J Urol* 2010; 183: 520 – 527
- [7] Siddiqui MM, Rais-Bahrami S, Turkbey B et al. Comparison of MR/ultrasound fusion-guided biopsy with ultrasound-guided biopsy for the diagnosis of prostate cancer. *JAMA* 2015; 313: 390 – 397
- [8] Valerio M, Donaldson I, Emberton M et al. Detection of Clinically Significant Prostate Cancer Using Magnetic Resonance Imaging-Ultrasound Fusion Targeted Biopsy: A Systematic Review. *Eur Urol* 2015; 68: 8 – 19
- [9] Schimmöller L, Blondin D, Arsov C et al. MR-guided in-bore biopsy: Differences between prostate cancer detection and localization within primary and secondary biopsy settings. *AJR Am J Roentgenol* 2016; 206: 92 – 99
- [10] Bloch BN, Genega EM, Costa DN et al. Prediction of prostate cancer extracapsular extension with high spatial resolution dynamic contrast-enhanced 3-T MRI. *Eur Radiol* 2012; 22: 2201 – 2210
- [11] Ouzzane A, Puech P, Villers A. MRI and surveillance. *Curr Opin Urol* 2012; 22: 231 – 236
- [12] Weinreb JC, Barentsz JO, Choyke PL et al. PI-RADS Prostate Imaging – Reporting and Data System: 2015, Version 2. *Eur Urol* 2016; 69: 16 – 40
- [13] Leitlinienprogramm Onkologie (Deutsche Krebsgesellschaft, Deutsche Krebshilfe, AWMF): Konsultationsfassung: Interdisziplinäre Leitlinie der Qualität S3 zur Früherkennung, Diagnose und Therapie der verschiedenen Stadien des Prostatakarzinoms, Langversion 4.0, 2016 AWMF Registernummer: 043/022OL. <http://leitlinienprogramm-onkologie.de/Prostatakarzinom.58.0.html> (Zugriff am: 20.03.2017)
- [14] Graham J, Kirkbride P, Kimberly C et al. Prostate cancer: summary of updated NICE guidance. *BMJ* 2014; 348: f7524
- [15] The National Institute for Health and Clinical Excellence (NICE). Prostate cancer: diagnosis and management. Clinical Guideline 2014. <https://www.nice.org.uk/guidance/cg175>
- [16] EAU Guidelines on Prostate Cancer 2016. <https://uroweb.org/wp-content/uploads/EAU-Guidelines-Prostate-Cancer-2016.pdf>
- [17] Mueller-Lisse UG, Lewerich B, Mueller-Lisse UL et al. MRI of the Prostate in Germany: Online Survey among Radiologists. *Fortschr Röntgenstr* 2015; 187: 703 – 711
- [18] Puech P, Randazzo M, Ouzzane A et al. How are we going to train a generation of radiologists (and urologists) to read prostate MRI? *Curr Opin Urol* 2015; 25: 522 – 535

- [19] Schoots IG, Petrides N, Giganti F et al. Magnetic resonance imaging in active surveillance of prostate cancer: a systematic review. *Eur Urol* 2015; 67: 627–636
- [20] Heijnsdijk EA, de Koning HJ, Huisman HJ et al. Overdetection, overtreatment and costs in prostate-specific antigen screening for prostate cancer. *Br J Cancer* 2009; 101: 1833–1838
- [21] Moore CM, Taneja SS. Integrating MRI for the diagnosis of prostate cancer. *Curr Opin Urol* 2016; 26: 466–471
- [22] Fütterer JJ, Briganti A, De Visschere P et al. Can Clinically Significant Prostate Cancer Be Detected with Multiparametric Magnetic Resonance Imaging? A Systematic Review of the Literature. *Eur Urol* 2015; 68: 1045–1053
- [23] Schimmöller L, Quentin M, Arsov C et al. Predictive power of the ESUR scoring system for prostate cancer diagnosis verified with targeted MR-guided in-bore biopsy. *Eur J Radiol* 2014; 83: 2103–2108
- [24] Rosenkrantz AB, Margolis DJ. Commentary regarding the inter-reader reproducibility of PI-RADS version 2. *Abdominal Radiology* 2016; 41: 907–909
- [25] Franiel T, Quentin M, Mueller-Lisse UG et al. MRT der Prostata: Empfehlungen zur Vorbereitung und Durchführung. *Fortschr Röntgenstr* 2017; 189: 21–28
- [26] Muller BG, Shih JH, Sankineni S et al. Prostate Cancer: Interobserver Agreement and Accuracy with the Revised Prostate Imaging Reporting and Data System at Multiparametric MR Imaging. *Radiology* 2015; 277: 741–750
- [27] Willis SR, van der Meulen J, Valerio M et al. A review of economic evaluations of diagnostic strategies using imaging in men at risk of prostate cancer. *Curr Opin Urol* 2015; 25: 483–489
- [28] Ahmed HU, El-Shater Bosaily A, Brown LC et al. Diagnostic accuracy of multi-parametric MRI and TRUS biopsy in prostate cancer (PROMIS): a paired validating confirmatory study. *Lancet* 2017; 389: 815–822
- [29] Egbers N, Schwenke C, Maxeiner A et al. MRI-guided core needle biopsy of the prostate: acceptance and side effects. *Diagn Interv Radiol* 2015; 21: 215–221
- [30] Bevölkerung und Erwerbstätigkeit – Ergebnisse des Mikrozensus 2015 – Fachserie 1 Reihe 2.2, Statistisches Bundesamt (Destatis); 2017