



In-Situ ‘Divide’ and ‘Deliver’: A Simple Technique to Preserve Nerves in Chimeric Anterolateral Thigh Flap Harvest

Dushyant Jaiswal¹ Hetanshu Parekh² Saumya Mathews¹ Amol Ghalme³

¹Department of Plastic and Reconstructive Surgery, Tata Memorial Hospital, Homi Bhabha National Institute, Mumbai, India

²Department of Plastic and Reconstructive Surgery, Mahamana Pandit Madan Mohan Malviya Cancer Centre & Homi Bhabha Cancer Hospital, Tata Memorial Center, Varanasi, India

³Department of Plastic and Reconstructive Surgery, Kokilaben Dhirubhai Ambani Hospital and Research Institute, Mumbai, India

Address for correspondence Hetanshu Parekh, Mch, DrNB, Department of Plastic and Reconstructive Surgery, Mahamana Pandit Madan Mohan Malviya Cancer Centre & Homi Bhabha Cancer Hospital, Tata Memorial Center, Varanasi, India (e-mail: hetanshu.parekh@gmail.com).

Indian J Plast Surg 2023;56:74–77.

Abstract

Keywords

- ▶ anterolateral thigh flap
- ▶ technique of alt harvest
- ▶ free flap reconstruction
- ▶ donor site morbidity in alt
- ▶ chimeric alt flap
- ▶ multiple paddle alt
- ▶ bipaddle alt harvest

Anterolateral thigh (ALT) flap is the workhorse for reconstruction in head and neck post cancer excision. Chimeric multi-paddle flaps are useful for composite defects involving skin, mucosa, and soft tissue. The nerve to vastus lateralis (VL) runs along the pedicle, frequently interdigitating with it or the perforators. Sometimes, the nerve may be preserved during harvest but needs to be sacrificed frequently, leading to increased donor site morbidity.

We recommend a simple technique to preserve the nerve, wherein the skin paddles or chimeric components are divided in-situ and manipulated around it without causing injury.

This technique was used in 27 cases over 5 years. All involved nerves, perforators and pedicles were preserved.

The technique can be extended to any flap harvest with multiple perforators with nerves in proximity, when multiple skin islands are desired.

Introduction

The versatility of the anterolateral thigh (ALT) flap for reconstruction of complex defects following cancer ablation is well documented.^{1,2} It allows harvest of multiple flap components and skin paddles based on separate perforators. It has minimal long-term complications and donor-site morbidity as compared with other thin fasciocutaneous flaps.^{3,4} Donor site morbidity is also minimal if it is closed primarily. Harvest without vastus lateralis (VL) and leaving its nerve supply intact

decreases morbidity, with minimal postoperative muscle weakness or restriction in knee movements or impairment of activities of daily life seen.⁵

The branches of the femoral nerve innervating the VL are intimately related to the vascular pedicle and perforators of the flap. Variations in anatomy and branching pattern of the nerves occur. The nerve may be travelling along or under or over or may be intertwined with the pedicle or perforators of the flap. Single perforator harvest is usually done preserving the entire nerve arborization. During harvest of chimeric or

article published online
February 2, 2023

DOI <https://doi.org/10.1055/s-0043-1760829>
ISSN 0970-0358.

© 2023. Association of Plastic Surgeons of India. All rights reserved. This is an open access article published by Thieme under the terms of the Creative Commons Attribution-NonDerivative-NonCommercial-License, permitting copying and reproduction so long as the original work is given appropriate credit. Contents may not be used for commercial purposes, or adapted, remixed, transformed or built upon. (<https://creativecommons.org/licenses/by-nc-nd/4.0/>)
Thieme Medical and Scientific Publishers Pvt. Ltd., A-12, 2nd Floor, Sector 2, Noida-201301 UP, India

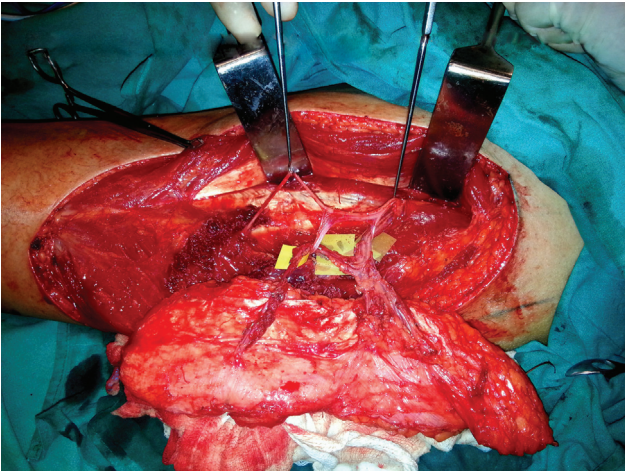


Fig. 1 Free ALT flap dissected with two perforators and a branch of the nerve to vastus lateralis muscle going in between the two perforators.

multi-paddle flaps, the preservation of two or more perforators in the presence of complex anatomy invariably leads to sacrifice of the nerve or its branches.

We propose a 'Divide' and 'Deliver' technique of harvesting multi-paddle or chimeric ALT flaps, which enables saving all nerve branches.

Case Series

We employed this in-situ 'Divide' and 'Deliver' technique in 27 cases over 5 years to preserve the integrity of the nerve, its branches and the perforators. (19 chimeric ALT and 8 ALT + TFL flaps).

These cases were multi-paddle flaps planned for reconstruction requiring mucosal lining and skin defects and in whom the nerve to VL or its branches were entangled and interlaced with the perforators of the flap.

The harvest was done in a standard manner with a noncommittal anterior straight incision (Doppler-guided), sub-facial perforator to pedicle dissection, without harvesting VL and preserving all nerve branches (► **Fig. 1**).

An estimate of the flap size required was done after assessment of the defect. Skin paddles of the flap were planned and after reconfirming the defect size, the skin paddles were 'divided' in situ, keeping the pedicle intact. Once divided, the skin paddles were maneuvered so as to 'deliver' them from between the branches of the nerve (► **Fig. 2**). The dissection was then completed to separate the nerve and its branches throughout its entire course from the perforators without any damage (► **Fig. 3**).

The average width of the flap was ~7 cm and the donor area was closed primarily.

All flaps were planned so as to be divided based on separate perforators. Postoperative course of the patients in the ward was uneventful. There was no incidence of flap loss or marginal necrosis. All flaps survived without any major complications. The reported donor site morbidity was minimal, with no complaints by the patients. There was no reported loss of sensation over lateral thigh and no change in

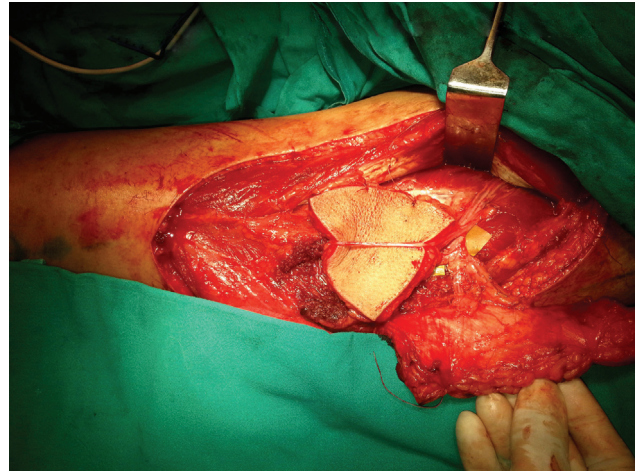


Fig. 2 One of the two skin paddles is being maneuvered and delivered from between the branches of the nerve.

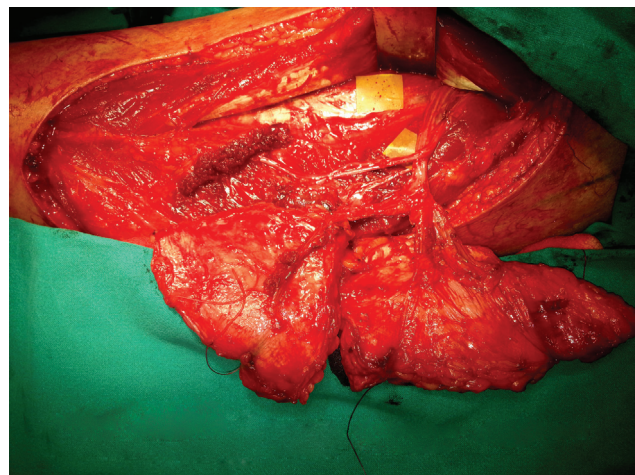


Fig. 3 The divided skin paddles are delivered from between the nerve branches to preserve both the perforators and also the nerve branches.

gait or weakness/difficulty in extension of the knee, was encountered or reported.

Discussion

Nerve preservation is a deliberate purposeful act in ALT harvest, for which extreme care in dissection and awareness of anatomy is needed. It is as important as muscle preservation to reduce the functional donor site morbidity. Hence, perforator dissection needs to be done with a simultaneous aim of preserving nerves and muscles. Magnification, immaculate hemostasis, bipolar cautery for dissection, microvascular instruments for perforator and pedicle handling, all reduce chances of injury.

The descending branch of the lateral circumflex femoral artery gives multiple perforators that supply the skin paddle, which are closely related to branches of the nerve to the VL. There are many spatial variations in the course of the pedicle, the nerve to VL, its branches and the perforators.⁵ Anatomical variations include the nerve passing through the pedicle

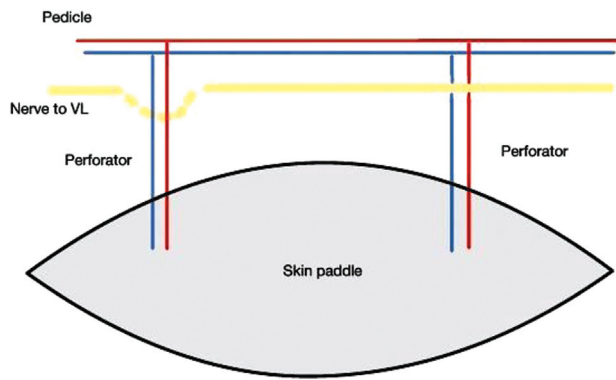


Fig. 4 ALT flap with 2 perforators with one perforator running below the nerve.

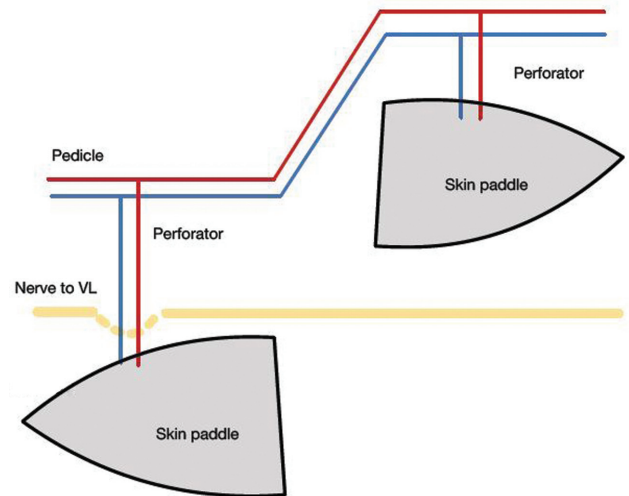


Fig. 6 Skin paddle is 'divided' and one of the paddles is 'maneuvered' (delivered) around the nerve.

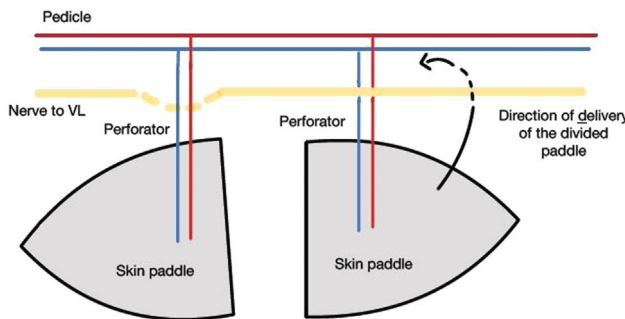


Fig. 5 Skin paddle is 'divided' and one of the paddles is 'maneuvered' (delivered) around the nerve.

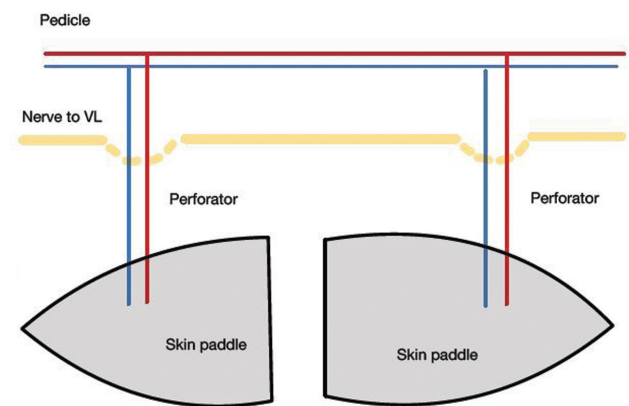


Fig. 7 Skin paddle is divided and delivered to preserve the nerve and perforators.

of the ALT flap, or passing between perforators, seen in 28% of a 36-human cadaveric thigh dissection study.³ In good hands, during harvest based on a single perforator/pedicle and no muscle, all nerves and branches can usually be preserved. However, harvest of multi-paddle chimeric ALT flaps require multiple perforators that are identified, dissected, and preserved. When unfavorable variations of nerve anatomy are encountered, wherein the motor nerve passes through the vascular pedicle itself or passes between perforators supplying the flap, the nerve or its branches are invariably cut to preserve the perforators.

Donor-site dysfunction is found to positively correlate with the degree of damage to the nerve to VL and/or harvest of VL and rectus femoris muscle or its innervation/blood supply during tissue harvest.⁵ Muscular weakness, fatigue, pain, knee instability, and rarely gait abnormalities have been found to occur as a consequence of such nerve dam-

age.⁶⁻⁸ To reduce donor site morbidity, it has become imperative to devise newer methods of harvest, which preserve the integrity of the nerve throughout its course.

'Divide and Deliver' technique entails in-situ planning of the skin paddle by assessing the defect. 'Dividing' of the skin paddle of appropriate size, based on separate perforators, keeping the pedicle intact. The paddles are then 'delivered' from the interlaced nerve branches/ loops of nerves, safeguarding the nerve branches as well as the perforators. (► Figs. 4-7).

Table 1 Advantages and limitations of the technique

Advantages	Limitations
Nerve supply of vastus lateralis is always completely preserved thus, preserving function and decreasing donor morbidity	Can be applied to specific defects only
Better results can be achieved by using various components of the chimeric flap for adequate reconstruction of the defect in all 3 dimensions (length, width, and depth)	Needs dissection of multiple perforators
	Defects need to be assessed and measured perfectly as once components are divided, then modifications are not possible

By application of this simple technique, we can safeguard the nerve supply of VL and its function, reduce postoperative donor site morbidity and enhance the functional recovery of the patients (► **Table 1**).

This technique can also be employed for other chimeric flaps or when large ALT needing a STSG for closure is required.⁹ Here a longer flap with primarily closable donor area can be harvested preserving the nerves. The flap can be divided into separate components or paddles based on separate perforators, which are subsequently rearranged to cover a larger defects.

Conclusion

In-situ 'divide' and 'deliver' technique of ALT harvest is an effective tool to reconstruct complex head and neck defects with minimal donor site morbidity. This concept can be extended to reconstruction of other complex defects of the chest/extremities by multi-paddle ALT flaps with an eye to achieve both aesthetic and functional goals without any donor-site impairment by avoiding sacrifice of the nerve during harvest.

Conflict of Interest
None declared.

References

- 1 Wei FC, Jain V, Celik N, Chen HC, Chuang DC, Lin CH. Have we found an ideal soft-tissue flap? An experience with 672 anterolateral thigh flaps. *Plast Reconstr Surg* 2002;109(07):2219–2226, discussion 2227–2230
- 2 Shieh SJ, Chiu HY, Yu JC, Pan SC, Tsai ST, Shen CL. Free anterolateral thigh flap for reconstruction of head and neck defects following cancer ablation. *Plast Reconstr Surg* 2000;105(07):2349–2357, discussion 2358
- 3 Rozen WM, le Roux CM, Ashton MW, Grinsell D. The unfavorable anatomy of vastus lateralis motor nerves: a cause of donor-site morbidity after anterolateral thigh flap harvest. *Plast Reconstr Surg* 2009;123(05):1505–1509
- 4 Pribaz JJ, Orgill DP, Epstein MD, Sampson CE, Hergueter CA. Anterolateral thigh free flap. *Ann Plast Surg* 1995;34(06):585–592
- 5 Kimata Y, Uchiyama K, Ebihara S, et al. Anterolateral thigh flap donor-site complications and morbidity. *Plast Reconstr Surg* 2000;106(03):584–589
- 6 Lipa JE, Novak CB, Binhammer PA. Patient-reported donor-site morbidity following anterolateral thigh free flaps. *J Reconstr Microsurg* 2005;21(06):365–370
- 7 Hanasono MM, Skoracki RJ, Yu P. A prospective study of donor-site morbidity after anterolateral thigh fasciocutaneous and myocutaneous free flap harvest in 220 patients. *Plast Reconstr Surg* 2010;125(01):209–214
- 8 Collins J, Ayeni O, Thoma A. A systematic review of anterolateral thigh flap donor site morbidity. *Can J Plast Surg* 2012;20(01):17–23
- 9 Jaiswal D, Mantri MR, Shankhdhar VK, Wagh SH. Chimeric ALT plus TFL perforator flap for breast reconstruction post radical mastectomy with large skin defect. *Indian J Plast Surg* 2021;54(02):208–210