



# Endoscopic Trans-Aqueductal Procedures for Juxta 4th Ventricular and Posterior Fossa Arachnoid Cyst using Flexible/Video Neuroendoscope: A Novel Approach

Subodh Raju<sup>1,3</sup> Ramesh Shighakolli<sup>2</sup> Lokesh Lingappa<sup>3</sup>

<sup>1</sup>Department of Neurosurgery, AIG Hospitals, Hyderabad, Telangana, India

<sup>2</sup>Department of Neurosurgery, Kamineni Hospitals, Hyderabad, Telangana, India

<sup>3</sup>Department of Neurosciences, Rainbow Children's Hospital, Hyderabad, Telangana, India

Address for correspondence Subodh Raju, MCh, Department of Neurosurgery, AIG Hospitals, Gachibowli, Hyderabad, 500033, Telangana, India (e-mail: subodh61raju@gmail.com).

AJNS 2023;18:62–69.

## Abstract

**Objective** Fourth ventricular and juxta fourth ventricular arachnoid cysts (ACs) are rare clinical entities. Conventionally, ACs are managed with either micro-surgical excision or cerebrospinal fluid (CSF) diversionary procedures such as a shunt. Effective treatment modality still remains controversial. Advances in neuroendoscopy have helped in the effective management of this benign condition in a minimally invasive method. Description of a subset of patients with fourth ventricular and juxta fourth ventricular ACs and hydrocephalus who underwent transaqueductal cysto-ventriculostomy with a flexible neuroendoscope was the objective of this study.

**Methods** This study included the data of patients with fourth ventricular and juxta fourth ventricular ACs and hydrocephalus operated between 2008 and 2019. Of 350 intraventricular neuroendoscopic procedures done during the last 11 years, 8 had obstructive hydrocephalus due to fourth ventricular and juxta ventricular arachnoid cyst. Endoscopic transaqueductal cystoventriculostomy and transaqueductal shunt placement was done in all using a flexible neuro-endoscope.

**Results** Patients were aged 20 days to 15 months; in the neonate, the diagnosis was established during routine antenatal screening. Surgical procedure was done using a flexible neuro-endoscope. All improved symptomatically, radiologically and are on regular follow-up to date. One patient had postoperative meningitis, which gradually improved with antimicrobial therapy. None required alternative form of treatment such as shunt or craniotomy and microsurgical excision.

**Conclusion** Endoscopic transaqueductal cysto-ventriculostomy is a safe, effective and minimal invasive modality in the hands of an experienced neurosurgeon for the management of fourth ventricular and juxta ventricular arachnoid cysts.

## Keywords

- ▶ hydrocephalus
- ▶ arachnoid cyst
- ▶ transaqueductal procedures
- ▶ flexible neuro endoscopy
- ▶ minimal invasive.

article published online  
March 27, 2023

DOI <https://doi.org/10.1055/s-0043-1760858>.  
ISSN 2248-9614.

© 2023. Asian Congress of Neurological Surgeons. All rights reserved.

This is an open access article published by Thieme under the terms of the Creative Commons Attribution-NonDerivative-NonCommercial-License, permitting copying and reproduction so long as the original work is given appropriate credit. Contents may not be used for commercial purposes, or adapted, remixed, transformed or built upon. (<https://creativecommons.org/licenses/by-nc-nd/4.0/>)

Thieme Medical and Scientific Publishers Pvt. Ltd., A-12, 2nd Floor, Sector 2, Noida-201301 UP, India

## Introduction

Arachnoid cysts (AC) account for approximately 1% of all intracranial mass lesions,<sup>1</sup> and are more common in the middle cranial fossa followed by posterior cranial fossa.<sup>2</sup> They are often incidental and managed conservatively, but the effective treatment modality still remains controversial. Symptomatic cases are managed by different modalities, i.e., cyst excision, marsupialization of the cyst, cyst fenestration, cystoperitoneal shunt, and endoscopic cysto-ventriculostomy.<sup>3,4</sup>

Neuro-endoscopy achieves the fenestration of cyst less invasively, avoids shunt and open micro surgery-related complication especially in the eloquent areas. We present a series of eight cases managed with endoscopic trans-aqueductal cysto-ventriculostomy of fourth ventricular and juxta fourth ventricular arachnoid cyst, which is sparsely reported.

## Description of Cases

This is a prospective analysis of a subset of patients with fourth ventricular and juxta fourth ventricular ACs and hydrocephalus who underwent transaqueductal cysto-ventriculostomy with a flexible neuro-endoscope. Of 350 intraventricular neuro-endoscopic procedures performed on children between 2008 and 2019, 8 were for fourth ventricular and juxta fourth ventricular arachnoid cysts (► **Table 1**).

Patients were aged 20 days to 15 months; in the neonate (20 days old), the diagnosis was established during antenatal screening; others were aged 6 months or older. Progressive increase in the size of the head with signs of raised intracranial pressure (ICP) was the clinical feature.

Our surgical goal was to decompress the arachnoid cyst and treat the hydrocephalus with a single approach.

## Surgical Procedure

### General Principles

All patients were assessed clinically and radiologically (computed tomography [CT] and magnetic resonance imaging [MRI]), pre- and postoperatively. Preoperative antibiotics and other patient safety issues were followed as per the standard hospital protocol.

All were operated under general anesthesia in supine position ensuring the stability of head. A standard pre-coronal burr hole (Kocher's point) was performed. After incision of the dura, working sheath of the rigid endoscope with obturator was introduced into the lateral ventricle. Initially, a standard third ventriculostomy was done with the help of a rigid endoscope and the stoma was dilated with a Fogarty catheter. The sheath was stationed at the foramen of Monroe. A 4 mm flexible neuroendoscope/3.2 mm video neuroendoscope (Karl Storz) was passed through the sheath,

**Table 1** Clinical features, imaging, and surgical outcomes

S. No.	Age	Clinical features	Imaging	Procedure	Follow-up	Remarks
1	20 d	Diagnosed on antenatal screening	Right cerebello-pontine angle arachnoid cyst with hydrocephalus	ETV + TA CV + CC + RP	10 months	Clinical and radiological improvement
2	8 mo	Progressive increase in head size with raised ICP features	Right cerebello-pontine angle arachnoid cyst with hydrocephalus	ETV + TA CV + RP	16 months	Clinical and radiological improvement
3	8 mo	Progressive increase in head size with raised ICP features	Posterior fossa arachnoid cyst with hydrocephalus	ETV + TA CV + RP	17 months	Clinical and radiological improvement
4	15 mo	Raised ICP features	Posterior fossa arachnoid cyst with hydrocephalus	ETV + TA CV + RP	19 months	Had postoperative meningitis; improved neurologically
5	6 mo	Progressive increase in head size with raised ICP features	Posterior fossa arachnoid cyst with hydrocephalus	ETV + TA CV + RP	10 months	Clinical and radiological improvement
6	13 mo	Raised ICP features	Posterior fossa arachnoid cyst with hydrocephalus	ETV + TA CV		Clinical and radiological improvement
7	8 mo	Progressive increase in head size and raised ICP	Retrocerebellar arachnoid cyst	ETV + TA-TM CV + RP	1 year	Developed subdural hygroma; improved with conservative management
8	12 mo	Progressive increase in head size and raised ICP	Retrocerebellar arachnoid cyst	ETV + TA-TM CV + VPS	2 years	Clinical and radiological improvement

Abbreviations: CC, choroid plexus cauterization; ETV, endoscopic third ventriculostomy; ICP, intracranial pressure; RP, reservoir placement; TA CV, trans aqueductal cysto ventriculostomy; TA-TM CV, trans aqueductal transmagendal cysto ventriculostomy; VPS, ventriculoperitoneal shunt placement.

**Table 2** Comparison between techniques for transaqueductal cysto-ventriculostomy with the existing technique

Parameters	New technique	Existing technique
Instrumentation		
Technical		
Approach	Single precoronal burr hole	Suboccipital craniotomy with cyst marsupialization or a cysto + ventriculoperitoneal shunt
Ventriculostomy	Purely endoscopic technique	Microsurgical technique
Expertise	Requires extensive training	
Complications	Minimal, i.e., subdural hygroma	All craniotomy and/or shunt related issues, pseudomeningocele, cerebrospinal fluid leak
Preoperative/anesthetic	Shorter duration of surgery	Longer duration
Intra-operative	Minimal blood loss	Blood loss in craniotomy is higher
Postoperative	Early recovery and discharge from the hospital	Longer recovery and hospital stay
Advantages	Minimally invasive and access and single burr hole surgery	Conventional surgery and familiar to many
Limitations	Steep learning curve, especially with the use of flexible neuroendoscopy	Cannot address the issue with a single procedure; requirement of craniotomy and ventriculoperitoneal shunt for the cyst and hydrocephalus
Disadvantage	Risk of injury to periaqueductal structures during a transaqueductal procedure	All complications and risks of craniotomy and/or shunt related

with tip maneuvered through the foramen of Monroe and then through the aqueduct into the fourth ventricle. The arachnoid cyst bulging into the fourth ventricle was cauterized, shrunk with a low current flexible monopolar and marsupialized. ► **Table 1** summarizes the clinical features, and procedures done in these patients.

In two (cases 7 and 8), the cyst was retrocerebellar, which required transforaminal, transaqueductal and transmagendal procedures. In one case (case 8), after the cyst marsupialization, a shunt catheter was placed into as endoscopic third ventriculostomy (ETV) could not be performed because of narrow prepontine space. The shunt with multiple fenestration was placed through the aqueduct and foramen of Magendie into the cyst. This catheter in turn was connected to a routine (ventriculo-peritoneal) shunt. The neuroendoscope and sheath were removed after completion of the surgery. In two patients, Ommaya reservoir was placed following the initial procedure, where the opening intracranial pressure was noted to be very high for controlled tapping of CSF in case of postoperative raised pressure or impending leak from surgical site wound.

### Specific Technical Aspects

All surgeries were performed by an experienced neurosurgeon having more than two decades of experience in pediatric neurosurgery, expert in neuroendoscopy, specifically with flexible neuroendoscopy.

All these cases had a naturally dilated aqueduct because of fourth ventricular outlet obstruction and none required an aqueductoplasty. However, this procedure to be avoided undilated aqueduct.

A standard rigid endoscope was used for third ventriculostomy followed by a flexible neuroendoscope/video neuroendoscope (STORZ) with a working channel; standard accessories such as grasping forceps and monopolar cautery were used for the transaqueductal procedure.

A standard rigid scope was used for ETV. Keeping the sheath in place, the flexible neuroendoscope was passed through it.

A flexible neuroendoscope with an outer diameter of 4 mm/3.2 mm with a working channel can easily be maneuvered through the aqueduct with a standard pre-coronal burr hole without causing any damage to the fornix, with special and extra care particularly for the neonate.

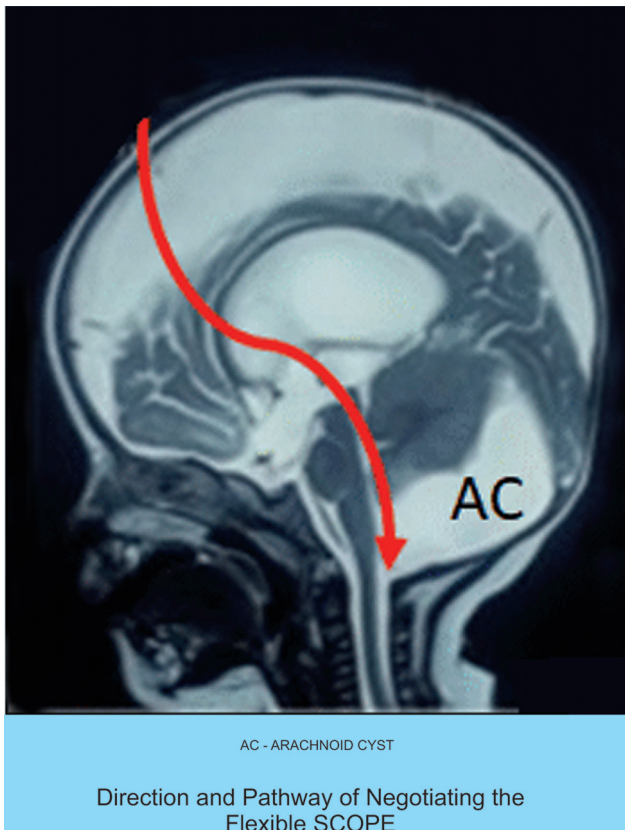
There were no intraoperative complications. All eight patients improved symptomatically, clinically, radiologically and are on regular follow-up to date. One patient had postoperative meningitis, which gradually improved with antimicrobial therapy. None required alternative form of treatment such as shunt or craniotomy and microsurgical excision.

► **Table 2** compares the new technique with the existing technique for transaqueductal cysto-ventriculostomy.

► **Figs. 1–6** depict the important surgical techniques adapted for the new technique.

### Discussion

Arachnoid (leptomeningeal) cysts are benign, space-occupying lesions within the split layers of the arachnoid membrane and are filled with cerebrospinal fluid (CSF).<sup>5,6</sup> Only 5 to 10% of these cysts have been found in the posterior cranial fossa, with the quadrigeminal plate, retro cerebellar area,



**Fig. 1** Direction of videoneuroendoscope/flexible neuroendoscope transventricular, transformaminal, transtentorial into the fourth ventricle.

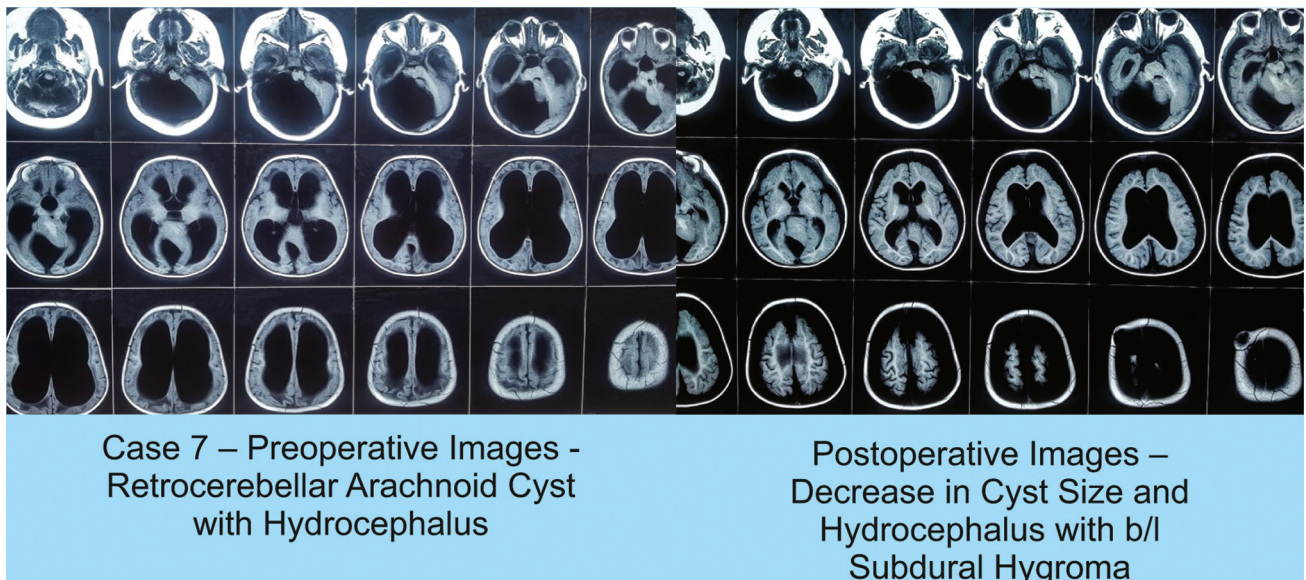
cerebellopontine angle, fourth ventricle and clivus being common sites of occurrence. ACs of the fourth ventricle may present diversely such as normal pressure hydrocephalus,<sup>7</sup> raised ICP, and cerebellar dysfunction, which need immediate surgical intervention. Simple ACs and hydrocephalus

are generally approached conservatively with wait and watch strategy. In our series, all presented with a large cyst and hydrocephalus, manifestation of pressure effects; so, it was pertinent to treat both in a single sitting and single approach procedure.

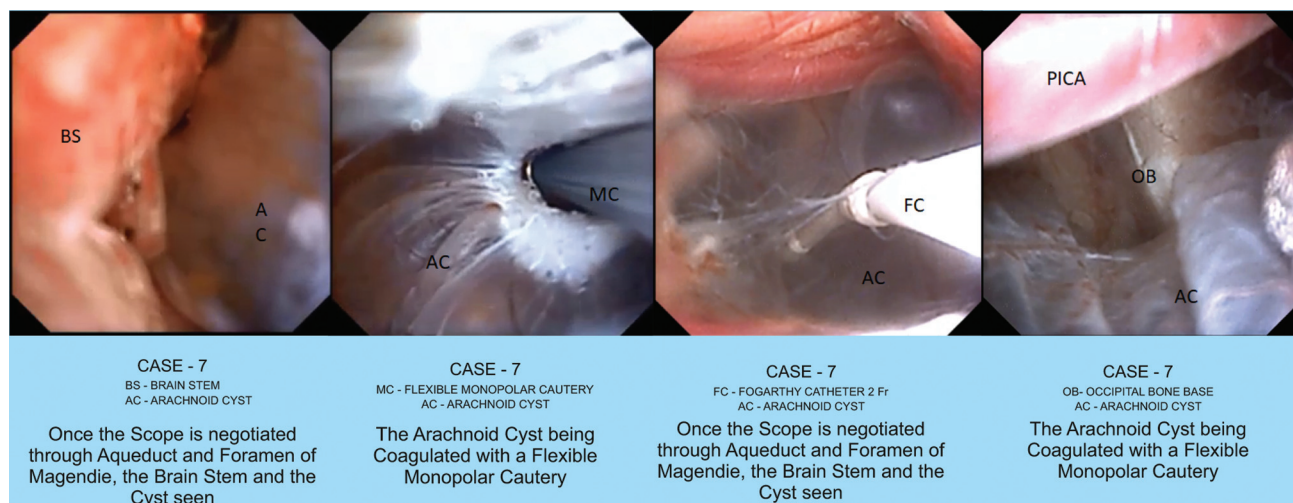
Surgery is indicated to prevent developmental delays associated with asymptomatic patients. Indications and use of cranial neuroendoscopy, a minimally invasive technique, are gradually expanding. Intracranial AC is an attractive target for neuroendoscopy. Flexible neuroendoscope helps to navigate into the remote areas of ventricle, where a rigid endoscope cannot reach without compromising safety. Novel idea of endoscopic transtentorial cysto-ventriculostomy has shifted the difficulty in approach towards an easy, less laborious procedure; video neuroendoscopy, more precise adjunct causes minimal damage to the surrounding structures and reduces associated complications. Success of neuroendoscopy for ACs in infants,<sup>8</sup> has demonstrated the practicality in younger patients, which is proven in the 20 day old neonate in our series.

Craniotomy with micro-surgical approach and shunting are the established modalities of management but are associated with complications such as meningitis, injury to neuro-vascular structures around the fourth ventricle, shunt infection, malfunction, and dependence on shunt. Endoscopy avoids life-long shunt dependence, shunt-related complications and has less chances of recurrence.<sup>9</sup> Flexible neuroendoscope is successfully used for trans lamina terminalis third ventriculostomy, if standard third ventriculostomy could not be achieved safely.<sup>10</sup>

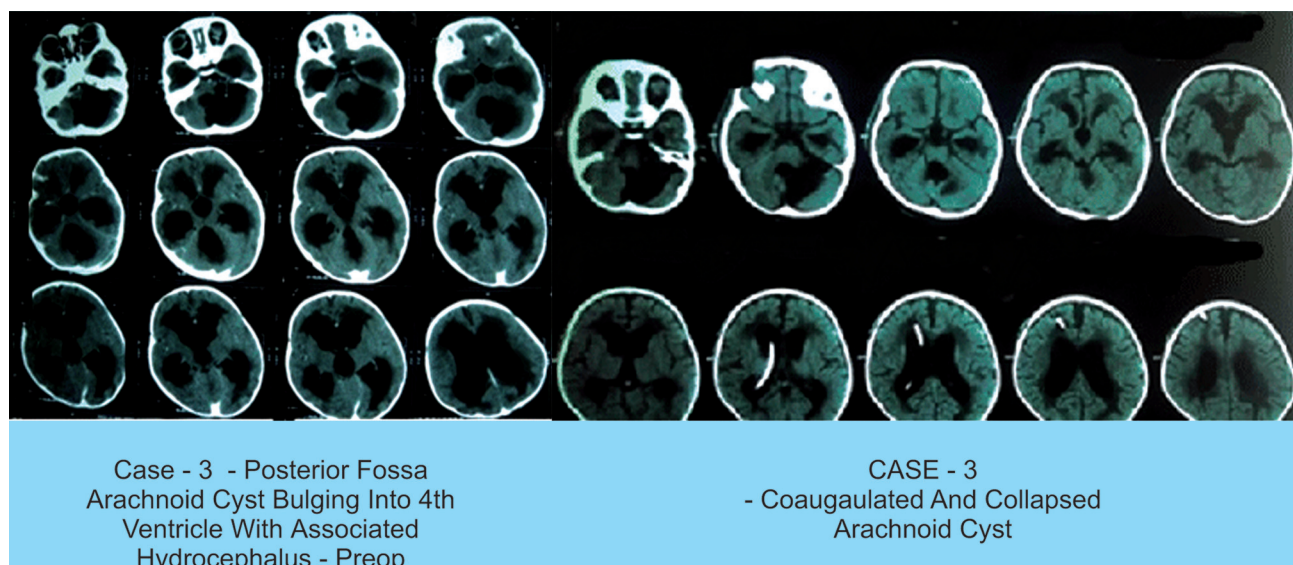
Endoscopic cysto cisternostomies and cysto-ventriculostomies are safe and effective minimally invasive techniques for the treatment of arachnoid cysts.<sup>11</sup> In this series, we used flexible neuroendoscopy effectively in the management of benign fourth ventricular lesions (arachnoid cyst) in a minimally invasive way.



**Fig. 2** Preoperative retrocerebellar arachnoid cyst with hydrocephalus and postoperative changes: decrease in cyst size and hydrocephalus with bilateral subdural hygroma.



**Fig. 3** Visualization of the brain stem and the cyst once the scope is negotiated through aqueduct and foramen of Magendie, coagulation of AC with a flexible monopolar cautery, dilation of the cyst openings with Fogarty catheter and visualization of PICA after coagulation of the cyst in the occipital bone.



**Fig. 4** Posterior fossa arachnoid cyst bulging into the fourth ventricle with associated hydrocephalus (preoperative), well-decompressed arachnoid cyst and ventricles (postoperative).

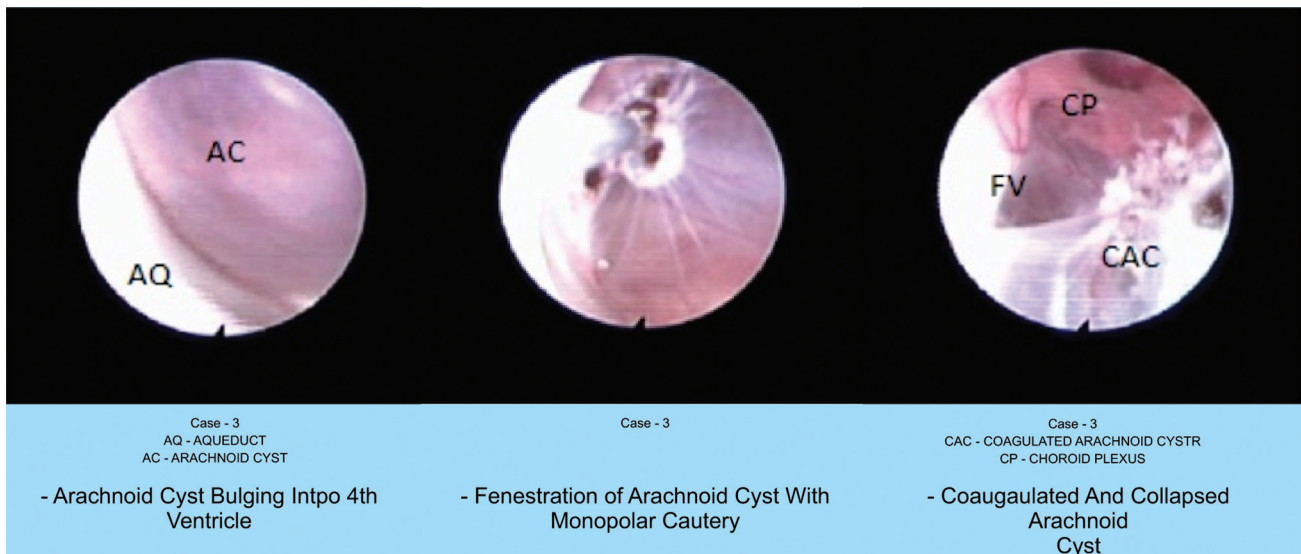
Possible approach for navigating into the fourth ventricle endoscopically are from the third ventricle through the cerebral aqueduct<sup>12</sup> and via the cerebellomedullary cistern through the foramen of Magendie.<sup>13</sup> In our series, location of the cyst caused obstruction of the fourth ventricular outlet, due to which the aqueduct was naturally dilated that allowed easy passage of the flexible neuroendoscope without causing any brain stem dysfunction or any ependymal contusion. In our series, we did not use neuronavigation, which is not possible with flexible neuroendoscope.

Transaqueductal navigation of the fourth ventricle has been considered dangerous. Neuroendoscopic exploration of the fourth ventricle done using rigid endoscopes in the past were associated with many sequelae, particularly disturbances of ocular movement.<sup>14</sup> In our series, all had naturally dilated aqueduct because of fourth ventricular outlet ob-

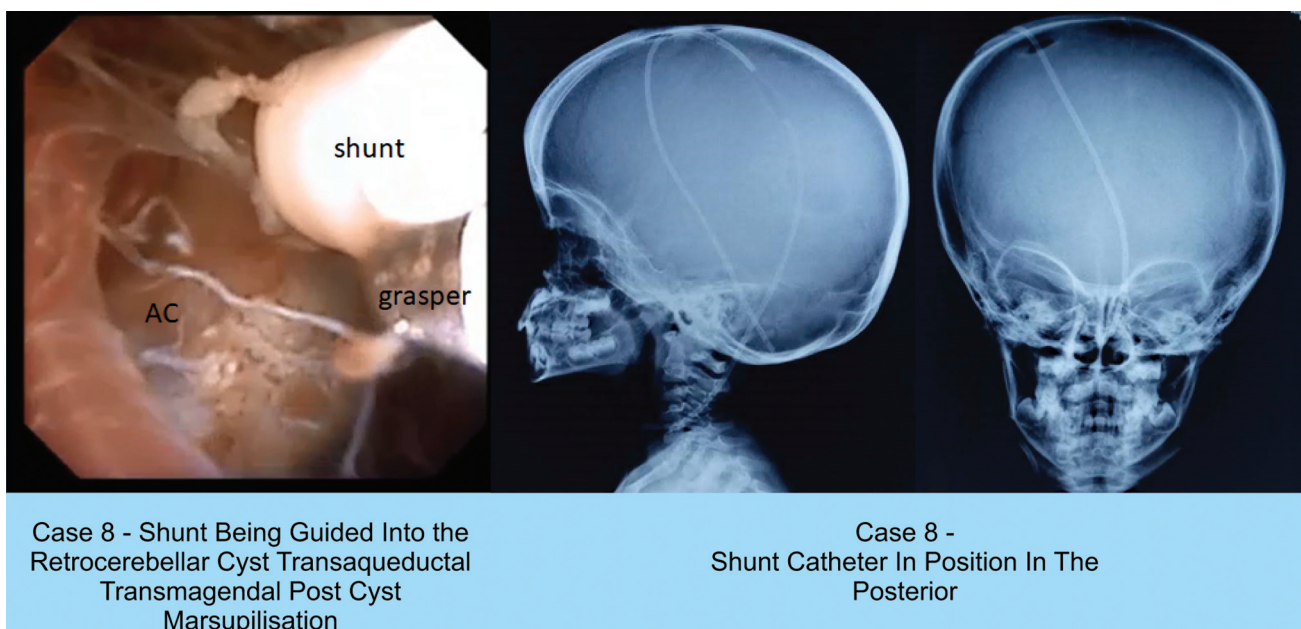
struction and none required an aqueductoplasty. In the absence of dilation, navigating a non-stenotic aqueduct has to be avoided.

Decompression/marsupialization of the fourth ventricular cyst through trans-frontal approach via the third ventricle is reported to be safe, though there is a possibility of transient complications (hemiparesis, ocular ptosis).<sup>15</sup> Approach through sub-occipital craniotomy, transcerebellar endoscopy and fenestration of cyst in the fourth ventricular AC has been reported as a safe procedure.<sup>2</sup>

Fourth ventricle is the common site for neurocysticercosis brain, resulting in CSF blockage. Available reports state success of endoscopic approach via a frontal burr hole in patients with hydrocephalus, dilation of aqueduct, and foramen of Monro.<sup>16</sup> Exploration through the aqueduct for removal of fourth ventricular neurocysticercosis is reported by Suri et al.<sup>17</sup>



**Fig. 5** Arachnoid cyst bulging into the fourth ventricle, fenestration of arachnoid cyst with monopolar cautery, coagulated and collapsed arachnoid cyst.



**Fig. 6** Shunt being guided into the retrocerebellar cyst transaqueductal transmagendal post cyst marsupilization, Shunt catheter in position in the posterior fossa—draining the cyst and the ventricles.

Aspiration of cyst contents of fourth ventricular neurocysticercosis by positioning a rigid endoscope at the opening of cerebral aqueduct is another method described.<sup>18</sup>

Successful endoscopic removal of cysticercal cysts in the fourth ventricle through a midline durotomy between the opisthion and the posterior arch of C-1, advancing toward the fourth ventricle through the foramen of Magendie, avoiding transductal pathway using a flexible endoscope has been documented.<sup>15,19</sup>

Neuroendoscopy offers a different outlook for anatomy of the fourth ventricle. Neuroendoscopy provides a superior and detailed visualization, particularly of the structures located in the inferior triangle compared to microsurgery. But the expe-

rience with trans aqueductal approach for fourth ventricular lesions is limited even among neurosurgeons who are well versed with flexible endoscopes; hence, difficulty and procedure related complications can be expected, though mortality is not reported. We used neuro-endoscopic techniques, which is considered risky by a few, as simple endoscopic procedures will not address both pathologies. We performed ETV for hydrocephalus, which was necessary to release the pressure symptoms; we approached posterior fossa endoscopically as the opening of the cyst (cyst ventriculostomy) to reduce the size of the cyst and pressure on the posterior fossa was required. Endoscopic transaqueductal management of the fourth ventricular AC is rarely reported; a single case of

endoscopic treatment of fourth ventricular AC via the third ventricle has been reported by Martinoni et al<sup>12</sup> and a case of transaqueductal trans-Magenie fenestration of arachnoid cyst in the posterior fossa was described with good outcome by Felliti et al.<sup>20</sup>

Longatti et al<sup>21</sup> who performed 75 endoscopic explorations for spectrum of disorders reported no deaths but caution us about the complications (extreme bradycardia [n=04]; ependymal contusion [n=01]). They identified around 20 anatomical structures, consistently by exploring the fourth ventricle with a flexible neuroendoscope. Hence, endoscopic trans-aqueductal navigation of the fourth ventricle using a flexible endoscope is safe in expert hands,<sup>21,22</sup> emphasizing the need for training.

We suggest performing a minimum of 20 procedures with flexible neuroendoscope to develop a good hand-eye coordination, understand the maneuverability of the scope, and get familiarized with the anatomy of the structures in the third ventricle, aqueduct, and the fourth ventricle.

The utility of neuro-endoscopy and frameless neuro-navigation in exploring the fourth ventricle has been investigated. This combination determines the entry point accurately, helps to plan trajectory, minimize injury to the vital structures and helps surgeon to orient within the cystic cavity for appropriate fenestration sites. Its applicability in cases of small ventricles and while using a rigid scope to target the aqueduct or planning a transaqueductal procedure is the focus area to explore.<sup>23</sup>

These posterior fossa arachnoid cyst cause fourth ventricular outlet obstruction and exert mass effect on posterior fossa structures. Fenestrating the cyst will help not only in decreasing the size of the cyst and mass effect but also the obstructing pathway. By performing an additional successful ETV as a backup, hydrocephalus is also managed and was considered in few patients in our series. Large cysts causing mass effect also have to be taken care of and this cyst decompression may not be enough to treat this hydrocephalus.

Neuroendoscopy confers various advantages; surgery through a small frontal burr hole, less intraoperative time and minimally invasive are a few. It requires learning, experience to navigate the flexible neuroendoscope through the aqueduct without causing injury to brain stem, and vital structures in the floor of fourth ventricle. Intraventricular bleeding when encountered is managed with continuous copious irrigation or transiently raising ICP by opening the inlet for irrigation and closing the outlet under strict hemodynamic monitoring; there were no intraoperative complications including intraoperative bleeding in the fourth ventricle, bradycardia in our study. In our series, there was no mortality; post-operative meningitis was reported in one patient, which was managed appropriately. None of our patients required alternative form of treatment indicating the success of the procedure.

## Conclusion

Transaqueductal neuro-endoscopy helps in managing fourth ventricular and juxta fourth ventricular arachnoid cysts

safely and effectively with minimal invasiveness. It avoids complications that are associated with the conventional modalities of management. Our preliminary experience shows transaqueductal navigation of the fourth ventricle using flexible neuroendoscope is safe in expert hands.

## Conflict of Interest

None.

## Acknowledgment

We thank Dr. M.S. Latha, Rainbow Children's Hospital, for editing and proofreading this manuscript.

## References

- 1 Harsh GR IV, Edwards MSB, Wilson CB. Intracranial arachnoid cysts in children. *J Neurosurg* 1986;64(06):835-842
- 2 Helland CA, Lund-Johansen M, Wester K. Location, sidedness, and sex distribution of intracranial arachnoid cysts in a population-based sample. *J Neurosurg* 2010;113(05):934-939
- 3 Pell MF, Thomas DG. The management of infratentorial arachnoid cyst by CT-directed stereotactic aspiration. *Br J Neurosurg* 1991;5(04):399-403
- 4 Ciricillo SF, Cogen PH, Harsh GR, Edwards MS. Intracranial arachnoid cysts in children. A comparison of the effects of fenestration and shunting. *J Neurosurg* 1991;74(02):230-235
- 5 Miscellaneous tumours cysts metastases. In: Osborn AG, ed. *Diagnostic Neuroradiology*. St Louis, Missouri: Mosby; 1994: 639-642
- 6 Samii M, Carvalho GA, Schuhmann MU, Matthies C. Arachnoid cysts of the posterior fossa. *Surg Neurol* 1999;51(04):376-382
- 7 Korosue K, Tamaki N, Fujiwara K, Matsumoto S. Arachnoid cyst of the fourth ventricle manifesting normal pressure hydrocephalus. *Neurosurgery* 1983;12(01):108-110
- 8 Raju S, Sharma RS, Moini S, Momin J. Neuroendoscopy for intracranial arachnoid cysts in infants: therapeutic considerations. *J Neurol Surg A Cent Eur Neurosurg* 2016;77(04):333-343
- 9 Choi JU, Kim DS, Huh R. Endoscopic approach to arachnoid cyst. *Childs Nerv Syst* 1999;15(6-7):285-291
- 10 Raju S, Ramesh S. Endoscopic third ventriculostomy through lamina terminalis: A feasible alternative to standard endoscopic third ventriculostomy. *Neurol India* 2016;64(01):75-80
- 11 Schroeder HW, Gaab MR, Niendorf WR. Neuroendoscopic approach to arachnoid cysts. *J Neurosurg* 1996;85(02):293-298
- 12 Martinoni M, Toni F, Lefosse M, Pozzati E, Marliani AF, Mascari C. Endoscopic treatment of a fourth ventricle arachnoid cyst via the third ventricle: a case report. *Neurosurgery* 2014;10(Suppl 2):E374-E377, discussion E377-E378. Doi: 10.1227/NEU.0000000000000335
- 13 Matula C, Reinprecht A, Roessler K, Tschabitscher M, Koos WT. Endoscopic exploration of the IVth ventricle. *Minim Invasive Neurosurg* 1996;39(03):86-92
- 14 Gallo P, Szathmari A, Simon E, et al. The endoscopic trans-fourth ventricle aqueductoplasty and stent placement for the treatment of trapped fourth ventricle: long-term results in a series of 18 consecutive patients. *Neurol India* 2012;60(03):271-277
- 15 Anandh B, Mohanty A, Sampath S, Praharaj SS, Kolluri S. Endoscopic approach to intraventricular cysticercal lesions. *Minim Invasive Neurosurg* 2001;44(04):194-196
- 16 Zymberg ST, Paiva Neto MA, Gorgulho AAP, Cavalheiro S. Endoscopic approach to fourth ventricle cysticercosis. *Arq Neuropsiquiatr* 2003;61(2A):204-207 [http://www.scielo.br/scielo.php?script=sci\\_arttext&pid=S0004-282X2003000200009&lng=en](http://www.scielo.br/scielo.php?script=sci_arttext&pid=S0004-282X2003000200009&lng=en) 10.1590/S0004-282X2003000200009
- 17 Suri A, Goel RK, Ahmad FU, Vellimana AK, Sharma BS, Mahapatra AK. Transventricular, transaqueductal scope-in-scope endoscopic

- excision of fourth ventricular neurocysticercosis: a series of 13 cases and a review. *J Neurosurg Pediatr* 2008;1(01):35–39
- 18 Proaño JV, Madrazo I, Avelar F, López-Félix B, Díaz G, Grijalva I. Medical treatment for neurocysticercosis characterized by giant subarachnoid cysts. *N Engl J Med* 2001;345(12):879–885
- 19 Bergsneider M. Endoscopic removal of cysticercal cysts within the fourth ventricle. Technical note. *J Neurosurg* 1999;91(02):340–345
- 20 Feletti A, Alicandri-Ciufelli M, Pavesi G. Transaqueductal trans-Magendie fenestration of arachnoid cyst in the posterior fossa. *Acta Neurochir (Wien)* 2016;158(04):655–662
- 21 Longatti P, Basaldella L, Feletti A, Fiorindi A, Billeci D. Endoscopic navigation of the fourth ventricle. Technical note and preliminary experience. *Neurosurg Focus* 2005;19(06):E12. Doi: 10.3171/foc.2005.19.6.13
- 22 Longatti P, Fiorindi A, Feletti A, D'Avella D, Martinuzzi A. Endoscopic anatomy of the fourth ventricle. *J Neurosurg* 2008;109(03):530–535. Doi: 10.3171/JNS/2008/109/9/0530
- 23 Karabatsou K, Hayhurst C, Buxton N, O'Brien DF, Mallucci CL. Endoscopic management of arachnoid cysts: an advancing technique. *J Neurosurg* 2007;106(6, Suppl)455–462