



# Bioengineering an Osteoinductive Treatment for Bone Healing Disorders: A Small Animal Case Series

William G. Marshall<sup>1,2</sup> Cristina Gonzalez-Garcia<sup>2</sup> Sara Trujillo<sup>2</sup> Andres Alba-Perez<sup>2</sup> Peter Childs<sup>2</sup>  
David W. Shields<sup>2,3</sup> Andrew Tomlinson<sup>4</sup> Rob Pettitt<sup>4</sup> Barbro Filliquist<sup>5</sup> Po-Yen Chou<sup>5</sup>  
Matthew J. Dalby<sup>2</sup> Sandra A. Corr<sup>1</sup> Manuel Salmeron-Sanchez<sup>2</sup>

<sup>1</sup> Small Animal Hospital, School of Veterinary Medicine, University of Glasgow, United Kingdom

<sup>2</sup> Centre for the Cellular Microenvironment, University of Glasgow, United Kingdom

<sup>3</sup> Queen Elizabeth University Hospital, Glasgow, United Kingdom

<sup>4</sup> Small Animal Teaching Hospital, School of Veterinary Science, University of Liverpool, United Kingdom

<sup>5</sup> Department of Surgical and Radiological Sciences, School of Veterinary Medicine, University of California Davis, California, United States

**Address for correspondence** Manuel Salmeron-Sanchez, PhD, Centre for the Cellular Microenvironment, University of Glasgow, Glasgow, G12 8LT, Scotland, United Kingdom  
(e-mail: Manuel.Salmeron-Sanchez@glasgow.ac.uk).

VCOT Open 2023;6:e41–e51.

## Abstract

The aim of this article was to study clinical and radiographic outcomes following treatment of bone healing disorders with a novel osteoinductive system that utilizes poly (ethyl acrylate), fibronectin and an ultra-low concentration of recombinant human bone morphogenetic protein-2. A case series of nine dogs and two cats were treated, and clinical records and radiographs were reviewed. Radiographs were scored by two blinded observers using the modified Radiographic Union Score for Tibial Fractures. Long-term follow-up was obtained using the Canine Orthopaedic Index and Feline Musculoskeletal Pain Index. Follow-up data were available for 11 treatments (10 cases). Complications: three minor, three major, one catastrophic (non-union requiring amputation). Lameness median 320 (range: 42–1,082) days postoperatively: ‘sound’ (three cases), ‘subtle’ (two), ‘mild’ (three), ‘moderate’ (one), and ‘non-weightbearing’ (one). The attending clinician judged 9 of 11 treatments achieved radiographic union; modified Radiographic Union Score for Tibial Fractures observers 1 and 2 agreed with the clinician in 8/9 and 5/9 treatments respectively. Long-term Canine Orthopaedic Index scores for five dogs median 650 (range: 544–1,724) days postoperatively: 15/64 (median) for four dogs with acceptable outcomes, 30/64 in one dog with a poor outcome. Feline Musculoskeletal Pain Index scores for two cats 433 and 751 days postoperatively: 48/60 and 60/60. Eight of 10 cases were sound or showed subtle or mild lameness in the short- or long-term, and radiographic union occurred in the majority of treatments.

## Keywords

- ▶ bioengineering
- ▶ bone morphogenetic protein
- ▶ cats
- ▶ dogs
- ▶ fracture healing

received  
February 4, 2022  
accepted after revision  
January 5, 2023

DOI <https://doi.org/10.1055/s-0043-1762900>.  
ISSN 2625-2325.

© 2023. The Author(s).  
This is an open access article published by Thieme under the terms of the Creative Commons Attribution License, permitting unrestricted use, distribution, and reproduction so long as the original work is properly cited. (<https://creativecommons.org/licenses/by/4.0/>)  
Georg Thieme Verlag KG, Rüdigerstraße 14, 70469 Stuttgart, Germany

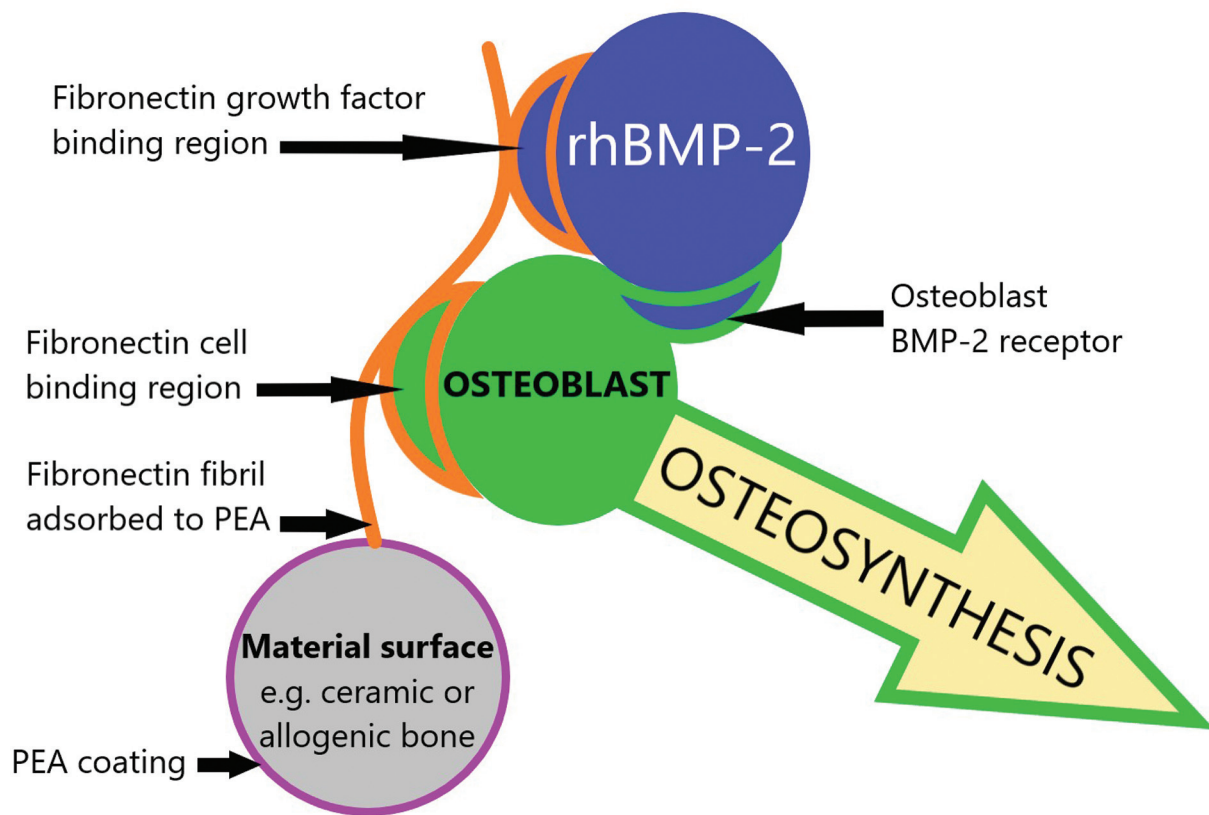
## Introduction

Fractures in an estimated 3.4 to 4.6% of dogs and cats fail to heal.<sup>1–3</sup> Recombinant human bone morphogenetic protein-2 (rhBMP-2) is an osteoinductive growth factor used to treat fracture non-union in dogs, cats and humans.<sup>4–9</sup> In veterinary reports, collagen sponges,<sup>4,6</sup> ceramics,<sup>5</sup> or combinations thereof,<sup>7</sup> were soaked in rhBMP-2 of concentration 200 µg/mL,<sup>6,7</sup> 500 µg/mL<sup>5</sup> or 1,500 µg/mL,<sup>4</sup> and implanted at the injury site. Schmoekel and colleagues<sup>8</sup> used 600 µg/mL rhBMP-2 in a fibrin matrix. To put these concentrations in perspective, in one experimental study 300 ng/mL (0.3 µg/mL) represented a physiological concentration of rhBMP-2.<sup>10</sup> When rhBMP-2 is delivered using a collagen sponge, the high initial concentration declines rapidly,<sup>11,12</sup> and in human tibial fractures, superior clinical outcomes were seen at 1,500 µg/mL rhBMP-2, versus 750 µg/mL, suggesting a high concentration is needed.<sup>9</sup> The incorporation of calcium phosphate into a carrier material prolongs the rhBMP-2 retention profile, but high concentrations are still required.<sup>12</sup>


Complications such as implant failure, infection, incisional swelling and discharge have been reported in animals treated with rhBMP-2.<sup>5,8</sup> In humans, serious adverse effects are well recognized, including exuberant or ectopic bone formation causing neuroforaminal stenosis following vertebral fusion.<sup>13</sup> In fractures, surgical site infection and ectopic

bone formation have been reported, and the latter can require surgical removal.<sup>14</sup> Reducing the dose of rhBMP-2 and preventing its diffusion from the treatment site may reduce the incidence and severity of adverse effects.<sup>13</sup>

A novel osteoinductive system is under development. It utilizes rhBMP-2, poly (ethyl acrylate) (PEA) and the protein fibronectin (►Fig. 1). Poly (ethyl acrylate) is a non-toxic polymer used in paints, and as a binder for textiles.<sup>15</sup> Material surfaces, including the surfaces of osteoconductive bone grafts, can be coated with PEA using plasma-enhanced chemical vapour deposition<sup>16</sup> (►Fig. 2). Fibronectin is a component of the extracellular matrix, necessary for normal development and wound healing. In body tissues, fibronectin forms a network in a process called fibrillogenesis that is triggered by cells.<sup>17</sup> Fibrillogenesis can also be driven chemically using polymeric materials such as PEA.<sup>18</sup> PEA interacts with fibronectin through its hydrophobic surface, promoting fibronectin unfolding and assembly, exposing cell integrin (FNIII9–10) and growth factor binding (FNIII12–14) domains.<sup>18</sup> The rhBMP-2 binds to fibronectin assembled on the surface of PEA, which allows its efficient presentation to bone-forming cells.<sup>16</sup> Importantly, rhBMP2 binds to fibronectin next to the integrin binding site which promotes integrin-growth factor receptor synergistic signalling, enhancing cell response.<sup>19</sup> By exploiting the unique interaction between PEA and fibronectin, the concentration of rhBMP-2 can be ultra-low: in a murine experimental study efficacy



**Fig. 1** Schematic of a novel osteoinductive system: An osteoconductive material (grey circle) is coated with poly (ethyl acrylate) (PEA, purple ring). Fibronectin (orange line) is adsorbed to PEA and its cell and growth factor binding regions are exposed. Recombinant human bone morphogenetic protein-2 (rhBMP-2) is bound by fibronectin. When introduced to a fracture site, the fibronectin presents rhBMP-2 to bone forming cells, inducing osteosynthesis.



**Fig. 2** Custom-made plasma chamber used to coat hydroxyapatite/tricalcium phosphate granules with the polymer poly (ethyl acrylate) by plasma-enhanced chemical vapour deposition (A). Granules in solution during adsorption of fibronectin and then recombinant human bone morphogenetic protein-2 (B).

was demonstrated at 50 ng/mL, and 50 µg/mL has been used in a canine clinical case.<sup>16,20</sup>

This osteoinductive system was used to treat bone healing disorders in a series of companion animals, and we aim to describe the radiographic and clinical outcomes. The first canine case has previously been reported, with a slightly different methodology, alongside experimental validation of the system.<sup>16,20</sup> Further follow-up data on that first case are given here, alongside new information on other cases.

## Materials and Methods

### Case Selection

Canine and feline cases with a bone healing disorder or complication were treated where, considering prognosis and standard treatment costs, amputation was the only other option. Any case with a complication following fracture management or arthrodesis was considered.

### Preparation of Graft Materials

Hydroxyapatite/tricalcium phosphate (HA/TCP) composite granules 1 to 4 mm in length (Ceramisys Reprobone, Sheffield, UK) were selected as a suitable osteoconductive material for delivery of the osteoinductive system. These synthetic HA/TCP granules were more readily available than the allogenic bone chips used in the first case reported.<sup>16</sup> The granules were coated with PEA using plasma-enhanced chemical vapour deposition. Approximately 2cc of HA/TCP granules were placed into a custom-made capacitively coupled plasma chamber (University of Glasgow, ► Fig. 2A), in a glass petri dish. Air plasma was generated using 100 W of power, applied at a radio frequency of 13.56 MHz, for 5 minutes. Ethyl acrylate monomer (Sigma-Aldrich, Merck KGaA, Darmstadt, Germany) was added to the chamber and plasma polymerization performed at 100 W for 15 minutes, coating the HA/TCP granules with an ultra-thin, invisible layer of PEA. Pressure within the plasma

chamber was maintained manually at 1.8 to 2.10<sup>-1</sup> mbar. The granules were then divided between Vacutainer collection tubes, 0.2 to 0.3 g in each, and sterilized using ethylene oxide. The rhBMP-2 (Inductos, Medtronic Biopharma B.V., Earl Bakkenstratt 10, 6422 PJ Heerlen, the Netherlands) was reconstituted with sterile water according to the manufacturer's instructions to produce a 1,500 µg/mL solution. Aliquots of 20, 50, and 100 µL were stored frozen at -80°C. On the day of treatment, human fibronectin from blood plasma (R&D Systems, Minneapolis, Minnesota, United States) and rhBMP-2 were sequentially adsorbed onto the PEA coated HA/TCP granules (► Fig. 2B). *Adsorption protocol:* under aseptic (cell culture) conditions, 2 mL of Dulbecco's Phosphate Buffered Saline (DPBS, ThermoFisher Scientific, Waltham, Massachusetts, United States) was added to a Vacutainer containing PEA coated HA/TCP granules. A vacuum was created by evacuating the air using a needle and syringe to allow diffusion of saline through the pores of the granules. Fibronectin was added to make a 20 µg/mL solution and was adsorbed onto the granules for 1 hour at room temperature. The fibronectin solution was removed, and the granules washed with 2 mL of DPBS. A final 2 mL of DPBS was added, followed by rhBMP-2, creating a 50 µg/mL solution. The rhBMP-2 was adsorbed for a minimum of 1 hour, the granules remained in the solution until used in the operating theatre. A single vacutainer of granules was used for each clinical case, and the volume implanted was dictated by bone defect size.

### Operative Techniques, Clinical and Radiographic Follow-Up

General anaesthesia was induced with propofol or alfaxalone and maintained with isoflurane, and cefuroxime (20 mg/kg) was administered intravenously preoperatively and intraoperatively every 90 minutes. A local anaesthetic nerve block or epidural was performed at the discretion of the anaesthetist. In each case a standard open approach was made to the

injury site and a bacteriology swab taken at the discretion of the surgeon. Fracture surfaces were debrided of fibrous tissue and necrotic bone using rongeurs, until small bleeding osseous vessels were visible (paprika sign). An air driven burr was applied to joint surfaces to be arthrodesed, to expose subchondral bone. Osteostixis of fracture or joint surfaces was performed using a drill bit or K-wire. A radial mal-union correction required a closing wedge osteotomy and ulnar osteotomy, performed with an oscillating saw. All bones were stabilized using standard internal or external skeletal fixation techniques. The HA/TCP granules (as prepared above) were then removed from the rhBMP-2 solution in sterile fashion. Any additional bone graft was mixed with the granules before implantation (►Fig. 3). Soft tissues were closed routinely, and postoperative analgesia provided according to current standard of care. Standard orthogonal radiographs were taken under general anaesthesia postoperatively, and thereafter under sedation at clinically appropriate intervals, following clinical reassessment.

### Clinical Record and Radiographic Review

Complications were categorized according to Cook and others.<sup>21</sup> The final subjective lameness assessment was recorded: sound = no visible lameness; subtle = barely perceptible lameness; mild = consistently weight-bearing but obvious lameness; moderate = consistently weight-bearing but very obvious lameness; non-weightbearing. Bone defect size was taken from the surgical report or measured on a radiograph. The author's (W.G.M.) assessment of the final radiographs was simplified to 'union', 'progressing' if the implants appeared stable and there was evidence of callus formation, or 'non-union'. Two orthopaedic surgeons (B.F. and P.Y.C.), blinded to patient and radiographic details, scored the final set of radiographs using the modified Radiographic Union Score for Tibial Fractures<sup>22</sup> (mRUST). The mRUST scores each of the four cortices: 1 = fracture line,

no callus; 2 = callus visible; 3 = bridging callus; 4 = remodelled, no fracture line. The question 'Is the fracture healed?' (yes or no) is also answered. The question 'Is there evidence of exuberant or ectopic bone formation?' was added as this is a known complication of rhBMP-2.<sup>13,14</sup>

### Long-Term Owner Reported Outcome

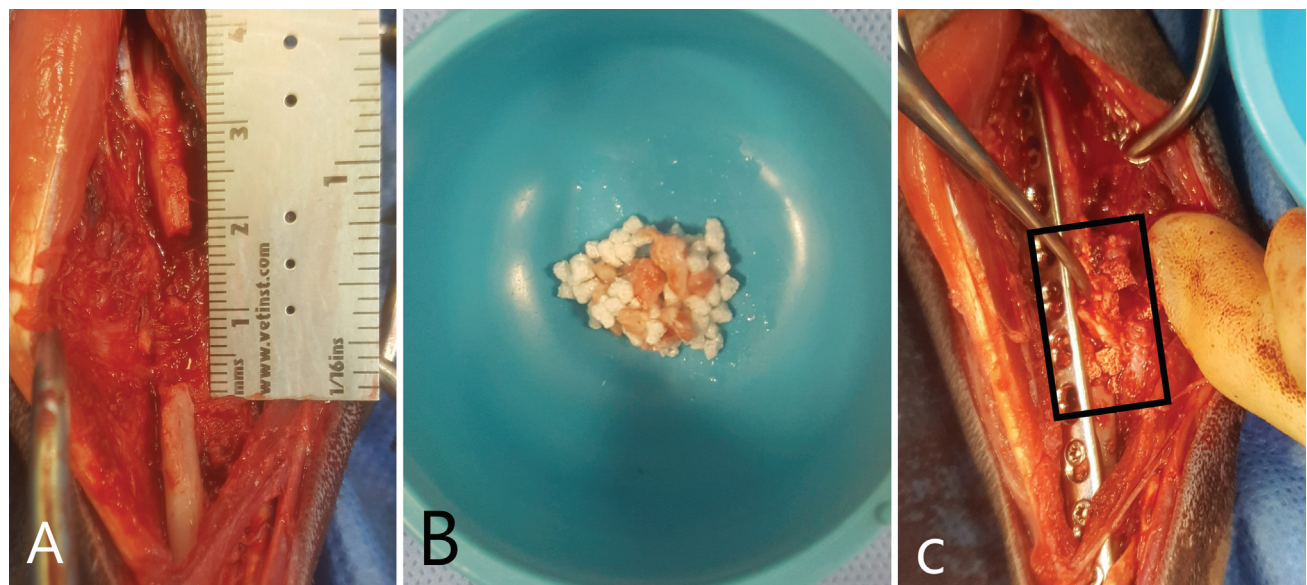
Animal owners were contacted by telephone more than a year after treatment and asked to complete the Canine Orthopaedic Index (COI, <https://www.vet.upenn.edu/research/clinical-trials-vcic/our-services/pennchart/canine-orthopaedic-index>) or the Feline Musculoskeletal Pain Index (FMPI; <https://novacatclinic.com/wp-content/uploads/2016/07/FMPI-V10-w-instructions.pdf>). The COI was expressed as score/possible score, assigning scores to each answer as per Balzer and Owen<sup>23</sup>: 'none', 'no problems', 'never', or 'excellent' = 0. 'Mild', 'mild problems', 'rarely', or 'very good' = 1. 'Moderate', 'moderate problems', 'occasionally', or 'good' = 2. 'Severe', 'severe problems', 'frequently', and 'fair' = 3. 'Extreme', 'extreme problems', 'constantly', and 'poor' = 4. The COI was scored out of 64. The FMPI results were expressed as score/possible score. The highest possible score was 68; therefore, 68/68 reflected normal function in cats. Questions answered with 'not applicable' were not scored.

### Histopathology

In one case in which the limb was amputated, sections were examined following staining with haematoxylin and eosin, von Kossa and Masson's trichrome.

### Results

Twelve treatments were performed in 11 cases. One dog (case 6/6) developed atlanto-axial subluxation and was euthanized 28 days after treatment; therefore, data on that case are not presented. The details of 11 treatments



**Fig. 3** Atrophic non-union of the radius in a cat (case 3) with a 16 mm defect (A). Autogenous graft materials were mixed with the osteoinductive system (B), and implanted within the defect following internal fixation (C, graft materials within black rectangle).

performed in 10 cases are given in ►Tables 1 to 4. The first clinical reassessment was 6 to 30 days postoperatively (median: 13 days). The final subjective lameness assessment was made (by W.G.M. or A.T. in case 5) between 42 and 1,082 days postoperatively (median: 320 days). Long-term COI or FMPI scores were obtained for seven cases between 433 and 1,724 days postoperatively (median: 650 days; ►Table 5). The four dogs that achieved bone union had a median COI score of 15/64. The affected limb of case 9 was amputated 544 days postoperatively due to persistent non-union. Histology and bacteriology of the non-union site were performed: A predominantly fibrocartilaginous reparative process was present with fibrous trabeculae delimiting small cavities containing low numbers of birefringent particles (interpreted as HA/TCP granules). Multinucleated cells (interpreted as foreign body giant cells) were associated with the fibrous trabeculae and occasionally contained phagocytosed birefringent particles. Aerobic and anaerobic cultures of a bacteriology swab were negative.

## Discussion

Non-union is the classic indication for rhBMP-2 treatment in dogs,<sup>5-7</sup> but it has also been used for arthrodesis,<sup>8</sup> delayed union and simply difficult fracture cases where complications were anticipated.<sup>4</sup> The cases of implant failure and peri-implant fracture treated here may have healed with revision of the fixation alone, but this novel adjunctive treatment had the potential to accelerate bone healing and was offered in the best interest of the animals.

This case series represents an early clinical translation of the osteoinductive system, and to our knowledge the lowest concentration of rhBMP-2 used clinically. Though there is evidence of its safety and efficacy,<sup>16</sup> it was felt prudent to use this system to supplement, rather than replace, established treatments. Eight treatments therefore included autogenous cancellous bone graft. In three treatments, local bone fragments provided some additional graft material. Human surgeons have taken a similar approach with rhBMP-7 in scaphoid fracture non-union, where adding a high dose (3,500 µg) to autograft decreased healing time from 9 to 4 weeks.<sup>24,25</sup> It should be noted that rhBMP-7 is no longer commercially available for clinical use.

There were three minor complications and three major complications that were successfully managed. In case 9, an olecranon non-union failed to heal and the limb was amputated. At revision of the fixation, an intraoperative bacteriology swab was positive for *Staphylococcus* spp. Histopathology performed post-amputation was consistent with a fibrous non-union, but no neutrophils were observed. Although a bacterium was cultured at the revision, it is impossible to know if infection caused the persistent non-union as the histopathology does not support that. One previous case series which used 500 µg/mL rhBMP-2 in a compression resistant matrix reported minor and major complications in eight and two out of 11 treatments respectively, and all bones healed.<sup>5</sup> Long-term (> 1 year) follow-up data for six cases treated using this system were recently published—all bones healed with

normal architecture (shown by computed tomography) and all dogs were weight bearing on the affected limb.<sup>26</sup> Another series utilizing 600 µg/mL rhBMP-2 in a fibrin matrix reported 10% failure of bone healing (two arthrodesis and two non-unions from 41 treatments).<sup>8</sup> The 9% rate of failure of healing reported here (one of 11 treatments) is comparable, using a rhBMP-2 concentration of only 50 µg/mL. In one human study, only 65 of 142 open tibial fractures treated with 1,500 µg/mL rhBMP-2 in a collagen sponge healed without the need for a secondary intervention.<sup>9</sup>

In humans, infection is an important cause of non-union and thorough preoperative testing is recommended.<sup>27</sup> Five deep tissue samples from the bone-implant interface should be submitted for bacteriology and histology.<sup>28</sup> In our case series, preoperative bacteriology testing was performed in cases of non-union, except in case 2 where the original surgery had been performed more than a year prior, the implants had been removed and there was no clinical or radiographic evidence of infection. Preoperative bacteriology was not performed in more straightforward cases (e.g., 7 and 10), but the positive intraoperative culture results do not support that decision. In case 3, a preoperative deep tissue sample was negative for bacterial growth, as was an intraoperative swab; however, the explanted bone plate cultured *Staphylococcus* spp. and *Escherichia coli*. A (single) preoperative deep tissue sample was submitted for histology and did not show any evidence of inflammation. Histologically, the complete absence of neutrophils at a non-union site is highly predictive of aseptic non-union, whereas more than five neutrophils per high power field is strongly predictive of infection.<sup>28</sup> In case 3, active infection seems unlikely based on the histology, and despite the positive culture the clinical outcome was excellent.

Eight of 10 cases were sound or showed subtle or mild lameness in the short- or long-term. Unblinded lameness assessments are subject to bias, so this should be interpreted with caution, alongside the other data. Because of the diversity of cases, it is difficult to draw comparisons with other publications, but the outcomes were perhaps not as positive as those reported by Massie and colleagues, where 9 of 11 limbs regained full function.<sup>5</sup>

One previous retrospective review of canine tibial fractures used mRUST scoring to determine the time to union.<sup>29</sup> It is considered a reliable way of assessing fracture healing in the human tibia, humerus, forearm and femur<sup>21,30-32</sup> and in tarsal arthrodesis.<sup>33</sup> Reliability is greater with interlocking nail or external skeletal fixation, compared with bone plates, which can obscure the cortex.<sup>30</sup> In 10 of the 22 scores given here, the presence of bone plates prevented assessment of at least one cortex so we agree with Misir and colleagues<sup>30</sup> that plate fixation imposes limitations on the mRUST. However, in eight out of nine treatments mRUST observer 1 agreed with the attending clinician that the fractures had healed. Observer 2 agreed with the attending clinician that the fractures had healed in five out of nine treatments, though the high mRUST scores given in three treatments are perhaps at odds with the subjective impression that the fracture had *not* healed. The three cases in question had mRUST scores of 12 or

**Table 1** Cases treated: signalment, condition, prior treatment and chronicity

Case/ Treatment	Species	Breed	Sex	W (kg)	Age (y)	Condition	Prior surgeries	Prior stabilization method	Prior bone graft	Days post-injury or first surgery
1/1	Canine	Munsterländer	FN	22	2.67	Humeral diaphysis non-union	2	ORIF revised to modified type 2 ESF	At ESF revision, cancellous autogenous	229
2/2	Canine	Mixed	FN	7.5	3.58	Olecranon non-union	1	ORIF	Demineralized bone matrix	351
3/3	Feline	DSH	MN	3.9	1.75	Radial diaphyseal non-union	1	ORIF	None	178
4/4	Canine	Labrador	MN	38.9	3.75	Intertarsal instability post-PTA	1	Type 2 transarticular ESF, calcaneotibial screw	None	576
5/5	Canine	GSD	M	51	9.75	PCA implant failure/failure to fuse	3	ORIF	Demineralized bone matrix and cancellous allograft	819
7/7	Canine	Yorkshire Terrier	MN	4.8	5.82	Diaphyseal femoral fracture implant failure	1	ORIF	None	14
8/8	Feline	Mixed	MN	6	1.69	Diaphyseal tibial fracture delayed union	1	Type 1A ESF	None	50
9/9	Canine	Chihuahua	MN	1.7	1.96	Olecranon intraarticular non-union	0	None	None	72
10/10	Canine	Chihuahua	M	3.3	0.77	Distal radius and ulna peri-implant fracture	1	ORIF	None	25
11/11	Canine	Yorkshire Terrier	M	4	11.07	Diaphyseal tibial fracture implant failure	1	ORIF	None	23
9/12	Canine	Chihuahua	MN	1.7	2.07	Distal radius and ulna malunion	1	ORIF	None	429

Abbreviations: DSH, domestic short-haired; ESF, external skeletal fixator; F, female; GSD, German Shepherd Dog; M, male; N, neutered; ORIF, open reduction and internal fixation; PCA, pancarpal arthrodesis; PTA, pantarsal arthrodesis; W, weight.

**Table 2** Bone defect, bacterial culture, antibiotic medications, additional bone grafting and fixation

Case/Treatment	Bone defect	Bacterial culture at treatment (and preoperatively, if performed)	Postoperative anti-biomatic medications	Bone graft and site	Fixation
1/1	Yes 20 mm	Staphylococcus ( <i>Staphylococcus</i> )	Cephalexin 300 mg BID 4 months	Cancellous, contralateral HH	ORIF orthogonal 10-hole LCPs 3.5 and 2.7 mm
2/2	Yes 4mm	Negative	Cephalexin 150 mg BID 5 days	Cancellous, ipsilateral HH	ORIF 7-hole 2.4 mm LCP
3/3	Yes 16 mm	Negative (swab) Staphylococcus and <i>E. coli</i> (bone plate) (negative)	Potentiated amoxicillin 75 mg BID 1 week	Ipsilateral iliac crest and HH	ORIF LCP 12-hole 2.0 mm
4/4	No	<i>E. coli</i> (CT screw site) ( <i>E. coli</i> )	Cephalexin 500 mg BID 5 days then 600 mg BID 10 days	Contralateral HH	ORIF 3.5/2.7 DCP medial PTA plate and 3.5 mm calcaneotibial screw
5/5	No	<i>Pseudomonas</i> spp. (negative)	Marbofloxacin 120 mg SID 8 weeks, trimethoprim sulphamide 120/600 mg BID 4 weeks	Ipsilateral HH	ORIF 3.5/3.5 mm PCA dorsally and 2.7/2.0 mm PCA medially
7/7	Yes – 9 mm at caudal cortex	Staphylococcus	Cephalexin 125mg PO BID 19 days	Morselized free cortical fragment	ORIF IM pin (1.1 mm K-wire) and 10-hole 2.0 mm LCP
8/8	Yes – 16 mm lateral cortex	Negative	Cephalexin 125 mg PO BID 5 days	Morselized free cortical fragment	ORIF IM pin (1.6mm K-wire) and 14-hole 2.4 mm LCP
9/9	Yes – 2 mm	Negative	Cephalexin 25 mg BID 5 days	Cancellous, ipsilateral HH	ORIF 1.5/2.0mm LCP 5 hole
10/10	No	<i>E. coli</i>	Cephalexin 75 mg BID 19 days	None	ORIF 2.0mm LCP T-plate
11/11	Yes – 19 mm lateral cortex	Negative	Cephalexin 100 mg BID 5 days	Cancellous, contralateral HH	ORIF orthogonal 1.5/2.0 mm LCPs 10 and 7 hole
9/12	No	Negative	Cephalexin 25 mg BID 5 days	Morselized radial wedge	3 mm closing wedge radial osteotomy, ulnar osteotomy, ORIF 2.0 mm LCP

Abbreviations: BID, twice daily; DCP, dynamic compression plate; *E. coli*, *Escherichia coli*; HH, humeral head; IM, intramedullary; LCP, locking compression plate; ORIF, open reduction and internal fixation; PCA, pancarpal arthrodesis; PO, per os; PTA, pantarsal arthrodesis; SID, once daily.

**Table 3** Subjective lameness outcome, complications and revision surgery

Case/ Treatment	FLA (days)	FLA (grade)	Recorded complications and revision surgery
1/1	1,082	Moderate	<i>Minor</i> – moderate postoperative swelling for one week, reduced range of movement in the shoulder and elbow
2/2	973	Subtle	None
3/3	91	Sound	<i>Minor</i> – swelling of foot for three days
4/4	650	Subtle	<i>Major</i> – calcaneotibial screw breakage and gastrocnemius tendon pain – tenotomy and screw removal 338 days postoperative. Draining sinus over medial plate, plate removal 656 days postoperative
5/5	95	Sound	<i>Major</i> – incisional infection managed with oral antibiotic medications. Pelvic limb ataxia due to suspected degenerative myelopathy may have impacted on gait analysis
7/7	42	Mild	None
8/8	42	Mild	<i>Minor</i> – swelling of the foot for 6 days, loss of alignment in frontal plane – increased proximal tibial valgus from 3 to 13 degrees
9/9	544	NWB	<i>Catastrophic</i> – implant failure at 222 days, revised with 6-hole 1.5/2.0 LCP. Culture at revision – <i>Staphylococcus</i> . Antibiotic medications – cephalixin 25mg BID 5 days then 50 mg BID 20 days. Non-union treated by amputation at 544 days
10/10	545	Mild	<i>Major</i> – implant failure 31 days postop, revised to transarticular ESF Type 1B. Re-fracture through ESF hole 237 days post treatment, repaired with 11-hole 2.0mm LCP
11/11	47	Sound	None
9/12	544	NWB	None related to this treatment but amputation performed due to concomitant olecranon non-union

Abbreviations: BID, twice daily; ESF, external skeletal fixator; FLA, final lameness assessment; LCP, locking compression plate; NWB, non-weight-bearing.

**Table 4** Final radiographic outcomes

Case/ Treatment	Radiographic reassessments (d)	Clinician opinion	mRUST observer 1	Healed? Yes/No observer 1	Excess bone? Yes/No observer 1	mRUST observer 2	Healed? Yes/No observer 2	Excess bone? Yes/No observer 1
1/1	50	Union	7/8 <sup>a</sup>	Yes	No	13/16	Yes	No
2/2	50	Union	7/8 <sup>a</sup>	Yes	No	16/16	Yes	No
3/3	65, 91	Union	6/12 <sup>a</sup>	No	No	8/16	No	No
4/4	42, 337	Union	10/12 <sup>a</sup>	Yes	No	12/12 <sup>a</sup>	Yes	Yes
5/5	54	Progression	6/16	No	No	7/16	No	No
7/7	42	Union	9/12 <sup>a</sup>	Yes	Yes	13/16	No	No
8/8	42	Union	16/16	Yes	No	16/16	Yes	Yes
9/9	56, 104, 222	Non-union	4/4 <sup>a</sup>	Unable to interpret	No	6/8 <sup>a</sup>	Yes	No
10/10	31, 54, 100	Union	13/16	Yes	No	14/16	Yes	No
11/11	47	Union	10/12 <sup>a</sup>	Yes	No	13/16	No	No
9/12	117	Union	6/8 <sup>a</sup>	Yes	No	12/16	No	No

Abbreviation: mRUST, modified Radiographic Union Score for Tibial Fractures.

<sup>a</sup>Bone plate prevented assessment of one or more cortices.



**Table 5** Long-term owner reported follow-up

Case/Treatment	Duration of follow-up (d)	COI stiffness	COI function	COI gait	COI QoL	COI or FMPI total
1/1	1,724	4/16	1/16	18/20	0/12	23/64 COI
2/2	961	5/16	3/16	11/20	0/12	19/64 COI
3/3	751	N/A	N/A	N/A	N/A	60/60 FMPI
4/4	650	2/16	0/16	6/20	3/12	11/64 COI
7/7	583	0/16	1/16	3/20	0/12	4/64 COI
8/8	433	N/A	N/A	N/A	N/A	48/60 FMPI
9/9 and 9/12	544	3/16	4/16	16/20	7/12	30/64 COI

Abbreviations: COI, Canine Orthopedic Index (lower score = better outcome); FMPI, Feline Musculoskeletal Pain Index (higher score = better outcome); N/A, not available; QoL, quality of life.

13/16 which, in one human study, equated to around 70% confidence that a fracture has healed.<sup>34</sup> In answer to the question 'Radiographically is the fracture healed?', observers 1 and 2 agreed in 7/11 cases. Observers 1 and 2 said there was evidence of exuberant or ectopic bone formation in one and two cases respectively, but there was no agreement between observers. Ectopic bone formation was not diagnosed or treated by the attending clinicians in our series, and previous veterinary case series and reports<sup>4-8</sup> do not describe it either. In humans, 12 reports of ectopic bone were made to the U.S. Food and Drug Administration over 7 years and 5 were significant enough to require re-operation.<sup>14</sup>

The long-term COI gave case 9 the highest (worst) quality of life and overall scores, which is explained by the persistent non-union. Case 1 had a gait score of 18/20 because of reduced range of movement in the elbow and shoulder, but the dog had a normal quality of life. Cases 2 and 4 showed mild residual lameness, but again both had normal or near-normal quality of life. By contrast, in dogs with elbow dysplasia there is a strong link between COI lameness and quality of life scores.<sup>35</sup> It may be that the lameness here was more mechanical than painful, hence the owner's perception of good quality of life. Case 3's FMPI score suggests the cat returned to normal in every respect. This case had a massive radial defect that was filled with graft materials (► **Fig. 3**), and on mRUST scoring neither observer was convinced of radiographic healing. The clinician's contrary radiographic assessment was probably biased by an encouraging clinical picture. It is reassuring that this cat achieved such excellent function at home, 751 days after treatment. Case 8 was considered 'not quite normal', or 'moderately worse than normal' on FMPI items pertaining to walking, running and jumping up and down. This tibial fracture radiographically healed but a mild valgus deformity may have caused the abnormal limb function.

Questions surrounding this system remain. The optimal rhBMP-2 concentration or dose, the fate of PEA within the body and safety and efficacy when compared with other bone graft or rhBMP-2 systems are unknown. In this case series, it is impossible to separate the effects of autogenous graft, the osteoconductive granules and the system itself. The COI and FMPI were used here to capture long-term outcome, but are not yet validated for use in animals with fractures.

The time required for preparation of the novel system on the day of surgery is a practical limitation of the current methodology.

In conclusion, an osteoinductive system that utilizes PEA, fibronectin and an ultra-low dose of rhBMP-2 has been used to augment the treatment of bone healing disorders in companion animals. Eight of 10 cases were sound or showed subtle or mild lameness in the short- or long-term, and radiographic union occurred in the majority of treatments. Development of this system continues, and safety and efficacy data could now be sought through a randomized controlled clinical trial.

#### Ethical Approval

The Veterinary Medicines Directorate, Royal College of Veterinary Surgeons (RCVS) and UK Home Office provided guidance. After considering experimental in vivo data,<sup>16,19</sup> the RCVS agreed clinical cases could be treated, though a formal controlled clinical trial was not permitted. The University of Glasgow Ethics Committee granted approval (application 37a/17, date of approval November 28, 2018).

#### Informed Consent

All owners gave fully informed consent.

#### Authors' Contributions

Marshall WG, BVMS, DECVS: HEALIGRAFT grant preparation, FN/ rhBMP-2 adsorption and surgical procedures, was involved in clinical follow-up, record and radiograph review, descriptive statistics, manuscript preparation and submission. Gonzalez-Garcia C, PhD: FN/ rhBMP-2 adsorption procedures, reviewed and approved the manuscript. Trujillo S, PhD: FN/ rhBMP-2 adsorption procedures, reviewed and approved the manuscript. Alba-Perez A, PhD: HEALIGRAFT grant preparation and submission, reviewed and approved the manuscript. Childs P, PhD: plasma-enhanced chemical vapour deposition, reviewed and approved the manuscript. Shields DW, MBChB, Dip-MedEd, MSc, PhD, FRCS, developed EO sterilization protocol, assisted with surgical procedures, reviewed and approved the manuscript. Tomlinson A, BVSc, DECVS: surgical procedure (case 5), was involved in clinical follow-up,

record and radiograph review, reviewed and approved the manuscript. Pettitt R, BVSc, DSAS (Orth): surgical procedure (case 5) reviewed and approved the manuscript. Filliquist B, DVM, DACVS-SA, DECVS: mRUST scoring, reviewed and approved the manuscript. Chou P-Y, BVM, MVM, MS, DACVS-SA: mRUST scoring, reviewed and approved the manuscript. Dalby MJ, PhD: co-inventor of novel system and development of clinical protocol, SBCF and HEALIGRAFT grant preparation, reviewed and approved the manuscript. Corr SA, BVMS, PhD, DECVS: Vet Fund grant preparation and submission, development of HealiOst clinical protocol, administered long-term follow-up questionnaires, reviewed and approved the manuscript. Salmeron-Sanchez M, PhD: co-inventor of novel system and development of clinical protocol, SBCF and HEALIGRAFT grant preparation, reviewed and approved the manuscript.

### Funding

All or part of the treatment costs were covered by grant funding, but no other incentive was provided to animal owners. European Research Council Proof of Concept Grant (HEALIGRAFT, 790380), Sir Bobby Charlton Foundation (SBCF) (synthetic bone project), The Vet Fund, University of Glasgow; UK Regenerative Medicine Platform (MR/R015651/1), University of Glasgow; and the Engineering and Physical Sciences Research Council (EPSRC EP/P001114/1).

### Conflict of Interest

Manuel Salmeron-Sanchez and Matthew Dalby hold a patent for the novel osteoinductive system: US-2018133364-A1 (Materials and Methods for Tissue Regeneration).

### Acknowledgments

The authors thank Veronica Patton, DVM, DACVP, for performing the histopathology and Elena Addison, MA, VetMB, DECVS, for her assistance with the clinical management of cases 1 and 3.

### References

- Phillips IR. A survey of bone fractures in the dog and cat. *J Small Anim Pract* 1979;20(11):661–674
- Atilola MAO, Sumner-Smith G. Non-union fractures in dogs. *J Vet Orthop*. 1984;3:21–24
- Marshall WG, Filliquist B, Tzimtzimis E, et al. Delayed union, non-union and mal-union in 442 dogs. *Vet Surg* 2022;51(07):1087–1095
- Pinel CB, Pluhar GE. Clinical application of recombinant human bone morphogenetic protein in cats and dogs: a review of 13 cases. *Can Vet J* 2012;53(07):767–774
- Massie AM, Kapatkin AS, Fuller MC, Verstraete FJ, Arzi B. Outcome of nonunion fractures in dogs treated with fixation, compression resistant matrix, and recombinant human bone morphogenetic protein-2. *Vet Comp Orthop Traumatol* 2017;30(02):153–159
- Vezzoni L, Abrescia P, Vezzoni A. Internal radioulnar fixation for treatment of non-union of proximal radius and ulna fractures in a toy breed dog. *Vet Comp Orthop Traumatol Open*. 2021;4:e24–e31
- Franch J, Barba A, Rappe K, Maazouz Y, Ginebra MP. Use of three-dimensionally printed  $\beta$ -tricalcium phosphate synthetic bone graft combined with recombinant human bone morphogenetic protein-2 to treat a severe radial atrophic nonunion in a Yorkshire terrier. *Vet Surg* 2020;49(08):1626–1631
- Schmoekel HG, Weber FE, Hurter K, et al. Enhancement of bone healing using non-glycosylated rhBMP-2 released from a fibrin matrix in dogs and cats. *J Small Anim Pract* 2005;46(01):17–21
- Govender S, Csimma C, Genant HK, et al; BMP-2 Evaluation in Surgery for Tibial Trauma (BESTT) Study Group. Recombinant human bone morphogenetic protein-2 for treatment of open tibial fractures: a prospective, controlled, randomized study of four hundred and fifty patients. *J Bone Joint Surg Am* 2002;84(12):2123–2134
- Brigaud I, Agniel R, Leroy-Dudal J, et al. Synergistic effects of BMP-2, BMP-6 or BMP-7 with human plasma fibronectin onto hydroxyapatite coatings: a comparative study. *Acta Biomater* 2017;55:481–492
- Yang HS, La W-G, Cho Y-M, Shin W, Yeo G-D, Kim B-S. Comparison between heparin-conjugated fibrin and collagen sponge as bone morphogenetic protein-2 carriers for bone regeneration. *Exp Mol Med* 2012;44(05):350–355
- Seeherman H, Wozney JM. Delivery of bone morphogenetic proteins for orthopedic tissue regeneration. *Cytokine Growth Factor Rev* 2005;16(03):329–345
- James AW, LaChaud G, Shen J, et al. A review of the clinical side effects of bone morphogenetic protein-2. *Tissue Eng Part B Rev* 2016;22(04):284–297
- Woo EJ. Adverse events after recombinant human BMP2 in non-spinal orthopaedic procedures. *Clin Orthop Relat Res* 2013;471(05):1707–1711
- Ohara T, Sato T, Shimizu N, et al. Acrylic acid and derivatives. In: Ullmann's Encyclopaedia of Industrial Chemistry. New Jersey, USA: Wiley; 2020
- Cheng ZA, Alba-Perez A, Gonzalez-Garcia C, et al. Nanoscale coatings for ultralow dose BMP-2-driven regeneration of critical-sized bone defects. *Adv Sci* 2019;6:1800361
- Mao Y, Schwarzbauer JE. Fibronectin fibrillogenesis, a cell-mediated matrix assembly process. *Matrix Biol* 2005;24(06):389–399
- Salmerón-Sánchez M, Rico P, Moratal D, Lee TT, Schwarzbauer JE, García AJ. Role of material-driven fibronectin fibrillogenesis in cell differentiation. *Biomaterials* 2011;32(08):2099–2105
- Llopis-Hernández V, Cantini M, González-García C, et al. Material-driven fibronectin assembly for high-efficiency presentation of growth factors. *Sci Adv* 2016;2(08):e1600188
- Marshall WG, Alba-Perez A, Gonzalez-Garcia C, et al. Bioengineering a novel growth factor system for fracture non-union: first successful treatment of a dog. Poster abstract ECVS Symposium, Budapest, Hungary; 2019 Doi: 10.1111/vsu.13248
- Cook JL, Evans R, Conzemius MG, et al. Proposed definitions and criteria for reporting time frame, outcome, and complications for clinical orthopedic studies in veterinary medicine. *Vet Surg* 2010;39(08):905–908
- Litrenta J, Tornetta P III, Mehta S, et al. Determination of radiographic healing: an assessment of consistency using RUST and modified RUST in metadiaphyseal fractures. *J Orthop Trauma* 2015;29(11):516–520
- Balzer W, Owen R. Survey of 156 police dogs in New Zealand: functional assessment and Canine Orthopaedic Index. *Vet Comp Orthop Traumatol* 2019;32(03):A1–A12
- Bilic R, Simic P, Jelic M, et al. Osteogenic protein-1 (BMP-7) accelerates healing of scaphoid non-union with proximal pole sclerosis. *Int Orthop* 2006;30(02):128–134
- Ronga M, Baldo F, Zappalà G, Cherubino P. Recombinant human bone morphogenetic protein-7 for treatment of long bone non-union: an observational, retrospective, non-randomized study of 105 patients. *Injury. Int. J. Care Injured*. 2006;37S:S51–S56
- Castilla A, Filliquist B, Spriet M, et al. Long-term assessment of bone regeneration in nonunion fractures treated with compression-resistant matrix and recombinant human bone

- morphogenetic protein-2 in dogs. *Vet Comp Orthop Traumatol* 2023;36(01):29–38
- 27 Mills L, Tsang J, Hopper G, Keenan G, Simpson AHRW. The multifactorial aetiology of fracture nonunion and the importance of searching for latent infection. *Bone Joint Res* 2016;5(10):512–519
- 28 Govaert GAM, Kuehl R, Atkins BL, et al; Fracture-Related Infection (FRI) Consensus Group. Diagnosing fracture-related infection: current concepts and recommendations. *J Orthop Trauma* 2020;34(01):8–17
- 29 Alcantara BM, Minto BW, Franco GG, Lucena DVF, Dias LGG. Bridge plating for simple tibial fractures treated by minimally invasive plate osteosynthesis. *Arq Bras Med Vet Zootec* 2021;73:589–597
- 30 Misir A, Uzun E, Kizkapan TB, Yildiz KI, Onder M, Ozcamdalli M. Reliability of RUST and Modified RUST Scores for the evaluation of union in humeral shaft fractures treated with different techniques. *Indian J Orthop* 2020;54(Suppl (Suppl 1):121–126
- 31 Kizkapan TB, Misir A, Oguzkaya S, Ozcamdalli M, Uzun E, Sayer G. Reliability of radiographic union scale in tibial fractures and modified radiographic union scale in tibial fractures scores in the evaluation of pediatric forearm fracture union. *Jt Dis Relat Surg* 2021;32(01):185–191
- 32 Misir A, Yildiz KI, Kizkapan TB, Uzun E, Özcamdalli M, Oğuzkaya S. Reliability of RUST and modified RUST scores for evaluation of union in pediatric and adult femoral shaft fractures. *Acta Orthop Traumatol Turc* 2021;55(02):127–133
- 33 Saad BN, Zurita D, Li DJ, Dailey H, Yoon RS, Liporace FA. Bone marrow aspirate concentrate as a reliable adjunct in tibiotalo-calcaneal fusion: A radiographic modified RUST score analysis. *Ind J Orthop*; 2021 Doi: 10.1007/s43465-021-00425-2
- 34 Coburn A, Shearer D, Albright P, et al. Evaluating reliability and validity of the modified radiographic union scale for tibia (mRUST) among North American and Tanzanian surgeons. *OTA Int*; 2020 Doi: 10.1097/O19.0000000000000093
- 35 Bergström A, Johard S, Lee MH, Comin A. Long term prognosis of quality of life in dogs diagnosed with mild to moderate elbow dysplasia in Sweden. *Front Vet Sci* 2020;7:572691. Doi: 10.3389/fvets.2020.572691