



# Spontaneous Resolution of a Humeral Intracondylar Fissure in a Skeletally Immature French Bulldog

Ben William Garland<sup>1</sup> Emilian Adrian Dumitru<sup>2</sup> Alejandro Ororbia<sup>3</sup> Bill Oxley<sup>4</sup>

<sup>1</sup>Department of Small Animal Surgery, Debenham Vets Surgical Referrals, Debenham, Suffolk, United Kingdom of Great Britain and Northern Ireland

<sup>2</sup>Chirstchurch Veterinary Referrals, Tuddenham Road Business Centre, Tuddenham Road, Ipswich, United Kingdom of Great Britain and Northern Ireland

<sup>3</sup>Department of Diagnostic Imaging, Pride Veterinary Centre, Derby, United Kingdom of Great Britain and Northern Ireland

<sup>4</sup>Vet3D, Staveley, UK

**Address for correspondence** Ben William Garland, BVetMed (Hons), CertAVP (GSAS), MRCVS, Department of Small Animal Surgery, Debenham Veterinary Practice, 1 Cherry Tree Lane, Debenham, Stowmarket, Suffolk IP14 6QT, United Kingdom of Great Britain and Northern Ireland (e-mail: Ben.veterinary@gmail.com).

VCOT Open 2023;6:e37–e40.

## Abstract

A 4-month-old male entire French bulldog was presented for the investigation of acute left thoracic limb lameness. Computed tomography (CT) revealed a right-sided humeral intracondylar fissure (HIF) and a left-sided medial humeral condylar fracture which was managed by open reduction and internal fixation. Follow-up CT at 36 days after surgery revealed healing of the condylar fracture and partial resolution of the HIF, which was radiographically unapparent on further CT images 105 days thereafter (at 220 days of life). To the best of the authors' knowledge, this is the first reported case of spontaneous resolution of a HIF beyond the normal age of reported humeral condyle ossification center closure.

## Keywords

- ▶ spontaneous regression
- ▶ French bulldog
- ▶ humeral intracondylar fissure

## Introduction

Humeral intracondylar fissure (HIF) is a widely reported condition associated with variable degrees of morbidity.<sup>1–8</sup> Presentation ranges from clinically silent, to variable thoracic limb lameness, or as a precursor to condylar fractures with or without prodromal lameness. The aetiology remains controversial and may vary between breed or individuals. Normal anlage ossification of the canine humeral condyles originates from discrete ossification centres, radiographically evident at  $14 \pm 8$  days after birth. As ossification progresses these centres remain separated by a cartilaginous plate until ossification occurs at  $70 \pm 14$  days after birth.<sup>1,9</sup> Thereafter, only the distal humeral physal plate is present with subsequent closure reported between 5 and 8 months of age.<sup>10,11</sup>

There are several proposed aetiopathologies for HIF development including failure of routine humeral epiphyseal

ossification<sup>1</sup>; stress fracture propagation<sup>2–5</sup>; secondary to dysplastic elbow joints presenting as either humeroanconeal impingement<sup>12</sup> or radioulnar incongruency<sup>2,13</sup>; or as a heritable defect<sup>1</sup>. De novo HIF formation has also been reported in two Spaniel dogs with previously documented unaffected condyles.<sup>14,15</sup> While HIF in dogs is typically seen in skeletally mature individuals, it has been documented in patients as young as 4 months of age.<sup>3,5</sup>

In addition to the classically recognized Spaniel signalment, French bulldogs have been reported as an at-risk breed for HIF and associated humeral condylar fractures.<sup>16–18</sup> The prevalence of HIF has recently been reported in two discrete populations of French bulldogs. While absent in non-lame populations presenting for non-orthopaedic conditions, a high prevalence of contralateral HIF was noted where French bulldogs present with documented humeral condylar fractures.<sup>16,19,20</sup> To the best of the authors' knowledge, there are

received

August 3, 2022

accepted after revision

January 12, 2023

DOI <https://doi.org/>

10.1055/s-0043-1762901.

ISSN 2625-2325.

© 2023. The Author(s).

This is an open access article published by Thieme under the terms of the Creative Commons Attribution License, permitting unrestricted use, distribution, and reproduction so long as the original work is properly cited. (<https://creativecommons.org/licenses/by/4.0/>)

Georg Thieme Verlag KG, Rüdigerstraße 14, 70469 Stuttgart, Germany

no reports of spontaneous resolution of HIF lesions in French bulldogs within the literature.

### Case Description

A 4-month-old (115 days) old male entire French bulldog weighing 7 kg was presented because of an acute onset left thoracic limb lameness after normal exercise 48 hours previously. Previous lameness had not been noted by the owner. Orthopaedic examination revealed diffuse periarticular soft tissue swelling, pain and crepitus of the left elbow with intact neurological function and no visible skin wounds. No additional trauma or comorbidities were recognized during the remainder of the routine physical or orthopaedic examination.

Under general anaesthesia, computed tomography (CT) imaging of the elbows was performed using a 32-slice helical scanner (SOMATOM go.Now, Siemens Healthcare Ltd, Park View, Watchmoor Park, Camberley, Surrey, UK). Key radiological findings included a non-displaced Salter Harris IV fracture of the left medial humeral condyle and a HIF affecting the right condyle. This was characterized by a faint, ill-defined hypoattenuating line with sclerotic margins bisecting the humeral condyle from the articular surface to the supratrochlear fossa (►Fig. 1).

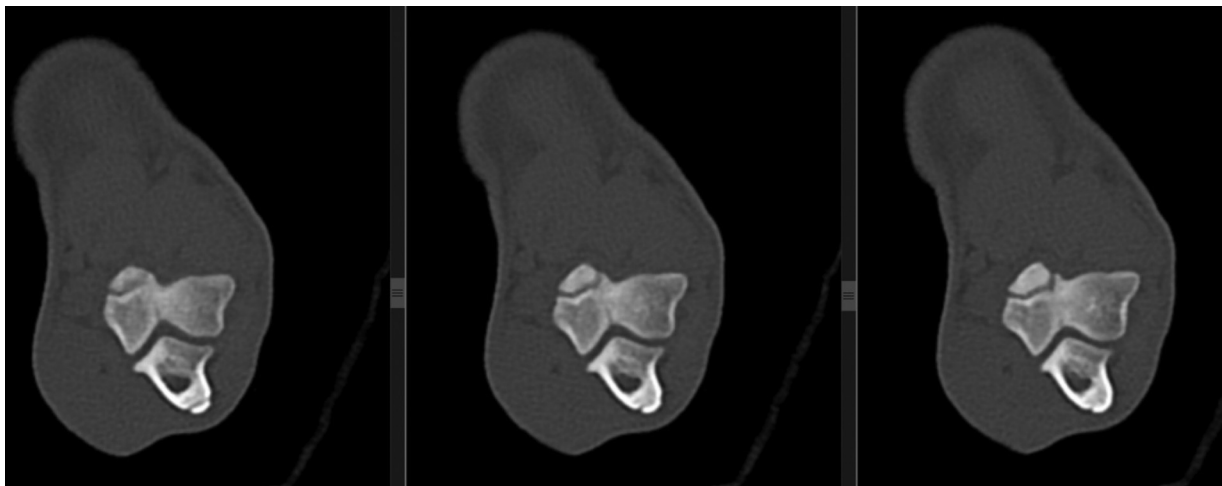
Left humeral medial condylar fracture osteosynthesis was performed by open reduction and internal fixation with a combination of a transcondylar screw and caudomedial locking plate in neutralisation mode. Postoperative orthogonal radiographs demonstrated anatomic fracture reduction and appropriate implant positioning, and the patient was discharged the following day. Postoperative care instructions comprised strict cage rest, with short leash walks three to four times daily for several minutes. Once daily oral meloxicam (Loxicom 1.5 mg/mL oral suspension, Norbrook Laboratories Ltd) for 14 days was prescribed. Serial orthopaedic and CT examinations were performed to assess both fracture healing and the right elbow HIF at 36 and 105 days postoperatively. Computed tomographic examination at 36 days revealed union of the left humeral condyle fracture characterized by

an absence of visible intracondylar lucency immediately cranial and caudal to the transcondylar screw with complete uniform cortical margins of subchondral bone, supratrochlear foramen and the medial epicondylar crest in agreement with the visible findings on orthogonal radiographs. The previously described HIF was still visible but less evident than in the initial images; the hypoattenuating line was narrower, and bordered on each side with a narrow sclerotic zone (►Fig. 2). Following documented fracture healing all medications were withdrawn and a staged increase in activity was recommended by gradually increasing the duration of lead-controlled walks. At final CT examination of the right elbow joint (105 days postoperatively), the previously noted hypoattenuating line was no longer present, and there was no irregularity in the subchondral bone contour. A small, ill-defined area of sclerosis was still visible within the humeral intracondylar region (►Fig. 3). Resumption of normal unrestricted activity was allowed again, based on these findings. Right thoracic limb lameness was not seen at follow-up orthopaedic re-examination (105 days postoperatively) or reported by the owners at telephone follow-up 389 days following original HIF diagnosis.

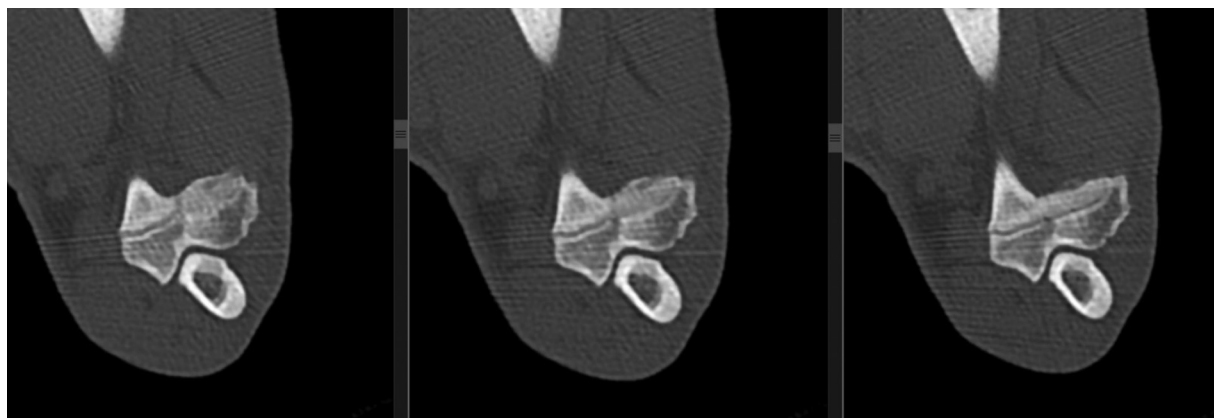### Discussion

Spontaneous resolution of HIF has not, to our knowledge, been previously documented. As stated, the aetiopathogenesis of HIF remains elusive with various hypotheses proposed and broadly considered as failure of normal 'anlage' ossification or fracture propagation secondary to an underlying pathology.<sup>1-5,12,13,19-23</sup> Indeed, the possibility that a different process causes these fissures in different breeds or individuals at different ages cannot be excluded.

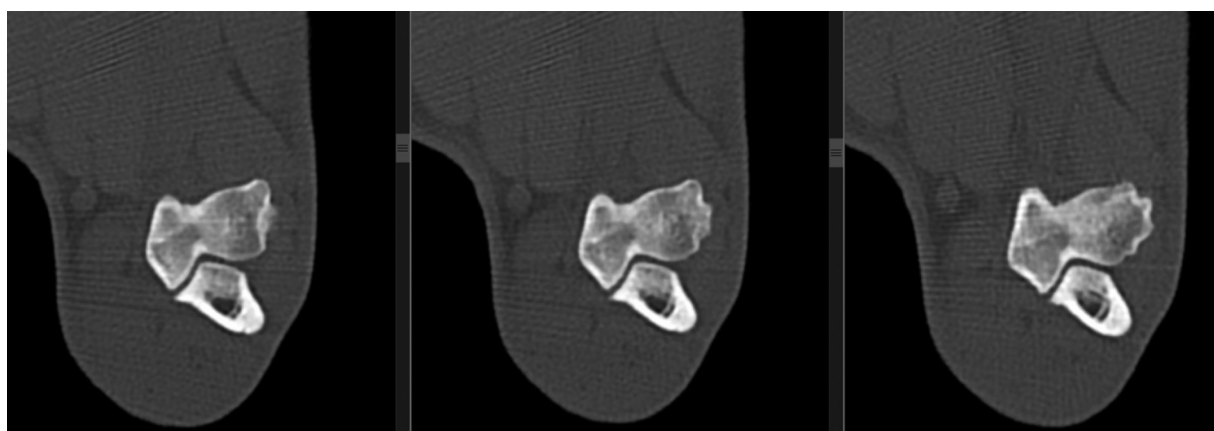In this skeletally immature dog, it would seem plausible that resolution of an abnormality of ossification could have permitted spontaneous healing of the fissure. Ossification is a complex physiological process, regulated by both intrinsic and extrinsic mechanisms. The effect of external forces on the natural epiphyseal ossification process is important and has been demonstrated experimentally.<sup>24</sup> Forces applied



**Fig. 1** Day 0 right humeral condyle (W/L 500:2500) viewed in serial transverse images through the humeral condyle showing hypoattenuating intracondylar line bordered by hyperattenuating sclerotic bone.



**Fig. 2** Day 36 right humeral condyle (W/L 500:2500) viewed in serial transverse images through the humeral condyle showing a faint hypoattenuating intracondylar line bordered by hyperattenuating sclerotic bone.



**Fig. 3** Day 105 right humeral condyle (W/L 500:2500) viewed in serial transverse images through the humeral condyle showing a faint hypoattenuating ovoid intracondylar region bordered by mildly hyperattenuating sclerotic bone. A discrete hypoattenuating line is not present.

parallel to the direction of axial loading promote early ossification,<sup>25,26</sup> while perpendicular or shear forces may cause radiographic physal widening but not a delayed closure.<sup>27</sup> In this present case, it is also possible that strict cage rest, as part of the recommended postoperative management for contralateral humeral condylar fracture repair, leads to a period of reduced forces acting on the condyles providing a biomechanical environment to allow the fissure to ossify. Alternatively, a potential spontaneous resolution of a transient elbow incongruity may have occurred during this time period. The latter possibility has been suggested to play a role in the development of medial coronoid process disease, and, as in that condition might be expected to vary in its effect between individuals.<sup>28,29</sup> However, elbow joint incongruity was not detected on initial CT examination to support this theory.

In the case presented here we could argue an alternative hypothesis that this was not resolution of a HIF but rather delayed 'normal' ossification of the humeral condyle in an individual compared with what is typically described ( $70 \pm 14$  [standard deviation] days). The frequently referred to timeframe of  $70 \pm 14$  days after birth was derived from a combination of dog breeds including German Shepherd,

Beagle, Collie and bulldogs in a single study.<sup>9</sup> In the latter breed, Hare's (1961) study noted ossification centres were found to develop comparatively later.<sup>19</sup> Such breed-specific delayed ossification could result in mechanically compromised condylar structures in French bulldogs at a time in life when intensity of exercise typically increases. The median age of 5 months at which French bulldogs present with humeral condylar fractures reported by Sanchez Villamil and colleagues,<sup>17</sup> and the 56% incidence of contralateral HIF in French bulldogs aged more than 13 weeks with condylar fractures reported by Strohmeier and Harris<sup>16</sup> could also be supported by this proposed delayed ossification.

Further investigation would be needed to differentiate between these hypotheses; however, the implication of these findings suggests that there is a possibility for spontaneous HIF resolution or delayed ossification which should be considered when approaching clinical cases. Where incidental HIF is detected in skeletally immature patients, it may be prudent to re-take radiographs of the condyles to assess the status of the HIF at subsequent points of time prior to prophylactic surgical stabilization. By extension, such a staged approach could arguably be preferable to concurrent

treatment of a fracture and contralateral HIF. Clearly the benefit of potentially avoiding an unnecessary surgery for any incidentally diagnosed HIF in a young French bulldog must be balanced against the risk of fracture. It has been shown that a minority (24%) of incidentally-diagnosed HIFs in a single cohort of adult Spaniels required surgical intervention, and fractures can occur without prodromal lameness.<sup>5</sup> Unfortunately, as is the nature of single case reports, we lack the data to make an informed decision where the balance of risk lies in such cases. If an initial conservative approach is adopted, it would seem prudent to minimize the risk of fracture by strict exercise moderation and specific attention to lameness monitoring with serial imaging. In conclusion, we report the presence of HIF in a skeletally immature French bulldog at an age beyond the reported time for closure, which was noted to spontaneously resolved at follow-up cross-sectional imaging.

#### Conflict of Interest

None.

#### References

- 1 Marcellin-Little DJ, DeYoung DJ, Ferris KK, Berry CM. Incomplete ossification of the humeral condyle in spaniels. *Vet Surg* 1994;23(06):475–487
- 2 Butterworth SJ, Innes JF. Incomplete humeral condylar fractures in the dog. *J Small Anim Pract* 2001;42(08):394–398
- 3 Meyer-Lindenberg A, Heinen V, Fehr M, et al. Incomplete ossification of the humeral condyle as a cause of lameness in dogs. *Vet Comp Orthop Traumatol* 2002;15(03):187–194
- 4 Moores A. Humeral condylar fractures and incomplete ossification of the humeral condyle in dogs. *In Pract* 2006;28(07):391–397
- 5 Moores AP, Moores AL. The natural history of humeral intracondylar fissure: an observational study of 30 dogs. *J Small Anim Pract* 2017;58(06):337–341
- 6 Holloway GL, Midgley D. Lateral condylar fracture secondary to humeral intracondylar fissure in a cat. *Vet Surg* 2021;50(04):898–903
- 7 Bardet J, Hohn R, Rudy R, Olmstead M. Fractures of the humerus in dogs and cats a retrospective study of 130 Cases. *Vet Surg* 1983;12(02):73–77
- 8 Chan AJ, Reyes Rodriguez NA, Bailey SJ, Langley-Hobbs SJ. Treatment of humeral condylar fractures and humeral intracondylar fissures in cats with patellar fracture and dental anomaly syndrome. *J Feline Med Surg* 2020;22(10):1008–1015
- 9 Hare WC. The ages at which the centers of ossification appear roentgenographically in the limb bones of the dog. *Am J Vet Res* 1961;22:825–835
- 10 Sumner-Smith G. Observations on epiphyseal fusion of the canine appendicular skeleton. *J Small Anim Pract* 1966;7(04):303–311
- 11 Lefebvre JB, Robertson TR, Baines SJ, Jeffery ND, Langley-Hobbs SJ. Assessment of humeral length in dogs after repair of Salter-Harris type IV fracture of the lateral part of the humeral condyle. *Vet Surg* 2008;37(06):545–551
- 12 Danielski A, Yeadon R. Humero-anconeal elbow incongruity in spaniel breed dogs with humeral intracondylar fissure: arthroscopic findings. *Vet Surg* 2022;51(01):117–124
- 13 Moores AP, Agthe P, Schaafsma IA. Prevalence of incomplete ossification of the humeral condyle and other abnormalities of the elbow in English Springer Spaniels. *Vet Comp Orthop Traumatol* 2012;25(03):211–216
- 14 Farrell M, Trevail T, Marshall W, Yeadon R, Carmichael S. Computed tomographic documentation of the natural progression of humeral intracondylar fissure in a cocker spaniel. *Vet Surg* 2011;40(08):966–971
- 15 Witte PG, Bush MA, Scott HW. Propagation of a partial incomplete ossification of the humeral condyle in an American cocker spaniel. *J Small Anim Pract* 2010;51(11):591–593
- 16 Strohmeier UW, Harris KP. Humeral intracondylar fissures in French bulldogs. *Vet Rec* 2021;189(11):e504. Doi: 10.1002/vetr.504
- 17 Sanchez Villamil C, Phillips ASJ, Pegram CL, O'Neill DG, Meeson RL. Impact of breed on canine humeral condylar fracture configuration, surgical management, and outcome. *Vet Surg* 2020;49(04):639–647
- 18 Rørvik A. Risk factors for humeral condylar fractures in the dog: a retrospective study. *J Small Anim Pract* 1993;34(06):277–282
- 19 Anderson OJ, Langley-Hobbs SJ, Parsons KJ. Humeral condylar fractures and fissures in the French bulldog. *Vet Surg* 2023;52(01):134–145
- 20 Mella S, Dirrig H, Meeson RL. Computed tomographic features of non-lame French bulldog elbows. *Vet Comp Orthop Traumatol* 2022;35(03):175–183
- 21 Charles EA, Ness MG, Yeadon R. Failure mode of transcondylar screws used for treatment of incomplete ossification of the humeral condyle in 5 dogs. *Vet Surg* 2009;38(02):185–191
- 22 Sjoström L, Kasstrom H, Kollberg M. Ununited anconeal process in the dog: pathogenesis and treatment by osteotomy of the ulna. *Vet Comp Orthop Traumatol* 1995;8:170–175
- 23 Larsen L, Roush J, McLaughlin R, et al. Microangiography of the humeral condyle in the cocker spaniel and non-cocker spaniel dogs. *Vet Comp Orthop Traumatol* 1999;12:134–137
- 24 LeVeau BF, Bernhardt DB. Developmental biomechanics. Effect of forces on the growth, development, and maintenance of the human body. *Phys Ther* 1984;64(12):1874–1882
- 25 Ehrlich MG, Mankin HJ, Treadwell BV. Biochemical and physiological events during closure of the stapled distal femoral epiphyseal plate in rats. *J Bone Joint Surg Am* 1972;54(02):309–322
- 26 Reich A, Jaffe N, Tong A, et al. Weight loading young chicks inhibits bone elongation and promotes growth plate ossification and vascularization. *J Appl Physiol* 2005;98(06):2381–2389
- 27 Chang CY, Shih C, Penn IW, Tiu CM, Chang T, Wu JJ. Wrist injuries in adolescent gymnasts of a Chinese opera school: radiographic survey. *Radiology* 1995;195(03):861–864
- 28 Gemmill TJ, Clements DN. Fragmented coronoid process in the dog: is there a role for incongruity? *J Small Anim Pract* 2007;48(07):361–368
- 29 Fitzpatrick N, Yeadon R. Working algorithm for treatment decision making for developmental disease of the medial compartment of the elbow in dogs. *Vet Surg* 2009;38(02):285–300