






Malignant Peripheral Nerve Sheath Scalp Tumor: A Short-Term Institutional Experience with Literature Review

Vikas Chandra Jha¹  Mohammad Shahnawaz Alam¹  Vivek Saran Sinha¹ 

¹Department of Neurosurgery, All India Institute of Medical Sciences, Patna, India

Address for correspondence Vikas Chandra Jha, MCH, Department of Neurosurgery, All India Institute of Medical Sciences, Patna, 801507, India (e-mail: drvikaschandrajha@aaimspatna.org).

AJNS 2023;18:157–164.

Abstract

Malignant peripheral nerve sheath tumor (MPNST) of the scalp is rare. These lesions are associated with neurofibromatosis type 1 (NF1), but patients had been reported without NF1 also. We tried to analyze the difference between the clinical course and outcome of the patient with MPNST having stigmata of NF1 and without it. We included five patients treated over 3 years between July 2018 and July 2021 with diffuse scalp MPNST. Two of these five patients with MPNST of the scalp had neurocutaneous stigmata of NF1. Three were female and two males with an average age of 38.40 ± 18.48 years—the youngest with NF1 being a 19-year-old female. We found dull aching pain as the most typical complaint in all patients and a repeated episode of generalized seizure in one patient. In these cases, two patients with NF1 have highly vascular tumors and attained large sizes greater than 30 cm. These two cases required preoperative digital subtraction angiography (DSA) and embolization with n-butyl acrylate. Total excision of the tumor was done in all patients with radiotherapy. Metastases within 1 year were noted in two patients with NF1, and one of these two succumbed to her illness. The rest of the three patients without NF1 are under follow-up with no evidence of disease with a maximum follow-up of 2 years. Large MPNST (size > 20 cm) are rare and reported to have been associated with and without NF1. Patients with scalp MPNST with NF1 can achieve larger size with fast progression of tumor size and higher chances of recurrence and metastases.

Keywords

- ▶ malignant peripheral nerve sheath tumor
- ▶ diffuse scalp lesion
- ▶ neurofibromatosis type 1
- ▶ clinical course
- ▶ treatment outcome

Introduction

Malignant peripheral nerve sheath tumors of the scalp are rare as reported in different studies.^{1–3} Generally, it involves extremities followed by the chest, abdomen, and neck. In all, 50% of the tumor had been reported to be associated with NF1. Although scalp MPNST are rare

tumors, they have the propensity to attain giant size.^{3,4} Clinical courses of the patient having NF1 and without these stigmata have been variably reported.^{1–4} None of the reported studies have a sufficient number of patients to reach a particular conclusion. We tried to analyze the patient's clinical course and treatment outcomes in our series of patients.

article published online
March 27, 2023

DOI <https://doi.org/10.1055/s-0043-1763524>.
ISSN 2248-9614.

© 2023. Asian Congress of Neurological Surgeons. All rights reserved.

This is an open access article published by Thieme under the terms of the Creative Commons Attribution-NonDerivative-NonCommercial-License, permitting copying and reproduction so long as the original work is given appropriate credit. Contents may not be used for commercial purposes, or adapted, remixed, transformed or built upon. (<https://creativecommons.org/licenses/by-nc-nd/4.0/>)

Thieme Medical and Scientific Publishers Pvt. Ltd., A-12, 2nd Floor, Sector 2, Noida-201301 UP, India

Patient's Details

Patients with malignant peripheral nerve sheath tumors had an average age of 38.40 ± 18.48 years; the youngest patient was 19 years old, and the oldest patient was 60 years old. There were three females and two males in the study. The duration taken to grow up to the present size (> 20 cm) was nearly 6.5 months in patients having neurocutaneous stigmata of NF1. All patients were anemic, and those with NF1 presented with severe anemia for which repeated blood transfusion was given. Dull aching pain was the most typical complaint of patients (**►Table 1**).

Scalp lesion had mixed density on noncontrast computerized tomography head. Magnetic resonance imaging (MRI) brain with MR arteriography suggested heterogeneously contrast-enhancing lesions in all patients with diffuse scalp involvement. MR angiography suggested a doubtful vascular supply from intracranial vessels, for which preoperative digital subtraction angiography (DSA) was performed. All patients had a vascular supply from the middle meningeal and superficial temporal artery and two from the occipital artery. Preoperative embolization was performed with n-butyl cyanoacrylate seeing high vascularity of the tumor. The intraoperative dural breach was noted in two patients. Total excision covering the calvaria with a rotational flap was performed. All tumors had spindle-shaped cells arranged in a palisading pattern with mucinous content interspersed in between, and they positively stained for S100. All patients were given adjuvant radiotherapy (44 Gy/30 divided doses) and chemotherapy (Lipodox protocol chemotherapy). Two patients with NF1 had metastases within 12 months (**►Table 2**).

Discussion

MPNST constitutes 3 to 10% of soft tissue sarcoma. Its incidence is 0.001% in the general population. In all, 50% of the MPNST occurs in association with neurofibromatosis type 1.^{1,2} Lifetime risk of development of MPNST in patients with NF1 is 10%. Involvement of the scalp is rare, and nearly 20 patients have been reported.^{3,4}

The age incidence of the lesion is 20 to 50 years with male predominance.^{1,2} In the study by Arshi et al, the mean age at detection of the lesion was 50.7 ± 22.4 years in the present study, patients were younger compared to reported studies, which suggests that MPNST can develop in younger patients also. Three females and two males suggested slight male predominance in the present study, contrary to the higher male-to-female ratio in other studies.^{3,4} Patients with the largest lesions were females of younger age and having neurocutaneous stigmata of NF1, which suggests that patients having NF1 can present earlier with giant lesions.

Most lesions are in the occipital region, followed by the frontal, temporal, and parietal regions. The location of the lesion in the present series was extensive as it involved the frontal, temporal, parietal, and occipital regions with an average size of 27.6 ± 5.17 cm, contrary to the earlier reports where the lesion was localized and of smaller size. The average tumor dimension reported in the present study was more extensive than in other reported cases. All patients in the present series had a tumor larger than 20 cm, with one patient having a tumor size of 32 cm. Ten of the 20 patients reported earlier by different authors have lesions more than 20 cm, and the duration of onset of symptoms was shorter in their studies⁵⁻¹⁰ (**►Table 1**). Lesions in the present study

Table 1 Clinica features of the patients having malignant peripheral nerve sheath tumour

Patient	Age/ sex	location	Features of NF1	symptoms	Duration of symptoms (mo)	Size of the tumour (largest diameter in centimeter)
1. (►Figs. 1,2)	19 y/f	RT Temporo- parietal-occipital	+	Fungating scalp mass, with breathlessness, severely, anaemic, repeated transfusion given but anemia not improving preoperatively, aching pain	7	34 (34 × 28 × 24)
2. (►Figs. 3,4)	23 y/f	Suboccipital region	+	Multilobulated scalp mass, surface erosions present, anemic	6	32 (32 × 26 × 24)
3. (►Fig. 5)	60 y/m	Occipital region	–	Multilobulated scalp mass, with surface erosion and occasional serosanguinous discharge	36	26 (26 × 24 × 20)
4. (►Figs. 6,7)	35 y/f	Frontal	–	Multilobulated ulcerated region	30	24 (24 × 20 × 18)
5. NA	55 y/m	Occipital and suoccipital area	–	Multilobulated, bosslated, nonulcerative	24	22 (22 × 18 × 20)

Abbreviations: f, female; m, male; y, year.

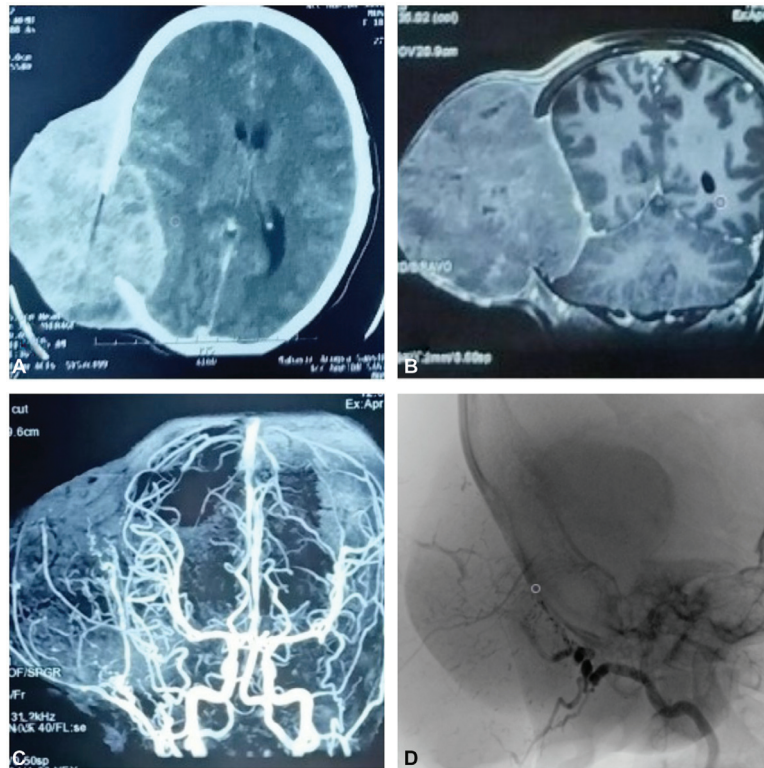


Fig. 1 (A) Non contrast computed tomography (NCCT) head suggests hyperdense lesion with the erosion of calvaria and intracranial extension. (B) Magnetic resonance imaging (MRI) brain with contrast suggesting contrast-enhancing lesion with noncontrast enhancing area in between. (C) Magnetic resonance arteriography (MR-angiography) suggesting high vascularity of lesion with feeders from superficial temporal artery and middle meningeal artery. (D) Glue embolization (n-butyl cyanoacrylate) was done through the right external carotid artery to decrease vascularity.

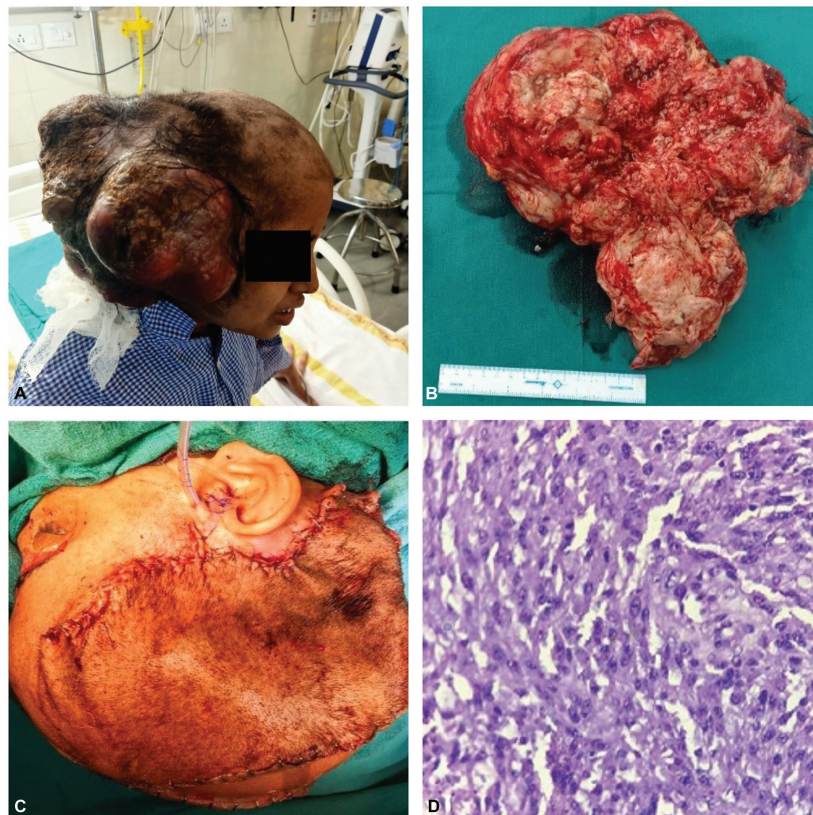


Fig. 2 (A) Multilobulated lesion involving the right fronto-temporo-parietal region. (B) Tumour mass after surgery performed. (C) Scalp defect was covered with a rotational flap and bare area with a split skin graft. (D) Histopathology with H&E staining suggesting sheets of spindle cells spread with the collagenous and mucinous matrix.

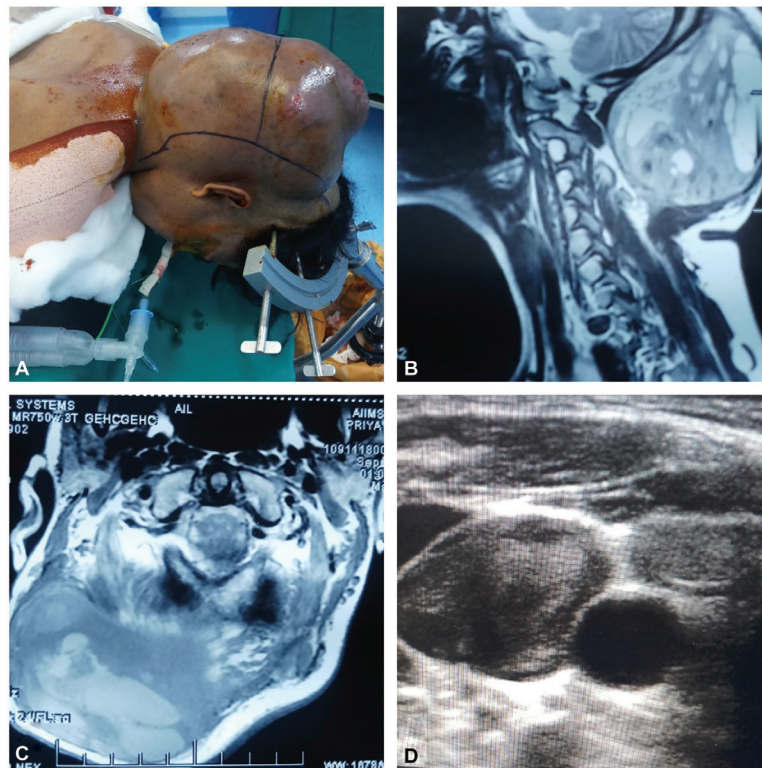


Fig. 3 (A) Tumor mass of max. dimension 32 cm overlying occipital area and up to lower cervical region with lateral extension up to bilateral carotid artery. (B) Saggital T2 MRI sequence showing tumor with variable intensity overlying occipital and cervical area. (C) Axial T2 MRI sequence showing hyperdense area interspersed with isodense suggesting cystic degeneration within the lesion. (D) Intraoperative ultrasonography revealed a lesion involving the right common carotid artery.

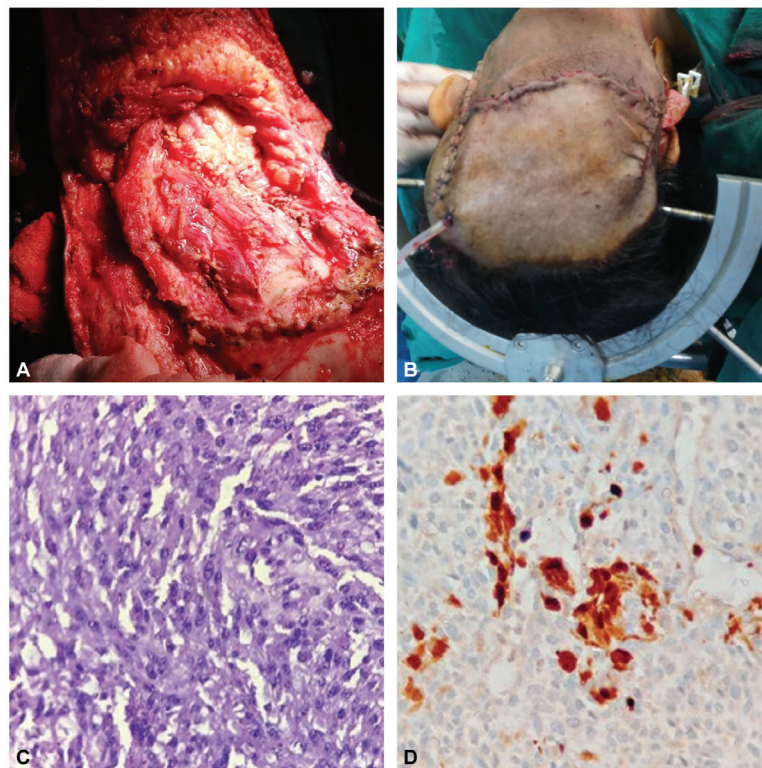


Fig. 4 (A) Tumour bed revealing infiltration of muscles in neck region being infiltrated by the tumor which was excised completely. (B) Scalp and neck region after reconstruction following tumor excision. (C) H&E staining of tumor biopsy revealing sheets of spindle cells intermixed with sheets of collagen and mucinous matrix. (D) Immunohistochemistry suggesting S100 staining of tumor.

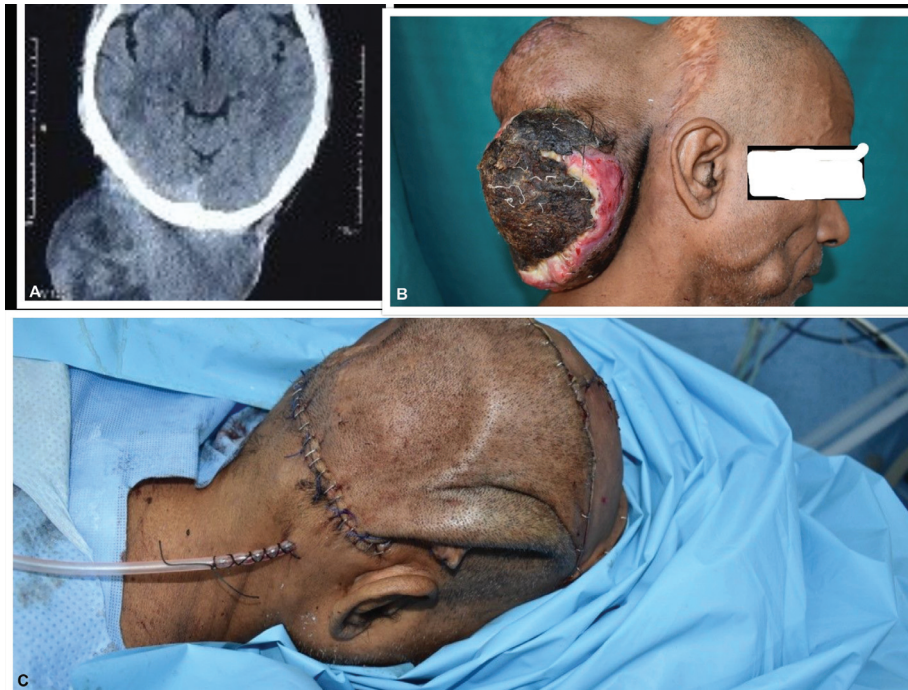


Fig. 5 (A) Tumour overlying occipital calvaria and overhanging in the neck region. (B) NCCT head revealing tumor mass in the occipital region and overlying torcula with no obvious calvarial breach.(C) Postoperative image showing excision of the lesion with the reconstruction of scalp defect by a rotational flap.

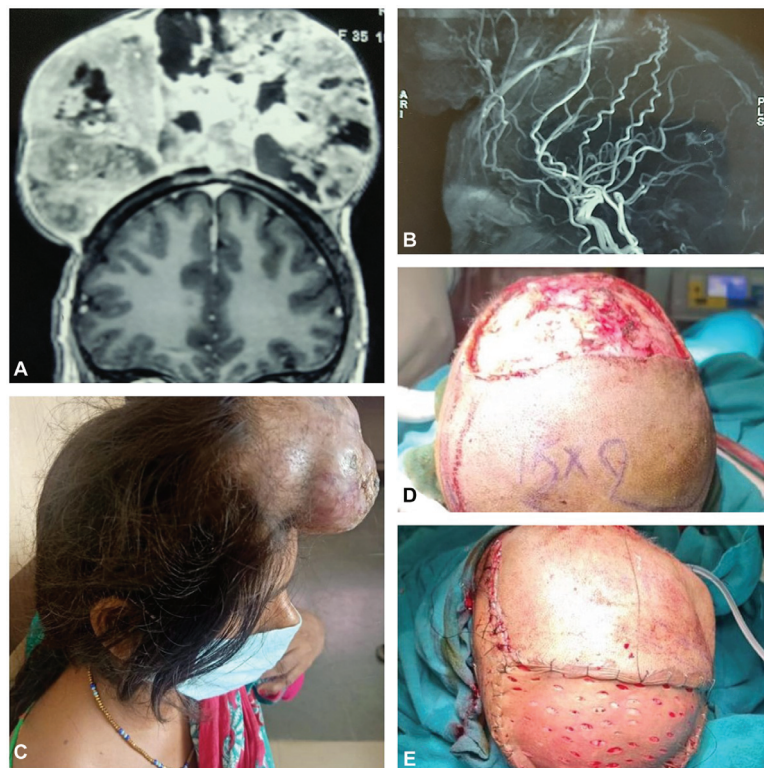


Fig. 6 (A) MRI brain with contrast revealing lesion involving bifrontal region with patchy non-enhancing area interspersed among contrast-enhancing area suggestive of necrosis. (B) MR arteriography revealing vascular tumor supplied by the superficial temporal artery. (C) Preoperative image revealing tumor mass overlying bifrontal region and overhanging anterosuperiorly. (D) Scalp defect following tumor excision. (E) Postoperative image following rotational flap reconstruction.

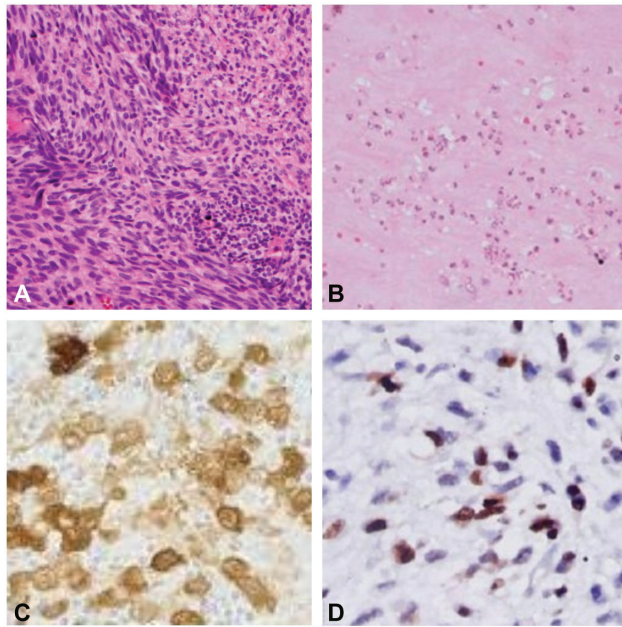


Fig. 7 (A) Pleomorphic spindle cells with mitotic figures and necrosis in between. (B) Focal S100 staining of MPNST. (C) MPNST with the area of necrosis seen. (D) Tumor showing high proliferative index ki67 70%.

were multilobulated and gave a double brain appearance. It indicates late detection of the lesion, but mostly it was unwillingness by the patient for treatment that led to such a large size.

NCCT head was suggestive of a large breach of the calvarias in occipital, temporal, and frontal bones in almost all patients, with evidence of a dural breach in two patients. MR angiography was suggestive of arterial supply from the middle meningeal and superficial temporal branch in all patients and suspected supply from the middle cerebral artery with tumor blush, suggesting high vascularity in

two patients with NF1 (►Table 3). Intraoperative DSA suggested blood supply from the middle meningeal and superficial temporal artery branches, which were embolized with n-butyl cyanoacrylate. Such high vascularity of the tumor had not been reported earlier in giant MPNST. MPNST despite being diffuse and large, is moderately vascular. Two patients were anemic with preoperative hemoglobin of 6 g/dL although they were transfused 8 units of blood as they had initial hemoglobin of 4 g/dL. Once the tumor was excised and two units of blood were transfused, their hemoglobin was 11 g/dL. It can be explained by ongoing blood loss inside the tumor cavity. If the tumor had not been embolized, the patient could have had severe blood loss during surgery, which could have been life-threatening. Such features have not been reported earlier in any of the giant MPNSTs reported to date, which needs mentioning.

Intraoperatively, there was evidence of intradural tumor invasion at places that were noted in three patients. Although scalp MPNST achieved a giant size as reported by different authors, the intradural extension had been reported by Mullins et al.² It suggests less invasiveness of the lesion inside the dura and intraparenchymal structure even if the duration of progression because the onset is long. Postoperative histopathology suggested S100 and vimentin positivity in all patients with high proliferation indices although such consistent association with the S100 marker had not been reported in earlier reported patients, suggestive of the origin of such tumors from perineurium. Its positivity in such patients is present in 50 to 90% of patients, and it may stain positive for smooth muscle actin, vimentin.¹⁰ It has no prognostic significance. In such patients, neither it has a high diagnostic value⁹ (►Table 3).

The proximity of such giant size lesions to nearby critical neurovascular structures and microscopic deposits makes complete excision difficult, and local recurrence is inevitable.

Table 2 Radiological features and management of the patients having malignant peripheral nerve sheath tumour

Patient	Radiology	Preoperative embolisation	Surgery	Breach of dura/calvaria	Histopathology and immunohistochemistry	RT/CT	Follow up
1	Diffuse heterogenous contrast enhancing lesion with erosion of calvaria	DSA suggested feeders from right ECA, embolisation with n-butylcyanoacrylate	Excision with wound cover by rotational flap	+	S-100 +ve, EMA&H-cal-desmon and SMA +ve	Both given	12 (lost to follow up)
2	Heterogeneously contrast enhancing, infiltrating the suboccipital muscles, engulfing bilateral common carotids	DSA suggested few feeders from occipital artery, embolisation done	Excision with wound cover by rotational flap.	-nt	S-100 +ve, vimentin & actin +ve	Both given	13 (lost to follow up)
3	Lesion was heterointense with mild contrast enhancement	Moderately vascular (not embolised)	Excision with rotational flap	+	S-100 +ve, SMA +ve	given	16, NED
4	Heterogeneously contrast enhancing	Moderately vascular (not embolised)	Excision with rotational flap	+	S-100 +ve, SMA +ve		12, NED
5	Heterogeneously contrast enhancement	Moderately vascular (not embolised)	Excision with rotational flap	+	S-100 +ve, vimentin +ve		24, NED

Abbreviations: NED, no evidence of disease; +present, –absent.

Table 3 Reported cases of Giant Malignant peripheral nerve sheath tumor of the scalp, and present case series

Case report (year)	Sex	Age	Location	NF (Type-1)	Bone infiltration	Time of growth (mo)	Size (cm)	IHC (S100)	Treatment	Follow up
Garg et al (2004) ¹¹	male	50	occipital	NA	Yes	96	21 × 17	+	S + RT	NA
Fukushima et al (2006) ⁷	M	38	Occipital	no	no	36	21 × 19 × 9	+	S	4 months (DOD)
Ge et al (2010) ⁸	M	52	Parietal	yes	yes	120	22 × 19	+	S	6 months
Shintaku et al ¹³	F	59	Scalp	yes	NA	18	12	–	S	18 months DOD
Chen et al (2011) ¹⁴	M	52	Rt forehead	U	U	U	U	U	U	U
Teles et al (2012) ¹	F	56	Occipital	yes	no	3	15 × 14.5 × 10.5	+	S	NA
Wang et al (2013) ⁶	M	35	Occipital	no	yes	60	10.07 × 9.38 × 6.49	–	S + RT	26 months NED
Liu et al (2016) ⁹	M	52	Rt forehead	NA	yes	60	28 × 25 × 10	+	S	60 months NED
Firdaus et al (2018) ⁴	M	45	Frontal	no	yes	24	30 × 20	+	S + RS	30 months DOD
	M	49	Frontal	no	yes	36	6 × 5 + 8 × 8	+	S + RT	12 months NED
Farinha et al ³	M	31	Fronto-parietal	no	yes	24	17 × 17	+	S + RT	
Present series										
Case 1	F	19	Temporo-parietal occipital	yes	yes	24	34 × 28 × 24	+	E + S + RT + CT	13 months, (mets, lost to follow up)
Case 2	F	23	Occipital + cervical	yes	no	36	32 × 26 × 24	+	E + S + RT	8 months, lost to follow up
Case 3	M	55	Occipital	no	yes	36	26 × 24 × 20	+	S + RT	16 months NED
Case 4	F	35	frontal	no	yes	30	24 × 20 × 18	+	E + S + RT	12 months NED
Case 5	M	60	Occipital region	no	yes	24	22 × 18 × 20	+	S + RT	24 months NED

Abbreviations: mets, metastatic lesions; CT, chemotherapy; E, embolization; NED-noevidence of disease; RT, radiotherapy; S, surgery & excision.

In the present series proximity of scalp MPNST to nearby critical neurovascular structure focusing us to leave very small residue and residual microdeposits in nearby bony and scalp margin may have caused subsequent recurrences. Different authors reported a high local recurrence rate, up to 50%, and distant metastases in nearly 20% of patients. In the present series, 40% of local recurrence with distant metastases was also noted on follow-up.^{11–13} Radiotherapy helps in local control. However, its importance in prolonging survival is debated by different authors, especially in giant-size lesions due to uncertain safe resection of the tumor because of its infiltrative nature.^{13–16} Kolberg et al did not find survival benefits following chemotherapy in their meta-analysis of patients with MPNST.¹⁶ Patients with large lesions and NF1 were started with chemotherapy, but recurrence and metastases could not shorten, raising doubt over chemotherapy in such lesions following surgery. Evans et al reported a 20% decrease in survival rate in patients with NF1, but Anghileri et al did not observe survival differences in patients associated with neurofibromatosis and sporadic cases.^{12,17} In the present series, overall poor survival of the patient with scalp MPNST was due to the diffuse spread of the lesions and proximity to the critical neuro-vascular structure where complete resection could not be achieved, and the tumor biopsy report also suggested a high proliferation index. These facts were responsible for early metastases in two patients with NF1. In patients without NF1, complete surgical excision with a safe margin was achieved, and they were

found to be disease-free at 2 years of most extended follow-up. It suggests that local control by total excision of the lesion is vital to the patient's survival despite the patient getting adjuvant radiotherapy and chemotherapy.

Conclusion

Patients with MPNST of the scalp in association with NF1 had fast tumor progression with high vascularity and proliferation index and have higher chances of recurrence and metastases with less response to radiotherapy and chemotherapy. Multimodal treatment with endovascular embolization helps decrease blood loss with safe resection of the tumor. Surgery and adjuvant treatment with RT and CT can improve survival if local excision of the tumor is complete. The present study is a small case series of a rare tumor and highlights essential observations; however, we need to have a more extensive patient series of patients with such lesions to reach significant conclusions.

Ethical Approval

Institutional ethical permission was obtained with IEC No. 441/2021.

Informed Consent

The patient's relatives' consent was taken at the time of admission to use his data for teaching and research purposes.

Conflict of Interest

None declared.

References

- 1 F. T, Amm A, Ba de L, et al. Giant malignant peripheral nerve sheath tumor of the scalp. *Acta Neurol Taiwan* 2012;21(03):133–135
- 2 Mullins BT, Hackman T. Malignant peripheral nerve sheath tumors of the head and neck: a case series and literature review. *Case Rep Otolaryngol* 2014;2014:368920. Doi: 10.1155/2014/368920
- 3 Cubas Farinha N, Belo D, Freitas H, Coiteiro D. Giant malignant peripheral nerve sheath tumor of the scalp: case report and review of the literature. *World Neurosurg* 2020;138:246–252. Doi: 10.1016/j.wneu.2020.03.039
- 4 Arshi A, Tajudeen BA, St John M. Malignant peripheral nerve sheath tumors of the head and neck: Demographics, clinicopathologic features, management, and treatment outcomes. *Oral Oncol* 2015;51(12):1088–1094
- 5 Firdaus M, Gill AS, Mukarramah DA, et al. Malignant peripheral nerve sheath tumor of the scalp: Two rare case reports. *Surg Neurol Int* 2018;9:102. Published 2018 May 15. doi: Doi: 10.4103/sni.sni_196_17
- 6 Wang J, Ou SW, Guo ZZ, Wang YJ, Xing DG. Microsurgical management of giant malignant peripheral nerve sheath tumor of the scalp: two case reports and a literature review. *World J Surg Oncol* 2013;11:269. Doi: 10.1186/1477-7819-11-269
- 7 Fukushima S, Kageshita T, Wakasugi S, et al. Giant malignant peripheral nerve sheath tumor of the scalp. *J Dermatol* 2006;33(12):865–868. Doi: 10.1111/j.1346-8138.2006.00197.x
- 8 Ge P, Fu S, Lu L, Zhong Y, Qi B, Luo Y. Diffuse scalp malignant peripheral nerve sheath tumor with intracranial extension in a patient with neurofibromatosis type 1. *J Clin Neurosci* 2010;17(11):1443–1444
- 9 Liu X, Li W, Yuan H, Gu W, Chen D. Surgical treatment of rare giant malignant tumors of the scalp: a report of 3 cases with different tumor types. *Oncol Lett* 2016;12(05):3411–3416
- 10 Guo A, Liu A, Wei L, Song X. Malignant peripheral nerve sheath tumors: differentiation patterns and immunohistochemical features—a mini-review and our new findings. *J Cancer* 2012;3:303–309. Doi: 10.7150/jca.4179
- 11 Garg A, Gupta V, Gaikwad SB, et al. Scalp malignant peripheral nerve sheath tumor (MPNST) with bony involvement and new bone formation: case report. *Clin Neurol Neurosurg* 2004;106(04):340–344
- 12 Anghileri M, Miceli R, Fiore M, et al. Malignant peripheral nerve sheath tumors: prognostic factors and survival in a series of patients treated at a single institution. *Cancer* 2006;107(05):1065–1074. Doi: 10.1002/cncr.22098
- 13 Shintaku M, Wada K, Wakasa T, Ueda M. Malignant peripheral nerve sheath tumor with fibroblastic differentiation in a patient with neurofibromatosis type 1: imprint cytological findings. *Acta Cytol* 2011;55(05):467–472. Doi: 10.1159/000330676
- 14 Chen DW, Gu WH, Fu SL. Giant scalp malignant peripheral nerve sheath tumor: one case report [article in Chinese]. *Zhonghua Er Bi Yan Hou Tou Jing Wai Ke Za Zhi* 2011;46(12):1047–1048
- 15 Gousias K, Boström J, Kovacs A, Niehusmann P, Wagner I, Kristof R. Factors of influence upon overall survival in the treatment of intracranial MPNSTs. Review of the literature and report of a case. *Radiat Oncol* 2010;5(01):114. DOI: Doi: 10.1186/1748-717X-5-114
- 16 Kolberg M, Høland M, Agesen TH, et al. Survival meta-analyses for >1800 malignant peripheral nerve sheath tumor patients with and without neurofibromatosis type 1. *Neuro-oncol* 2013;15(02):135–147. Doi: 10.1093/neuonc/nos287
- 17 Evans DGR, Baser ME, McGaughan J, Sharif S, Howard E, Moran A. Malignant peripheral nerve sheath tumours in neurofibromatosis 1. *J Med Genet* 2002;39(05):311–314. Doi: 10.1136/jmg.39.5.311