



A Case of Malignant Melanotic Schwannoma of the Trigeminal Nerve: A Case Report and Review of Literature

Anurag Chandrakant Dandekar¹ Nirav A. Mehta¹

¹Department of Neurosurgery, Bombay Hospital & Medical Research Centre, Mumbai, Maharashtra, India

AJNS 2023;18:352–356.

Address for correspondence Anurag Chandrakant Dandekar, MBBS, MS, MCH (3rd year), Department of Neurosurgery, Bombay Hospital & Medical Research Centre, Marine Lines, Mumbai, Maharashtra, 400020, India (e-mail: dr.anurag49@gmail.com).

Abstract

Intracranial melanotic schwannoma is quite rare, and involvement of the trigeminal nerve is even rarer. Early diagnosis and surgical excision are the mainstays of management. These tumors have a high tendency to recur and there is high possibility of metastasis. Adjuvant radiotherapy should be considered since the prognosis is uncertain. A 23-year-old man started developing numbness over the left side of the forehead 9 months ago that progressed to involve the ipsilateral cheek. The patient started having diplopia on looking to the left side 8 months ago. His relatives noticed a change in his voice 1 month ago and he developed weakness in the right upper and lower limbs, which was gradually progressive. The patient had slight difficulty swallowing. After examination, we found involvement of multiple cranial nerves with pyramidal signs. Magnetic resonance imaging (MRI) was suggestive of an extra-axial lesion in the left cerebellopontine angle extending into the middle cranial fossa, which was having high T1 and T2 signal loss with contrast enhancement. We achieved near-total excision of the tumor via a subtemporal extradural approach. Trigeminal melanotic schwannoma is a rare occurrence constituting melanin-producing cells and Schwann cells. Rapid progression of symptoms and signs should prompt the suspicion of the possible malignant nature of the pathology. Extradural skull base approaches reduce the risk of postoperative deficits. Differentiating melanotic schwannoma from malignant melanoma is of utmost importance in planning of management.

Keywords

- ▶ melanotic schwannoma
- ▶ trigeminal schwannoma
- ▶ Meckel's cave
- ▶ gasserian ganglion
- ▶ dumbbell-shaped tumors

Introduction

Although the trigeminal nerve is the second most common intracranial site of origin for schwannomas after the vestibular nerve, trigeminal schwannomas are far less common than vestibular schwannomas. Melanotic schwannomas (MSs) are nerve sheath tumors containing

melanin. These are rare peripheral nerve sheath tumors and the intracranial presentation has been reported 18 times in the literature, out of which trigeminal nerve involvement was seen only 6 times (▶ **Table 1**).¹ We present one such case of a young male highlighting the rapid progression of symptoms, radiology, and surgical approach.

article published online
June 7, 2023

DOI <https://doi.org/10.1055/s-0043-1768578>.
ISSN 2248-9614.

© 2023. Asian Congress of Neurological Surgeons. All rights reserved.

This is an open access article published by Thieme under the terms of the Creative Commons Attribution-NonDerivative-NonCommercial-License, permitting copying and reproduction so long as the original work is given appropriate credit. Contents may not be used for commercial purposes, or adapted, remixed, transformed or built upon. (<https://creativecommons.org/licenses/by-nc-nd/4.0/>)

Thieme Medical and Scientific Publishers Pvt. Ltd., A-12, 2nd Floor, Sector 2, Noida-201301 UP, India

Table 1 Review of literature¹

Study	No. of cases	Age (y)	Sex	Resection	Adjuvant therapy	Follow-up (mo)	Recurrence at last follow-up
Quencer et al ³⁴	1	22	M	GTR	None	14	None
Beck and Menezes ³⁵	1	12	M	N/A	Radiation therapy (recurrence after 2 y)	108	None
Carney ³⁰	2	N/A	N/A	N/A	N/A	N/A	N/A
Buhl et al ³⁶	1	28	M	GTR	None	N/A	N/A
Carrasco et al ³⁷	1	34	F	STR	None	3	Yes

Abbreviations: F, female; GTR, gross total resection; M, male; N/A, not available; STR, subtotal resection.

Case Description

A 23-year-old man, right-handed, started having numbness over his forehead on the left side 9 months ago, which later increased over a period of 10 to 15 days to involve areas over the ipsilateral cheek and sparing his lower jaw and angle of the mandible. He started having diplopia on the left horizontal gaze, 15 days after the appearance of the first symptom. The patient was evaluated for the same at another institute and magnetic resonance imaging (MRI) was done, which showed an extra-axial lesion in the left cerebellopontine angle involving the trigeminal nerve extending into the middle cranial fossa (►Fig. 1). The lesion was hyperintense on T1-weighted images, hypointense on T2-weighted images, and showed avid contrast enhancement. He was advised by the treating surgeon to undergo surgery, but because of some personal reasons, surgery was deferred. Three months ago, the patient started to experience occasional headaches, which were dull aching and holocranial. The patient and his relatives started experiencing a change in his voice quality for the last 1 month. The patient was having progressive weakness in his right upper limb and right lower limb for the last 15 days, which made it difficult for him to walk. He had difficulty chewing from the left side. There was no history of facial pain or any complaints regarding taste, hearing, or swallowing. On examination, we found that he was having wasting of the temporalis and masseter muscles on the left side, decreased sensation in the left ophthalmic

and maxillary nerve territory with a loss of corneal reflex, left sixth nerve paresis, subtle left-sided facial weakness, weak gag reflex on the left side, and pyramidal signs. Power in his right upper and lower limb was 4/5. There were no cerebellar signs (nystagmus). We did not find any neurocutaneous markers. We did an MRI of the brain with contrast (►Fig. 2), which was suggestive of a well-circumscribed dumbbell-shaped extra-axial lesion in the left cerebellopontine angle extending to the middle cranial fossa and was almost double the size it was 8 months ago. The lesion was hyperintense on T1-weighted images and hypointense on T2-weighted images, showing homogenous contrast enhancement. We performed a left subtemporal craniotomy and achieved gross total resection of the lesion via an extradural approach. The tumor was blackish in color, soft in consistency, and easily suckable (►Fig. 3). Postoperatively the patient showed improvement in the left-sided sixth nerve paresis, right-sided upper limb and lower limb weakness, and normal bilateral gag reflex. On microscopy, there were sheets of tumor cells with prominent melanin pigment deposition obscuring morphologic features, cells with marked nuclear pleomorphism, bizarre nuclear forms, giant cells with large prominent nucleoli, and abundant cytoplasm (►Fig. 4). Nerve twigs were identified in the wall of the lesion. On immunohistochemistry, the tumor cells were positive for S100 and HMB45. The tumor cells showed retained expression for H3K27Me3 protein and were negative for P53. Mib-1 labeling index was approximately 4 to 6%.

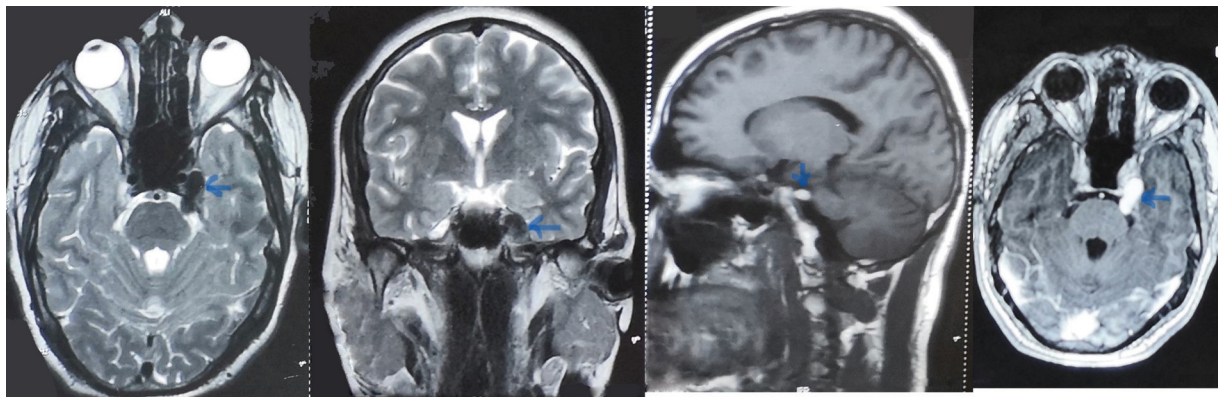


Fig. 1 A 9-month-old sagittal T1-weighted image showing hyperintense lesion (blue arrow), axial T2-weighted image showing hypointense lesion (blue arrow), coronal T2-weighted image showing hypointense lesion (blue arrow), and axial T1 with gadolinium contrast images showing homogenous enhancement of lesion (blue arrow).

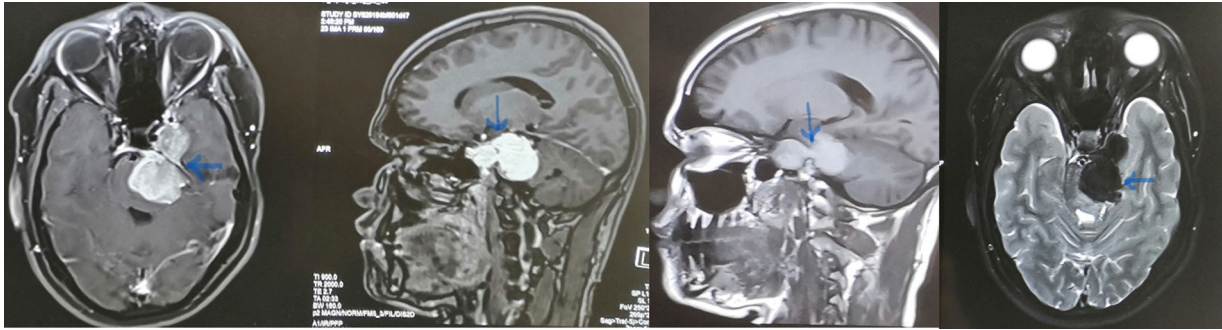


Fig. 2 Recent sagittal T1-weighted images showing dumbbell-shaped hyperintense lesion (blue arrow), axial T2-weighted image showing hypointense lesion (blue arrow), and gadolinium contrast-enhanced images showing homogenous enhancement of lesion (blue arrows).

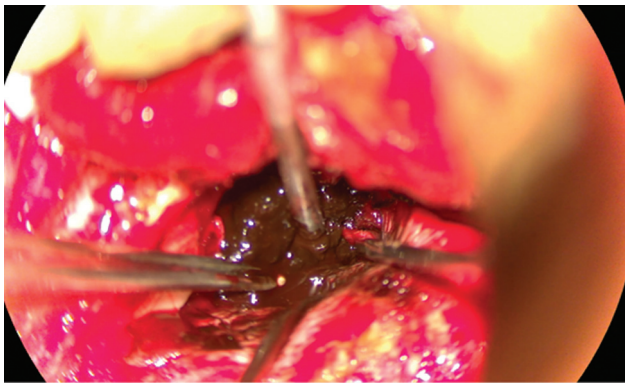


Fig. 3 Intraoperative images showing black-colored lesion.

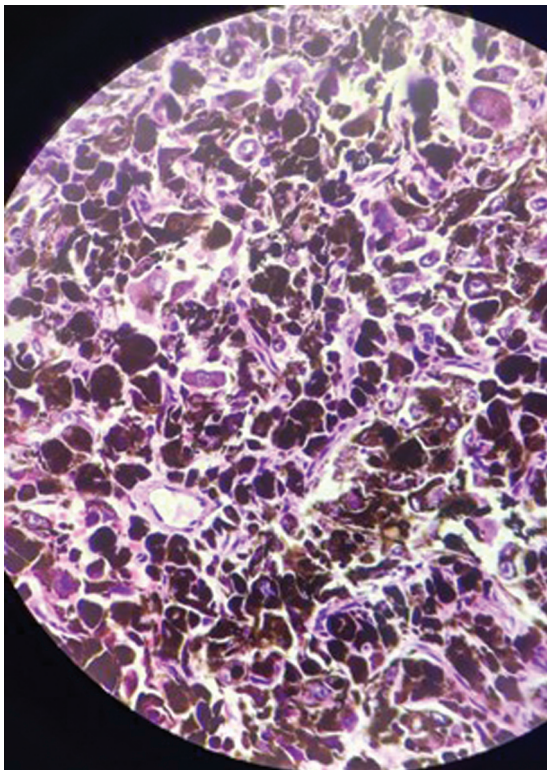


Fig. 4 Histopathological image showing tumor cells with prominent melanin pigment deposition and nuclear pleomorphism.

The final histopathology report was suggestive of malignant MS. The patient was advised adjuvant radiation therapy and follow-up.

Discussion

Schwannomas make up 8% of intracranial tumors,² and trigeminal schwannomas account for 0.8 to 8.0% of all intracranial schwannomas.^{3,4} Out of these trigeminal schwannomas, so far only six cases have been identified as MSs in the literature.¹ MSs contain melanin-producing cells and were first described by W.G. Millar in 1932 and the nomenclature was done by Fu et al in 1975.^{5,6} MSs are usually present in the fourth or fifth decade of life and there is no sex predilection.⁷ Our patient was a 23-year-old man, which made it an unusual age of presentation.

As per the 2021 WHO Classification of Tumors of the Central Nervous System, the previously designated “melanotic schwannoma” has been changed to malignant melanotic nerve sheath tumor. The central myelin–peripheral myelin transition zone of the trigeminal nerve root sheath is at a mean of 1.13 mm on the medial side and 2.47 mm on the lateral side away from the root entry zone at the brainstem.⁸ Schwannomas arise from the peripheral myelin zone. According to the point of origin, the tumor may be localized to the middle fossa (commonly referred as the ganglion type), the posterior fossa (commonly referred as the root type), or the extracranial space, or it may extend into multiple compartments.⁹ The location of the tumor also directs the surgical approach. Therefore, several surgical classification schemes have been proposed to guide the surgical approach. Jefferson proposed a very useful scheme in 1953 and classified trigeminal schwannomas as middle fossa (type A), posterior fossa (type B), and dumbbell-shaped (type C) tumors.¹⁰ Day and Fukushima modified the scheme slightly in their 1998 study. They also described type D tumors, which arise from the extracranial portion of the trigeminal nerve.⁹

Patients with trigeminal schwannoma present with facial hypoesthesia as the most common trigeminal symptom and is present in 70% of affected patients.¹¹ This was also the presenting complaint of our patient. Facial pain or trigeminal motor dysfunction is less common. In the case of large

tumors, lower cranial nerve deficits can be seen.^{12,13} Difficulty in chewing and masseter and temporalis muscle wasting may be seen in the cases with extracranial extension.¹⁴ Headaches, focal seizures, and long tract signs are also seen in these patients. In our patient, the progression of symptoms from first as facial hypoesthesia to long tract signs escalated quite quickly. This rapid progression of symptoms could have been the indicator of the malignant nature of the disease.

MRI is the gold standard in the assessment of these tumors. These lesions are isointense to slightly hyperintense on T1-weighted images and isointense to hypointense on T2-weighted images.¹⁵ A recently reported study revealed that due to the presence of melanin granules, MS and metastatic schwannomas have a similar appearance on MRI. A dumbbell-shaped growth and cystic structure are the indirect signs that favor MS over metastatic schwannomas.¹⁶ The differential diagnosis includes other melanotic lesions, such as malignant melanoma, pigmented meningioma, and medulloblastoma.¹⁷ In our patient, the lesion was hyperintense on T1-weighted images and hypointense on T2-weighted images, and showed homogenous contrast enhancement. It was a dumbbell-shaped lesion in both the middle and posterior fossae. All the radiological features were pointing toward the MS.

Classically, trigeminal schwannomas in the middle fossa (type A) have been resected via pterional trans-sylvian, subtemporal interdural, frontotemporal interdural, or the frontotemporal extradural approaches.^{18–21} Trigeminal schwannomas located solely in the posterior fossa (type B) can easily be resected via a conventional paramedian suboccipital or retro-sigmoid approach. Type C trigeminal schwannomas are the most challenging to treat because these tumors have large components in both the middle and posterior fossae. A subtemporal transtentorial route was advocated by Bordi et al and McCormick et al.^{22,23} Endoscopic endonasal transpterygoid approaches have also been devised with reported gross total resection rates of 63 to 100%.^{24–28} Large, symptomatic trigeminal schwannomas are best treated by surgical resection. Radiosurgery is considered an important adjuvant for residual or recurrent tumors smaller than 3 cm in diameter and in patients with symptoms in whom surgery carries a high risk of mortality and morbidity. The aim of radiosurgery is to achieve control of tumor growth without causing additional cranial nerve deficits. Fractionated external beam radiotherapy is used mainly for recurrent and inoperable trigeminal schwannomas.

We performed a subtemporal craniotomy and approached the tumor extradurally to excise the lesion in the middle fossa and accessed the posterior fossa lesion through Meckel's cave. MSs are prone to local recurrence and have a metastatic potential.^{29–31} The role of adjuvant radiation therapy is debatable. Despite encouraging data, no clinical series have been published to date on the effectiveness of radiotherapy. But we advised our patient radiation therapy keeping in mind the rapid progression and risk of recurrence of the disease.

The differential diagnosis of malignant MS include neurofibroma, melanocytoma, malignant melanoma, and pig-

mented dermatofibrosarcoma protuberans (Bednar's tumor). The neurofibroma nuclei are small and often elongated, unlike those of MS, which tend to be round or ovoid, with distinct nucleolus.³² Melanocytoma is a solitary, low-grade tumor, originating from leptomeningeal melanocytes, devoid of psammoma bodies, and lack pericellular basement membrane and adiposelike cells. MS is favored over malignant melanoma if the tumor arises in ganglia, features psammoma bodies and adiposelike cells, has cells with benign or mildly atypical cytology, and demonstrates evidence of pericellular basement membrane synthesis.^{32,33}

Conclusion

Trigeminal MSs are rare and have malignant potential. Clinicians should be aware of the radiological features to differentiate it from classical schwannomas, which could result in early intervention and the possibility of cure. Complete surgical excision followed by adjuvant radiation therapy is desired to stand a chance for cure. Histology and immunohistochemistry are the confirming tests that form the basis to distinguish it from malignant melanoma and change the course of the treatment altogether. Patients require long-term follow-up to gather more information about this disease.

Conflict of Interest

None declared.

References

- Spina A, Gagliardi F, Boari N, Terreni MR, Mortini P. Intracranial melanotic schwannomas. *J Neurol Surg A Cent Eur Neurosurg* 2015;76(05):399–406
- Ostrom QT, Gittleman H, Liao P, et al. CBTRUS statistical report: primary brain and central nervous system tumors diagnosed in the United States in 2007–2011. *Neuro-oncol* 2014;16(Suppl 4):iv1–iv63
- Lesoin F, Rousseaux M, Villette L, et al. Neurinomas of the trigeminal nerve. *Acta Neurochir (Wien)* 1986;82(3–4):118–122
- de Benedittis G, Bernasconi V, Ettorre G. Tumours of the fifth cranial nerve. *Acta Neurochir (Wien)* 1977;38(1–2):37–64
- Millar WG. A malignant melanotic tumor of ganglion cells arising from a thoracic sympathetic ganglion. *J Pathol Bacteriol* 1932;35:351–357
- Fu YS, Kaye GI, Lattes R. Primary malignant melanocytic tumors of the sympathetic ganglia, with an ultrastructural study of one. *Cancer* 1975;36(06):2029–2041
- Gulati HK, Joshi AR, Anand M, Deshmukh SD. Non psammomatous melanocytic schwannoma presenting as a subcutaneous nodule: a rare presentation of a rare lesion. *Asian J Neurosurg* 2016;11(03):317–318
- Peker S, Kurtkaya O, Uzün I, Pamir MN. Microanatomy of the central myelin-peripheral myelin transition zone of the trigeminal nerve. *Neurosurgery* 2006;59(02):354–359, discussion 354–359
- Day JD, Fukushima T. The surgical management of trigeminal neuromas. *Neurosurgery* 1998;42(02):233–240, discussion 240–241
- Jefferson G. The trigeminal neurinomas with some remarks on malignant invasion of the gasserian ganglion. *Clin Neurosurg* 1953;1:11–54

- 11 Yoshida K, Kawase T. Trigeminal neurinomas extending into multiple fossae: surgical methods and review of the literature. *J Neurosurg* 1999;91(02):202–211
- 12 Goel A, Muzumdar D, Raman C. Trigeminal neuroma: analysis of surgical experience with 73 cases. *Neurosurgery* 2003;52(04):783–790, discussion 790
- 13 Sharma BS, Ahmad FU, Chandra PS, Mahapatra AK. Trigeminal schwannomas: experience with 68 cases. *J Clin Neurosci* 2008;15(07):738–743
- 14 Goel A, Shah A, Muzumdar D, Nadkarni T, Chagla A. Trigeminal neurinomas with extracranial extension: analysis of 28 surgically treated cases. *J Neurosurg* 2010;113(05):1079–1084
- 15 Agrawal A, Singh V, Rohilla S, Sharma B. Trigeminal schwannoma. *Natl J Maxillofac Surg* 2017;8(02):149–152
- 16 Nenashev EA, Rotin DA, Stepanian MA, Kadasheva AB, Cherekaev VA. [Differential diagnosis between melanotic schwannoma of gasserian ganglion and metastatic melanoma of middle cranial fossa. *Vopr Neurokhir* 2012;76(02):58–64, discussion 64
- 17 Liessi G, Barbazza R, Sartori F, Sabbadin P, Scapinello A. CT and MR imaging of melanocytic schwannomas; report of three cases. *Eur J Radiol* 1990;11(02):138–142
- 18 Dolenc VV. Frontotemporal epidural approach to trigeminal neurinomas. *Acta Neurochir (Wien)* 1994;130(1–4):55–65
- 19 Samii M, Migliori MM, Tatagiba M, Babu R. Surgical treatment of trigeminal schwannomas. *J Neurosurg* 1995;82(05):711–718
- 20 Taha JM, Tew JM Jr, van Loveren HR, Keller JT, el-Kalliny M. Comparison of conventional and skull base surgical approaches for the excision of trigeminal neurinomas. *J Neurosurg* 1995;82(05):719–725
- 21 Mariniello G, Cappabianca P, Buonamassa S, de Divitiis E. Surgical treatment of intracavernous trigeminal schwannomas via a fronto-temporal epidural approach. *Clin Neurol Neurosurg* 2004;106(02):104–109
- 22 McCormick PC, Bello JA, Post KD. Trigeminal schwannoma. Surgical series of 14 cases with review of the literature. *J Neurosurg* 1988;69(06):850–860
- 23 Bordi L, Compton J, Symon L. Trigeminal neuroma. A report of eleven cases. *Surg Neurol* 1989;31(04):272–276
- 24 Komatsu F, Komatsu M, Di Ieva A, Tschabitscher M. Endoscopic approaches to the trigeminal nerve and clinical consideration for trigeminal schwannomas: a cadaveric study. *J Neurosurg* 2012;117(04):690–696
- 25 Raza SM, Donaldson AM, Mehta A, Tsiouris AJ, Anand VK, Schwartz TH. Surgical management of trigeminal schwannomas: defining the role for endoscopic endonasal approaches. *Neurosurg Focus* 2014;37(04):E17
- 26 Zhang QH, Chen G, Kong F, Guo HC, Li MC. Endoscopic endonasal surgery of trigeminal schwannoma extending into the infratemporal fossa. *Zhonghua Wai Ke Za Zhi* 2010;48(19):1454–1458
- 27 Shin SS, Gardner PA, Stefko ST, Madhok R, Fernandez-Miranda JC, Snyderman CH. Endoscopic endonasal approach for nonvestibular schwannomas. *Neurosurgery* 2011;69(05):1046–1057, discussion 1057
- 28 Haidar H, Deveze A, Lavieille JP. Mini-invasive surgery of infratemporal fossa schwannomas. *J Laryngol Otol* 2015;129(02):187–193
- 29 Antonescu Cr, Stratakis CA, Woodruff JM. Melanotic schwannoma. In: Fletcher CDM, Bridge JA, Hogendorn PCW, Martens F, eds. *Pathology and Genetics of Tumours of Soft Tissue and Bone*. Lyon, France: IARC Press; 2013:173
- 30 Carney JA. Psammomatous melanotic schwannoma. A distinctive, heritable tumor with special associations, including cardiac myxoma and the Cushing syndrome. *Am J Surg Pathol* 1990;14(03):206–222
- 31 Torres-Mora J, Dry S, Li X, Binder S, Amin M, Folpe AL. Malignant melanotic schwannian tumor: a clinicopathologic, immunohistochemical, and gene expression profiling study of 40 cases, with a proposal for the reclassification of “melanotic schwannoma.”. *Am J Surg Pathol* 2014;38(01):94–105
- 32 Rodriguez FJ, Stratakis CA, Evans DG. Genetic predisposition to peripheral nerve neoplasia: diagnostic criteria and pathogenesis of neurofibromatosis, Carney complex, and related syndromes. *Acta Neuropathol* 2012;123(03):349–367
- 33 Kurtkaya-Yapici O, Scheithauer B, Woodruff JM. The pathobiologic spectrum of Schwannomas. *Histol Histopathol* 2003;18(03):925–934
- 34 Quencer RM, Stokes NA, Wolfe D, Page LK. Melanotic nerve sheath tumor of the gasserian ganglion and trigeminal nerve. *AJR Am J Roentgenol* 1979;133(01):142–144
- 35 Beck DW, Menezes AH. Lesions in Meckel's cave: variable presentation and pathology. *J Neurosurg* 1987;67(05):684–689
- 36 Buhl R, Barth H, Hugo HH, Mautner VF, Mehdorn HM. Intracranial and spinal melanotic schwannoma in the same patient. *J Neurooncol* 2004;68(03):249–254
- 37 Carrasco CA, Rojas-Salazar D, Chiorino R, Venega JC, Wohlk N. Melanotic nonpsammomatous trigeminal schwannoma as the first manifestation of Carney complex: case report. *Neurosurgery* 2006;59(06):E1334–E1335, discussion E1335