



Piggyback Technique—A Safe Way of Performing Rib Biopsy

Rajesh Botchu¹ Neha Nischal^{1,2} Bhuvan Botchu³ Karthikeyan P. Iyengar⁴

¹Department of Musculoskeletal Radiology, Royal Orthopaedic Hospital, Birmingham, United Kingdom

²Department of Radiology, Holy Family Hospital, New Delhi, India

³Solihull Secondary School, Solihull, United Kingdom

⁴Department of Orthopaedics, Southport and Ormskirk NHS Trust, Southport, United Kingdom

Address for correspondence Rajesh Botchu, MRCS, FRCR, Royal Orthopaedic Hospital, Bristol Road South, Northfield B21 3AP, Birmingham, United Kingdom (e-mail: drbrajesh@yahoo.com).

Indian J Radiol Imaging 2023;33:541–542.

Abstract

Keywords

- ▶ rib biopsy
- ▶ piggyback technique
- ▶ image-guided

Rib biopsy can be challenging. A spectrum of bone biopsy techniques are available to undertake Rib Bone biopsy and yield a histological specimen. In this technical report, we described a new Piggyback technique of performing rib biopsy to decrease the incidence of pneumothorax and consolidate diagnostic accuracy.

Introduction

Image-guided bone biopsy is the mainstay for diagnosis of osseous lesions that is safe with low morbidity. These are done as day case procedures with excellent diagnostic yield. Baffour et al had showed diagnostic yield of 99% for lytic rib lesions and 92% for sclerotic rib lesions.¹ Percutaneous image-guided biopsies of rib lesions can be challenging due to proximity to lung, the thin caliber of the ribs, respiratory movement, and smooth contour of the ribs. Stabilization of the biopsy needle during the initial steps can be technically challenging and if not done accurately might result in a pneumothorax. Manually holding the needle to stabilize may increase radiation to the performing radiologist and clinician to their hands. This can be avoided or decreased by using techniques that include dual steristrip technique, BITT (Birmingham Intervention Tent Technique), SAHNA (surface adhesive and hand-aided needle-assisted biopsy technique) technique.^{2–4}

Technique

We describe a new technique to safely perform rib biopsy by using the adjacent rib as a support to guide and stabilize the biopsy needle—Piggyback technique.

The steps of this technique are as follows:

1. Patient is positioned in a lateral decubitus position.
2. After initial planning computed tomography, the trajectory/path of the biopsy is planned to ensure the adjacent rib is used as a support.
3. Using aseptic technique, after infiltration of the skin with local anesthetic, a small incision is made on the skin.
4. The biopsy needle is then advanced over the supporting rib into the rib lesion (▶ **Figs. 1 and 2**).
5. The inner trocar is then removed and the biopsy needle is advanced into the rib lesion using the adjacent rib as support.

We found this technique to be extremely useful in biopsy of small rib lesions in particular lesions involving the inner cortex of the rib. The adjacent rib prevents the medial displacement of the biopsy needle, hence decreasing the risk of pneumothorax. This can be used in any part of the rib, anterior or posterior, with meticulous planning. Any type of lesion, lytic or sclerotic, may be targeted with this approach. In fact, sclerotic lesions are usually more challenging and time-consuming to biopsy and this technique can help in overcoming problems with anchoring the needle.

article published online
May 6, 2023

DOI <https://doi.org/10.1055/s-0043-1768642>.
ISSN 0971-3026.

© 2023. Indian Radiological Association. All rights reserved.
This is an open access article published by Thieme under the terms of the Creative Commons Attribution-NonDerivative-NonCommercial-License, permitting copying and reproduction so long as the original work is given appropriate credit. Contents may not be used for commercial purposes, or adapted, remixed, transformed or built upon. (<https://creativecommons.org/licenses/by-nc-nd/4.0/>)
Thieme Medical and Scientific Publishers Pvt. Ltd., A-12, 2nd Floor, Sector 2, Noida-201301 UP, India

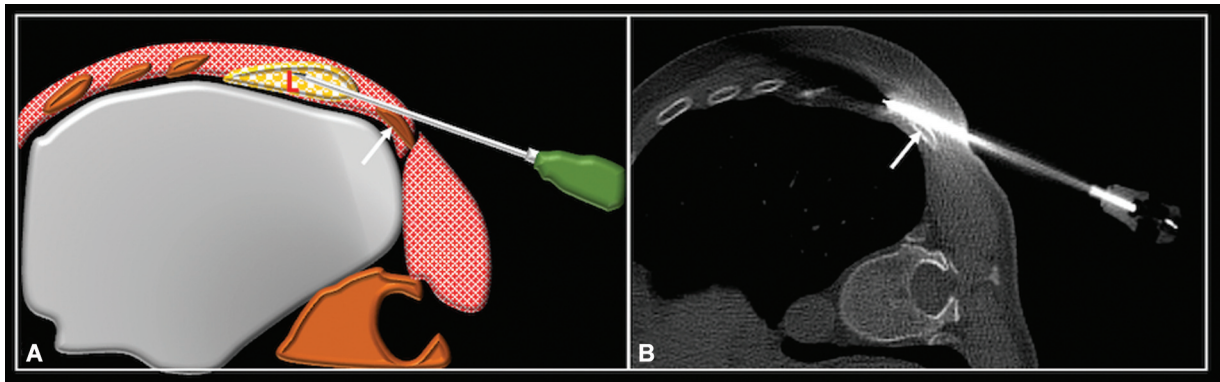


Fig. 1 Axial computed tomography showing needle with trocar in the rib lesion (A) using the adjacent rib as a piggyback (arrow). The trocar has been removed and needle advanced into the lesion (B).

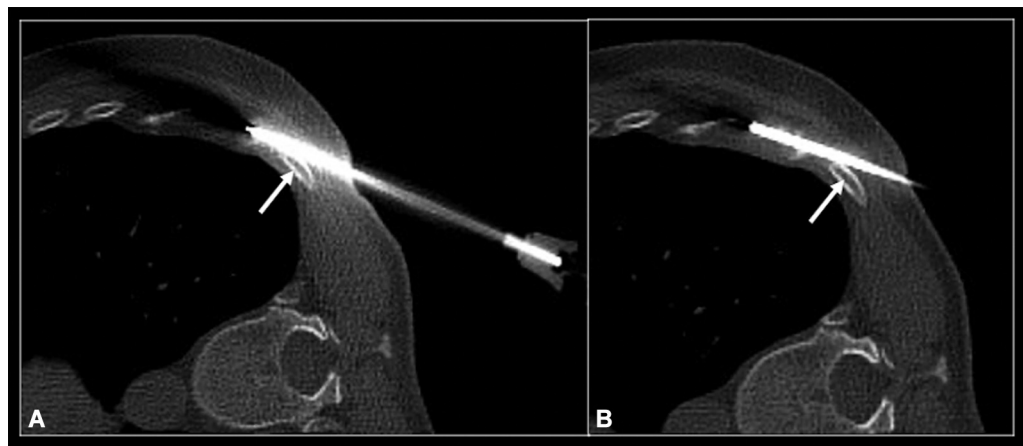


Fig. 2 Axial schematic (A) and computed tomography (B) showing biopsy needle with tip in the rib lesion using the adjacent rib as a piggyback (arrow).

Discussion

In our experience, piggyback technique is a safe, inexpensive, and effective way of biopsying rib lesions. These can be used in conjunction with other techniques previously described. Dual steristrip technique, BITT or SAHNA technique, helps to stabilize the needle and hence decrease radiation to the hand of the operator. Dual steristrip technique uses steristrips to stabilize the bone biopsy needle in relatively superficially located lesions. One end of a steristrip is affixed to the skin 2 cm from the needle skin entry point. It is then wrapped around the biopsy needle and the other end affixed to the skin at the opposite side of the needle. A second steristrip is then applied similarly at right angles to the first one. In the BITT, a plastic surgical forceps clamp is attached at an angle to the biopsy needle, creating a tent shape with the finger rings of the forceps stabilized on the table. The SAHNA technique also uses plastic forceps clamp to stabilize the needle, but in this case, the shank of the forceps clamp is stuck to the underlying skin with an adhesive dressing.

In the piggyback technique, the adjacent rib acts as a fulcrum over which the biopsy needle can be advanced and trajectory prevents the needle from deviating medially. This technique has been used successfully in our institute without any complications.

It is easy to learn and can be used for biopsy of any rib but is of particular use of rib lesion involving the second to tenth ribs.

Funding

None.

Conflict of Interest

None declared.

References

- 1 Baffour FI, Moynagh MR, Eiken PW, et al. Effectiveness and safety of percutaneous CT-guided rib biopsy. *J Vasc Interv Radiol* 2019; 30(01):82–86
- 2 Rajakulasingam R, Iqbal A, James SL, Botchu R. Surface adhesive and hand-aided needle-assisted biopsy technique (SAHNA). *Skeletal Radiol* 2020;49(03):469–473
- 3 Rajakulasingam R, Kho J, Almeer G, Azzopardi C, James SL, Botchu R. Birmingham Intervention Tent Technique (BITT): a technical note. *Indian J Radiol Imaging* 2021;31(02):521–523
- 4 McLoughlin E, Iqbal A, Patel A, James SL, Botchu R. Dual steristrip technique: a novel use of steristrips to reduce operator radiation dose during CT-guided intervention. *Skeletal Radiol* 2019;48(10): 1617–1620