




Cerebral Myiasis Secondary to Burr Hole Evacuation: A Rare Illustrative Case Report

Rama Chandra Deo¹ Abhijit Acharya¹  Souvagya Panigrahi¹ Satya Bhusan Senapati¹
A.K. Mahapatra¹ Sumirini Puppala²

¹Department of Neurosurgery, IMS & SUM Hospital, Bhubaneswar, Odisha, India

²Department of Neurology, IMS & SUM Hospital, Bhubaneswar, Odisha, India

Address for correspondence Sumirini Puppala, DM, Department of Neurology, IMS & SUM Hospital, BBSR, Bhubaneswar, Odisha, 751003, India (e-mail: sumirini@gmail.com).

AJNS 2023;18:410–413.

Abstract

Myiasis (maggot infestation) is a condition in which fly maggots feed off and develop in the tissues of living organisms. Most common in tropical and subtropical regions, human myiasis, is prevalent among individuals in close association of domestic animals and those inhabiting the unhygienic conditions. We, hereby, describe a rare case of cerebral myiasis (17th in the world, 3rd in India) that presented to our institution in Eastern India secondary in the operated site of craniotomy and burr hole few years back. Cerebral myiasis are exceedingly rare conditions, especially in high-income countries with only 17 previously published cases with the reported mortality as high as 6 out of 7 cases dying of the disease. We additionally also present a compiled review of previous case literatures to highlight the comparative clinical, epidemiological features and outcome of such cases. Although rare, brain myiasis should be a differential diagnosis of surgical wound dehiscence in developing countries where conditions do exist in this country that permit myiasis. This differential diagnosis should be remembered, particularly when the classic signs of inflammation are not present.

Keywords

- ▶ cerebral myiasis
- ▶ encephalitis
- ▶ maggots
- ▶ seizures
- ▶ wound dehiscence

Introduction

Myiasis (maggot infestation) is a condition in which fly maggots feed off and develop in the tissues of living organisms.¹ Most common in tropical and subtropical regions,² human myiasis is prevalent among individuals in close association of domestic animals and those inhabiting the unhygienic conditions.^{3,4} Other factors like immunocompromised status, diabetes, unhygienic conditions, and delay in seeking medical attention, may contribute to its prevalence.⁵ In developed

nations, it is typically associated with travel or immigration from endemic areas. Cerebral localization of myiasis is exceedingly rare^{2,5,6} and the involvement of a large area of brain tissue can result in very severe manifestations. Till date, only 17 such cases of cerebral myiasis have been reported.

We, hereby, describe another such rare case of cerebral myiasis that presented to our institution in Eastern India. We additionally also present a compiled review of previous case literatures to highlight the comparative clinical, epidemiological features and outcome of such cases.

article published online
June 16, 2023

DOI <https://doi.org/10.1055/s-0043-1769895>.
ISSN 2248-9614.

© 2023. Asian Congress of Neurological Surgeons. All rights reserved.

This is an open access article published by Thieme under the terms of the Creative Commons Attribution-NonDerivative-NonCommercial-License, permitting copying and reproduction so long as the original work is given appropriate credit. Contents may not be used for commercial purposes, or adapted, remixed, transformed or built upon. (<https://creativecommons.org/licenses/by-nc-nd/4.0/>)

Thieme Medical and Scientific Publishers Pvt. Ltd., A-12, 2nd Floor, Sector 2, Noida-201301 UP, India

Case Report

In November 2022, a 64-year-old male was brought to us with the complaint of multiple episodes of focal seizures and altered sensorium for the past 5 days, nonresponsive to medications. He presented with a large cranial lesion over the left temporal region with exposed brain and severe maggot infestation.

Tracing back the history, the patient was diagnosed with left frontoparietal chronic subdural hematoma in March of the year 2014. Hematoma evacuation with burr hole was done and the patient was discharged thereafter under satisfactory conditions. Two months postoperatively, he developed acute onset right-sided hemiplegia with slurring of speech. Repeat neuroimaging (noncontrast computed tomography [CT] brain) was done. It was suggestive of large hematoma with mass effect with midline shift. Hence, craniotomy and repeat hematoma evacuation were done through the same site as before. He improved postsurgery and improved over period of 15 to 20 days and was asymptomatic over the next 4 years. He was on regular medications but did not follow up thereafter. Unfortunately, due to improper hygiene, care and missed clinical appointments, the patient developed a small sinus at the operated site of burr hole with serous discharge. He showed to a local physician and the sinus apparently healed with medications. The lesion recurred with continuous foul-smelling bloody discharge for the past 10 days with enlarging left temporal extensive ulcerative lesion over the flap. As the patient clinically worsened, he was brought to our department.

The patient lived alone and was negligent to his wound. He had been taken to seek medical attention repeatedly but had always been partly compliant. Maggot infestation went unrecognized by family.

Physical examination revealed left temporal scalp and cranial calvarium erosion (4 cm × 5 cm; ► **Fig. 1**). The edges of the skin were hypertrophied and erythematous with eroded frontal dura, exposed cortex, and massive cortical maggot infestation. A cluster of approximately 20 to 30 motile maggots was found at the center of the defect with apparent

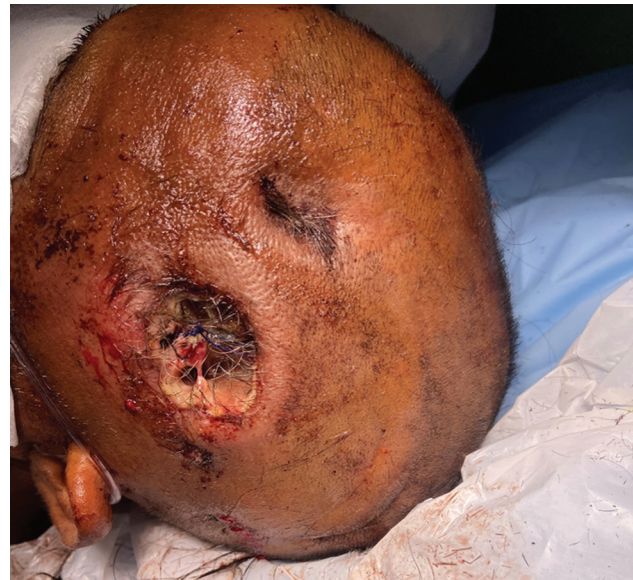

Fig. 1 A large temporal cranial lesion with exposed brain and severe maggot infestation.

serosanguinous discharge. The lesion smelled of rotten eggs (► **Video 1**). A plain CT scan of head was done (► **Fig. 2**) that revealed an extensive left frontotemporal defect with brain exposure.

Video 1

A cluster of approximately 20 to 30 motile maggots was found at the center of the cranial defect. Online content including video sequences viewable at: <https://www.thieme-connect.com/products/ejournals/html/10.1055/s-0043-1769895>.

The patient was immediately planned for surgical debridement. He was anesthetized with regional scalp block and sterile turpentine oil-soaked gauze was placed within

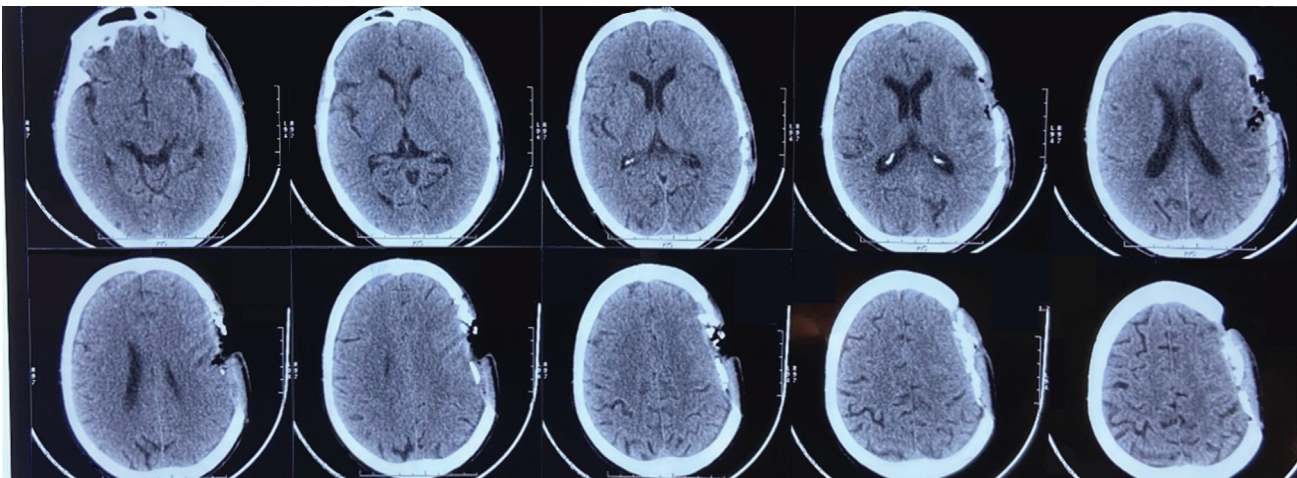


Fig. 2 Noncontrast computed tomography head revealed an extensive frontotemporal bony defect with brain exposure.

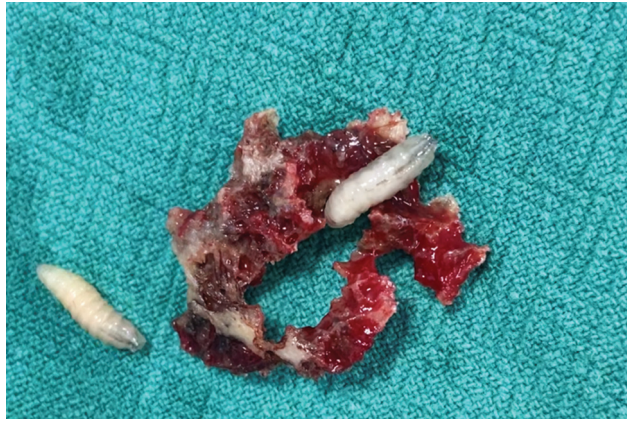

Fig. 3 The eroded bone was debrided in surgery.

the wound for the maggots to come out of the wound site. They were then handpicked using a forceps and around 25 to 30 maggots were removed. The osteomyelitic calvarial bone was debrided (►Fig. 3). The maggots were live and motile. Attendants were shown the organisms.

Thereafter, the patient was managed conservatively with broad-spectrum intravenous antibiotics and started showing signs of recovery. Daily dressings were done. His seizures gradually improved as the focus of cerebral irritation were excised. Repeat wound examination and neuroimaging showed no signs of new larvae development.

Table 1 List of worldwide reported cases of cerebral myiasis.

Sl. no.	Case	Year	Place	Age/Sex	Setting	Location	Outcome
1.	Froomin ¹⁵	1939	Russia	50 y/F	Unknown	Unknown	Unknown
2.	Semenov ¹⁶	1969	Russia	4 y/M	Scalp wound	Occipital	Death
3.	Zucoloto and Rossi ¹⁷	1971	USA	53 y/M	Facial myiasis	Frontal	Death
4.	Rossi and Zucoloto ¹¹	1973	USA	5 m/F	No prior lesion	Frontal	Death
5.	Gilly et al ¹⁸	1976	France	7 y/M	ICH	Frontal	Death
6.	Pouillaude et al ¹⁹	1980	France	6.5 y/M	ICH	Unknown	Death
7.	Arbit et al ¹³	1986	Canada	63 y/M	Scalp SCC	Frontal	Recovered
8.	Kalelioğlu et al ²⁰	1989	Turkey	8 y/M	ICH	Parieto-occipital	Recovered
9.	Cheshier et al ⁵	2007	USA	75 y/M	Angiosarcoma	Frontal	Death
10.	Marco de Lucas et al ¹²	2008	Spain	11 y/M	Cutaneous myiasis	Frontal	Unknown
11.	Terterov et al ¹⁴	2010	USA	42 y/M	Post-traumatic	Frontal	Recovered
12.	Giri et al ¹⁰	2016	India	38 y/M	Postcranioplasty	Frontotemporal	Recovered
13.	Navarro and Alves ²¹	2016	Brazil	36 y/M	Postcraniotomy	Frontal	Recovered
14.	Piña-Tornés et al ²	2016	Ecuador	30 y/M	Cutaneous myiasis	Parieto-occipital	Unknown
15.	Aggarwal and Maskara ⁶	2018	India	26 y/M	Scalp burn wound	Parietal	Recovered
16.	Curzi et al ¹	2020	Italy	72 y/M	Basal cell carcinoma scalp	Frontal	Recovered
17.	Algahtany et al ²²	2021	Saudi Arabia	24 y/M	Post-traumatic	Temporal and cerebellar	Recovered
18.	Current case	2022	India	64 y/M	Postcraniotomy	Frontotemporal	Recovering

Abbreviations: ICH, intra-cerebral hemorrhage; SCC, squamous cell carcinoma.

The maggots were sent for microbiological examination and were classified as *Sarcophaga carnaria* species (►Video 2). The cerebrospinal fluid (CSF) cultures sent were sterile. The patient almost reached normal sensorium and had no seizures for past 48 hours post which he was discharged and cranial reconstruction is planned on next visit after 6 weeks.

Video 2

The maggots were classified as *Sarcophaga carnaria* species. Online content including video sequences viewable at: <https://www.thieme-connect.com/products/ejournals/html/10.1055/s-0043-1769895>.

Discussion

The term myiasis was first coined by Hope in 1840.⁷ There are two types of myiasis based on its incidence: the primary and the secondary. In primary myiasis, the larvae penetrate the skin via a puncture wound, while in the secondary variety, fly eggs are laid into a skin ulcer. Benign or malignant dermatological or traumatic conditions have been associated with secondary myiasis,^{5,6,8,9} mostly attributable to inadequate wound care.^{6,10,11} Cerebral myiasis are exceedingly rare conditions, especially in high-income countries^{2,3,8} with only 17 previously published cases (►Table 1), and may lead

to life-threatening complications with the reported mortality as high as six out of seven cases dying of the disease.¹⁰

In India, myiasis is commonly caused by common housefly *Musca domestica* *nebulosa*. Sixteen out of eighteen cases showed male preponderance. More than half the cases (11 out of 18) are from developing nations. Only three cases (including the current case) have been reported from India. The frontal parenchymal involvement was common (66% of all cases). The age of presentation varied from 5 months to 75 years. Cases prior to the last two decades showed 96% mortality, while most cases recovered thereafter, probably to effective recent advances in antibiotics and antiseptics. Forty-four percent cases showed invasive cutaneous myiasis, while 64% was postcraniotomy.

A contrast-enhanced CT or magnetic resonance imaging is recommended to rule out venous sinuses integrity.⁹ The deeper the brain involvement, lesser was the survival. The larvae may penetrate the brain and spread via CSF to the subependymal space.¹² Treatment relies on larvae removal, debridement of necrotic/malignant tissue, and reconstruction of the defect. In the case of massive erosion and brain exposition, gentle irrigation with saline solution and mechanical removal is suggested. A sodium hypochlorite solution is also recommended, both intraoperatively and as a dressing. Intravenous broad-spectrum antibiotics are mandatory. Even in the setting of an open skull erosion with prolonged cortical exposure, in all available reports, surprisingly, there was absence of any secondary meningitis or encephalitis or sepsis. Maggot infestation may have reduced bacterial infection risk by protecting the tissue surface area and by eating dead tissues, leading to more prolonged survival.^{5,9,13,14}

Conclusion

Human cerebral myiasis is an exceedingly rare condition and is almost never encountered by physicians. There is only one report of postcraniotomy brain myiasis in the literature. Although rare, brain myiasis should be a differential diagnosis of surgical wound dehiscence in developing countries where conditions do exist in this country that permit myiasis. This differential diagnosis should be remembered, particularly when the classic signs of inflammation are not present and brain CT shows hypodense round and regular lesions on imaging.

Informed Consent

The authors certify that they have obtained all appropriate patient consent forms. In the form, the patient(s) has/have given his/her/their consent for his/her/their images and other clinical information to be reported in the journal. The patients understand that their names and initials will not be published and due efforts will be made to conceal their identity, but anonymity cannot be guaranteed.

Funding

None.

Conflict of Interest

None declared.

References

- Curzi C, Bartoletti V, Canova G, Giordan E. A severe case of brain myiasis: treatment rationale and review of literature. *Asian J Neurosurg* 2021;16(03):582–586
- Piña-Tornés AA, Salvador-Fernández CL, Lindao-Camacho R, González-Longoria-Boada LB, Vintimilla-Burgos NP, Selles Almarales M. Massive cutaneous myiasis mimicking brain invasion. Case report and literature review. *MÉDUIS*. 2016;29:145–153
- Sesterhenn AM, Pfützner W, Bräulke DM, Wiegand S, Werner JA, Taubert A. Cutaneous manifestation of myiasis in malignant wounds of the head and neck. *Eur J Dermatol* 2009;19(01):64–68
- Singh A. Prevalence of tracheopulmonary myiasis amidst humans. *Parasitol Res* 2021;120(03):1091–1096
- Cheshier SH, Bababeygy SR, Higgins D, Parsonnet J, Huhn SL. Cerebral myiasis associated with angiosarcoma of the scalp: case report. *Neurosurgery* 2007;61(01):E167, discussion E167
- Aggarwal A, Maskara P. Maggots in the brain: sequelae of ignored scalp wound. *World Neurosurg* 2018;109:115–116
- Laurence SM. Dipterous larvae infection. *BMJ* 1909;9:88
- Gabriel JG, Marinho SA, Verli FD, Krause RG, Yurgel LS, Cherubini K. Extensive myiasis infestation over a squamous cell carcinoma in the face. Case report. *Med Oral Patol Oral Cir Bucal* 2008;13(01):E9–E11
- Zhou X, Kambalame DM, Zhou S, et al. Human *Chrysomya bezziana* myiasis: a systematic review. *PLoS Negl Trop Dis* 2019;13(10):e0007391
- Giri SA, Kotecha N, Giri D, Diyora B, Nayak N, Sharma A. Cerebral myiasis associated with artificial cranioplasty flap: a case report. *World Neurosurg* 2016;87:661.e13–661.e16
- Rossi MA, Zucoloto S. Fatal cerebral myiasis caused by the tropical warble fly, *Dermatobia hominis*. *Am J Trop Med Hyg* 1973;22(02):267–269
- Marco de Lucas E, Díez C, Gutiérrez A, et al. Unusual MRI findings in a patient with history of frontal fracture and skin infestation by fly larvae, as a possible sign of intracerebral myiasis. *Clin Neurol Neurosurg* 2008;110(07):725–728
- Arbit E, Varon RE, Brem SS. Myiatic scalp and skull infection with diphtheria *Sarcophaga*: case report. *Neurosurgery* 1986;18(03):361–362
- Terterov S, Taghva A, MacDougall M, Giannotta S. Posttraumatic human cerebral myiasis. *World Neurosurg* 2010;73(05):557–559
- Froomin LL. Intradural cyst of parasitic origin (myiasis clinic). *Zh Ushn Nos Gori Bolezn* 1939;16:427–433
- Semenov PV. [A case of penetration of *Hypoderma lineatum* de Villers larva into the human brain]. *Med Parazitol (Mosk)* 1969;38(05):612–613
- Zucoloto S, Rossi MA. [Facial myiasis with spreading to the cranial vault]. *Rev Bras Med* 1971;28(01):13–16
- Gilly R, Lapras C, Mamelle JC, et al. [Hypodermic migrant myiasis with intracerebral hematoma. Apropos of a case in a 7-year-old child]. *Pediatric* 1976;31(01):67–75
- Pouillaude JM, Dupont J, Gilly R, Lapras C. Intracerebral myiasis in a child. *Pediatr Radiol* 1980;10(02):121–123
- Kalelioğlu M, Aktürk G, Aktürk F, et al. Intracerebral myiasis from *Hypoderma bovis* larva in a child. Case report. *J Neurosurg* 1989;71(06):929–931
- Navarro JN, Alves RV. Postoperative cerebral myiasis: a rare cause of wound dehiscence in developing countries. *Surg Neurol Int* 2016;7:69
- Algahtany MA, Alzailaie AK, Khoudir MA, Alqahtani FM, Osman TA, Shobowale EO. Conservative management of post-traumatic cerebral myiasis: report of a unique case and literature review. *J Pak Med Assoc* 2022;72(01):164–167