



# Evaluation of the Results of Septum Extension Batten Graft in Patients Referred for Septorhinoplasty

Hamidreza Hosnani<sup>1</sup> Shahin Bastaninez<sup>1</sup> Amirbahador Golchin<sup>1</sup> Hamed Givzadeh<sup>1</sup>

<sup>1</sup>Department of Otorhinolaryngology, Otorhinolaryngology Research Center, Tehran University of Medical Sciences, Tehran, Iran

Int Arch Otorhinolaryngol 2023;27(4):e602–e607.

Address for correspondence Hamed Givzadeh, Resident of Otorhinolaryngology - Head and Neck Surgery, Department of Otorhinolaryngology, Otorhinolaryngology Research Center, Tehran University of Medical Sciences, Tehran, Iran (the Islamic Republic of) (e-mail: gullass02@gmail.com).

## Abstract

**Introduction** Correction of caudal septal deviations has always been a challenging subject in septorhinoplasty. The septum batten extension graft (SBEG) is a new graft that has potential properties in rhinoplasty. However, few reports have evaluated the surgical outcomes of this technique.

**Objective** The purpose of this study was to evaluate the effectiveness of SBEG in correcting caudal septal deviation.

**Methods** This cross-sectional study was conducted on patients with caudal septal deviation undergoing septorhinoplasty using SBEG at 2 different hospitals in 2019. We then retrospectively reviewed medical records and photographs of 50 patients at the preoperative period, as well as at 1-month, and 12-month postoperatively. Gross changes in nasolabial angle, columellar show, nasal tip projection, and dorsal nasal deviation were evaluated by a photographic analysis method, and nasal obstruction was assessed by patient satisfaction with breathing.

**Results** There was a significant difference between the mean nasolabial angle and columellar show at 1 and 12-months postoperatively, compared with the previous values ( $p < 0.0001$ ). The nasolabial angles were in a favorable position with an increase of 12 to 15 degrees compared with the preoperative state. The columellar show also improved by an average of 1.2 mm and was in good condition. The postoperative dorsal nasal deviation was significantly reduced, and projection was significantly increased ( $3.521 \pm 0.087$  mm vs.  $0.719 \pm 0.028$ ;  $p < 0.0001$ ;  $p < 0.001$ ). Moreover, this method had a significant favorable effect on nasal obstruction ( $p = 0.049$ ).

**Conclusion** Our results showed that septorhinoplasty using SBEG is useful for correcting caudal septal deviation, with favorable surgical outcomes, and it has responded well to all five aforementioned criteria.

## Keywords

- ▶ batten extension graft
- ▶ septum
- ▶ caudal septal deviation
- ▶ rhinoplasty

## Introduction

Rhinoplasty is the most common surgery in otorhinolaryngology and plastic surgeries. Acknowledging all the details of

the anatomy cannot meet all the aesthetic expectations, but it can be beneficial to decrease its implications. The problems in rhinoplasty surgery include the complexity of the surgery method, and the possible anatomic variations of the nose

received

May 12, 2022

accepted

July 19, 2022

article published online

October 6, 2023

DOI <https://doi.org/>

10.1055/s-0043-1770083.

ISSN 1809-9777.

© 2023. Fundação Otorrinolaringologia. All rights reserved.

This is an open access article published by Thieme under the terms of the Creative Commons Attribution-NonDerivative-NonCommercial-License, permitting copying and reproduction so long as the original work is given appropriate credit. Contents may not be used for commercial purposes, or adapted, remixed, transformed or built upon. (<https://creativecommons.org/licenses/by-nc-nd/4.0/>)

Thieme Revinter Publicações Ltda., Rua do Matoso 170, Rio de Janeiro, RJ, CEP 20270-135, Brazil

cartilage and the hypodermis tissues before opening the nose, which can lead to complications during surgery. Most of the assessments are done on the surface of the skin and, thus, are not completely precise.<sup>1,2</sup>

The width and deviation of the nasal tip are one of the most common deformities of the nose in the rhinoplasty surgery candidates. Despite the advancements in aesthetic and plastic surgery, nasal tip correction surgery is still a challenge, and there are some unsolved problems, especially in terms of determining the involved factors in the nasal tip plastic surgery and the circumstances of evaluating its structure.<sup>3,4</sup> Nasal septum deviation is one of the reasons for nasal obstruction, nosebleed, and frequent rhinosinusitis. Although the ideal septum has a straight-line structure in the sagittal, most people have crooks and deviations. The etiology of septum deviation is mostly congenital, but it might result from traumatic or iatrogenic injuries.<sup>5</sup>

Correction of caudal septum deviations has always been one of the most difficult challenges of rhinoplasty. Additionally, providing strong support for the tip to be firm during the surgery is one of the priorities in rhinoplasty.<sup>6</sup> One of the most important concerns for plastic surgeons is failure in correcting the deviation and the nose staying straight during the recovery time.<sup>6,7</sup> For the purpose of correction, multiple methods were introduced; however, they also had limited efficiency. The new method, which is known as septum batten extension graft (SBEG), helps increase the accuracy of correcting deviations of S- and C-form septums. In this technique, a cartilage graft in a rectangular form is harvested from the septum floor. First, we smooth the septum with the previous methods as much as possible. Then, the batten graft is set so that its concavity is contrary to the septum's concavity. The septum is flattened and reinforced, and the graft is fixed to the caudal septum by three unabsorbable sutures.

Furthermore, as the batten graft is set so that its caudal part is 5 mm more caudal than the septum, it can simultaneously act as the extension graft. This way, we can set the tip on it and the desirable projection and rotation can be achieved. In addition to the above-mentioned features, as the batten graft is set so that the dorsal margin is parallel to the septum, it plays the role of a spreader graft and prevents the upper lateral cartilage of falling into the inner airway. Therefore, the SBEG plays three roles at the same time: 1) Keeping the septum straight and strong. 2) Acting as the extension graft. 3) Working as the spreader graft for surgeons. Eventually, the tongue-in-groove (TIG) is implemented and the tip is set on it.

Considering previous studies on the theme, SBEGs are the new grafts, and have many potential features in nose surgeries. Still, a few studies have worked on the results of using SBEG in primary rhinoplasties. As this graft can play many roles at the same time, the question arises of whether this graft has the necessary practicality and if it yields ideal results. It is critical to assess this important matter in short- and long-time studies. In this study, the goal is to assess the efficiency of the SBEG in the rhinoplasty surgery results.

## Assessment Method

This cross-sectional, descriptive study was done retrospectively on septorhinoplasty candidates with septum deviation that underwent septorhinoplasty with SBEG in a hospital and a private research center in 2019. This study was done after the confirmation of the Ethical Committee of the affiliated university (Ethical code: IR.TUMS.MEDICINE.REC.1399.043). Before surgery, all the patients signed a written consent form. Furthermore, throughout this study, all ethical contents in the Helsinki declaration on research, as well as the confidential principles for patients' information were observed. The inclusion criteria were cases with specific diagnoses of septum deviation with recommendation for primary septorhinoplasty, without history of previous nose surgery. The exclusion criterion was absence of deviation in the caudal and the revision surgery. The volume of sample was calculated based on 95% confidence interval (CI), 0.7% accuracy, 80% test capability, and 10% experimental mortality equal to 50 people.

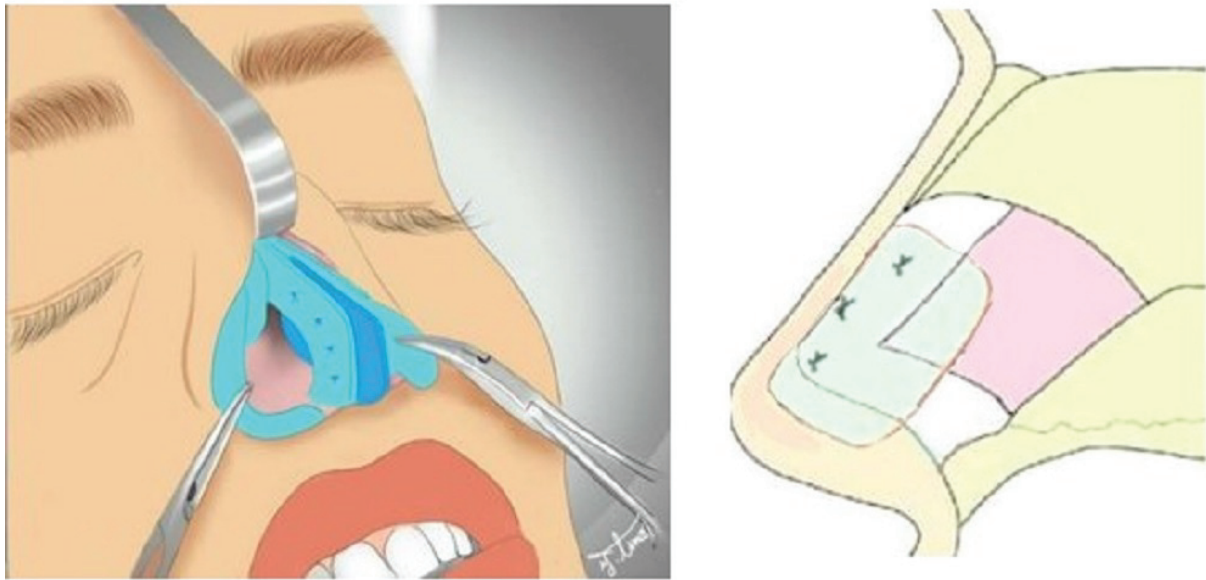
The basic demographic data of all the patients were collected and recorded at the beginning of the study. In this research, the results of the clinical examinations, condition, and imaging of the patients were accurately assessed before surgery, as well as 1-month and 1-year after it. The necessary data were collected and recorded using the designed check list by researchers. The angle between nose and lip (nasolabial angle), columellar show, nasal tip projection, and the dorsum deviation were assessed by using the image analysis method. Nose obstruction and patient's satisfaction regarding breathing were evaluated by interview, with use of the Likert scale (desirable, medium, undesirable). Eventually, the presurgical data, as well as the data of 1-month and 1-year after the rhinoplasty were compared. (→ Fig. 1)

## Statistical Analysis

To implement the statistical analysis, the Statistical Package Social Sciences (SPSS, IBM Corp. Armonk, NY, USA) software, version 25.0, was used. The information obtained was analyzed using descriptive statistics, including the frequency, average, standard deviation (SD) and frequency percentage. The normality of the data was assessed by the Kolmogorov-Smirnov test. To evaluate the association between the variables and the frequent measurement models, the correlation by the bootstrap method and two-variable correlation test (independence) were used. Also, the honestly significant difference (HSD) Tukey method was used to compare the results two-by-two. The significance level in the tests was considered as  $p = 0.05$ .

## Results

In the present study, the information of 50 patients before the surgery, and 1-month and 1-year after the surgery was assessed. The comparison between these three is shown in → Table 1.



**Fig. 1** The septum batten extension graft (SBEG) technique.

**Table 1** Comparison between the before and (1 month and 1 year) after the surgery. The values are the average  $\pm$  standard error, with a 95% confidence interval

Variable	Presurgery	1-year postsurgery	1-month postsurgery	p-value
Nasolabial angle	1.17 $\pm$ 88.98 (86.63–91.33)	1.2 $\pm$ 100.98 (98.56–103.4)	1.08 $\pm$ 104.06 (101.89–106.23)	>0.0001
Columellar show (mm)	0.06 $\pm$ 4.498 (4.826–5.076)	0.04 $\pm$ 3.81 (3.715–3.901)	0.05 $\pm$ 3.73 (3.608–3.826)	>0.0001
Projection	0.04 $\pm$ 0.562 (0.522–0.602)	0.041 $\pm$ 0.598 (0.555–0.637)	0.047 $\pm$ 0.599 (0.522–0.646)	>0.0001
Deviation (mm)	0.087 $\pm$ 3.521 (3.325–3.693)	0.028 $\pm$ 0.719 (0.658–0.776)		>0.0001

According to the results of **Table 1**, 1-year after the surgery, the average nasolabial angle is higher than before surgery ( $p < 0.0001$ ). However, the angle in the 1-month postsurgery was decreased ( $p < 0.0001$ ). Also, there was a meaningful difference between the nasolabial angle pre- and postsurgery at 1-month ( $p < 0.0001$ ). Additionally, as the difference between 95% CI for the average of nasolabial angle in both 1-month and 1-year postsurgery is within the standard interval, and the level of the first error is 0.05, we accept that the surgery was well implemented and the nasolabial angle of the patients is ideal. Also, the correlation scale between the nasolabial angle after 1-month and 1-year

is 92.45% (**Table 2**), which means that by evaluating each patient after the surgery, we can accurately anticipate the nasolabial angle for the first year after the surgery. The same association exists about the projection (**Table 2**).

In the assessment of the columellar show which was randomly evaluated, all the pair comparisons showed a difference between all the average pairs among each other ( $p < 0.0001$ ). Also, as the 95% CI for the columellar show's average values in both periods postsurgery (1-month and 1-year) are within the standard interval, and the level of first error is 0.05, we accept that the surgery was well implemented and the columellar show in the patients is ideal.

**Table 2** The assessment of correlation coefficient for the nasolabial angle and nasal tip projection in three time periods

Variable	1-month and 1-year postsurgery	Presurgery and 1-year after	Presurgery and 1-month after
Nasolabial angle	92.45%	67.35%	67.65%
Nasal tip projection	95.8%	88.71%	81.28%

**Table 3** The frequency and percentage of nose obstruction before and after the surgery

Nose obstruction	Ideal	Medium	Not ideal	p-value
Presurgery	23 (60.53)	2 (5.26)	13 (34.22)	0.049
Postsurgery	30 (78.96)	3 (7.89)	5 (13.16)	

In terms of projection variable, 30 of the patients needed projection increase. By evaluating them considering the 95% CI, there is a meaningful difference between pre- and postsurgery at 1-month and 1-year ( $p < 0.0001$ ). There is no meaningful difference between 1-month and 1-year after the surgery ( $p = 0.7$ ), which shows the projection stability during that time. Comparison of the dorsum deviation scale values pre- and postsurgery shows that there is no linear association between them. As the CIs have no overlaps with each other, at a meaningful level equal to 0.05, we accept that with a large scale, the deviation is decreased ( $p < 0.0001$ ). Although, it is worth saying that, as the deviation scale is always nonnegative, we can evaluate the zero deviation only if the value is zero postsurgery.

In the assessments regarding nose obstruction, the information on pre- and postsurgery for 38 of 50 patients was recorded (→ **Table 3**). According to the results of the independence correlation test, the surgery had a desirable and meaningful effect on nose obstruction ( $p = 0.049$ ). Out of the 13 patients who had nasal obstruction before the surgery, 2 reported no improvement, 2 felt better, and the nasal obstruction was resolved in 9 patients. Out of the 2 patients who did not suffer complete nose obstruction before the surgery, 1 had complete nose obstruction, and the other one completely recovered. As for the 23 patients who did not suffer nose obstruction, 20 maintained the same condition, 1 got worse, and 2 of them suffered slight nose obstruction.

Comparison between the nasolabial angle before and after the surgery based on the gender of the patients is shown in → **Table 4**. The results showed that there is a meaningful difference in all the pair of comparisons between the patients' nasolabial angle ( $p < 0.0001$ ).

**Discussion**

The results of the present study showed that a nasolabial angle between 12 and 15 degrees is considered desirable. Also, the correlation scale between the nasolabial angle in 1-month and 1-year postsurgery was 92.45%, which represents

the ability for proper anticipation of the nasolabial angle at 1-year postsurgery from the degree scale at 1-month postsurgery.

In a study by Karadavut et al.,<sup>8</sup> similar results were achieved, which means that using the extension graft caused a meaningful improvement in the nasolabial angle of up to 12.5 degrees. Also, in the study of Atighechi et al.,<sup>9</sup> the extension graft caused a meaningful rise in the nasolabial angle of up to 22.3 degrees. In the case of Akkus et al.,<sup>10</sup> the average nasolabial angle improvement was 16.8 degrees and statistically meaningful. However, in the study of Yi et al.,<sup>11</sup> there was no improvement in the nasolabial angle after septoplasty using caudal septal batten graft. Although only the batten graft was used in their study, not an extension. Furthermore, Chen et al.<sup>12</sup> also did not observe an increase in nasolabial angle by using extension graft; this finding might be caused by the high nasolabial angle in the Asian population. In sum, these findings confirm the desirable effect of SBEG in the nasolabial angle improvement.

Analyzing the images, we figured out a change in patients' columellar show and the assessment results showed that postsurgery results were meaningfully different when compared with presurgery; furthermore, it decreased to an average of 1.2 mm, which was closer to the medium standard. Also, the columellar show average in both periods after the surgery (1-month and 1-year) is within the standard interval. It means that in the implemented surgery using the mentioned method, the columellar show of the patients was desirable. In the study by Atighechi et al., the use of extension graft resulted in a decrease in the columellar show of patients to 1.76 mm,<sup>9</sup> which is in accordance with our findings. In the current study, the dorsum deviation scale pre- and postsurgery was evaluated and for improvements of 2.8 degrees, we observed a meaningful decrease in the nasal deviation in comparison with the condition presurgery. In the Chen et al. study, the dorsum deviation improvement was observed as the average of 3.7 degrees, and considered statistically meaningful.<sup>12</sup> In a study by Yi et al.,<sup>11</sup> the practicality of batten graft in septoplasty patients was accompanied by a

**Table 4** The comparison between the nasolabial angle before and after the surgery, based on patients' gender

Gender	Average presurgery	Average postsurgery	p-value	95% confidence interval	
				Lower bound	Upper bound
Female	89.36	1-month (103.7)	<0.0001	-14.33	-17.33
		1-year (100.96)	<0.0001	-11.6	-14.82
Male	87.63	1-month (105.35)	<0.0001	-17.72	-23.43
		1-year (101.04)	<0.0001	-13.42	-19.51

meaningful improvement in dorsum deviation. The results of the studies by Jang et al.<sup>13</sup> showed similar results when using nasal septal bone to correct the septum deviation.

The caudal septum deviation disrupts natural breathing due to a narrowing of the exterior valve and the nasal valve angle. Therefore, a decrease in the patients' nasal deviation helps improve their breathing condition. The current study's results showed that septorhinoplasty by using the SBEGs had a desirable and meaningful effect on the nasal obstruction and breathing condition. In this study, out of 13 patients who suffered nasal obstruction before the surgery, it was completely resolved in 9 patients (69.2%). In the study by Chung et al.,<sup>7</sup> the evaluation of 39 patients after surgery showed that the septoplasty caused improvement in the nasal obstruction by using batten graft for correction of caudal septum deviation, which was in accordance with the current study. In that study, the intensity of nasal obstruction symptoms (including oral breathing, xerostomia, hypoxemia, rhinorrhea, epistaxis, snoring, and headache) pre- and postsurgery was evaluated using the visual analog scale (VAS) for pain.<sup>7</sup> Also, in the study by Kim et al.,<sup>14</sup> a 90% improvement in the nasal obstruction (60.7% complete improvement and 30.3% relative improvement) was reported after the endonasal septoplasty by using the batten graft for the correction of septum deviation. In the study by Lee et al., using the septal bone grafts to correct the caudal septum deviation caused improvement in the nasal obstruction in 86% of the patients.<sup>15</sup> The results of the study by Wee et al. claimed that after the endonasal septoplasty surgery by using the septal batten graft, all the patients experienced breathing improvement and nasal obstruction correction.<sup>16</sup> Also, in a cohort study, Patel et al. reported a meaningful improvement in patients' breathing condition after using the septal extension graft.<sup>17</sup>

These findings show that SBEG in the caudal septum is an effective method in the correction of septum deviation and causes improvement in nasal obstruction. However, there are some detailed differences in the results of various studies, which are due to the patients' demographic data, details on surgery techniques, result in assessment methods, and difference in sample volume. In the current study, a meaningful statistical difference was observed between the projection scale before and after the surgery. It is worth saying that a remarkable coefficient of correlation was seen between the projection scale pre- and postsurgery. That is to say, by assessing the condition of each patient before the surgery, it was possible to provide desirable anticipation on the results 1-year after surgery.

In the study by Yi et al.,<sup>11</sup> the images of 52 patients, who suffered septum deviation and underwent endonasal septoplasty surgery with batten graft for caudal correction, were evaluated before and after the surgery, and no meaningful difference was observed between the projection and breathing correction after the surgery. On the other hand, Chen et al.<sup>12</sup> and Akkus et al.,<sup>10</sup> reported a rise in the projection postsurgery. To explain the differences in the results, we must highlight that the study by Chen et al. was done on the Asian nose form, and they attempted to correct the projec-

tion to the standard scale, which resulted in projection increase. Also, the Akkus et al. study was a retrospective cohort study done to compare the extension graft and the columellar strut, with 18 patients chosen from each group and the projection and nasolabial angle presurgery and at 6 and 20-months postsurgically were measured. In that study, when setting the graft, they attempted to increase the projection. In both groups, the nasolabial angle and projection increased after surgery and had a meaningful difference when compared to before surgery, but there were no differences in the results between both groups.

The goal of the current study was to correct the caudal septum deviation, create ideal support for the tip, and, in the necessary cases, increase the projection; additionally, the total number of our assessed patients was three times bigger than the studies discussed above.

In the end, we should mention that the current study has some limitations; including nonrandomized selection of samples and incomplete patient data in some of the cases. Furthermore, in this study, we did not implement an objective assessment of the airway, such as acoustic rhinometry to analyze the anatomic features of the caudal septum, and the breathing satisfaction questionnaire was not filled the patients, but the scale of their satisfaction was orally asked. Therefore, by doing a clinical trial study with a larger sample, and using standard questionnaires about the rhinoplasty results, we can achieve better results.

## Conclusion

The results of this study showed that septorhinoplasty with use of SBEG results in improvement of the nasolabial angle, columellar show, nasal deviation scale, projection, and nasal obstruction. This technique can provide more options in addition to the previous ones for surgeons.

### Appreciations

This article is derived from a student thesis and the research plan with the number 9611369003 in the medical faculty of the affiliated university.

### Funding

Nil.

### Conflict of Interests

The authors have no conflict of interests to declare.

## References

- Kim D, Mau T. Surgical anatomy of the nose. *Otolaryngology-Head and Neck Surgery* 2006;2:2511–2532
- Banan R, Nemati S, Alizadeh A, et al. Sonographic evaluation of nasal tip skin stickiness among patients undergoing rhinoplasty with or without defatting. *Journal of Inflammatory Diseases* 2012;16(02):22–27
- Parkes MH, Kanodia R, Kern EB. The universal tip: a systematic approach to aesthetic problems of the lower lateral cartilages. *Plast Reconstr Surg* 1988;81(06):878–890
- Byrd HS, Hobar PC. Rhinoplasty: a practical guide for surgical planning. *Plast Reconstr Surg* 1993;91(04):642–654, discussion 655–656

- 5 Haack J, Papel ID. Caudal septal deviation. *Otolaryngol Clin North Am* 2009;42(03):427–436
- 6 Constantine FC, Ahmad J, Geissler P, Rohrich RJ. Simplifying the management of caudal septal deviation in rhinoplasty. *Plast Reconstr Surg* 2014;134(03):379e–388e
- 7 Chung YS, Seol JH, Choi JM, et al. How to resolve the caudal septal deviation? Clinical outcomes after septoplasty with bony batten grafting. *Laryngoscope* 2014;124(08):1771–1776
- 8 Karadavut Y, Akyıldız I, Karadaş H, Dinç AE, Tulacı G, Tastan E. Effectiveness of caudal septal extension graft application in endonasal septoplasty. *Rev Bras Otorrinolaringol (Engl Ed)* 2017;83(01):59–65. Doi: 10.1016/j.bjorl.2016.01.014
- 9 Atighechi S, Sajadinejad BS, Baradaranfar MH, Dadgarnia MH, Shahbazian H. Caudal extension graft versus columellar strut with plumping graft for acute nasolabial angle correction in rhinoplasty surgery. *Eur Arch Otorhinolaryngol* 2015;272(07):1673–1677
- 10 Akkus AM, Eryilmaz E, Guneren E. Comparison of the effects of columellar strut and septal extension grafts for tip support in rhinoplasty. *Aesthetic Plast Surg* 2013;37(04):666–673. Doi: 10.1007/s00266-013-0141-1
- 11 Yi JS, Jang YJ. Effect of septoplasty with a caudal septal batten graft on changes in nasal shape. *Ann Otol Rhinol Laryngol* 2015;124(04):288–293. Doi: 10.1177/0003489414555899
- 12 Chen YY, Kim SA, Jang YJ. Centering a Deviated Nose by Caudal Septal Extension Graft and Unilaterally Extended Spreader Grafts. *Ann Otol Rhinol Laryngol* 2020;129(05):448–455. Doi: 10.1177/0003489419894617
- 13 Jang YJ, Kim JM, Yeo NK, Yoo JH. Use of nasal septal bone to straighten deviated septal cartilage in correction of deviated nose. *Ann Otol Rhinol Laryngol* 2009;118(07):488–494
- 14 Kim JH, Kim D-Y, Jang YJ. Outcomes after endonasal septoplasty using caudal septal batten grafting. *Am J Rhinol Allergy* 2011;25(04):e166–e170
- 15 Lee JW, Baker SR. Correction of caudal septal deviation and deformity using nasal septal bone grafts. *JAMA Facial Plast Surg* 2013;15(02):96–100
- 16 Wee JH, Lee J-E, Cho S-W, Jin HR. Septal batten graft to correct cartilaginous deformities in endonasal septoplasty. *Arch Otolaryngol Head Neck Surg* 2012;138(05):457–461
- 17 Patel PN, Abdelwahab M, Shukla ND, et al. Functional Outcomes of Septal Extension Grafting in Aesthetic Rhinoplasty: A Cohort Analysis. *Facial Plast Surg Aesthet Med* 2021;23(03):172–179