


Bone and Chronic Kidney Disease

Marie-Hélène Lafage-Proust, MD, PhD^{1,2} 

¹INSERM U1059 SAINBIOSE Université Jean Monnet, Saint-Etienne, France

²Service de Rhumatologie, CHU Saint-Etienne, Saint-Etienne, France

Address for correspondence Marie-Hélène Lafage-Proust, MD, PhD, Service de Rhumatologie, CHU Saint-Etienne, 42055 Saint-Etienne Cedex, France (e-mail: mh.lafage.proust@univ-st-etienne.fr).

Semin Musculoskelet Radiol 2023;27:463–470.

Abstract

Chronic kidney disease (CKD) induces mineral and bone disorders (CKD-MBD) that affect calcium and phosphate metabolism. This review links pathophysiology, histologic aspects, and radiologic signs. CKD leads to bone lesions, namely renal osteodystrophy, which may combine low or high bone remodeling, impaired mineralization, and bone loss. CKD-MBD also comprises vascular calcifications, which, together with bone disease, lead to a high risk of cardiovascular events and osteoporotic fractures that increase both morbidity and mortality. Osteoporosis assessment is based on screening for classic risk factors and CKD-related factors (disease duration/severity, transplantation history, dialysis vintage). Treatment of mineral disorders may combine serum phosphate lowering drugs, natural vitamin D or its 1- α derivatives, or calcium-sensing receptor agonists. Treatment of osteoporosis is conventional in mild to moderate stages but more complex in severe CKD because evidence about the efficacy and safety of anti-osteoporosis drugs is scant.

Keywords

- ▶ osteoporosis
- ▶ chronic kidney disease
- ▶ renal osteodystrophy
- ▶ fracture

The annual incidence of chronic kidney disease (CKD) in France is 1%, but 7 to 10% of the population have some kidney disorder.^{1,2} The current total number of individuals affected by CKD stages 1 to 5 worldwide was estimated as >850 million in 2019.³ CKD is classified in five stages according to glomerular filtration rate (GFR)⁴ (▶ **Table 1**), estimated by the Chronic Kidney Disease Epidemiology Collaboration equation, based on serum creatinine (except for older adult subjects, for whom the Cockcroft formula is still used).

The first two stages must repeatedly include other renal markers: albuminuria, urinary sediment abnormality, and kidney lesions of at least 3 months on pathology. Stage 5 is end-stage renal failure (ESRF), requiring dialysis or transplantation. For instance, in France in 2020, global incidence of treated ESRF was 157 per million, with almost 51,000 patients on dialysis and 42,000 with kidney transplantation.⁵ Incidence in recent years has increased most in people 65 to 74 years of age, by 5.8% per year up to 2019.

CKD leads to progressive disorders of calcium and phosphate metabolism, impacting bone histology in what is known as renal osteodystrophy (ROD), with an associated risk of fracture. It also induces vascular calcifications closely

associated with clinical cardiovascular events. Bone, vessel, and metabolic impacts are related pathophysiologically and together are known as CKD-MBD (mineral and bone disorder),⁶ largely implicated in the increased morbidity and mortality observed in uremic populations.

Osteoporosis is a generalized skeletal disease involving decreased bone mineral density (BMD) and/or altered bone microarchitecture, resulting in brittle bone and increased risk of fracture, whose incidence increases with age and in women after menopause. Thus CKD-linked osteoporosis combines primary bone loss related to age and sex and secondary bone damage specific to kidney failure,⁷ including ROD, which impacts diagnostic and treatment strategy. In advanced CKD, and independently of osteoporosis, the bone may also show focal lesions, such as brown tumors, related to hyperparathyroidism (HPT).

Disorders of Calcium and Phosphate Metabolism

The pathophysiology of CKD-MBD involves three hormones: fibroblast growth factor 23 (FGF-23), parathyroid hormone

Table 1 Stages of chronic kidney disease

Classification		
Stage	Description	GFR, mL/min/ 1.73 m ²
1	Renal involvement ^a with normal GFR	≥ 90
2	Renal involvement ^a with slightly impaired GFR	60–89
3	Moderate CKD	30–59
4	Severe CKD	15–29
5	Terminal CKD	< 15 or dialysis

Abbreviations: CKD, chronic kidney disease; GFR, glomerular filtration rate.

^aOther markers of renal involvement, such as albuminuria, urinary sedimentation disorder, tubular function (repeatedly over > 3 months), or kidney lesions on pathology.

(PTH), and vitamin D. The decrease in nephron count induced by CKD causes phosphate retention, stimulating FGF-23 secretion by bone that increases urinary excretion of phosphate to readjust phosphate excretion by the remaining nephrons. Increased FGF-23 reduces synthesis of active vitamin D (calcitriol) by the kidney. This results in hypocalcemia, aggravated by deficient renal tubular reabsorption, and hyperphosphatemia when CKD worsens, which leads to secondary HPT (II HPT). Moreover, this progresses in a context of overall decrease in tissue expression of the receptors of these hormones, such as loss of bone PTH receptors, leading to relative bone resistance to PTH. In the parathyroid glands, similar losses of receptors (vitamin D, FGF-23, or calcium-sensitive receptors) aggravate II HPT, which, together with recurrence of the cell proliferation, lead to the development of adenomas or hyperplasia and tertiary HPT (III HPT).

Renal Osteodystrophy

Bone Histology in Renal Osteodystrophy

On the turnover, mineralization, and volume (TMV) classification (► Fig. 1), histologic bone lesions can affect turnover (T), which may be normal, low, or high. In high T, qualitative abnormalities may also be observed, such as woven bone, medullary fibrosis, or increased cortical porosity (► Fig. 2), seen in severe HPT. Low turnover without a mineralization disorder (formerly known as adynamic bone) is the most prevalent bone lesion in Western countries, promoted by diabetes, advanced age, and excessive iatrogenic suppression of PTH. Primary mineralization (M), consisting of mineral deposition within nonmineralized collagen, may be normal or low, leading to osteomalacia (OM). And lastly, there may be alterations in bone mass or volume (V) in the trabecular and/or cortical compartments. Abnormalities in turnover and mineralization may be associated or isolated. They contribute to impaired mechani-

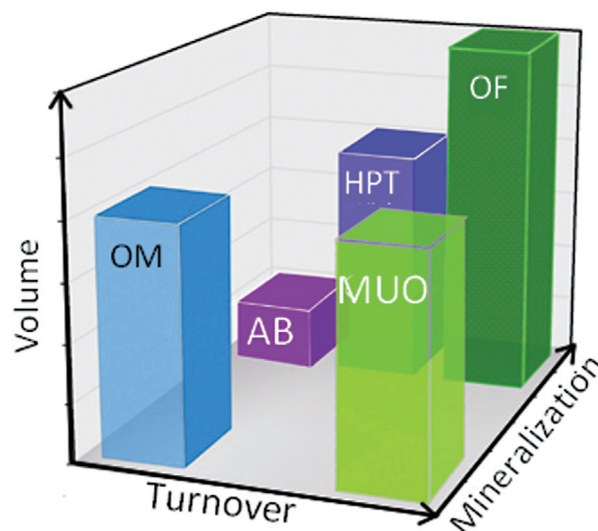


Fig. 1 Turnover, mineralization, and volume (TMV) histomorphometric classification of renal osteodystrophy (courtesy of Moe et al, 2006⁶). Axes correspond to the three parameters: bone (T)urnover (low to high), (M)ineralization (low to normal), and bone (V)olume (or mass: low to high). Blue: Osteomalacia (OM), low mineralization and turnover; volume low or normal depending on disease severity and duration. Purple: Adynamic bone (AB), low turnover without mineralization disorder. Purple and dark green: High or very high turnover, as in moderate hyperparathyroidism (HPT) or severe HPT (OF, osteitis fibrosa) without mineralization disorder. Light green: Mixed uremic osteopathy (MUO): high turnover and mineralization disorder.

cal resistance of bone, potentially already affected by low mass.

Definitive diagnosis is based on iliac crest bone biopsy for quantitative histomorphometry after double labeling by tetracycline. Secondary mineralization consists of adding extra mineral input in already mineralized tissue. In ROD, bone secondary mineralization is impaired by severe turnover disorders; however, this has been little described, although it contributes to brittleness. Histomorphometric iliac crest biopsy is the best way to establish the diagnosis if biological signs are ambiguous, but it is less used for many reasons, including unavailability of trephines and tetracycline, and loss of expertise in rheumatologists and nephrologists.⁸ However, a Canadian study showed that the procedure, performed under fluoroscopy in interventional radiology, could restore biopsy to its central place in the management of complex cases.⁹

Biological Signs and Diagnosis of Renal Osteodystrophy

Follow-up over several weeks or months of serum bone alkaline phosphatase (BAP), a bone formation marker independent of GFR, combined with a PTH assay, especially in advanced kidney failure, can provide indications of remodeling intensity, differentiating low from “non-low” and high from “non-high” turnover in almost 80% of cases.¹⁰ However, the occurrence of a major fracture (e.g., hip or pelvis) can

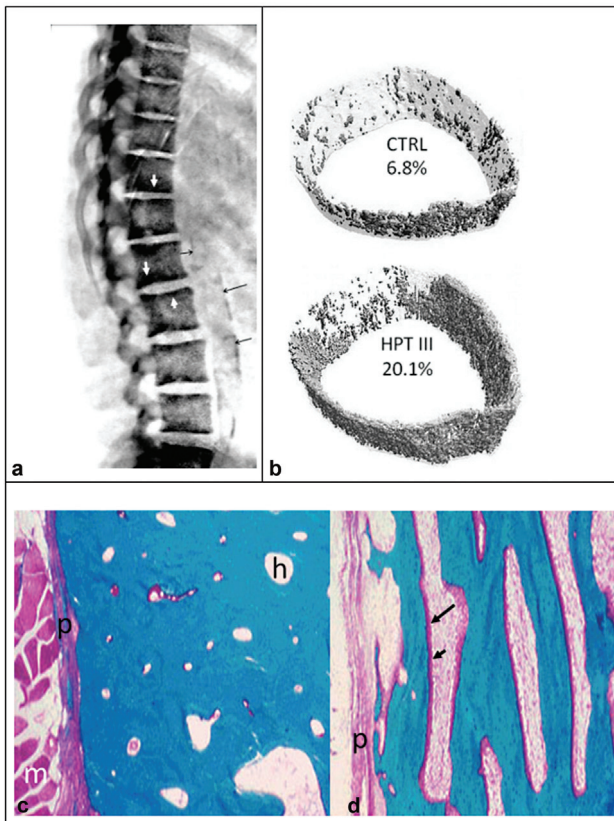


Fig. 2 Renal osteodystrophy related to tertiary hyperparathyroidism (III HPT). A 64-year-old hemodialyzed woman with hypercalcemia, serum parathyroid hormone (PTH) 950 to 1,100 pg/mL; normal < 65 pg/mL. (a) Lateral spinal dual-energy X-ray absorptiometry imaging (black arrows, aortic calcifications; white arrows, vertebral plate osteosclerosis that characterizes the “rugger-jersey spine.”) (b) Three-dimensional high-resolution peripheral quantitative computed tomography images (Scanco Medical) of the patient’s tibial cortex (III HPT: lower image) and of an age- and sex-matched patient with osteoporosis but not chronic kidney disease (CKD) (CTRL: upper image). Each gray mark is a pore. Center: Measured percentage of cortical porosity. (c, d) Histologic images of iliac crest cortex, $\times 10$ magnification, Masson-Goldner trichrome staining. Left: Normal. H, Havers canal; m, muscle; p, periosteum Right: III HPT: tunneling; arrows: hyperosteoidosis (arrows).

disturb BAP levels for several weeks or even months. Moreover, mineralization disorders can increase circulating BAP even without high turnover. Other parameters, such as TRAP5b, a resorption marker independent of GFR, or P1NP, another bone formation marker, are currently being studied.¹¹

Radiologic Signs in CKD-MBD

Radiologic signs of very severe secondary/tertiary HPT including images on plain radiographs of the “rugger-jersey” vertebral aspect (as described in **Fig. 3**) or phalangeal tuft resorption (**Fig. 3**) are rarely observed. The term “rugger-jersey” vertebrae describes the increase in vertebral endplate density that produces an alternating sclerotic-lucent-sclerotic appearance mimicking the horizontal stripes of an

American rugby jersey that can easily be distinguished from osteopetrosis or Paget’s disease.

Similarly, the occurrence of brown tumors has become relatively infrequent. Brown tumors are well-defined osteolytic or multilobular cystic lesions. The cortex may be thinned and/or blown but only exceptionally penetrated. Giant cell tumor, solid aneurysmal bone cyst, and giant cell reparative granuloma are included in the differential diagnoses for brown tumors. Multiple brown tumors (as described in **Fig. 3**) can still be observed in patients with mutations of genes responsible for HPT (i.e., paracellin or parafibromin) or in patients with refractory HPT, especially those immigrating from countries where ROD is less well monitored.

Tumoral calcinosis is also a rare and excruciatingly painful complication of HPT in renal patients that appears on radiographs as dense or multilobulated “cloud-like” calcifications located in soft tissues (**Fig. 3**). Signs of CKD-related OM do not differ from those observed in OM due to vitamin D deficiency. Overt OM can induce many fissures/ pseudofractures that can mimic bone metastases on a bone scan (**Fig. 4**). When localized to the foot, fissure-related swelling may clinically simulate inflammatory joint arthritis such as gout or pseudogout that occurs frequently in CKD patients. Computed tomography (CT) or magnetic resonance imaging (MRI) facilitates the correct diagnostic (**Fig. 4**).

Finally, lesions of vascular origin are commonly observed on plain radiographs of CKD patients. Vascular calcifications combine irregular intimal atheroma-related calcifications and linear media calcifications. Unique or multiple osteonecrosis of epiphyses, including femoral head, humerus, medial condyle, or talus, are more often found in kidney transplant patients (**Fig. 5**). They may be associated with calcified bone infarction, especially in diabetic patients with severe ischemic vascular disease (**Fig. 5**).

Fracture and Chronic Kidney Disease

Prevalence of CKD in Osteoporosis and of Osteoporosis in CKD

As mentioned earlier, the incidence of CKD and osteoporosis both increase with age. Stage 5 CKD patients showed a four- to sixfold greater risk of nonvertebral fracture than age- and sex-matched controls.^{6,12} CKD patients with fractures showed greater mortality than CKD patients without fractures or fracture patients without CKD. In the National Health and Nutrition Examination Survey III cohort, in the 50- to 74-year-old group, the prevalence of CKD was threefold higher in patients with a history of hip fracture than in those without.¹³ In the same cohort, women with osteoporosis aged 20 to ≥ 80 years showed 85% prevalence (95% confidence interval [CI], 79–91%) of slight to moderate decrease in GFR (< 60 mL/min) and 24% (95% CI, 19–29%) of severe renal disease (GFR < 35 mL/min).¹⁴ Taken together, these findings suggest that CKD is a risk factor for bone fragility, although the fact that it is an independent factor remains debated.

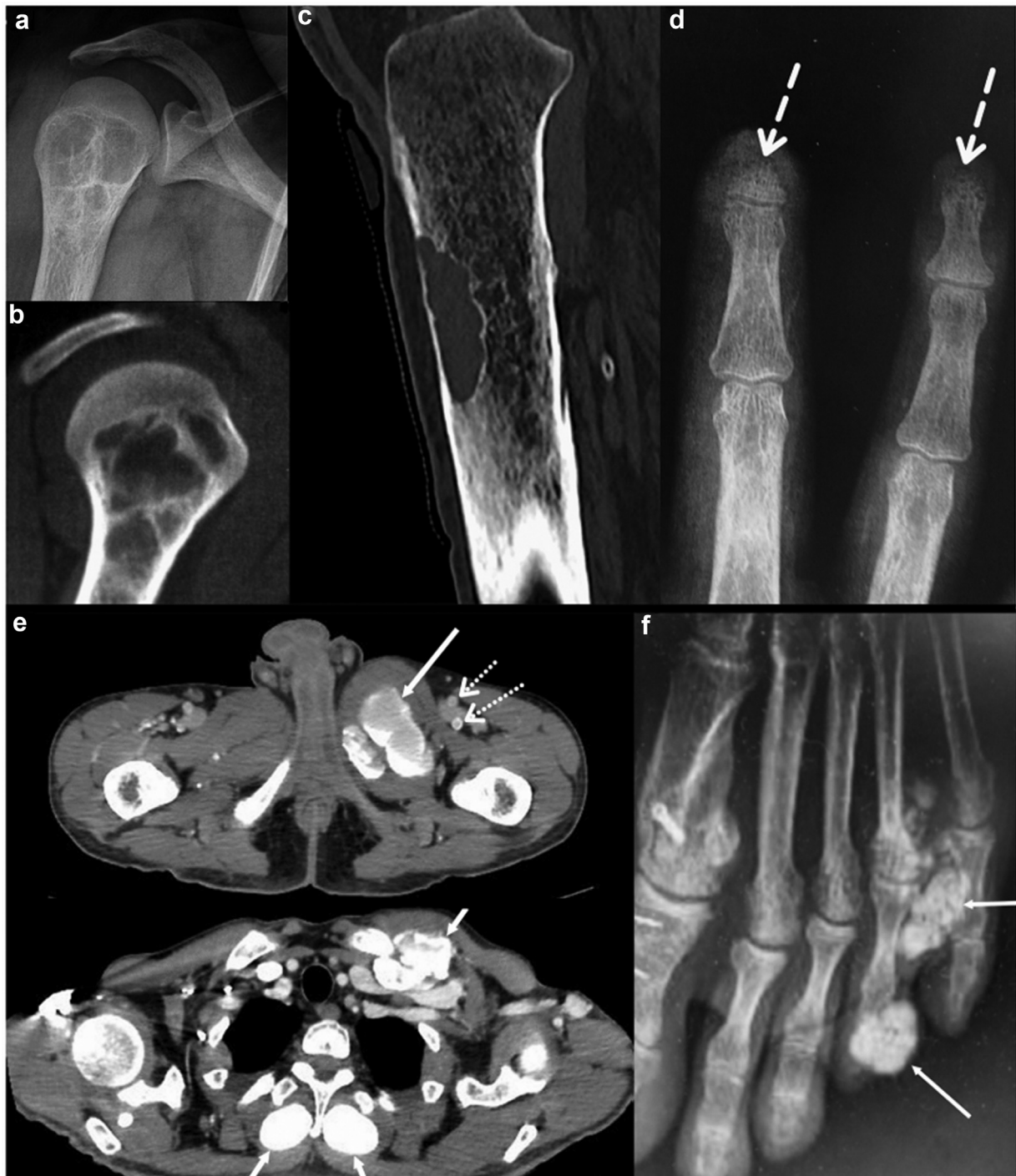

Fig. 3 Radiologic signs of severe hyperparathyroidism (HPT) in chronic kidney disease (CKD). (a–c) Brown tumors related to severe secondary or tertiary HPT. (a) Plain radiograph and (b) computed tomography (CT) image of upper epiphysis of the humerus in a 22-year-old female patient with CKD with a paracellin-1 mutation. (c) CT image of tibial brown tumor (patient from ► Fig. 2). (d) Phalangeal tuft resorption (right dotted arrow) combined with acro-osteolysis (left dotted arrow) in diabetic CKD patient combining severe HPT and peripheral arterial disease. (e) Abdominal and pelvis CT images of a 29-year-old CKD patient with extremely severe HPT (parathyroid hormone > 2,000 pg/mL; serum phosphate > 2.5 mmol/L), presenting with numerous calcium deposits localized to subcutaneous and intramuscular regions (arrows), associated with extensive arterial calcifications (dotted arrows). (f) Periarticular calcinosis of the foot (arrows).

Diagnosis of Fracture in CKD

Fracture diagnosis strategy does not differ from that used in patients without CKD and includes clinical examination followed by plain radiograph or CT, sometimes combined with MRI and/or bone scan. Difficulties may arise because

these patients, especially when on dialysis, have chronic pain and often show multiple comorbidities,¹⁵ so osteoporotic fracture in the spine, pelvis, or foot may be overlooked. Vertebral fracture assessment during dual-energy X-ray absorptiometry (DEXA), which provides a lateral image of

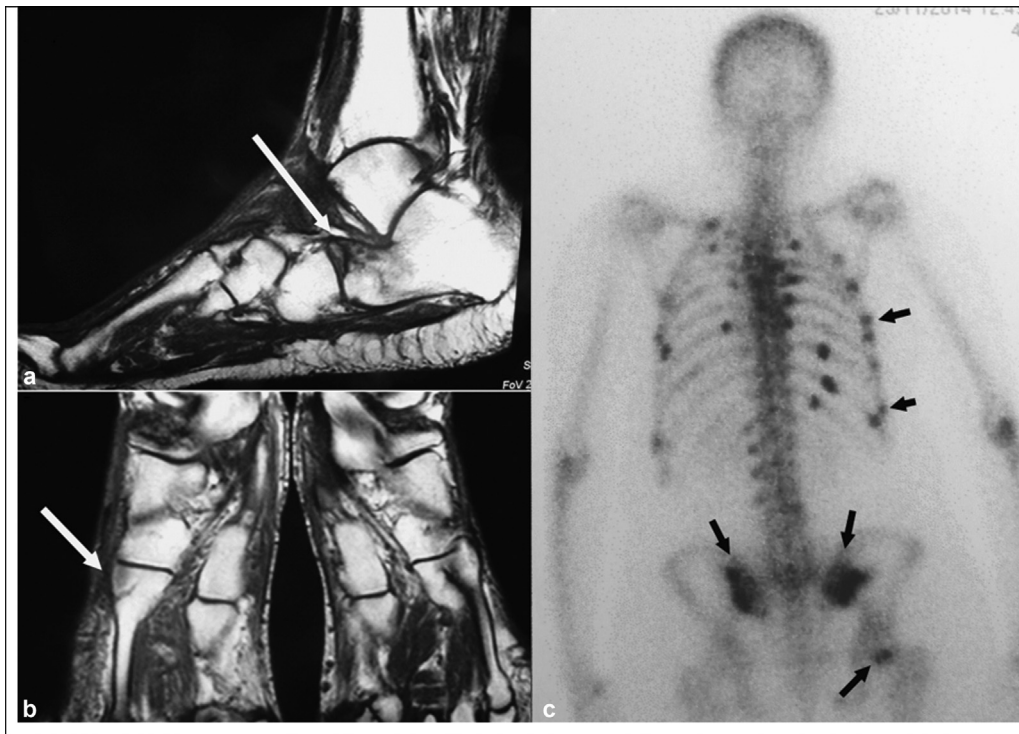

Fig. 4 Radiologic signs of osteomalacia (OM). (a, b) A 65-year-old patient with chronic kidney disease (CKD) who presented with limping due to an aching left foot that was swollen, mimicking inflammatory arthritis. Serum calcium was low (2.01 mmol/L), parathyroid hormone (PTH) was elevated (175 pg/mL), and bone alkaline phosphatase (BAP) was very high (95 µg/L; normal < 20 µg/L). Radiographs did not show any sign of fracture. Magnetic resonance imaging performed 1 month after radiographs revealed a fracture of the proximal part of the first metatarsal bone and of the distal region of the talus. Bone biopsy showed OM. (c) Bone scan of a 68-year-old female CKD patient who developed overt OM with generalized bone pain related to multiple fractures (ribs, sacrum, and femoral neck) with decreased serum calcium (1.99 mmol/L), increased PTH (485 pg/mL), and very high BAP (342 µg/L; normal < 20 µg/L).

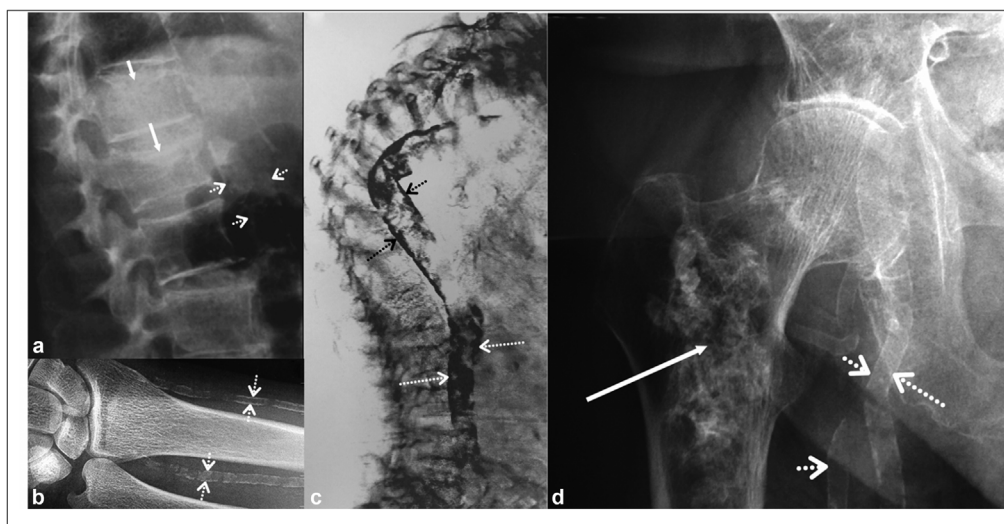


Fig. 5 Radiologic signs of vascular origin in patients with chronic kidney disease-mineral and bone disorders. (a) Lateral radiograph with fracture of L2 and L1 (arrows) and aorta calcifications (dotted arrows). (b) Media calcifications of the forearm (dotted arrows). Note the linear continuous aspect of the calcifications. (c) Lateral dual-energy X-ray absorptiometry image of the spine in a 76-year-old hemodialyzed woman with severe osteoporosis. Note the aorta calcifications that may impact the accuracy of bone mineral density measurement (dotted arrows). (d) Media calcifications of femoral arteries (dotted arrows) and bone infraction (arrow) in a diabetic hemodialyzed 69-year-old patient with severe ischemic peripheral arterial disease.

This document was downloaded for personal use only. Unauthorized distribution is strictly prohibited.

the complete dorsolumbar spine without parallax artifacts, can detect unnoticed vertebral fractures¹⁶ (–Fig. 6).

Fracture Risk Assessment and Diagnosis of Osteoporosis in CKD

Assessment is based on inventorying the classic fracture risk factors of female sex, family history of fracture, early menopause, corticosteroid treatment, and falls, and CKD-related risk factors such as duration of dialysis, history of kidney transplantation, and severe HPT.¹¹ Active screening for prevalent fractures is a key point because osteoporotic fracture indicates brittle bone regardless of BMD values.

Several studies showed that BMD on DEXA predicted fracture risk in CKD with the same precision as in the general population for stages 2 to 4^{17,18} and for stage 5.¹⁹ However, DEXA has good specificity for the diagnosis of bone fragility, but its sensitivity is poor because a third of the patients with fractures have a T score > 2.5. Importantly, in addition, BMD on DEXA sheds no light on underlying ROD because the BMD value results from a combination of bone mass abnormality and the degree of primary and secondary mineralization, as shown in –Fig. 7. Trabecular bone score, assessing spinal bone texture on DEXA, is currently under evaluation in CKD.²⁰

Finally, the combination of fracture risk factors and BMD in the femoral neck, using digital tools such as FRAX,²¹

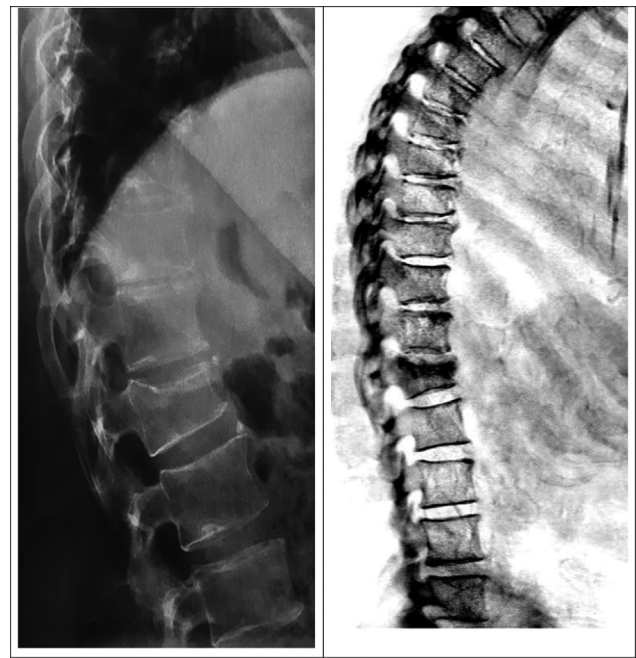


Fig. 6 An L1 osteoporotic fracture in a female hemodialyzed patient. Left: Radiographic view. Right: Lateral spinal vertebral fracture assessment view on dual-energy X-ray absorptiometry.

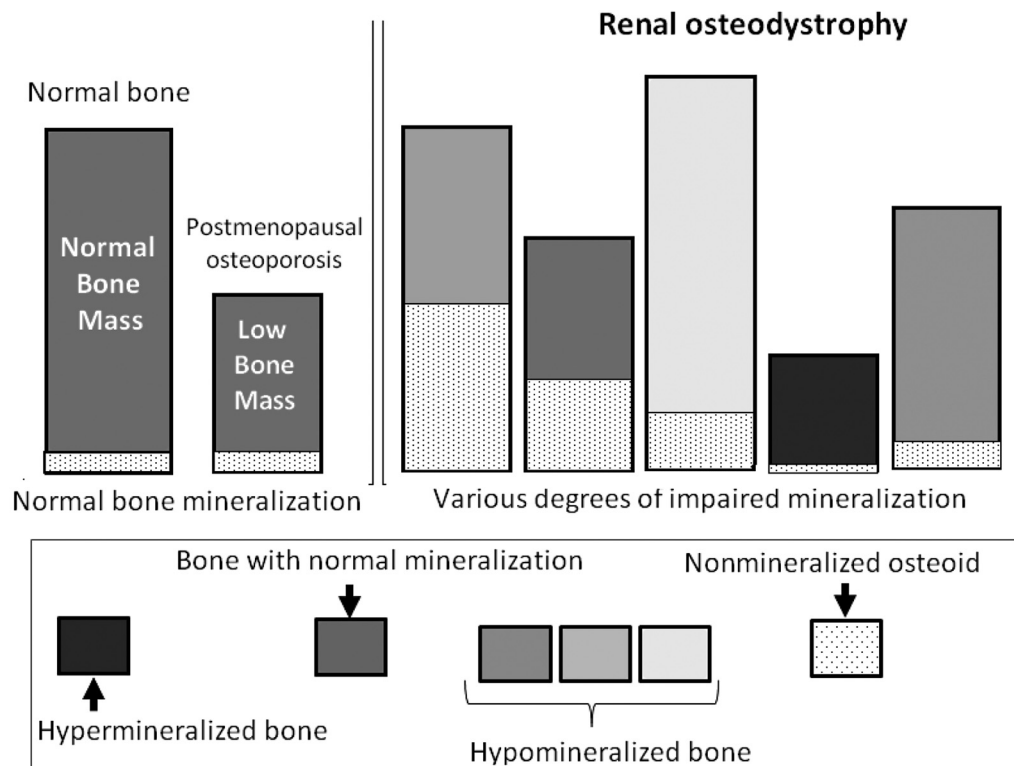


Fig. 7 Primary and secondary bone mineralization and volume abnormalities in renal osteodystrophy. Primary mineralization (mineral deposition within nonmineralized collagen: osteoid tissue) may be normal or low. Volume may be normal, low, or high. Secondary mineralization (further mineral input in mineralized tissue) may be normal, low (e.g., hyper-remodeling), or high (hypo-remodeling). These abnormalities impact bone mineral density.

QFracture, or Garvan, could be very helpful in predicting fracture risk in this population.^{22,23} High-resolution peripheral quantitative micro-CT (HR-pQCT) is presently confined to research. It is able to measure volumetric BMD and structural parameters in both the trabecular and cortical compartments at the tibia and the wrist. Several studies suggest that HR-pQCT may be useful and exhibit better performance than DEXA to predict fracture in the CKD population. However, this device is not widely available and will never be (► Fig. 2).

Treatment

Treatment of Renal Osteodystrophy

Treatment of ROD is usually initiated by the nephrologist if the patient is seen early enough. It is based on early prevention of II HPT by natural vitamin D in the early stages of CKD, then by 1- α hydroxylated derivatives, sometimes associated with calcium, with dietary advice. In patients on dialysis, dietary noncalcic phosphate chelators (sevelamer, lanthanum, or sucroferric oxyhydroxide) are then introduced in case of HPT, one of the most predictive biological factors for cardiovascular death.²⁴ Lastly, calcium receptor agonists such as cinacalcet or etelcalcetide are prescribed to counter severe II HPT. To various degrees and with levels of evidence, these treatments have a beneficial impact on bone when they act on serum PTH. As a last resort, a partial parathyroidectomy can be performed.

Specific Osteoporosis Treatments

According to their summaries of product characteristics, all anti-osteoporosis treatments are contraindicated (except for denosumab, which is not metabolized by the kidney) if GFR is < 30 mL/min. Thus administration of anti-osteoporotic drugs in patients with CKD 4 and 5 remains a matter of controversy²⁵ because of the lack of clinical studies of appropriate size evaluating these molecules. The increase in the severity of ROD in these populations makes it difficult to make confident therapeutic decisions without performing a bone biopsy, a practice that unfortunately has fallen into disuse in most nephrology departments.²⁶

There are no large-scale studies of CKD patients with GFR > 30 mL/min, but reassessment of patient GFR in the pivotal studies of anti-osteoporosis treatments showed these molecules were without danger, notably for renal function in CKD stage 2 or 3, and that they increased BMD to levels comparable with those of non-CKD subjects. Most of the studies were not suited to statistical assessment of change in fracture rates,²⁷ although the results indicated efficacy against fracture. This was the case for bisphosphonates,²⁸ teriparatide (PTH 1-34),²⁹ raloxifene (a selective estrogen receptor modulator [SERM]),³⁰ and denosumab (RANKL inhibitor monoclonal antibody).³¹ For denosumab, close monitoring of calcemia is strongly recommended due to the increased risk of hypocalcemia. And lastly, romosozumab (an anti-sclerostin antibody promoting bone formation, not available in France) has begun to show safety and efficacy for BMD in some small series.³²

Treatment of Fracture

A kyphoplasty³³ or a vertebroplasty may be indicated if a recent vertebral fracture is found, particularly in the event of intense pain, because the handling of opioids is sometimes difficult in patients with CKD stage 5. The indications for fracture surgery do not differ from those of nonuremic patients. However, because these patients are more fragile due to numerous comorbidities, the vital and functional prognosis remains worse than in fractured patients of the same age without renal insufficiency.³⁴

Conclusion

In kidney failure, bone is of concern to nephrologists, due to ROD, and to rheumatologists, due to risk of fracture. Diagnosis and fracture risk assessment have become more precise in recent years. Treatment is fairly well standardized in mild and moderate forms but is more complex in severe cases, including patients on dialysis.

Conflict of Interest

None declared.

References

- Loos-Ayav C, Briançon S, Frimat L, André JL, Kessler M pour le comité de pilotage EPIRAN. Incidence of chronic kidney disease in the general population, EPIRAN study [in French]. *Nephrol Ther* 2009;5(Suppl 4):S250–S255
- Bongard V, Dallongeville J, Arveiler D, et al. Assessment and characteristics of chronic renal insufficiency in France [in French]. *Ann Cardiol Angeiol (Paris)* 2012;61(04):239–244
- Jager KJ, Kovesdy C, Langham R, Rosenberg M, Jha V, Zoccali C. A single number for advocacy and communication—worldwide more than 850 million individuals have kidney diseases. *Kidney Int* 2019;96(05):1048–1050
- The CKD-EPI equation. Accessed June 5, 2023 at: <http://www.soc-nephrologie.org/eservice/calcul/eDFG.htm>
- Belkacem I, Galland B, Merle V, et al. Prévalence de l'IRCT et part des différentes modalités de traitement. *Nephrol Ther* 2022;x:18
- Moe S, Drüeke T, Cunningham J, et al; Kidney Disease: Improving Global Outcomes (KDIGO) Definition, evaluation, and classification of renal osteodystrophy: a position statement from Kidney Disease: Improving Global Outcomes (KDIGO). *Kidney Int* 2006; 69(11):1945–1953
- Salam SN, Eastell R, Khwaja A. Fragility fractures and osteoporosis in CKD: pathophysiology and diagnostic methods. *Am J Kidney Dis* 2014;63(06):1049–1059
- Novel-Catin E, Pelletier S, Fouque D, et al. Quantitative histomorphometric analysis of halved iliac crest bone biopsies yield comparable ROD diagnosis as full 7.5mm wide samples. *Bone* 2020;138:115460
- Lavigne F, Desbiens LC, Garneau G, Côté F, Mac-Way F. Iliac crest bone biopsy by interventional radiologists to improve access to bone biopsy in chronic kidney disease populations: technical note and a case series. *J Nephrol* 2021;34(03):901–906
- Sprague SM, Bellorin-Font E, Jorgetti V, et al. Diagnostic accuracy of bone turnover markers and bone histology in patients with CKD treated by dialysis. *Am J Kidney Dis* 2016;67(04):559–566
- Jørgensen HS, Behets G, Viaene L, et al. Diagnostic accuracy of noninvasive bone turnover markers in renal osteodystrophy. *Am J Kidney Dis* 2022;79(05):667–676.e1
- Jadoul M, Albert JM, Akiba T, et al. Incidence and risk factors for hip or other bone fractures among hemodialysis patients in the

- Dialysis Outcomes and Practice Patterns Study. *Kidney Int* 2006;70(07):1358–1366
- 13 Nickolas TL, McMahon DJ, Shane E. Relationship between moderate to severe kidney disease and hip fracture in the United States. *J Am Soc Nephrol* 2006;17(11):3223–3232
 - 14 Klawansky S, Komaroff E, Cavanaugh PF Jr, et al. Relationship between age, renal function and bone mineral density in the US population. *Osteoporos Int* 2003;14(07):570–576
 - 15 Perez-Villa F, Lafage-Proust MH, Gielen E, Ortiz A, Spasovski G, Argilés À The renal patient seen by non-renal physicians: the kidney embedded in the 'milieu intérieur'. *Clin Kidney J* 2020;14(04):1077–1087
 - 16 Jannot M, Mac-Way F, Lapiere V, Lafage-Proust MH. The use of bone mineral density measured by dual energy X-ray absorptiometry (DXA) and peripheral quantitative computed microtomography in chronic kidney disease. *J Nephrol* 2017;30(05):635–643
 - 17 Yencheck RH, Ix JH, Shlipak MG, et al; Health, Aging, and Body Composition Study. Bone mineral density and fracture risk in older individuals with CKD. *Clin J Am Soc Nephrol* 2012;7(07):1130–1136
 - 18 Naylor KL, Garg AX, Zou G, et al. Comparison of fracture risk prediction among individuals with reduced and normal kidney function. *Clin J Am Soc Nephrol* 2015;10(04):646–653
 - 19 Iimori S, Mori Y, Akita W, et al. Diagnostic usefulness of bone mineral density and biochemical markers of bone turnover in predicting fracture in CKD stage 5D patients—a single-center cohort study. *Nephrol Dial Transplant* 2012;27(01):345–351
 - 20 Rampersad C, Whitlock RH, Leslie WD, et al. Trabecular bone score in patients with chronic kidney disease. *Osteoporos Int* 2020;31(10):1905–1912
 - 21 FRAX: Tool to Evaluate Fracture Risk [in French]. Accessed June 5, 2023 at: <https://frax.shef.ac.uk/FRAX/tool.aspx?country=9>
 - 22 Desbiens LC, Sidibé A, Beaudoin C, Jean S, Mac-Way F. Comparison of fracture prediction tools in individuals without and with early chronic kidney disease: a population-based analysis of CARTA-GENE. *J Bone Miner Res* 2020;35(06):1048–1057
 - 23 Whitlock RH, Leslie WD, Shaw J, et al. The Fracture Risk Assessment Tool (FRAX®) predicts fracture risk in patients with chronic kidney disease. *Kidney Int* 2019;95(02):447–454
 - 24 Sigrist MK, Taal MW, Bungay P, McIntyre CW. Progressive vascular calcification over 2 years is associated with arterial stiffening and increased mortality in patients with stages 4 and 5 chronic kidney disease. *Clin J Am Soc Nephrol* 2007;2(06):1241–1248
 - 25 Evenepoel P, Cunningham J, Ferrari S, et al; European Renal Osteodystrophy (EUROD) workgroup, an initiative of the CKD-MBD working group of the ERA-EDTA, and the committee of Scientific Advisors and National Societies of the IOF. European Consensus Statement on the diagnosis and management of osteoporosis in chronic kidney disease stages G4–G5D. *Nephrol Dial Transplant* 2021;36(01):42–59
 - 26 Evenepoel P, D'Haese P, Bacchetta J, et al; ERA-EDTA Working Group on CKD-MBD. Bone biopsy practice patterns across Europe: the European renal osteodystrophy initiative—a position paper. *Nephrol Dial Transplant* 2017;32(10):1608–1613
 - 27 Chen CH, Lo WC, Hu PJ, et al. Efficacy of osteoporosis medications for patients with chronic kidney disease: an updated systematic review and network meta-analysis. *Front Pharmacol* 2022;13:822178
 - 28 Miller PD, Roux C, Boonen S, Barton IP, Dunlap LE, Burgio DE. Safety and efficacy of risedronate in patients with age-related reduced renal function as estimated by the Cockcroft and Gault method: a pooled analysis of nine clinical trials. *J Bone Miner Res* 2005;20(12):2105–2115
 - 29 Miller PD, Schwartz EN, Chen P, Misurski DA, Krege JH. Teriparatide in postmenopausal women with osteoporosis and mild or moderate renal impairment. *Osteoporos Int* 2007;18(01):59–68
 - 30 Ishani A, Blackwell T, Jamal SA, Cummings SR, Ensrud KEMORE Investigators. The effect of raloxifene treatment in postmenopausal women with CKD. *J Am Soc Nephrol* 2008;19(07):1430–1438
 - 31 Broadwell A, Chines A, Ebeling PR, et al. Denosumab safety and efficacy among participants in the FREEDOM extension study with mild to moderate chronic kidney disease. *J Clin Endocrinol Metab* 2021;106(02):397–409
 - 32 Miyauchi A, Hamaya E, Nishi K, Tolman C, Shimauchi J. Efficacy and safety of romosozumab among Japanese postmenopausal women with osteoporosis and mild-to-moderate chronic kidney disease. *J Bone Miner Metab* 2022;40(04):677–687
 - 33 Chen H, Yang H, Jia P, Bao L, Tang H. Effectiveness of kyphoplasty in the treatment of osteoporotic vertebral compression fracture patients with chronic kidney disease. *J Orthop Sci* 2016;21(05):571–578
 - 34 Iseri K, Carrero JJ, Evans M, et al. Secular trends in hip fracture incidence and subsequent mortality in dialysis patients and the general population in Sweden. *Bone* 2021;147:115909