



# Primary Intracranial Extraskelatal Mesenchymal Chondrosarcoma of the Brain in a Pediatric Patient: A Case Report and Review of Literature

Debanjan Sikdar<sup>1</sup> Sweety Gupta<sup>1</sup> Ravi Roshan<sup>1</sup> Shruti Agarwal<sup>2</sup> Deepa M. Joseph<sup>1</sup> Manoj Gupta<sup>1</sup>

<sup>1</sup>Radiation Oncology, All India Institute of Medical Sciences, Rishikesh, India

<sup>2</sup>Pathology, All India Institute of Medical Sciences, Rishikesh, India

Address for correspondence Debanjan Sikdar, MD, Radiation Oncology, All India Institute of Medical Sciences, Rishikesh 249202, India (e-mail: debanjansikdar@gmail.com).

Ind J Med Paediatr Oncol 2024;45:351–356.

## Abstract

### Keywords

- ▶ reirradiation
- ▶ intracranial
- ▶ management
- ▶ mesenchymal chondrosarcoma
- ▶ outcome
- ▶ pediatric

Intracranial extraskelatal mesenchymal chondrosarcoma, which is characterized by undifferentiated mesenchymal cells in the presence of occasional pockets of mature hyaline cartilage, is rare in our clinical practice and commonly seen in young adults. In the pediatric population, only a few cases have been reported. In this article, we describe a case of primary recurrent intracranial mesenchymal chondrosarcoma in an 11-year-old boy well treated by surgery, radiation, and chemotherapy. We also reviewed all previously published reports on pediatric patients on the basis of their manifestations and management.

## Introduction

Dahlin and Henderson reported the first case of intracranial extraskelatal mesenchymal chondrosarcoma (IEMC) in 1962.<sup>1</sup> It accounts for less than 0.16% of all intracranial tumors and has origins in the basal synchondroses or different parts of the meninges along the different dural folds.<sup>1</sup> The most frequent sites of origin in the central nervous system are often the meninges of the brain and spinal cord. The ideal course of treatment for IEMC is unknown at the moment, and there is scant information in the published literature concerning the procedure. With our case and previous literature review, we want to enlighten the reader about the usual clinical presentation, natural course of disease, and definitive treatment protocol for these patients. In pediatric patients, this aggressive intracranial tumor should be considered a differential diagnosis.

## Case Report

An 11-year-old boy was apparently well in 2015, when he developed headaches in the frontal region, nausea, vomiting,

a projectile nature, and abnormal body movements of all four limbs. His parents also complained about him using inappropriate words and losing social inhibition. Other systemic examinations were unremarkable. A giant, heterogeneously hyperintense mass of 5.6 × 5 × 4.6 cm occupied the left basifrontal region, extending into the suprasellar region, abutting the pituitary gland, involving the frontal lobe and frontal horn of the ventricle, and infiltrating the corpus callosum, inferiorly reaching up to the body of the sphenoid body, laterally into the parasellar region, and up to the medial temporal lobe. Its expansion caused a mass effect and a midline shift of up to 10 mm. The patient underwent frontal craniotomy, and subtotal resection (STR) of the tumor was done.

The mass, which was reddish-brown and firm in consistency, had a gritty sensation during surgery and was enucleated partially without any postoperative complications. A pathologic examination revealed the mesenchymal chondrosarcoma. Until September 2016, the patient received adjuvant radiotherapy (RT; 54Gy in 30 fractions), followed by six cycles of adjuvant chemotherapy (vincristine,

article published online  
September 14, 2023

DOI <https://doi.org/10.1055/s-0043-1770925>.  
ISSN 0971-5851.

© 2023. The Author(s).

This is an open access article published by Thieme under the terms of the Creative Commons Attribution License, permitting unrestricted use, distribution, and reproduction so long as the original work is properly cited. (<https://creativecommons.org/licenses/by/4.0/>)  
Thieme Medical and Scientific Publishers Pvt. Ltd., A-12, 2nd Floor, Sector 2, Noida-201301 UP, India

doxorubicin, and cyclophosphamide, or VAC). Following that, the patient was subjected to regular follow-up. In October 2021, there was a resurgence of the initial symptoms. The patient presented to the department of neurosurgery in the outside center with a complaint of multiple seizure episodes, progressive in intensity and frequency, not well controlled on antiepileptics, and associated with behavioral changes, but other neurological examination was within normal limits.

Magnetic resonance imaging (MRI) of the brain revealed regrowth of the previous tumor, a  $3.9 \times 4 \times 4.1$  cm, well-defined round lesion in the left frontal lobe, extending to involve the left hypothalamus, basal ganglia, optic chiasma, and left optic nerve completely encased, and left superior temporal lobe. With tumor infiltration, the orbital fissure has widened at the orbital apex, and he was seen at our institution for a second opinion and further management. He underwent a second surgery and had the tumor subtotally resected. Histopathological examination of the specimen shows spindle-shaped cells without any cartilaginous tissue (hematoxylin and eosin,  $10\times$  and  $40\times$ ). Immunohistochemical studies showed positivity for S-100 (►Fig. 1) and vimentin (►Fig. 2), which were always present, focally positive for GFAP and negative for synaptophysin, neurofilament, cytokeratin, SMA, caldesmon, EMA, ERG, MUC4, and NeuN with ki67 of 1%.

The morphology and immunophenotype of the tumor were almost unchanged over the 6-year period. The absence of necrosis and decreased mitotic activity were noted in the second histopathological specimen. Postoperative MRI of the brain showed no evidence of residual disease. Previous histopathology was also reviewed. Both histologies showed a low-grade mesenchymal tumor with an area of necrosis. A chest computed tomography (CT) scan is suggestive of multiple lung metastases. For systemic control, we start the patient on a multiple receptor tyrosine kinase inhibitor, *pazopanib* 400 mg daily. Due to a symptomatic intracranial lesion, he was planned for reirradiation at the dose of 36 Gy in 20 fractions, to restrict the cumulative dose of the optic

apparatus. The patient completed reirradiation with oral pazopanib 400 mg daily on June 20, 2022. After that, the patient is on regular monthly follow-up and oral pazopanib 600 mg daily. At present, he is doing well with good symptomatic improvement. His response assessment scan is planned for the last week of November 2022.

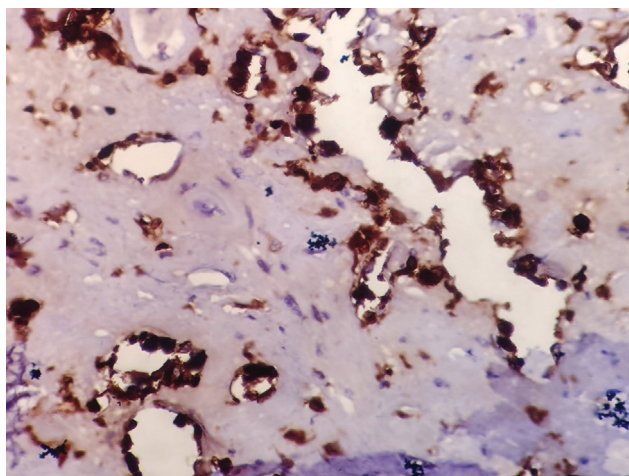
## Discussion

### Background

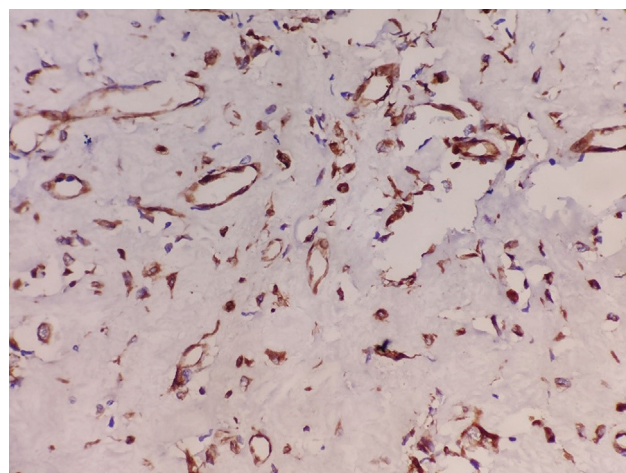
The term “mesenchymal chondrosarcoma” was coined by Lightenstein and Bernstein in 1959 based on the histopathological findings they observed in a special type of unusual chondroid tumor that originated from bone. In 1962, Dahlin and Henderson reported an intracranial tumor in a 44-year-old female patient, which is known to be the first case of IEMC.<sup>1,2</sup> However, until now, most commonly reported tumors had an origin from the base of the skull, with very few reports of intracranial extraskeletal chondrosarcomas in pediatric patients.<sup>3</sup> Mesenchymal chondrosarcoma is a variable-grade malignant tumor of the brain with a high propensity for locoregional recurrence and occasional metastasis, commonly in adult patients. Only one case other than ours with distant metastasis was reported in previous literature about pediatric patients.

### Radiological Findings

Following a clinical examination, radiological investigation, such as a CT scan, MRI, or angiography, is required to evaluate any vascular intracranial lesion. Because of the rarity of this tumor, other differential diagnoses should be ruled out radiologically before diagnosis and are also important for surgical decision-making by evaluating the possible neurovascular involvement and the extent and involvement of the mass in a diagnostic MRI. Dural base lesions such as meningioma or low-grade gliomas such as oligodendroglioma, astrocytoma, and hemangiopericytoma should be the preoperative differential diagnosis. Plain skull X-rays, though rarely utilized, show signs of raised intracranial pressure such as a “beaten copper” appearance, stippled calcification,



**Fig. 1** Immunohistochemical examination shows diffuse positivity of marker S-100, which is always positive in intracranial chondrosarcoma.



**Fig. 2** Immunohistochemistry of highly cellular tumor showing positivity of vimentine.

or destructive changes.<sup>4</sup> Because of its high vascularity, MRI is the imaging modality of choice for IEMC. A well-defined lobulated brain lesion with T1-contrast hyperintensity, iso-intensity, or homogenous hyperintensity of the T2-weighted image is the characteristic MRI finding in IEMC.<sup>5</sup>

Consequently, for the same reason, especially for larger lesions, angiography in the preoperative setting allows prophylactic embolization to reduce blood loss during resection. After the initial treatment, metastasis to extracranial sites was very rare in pediatric patients. A spinal metastasis was reported after a long dormant period, but our case had multiple lung metastases.<sup>5-8</sup> That is why, as metastatic work-up in the form of a CT scan of the thorax is mandatory in primary IEMC, and to rule out the primary from the other site, a whole-body positron emission tomography (PET)-CT scan or bone scan with contrast-enhanced CT of the thorax and abdomen should be considered mandatory investigations.

### Tumor Characteristics and Presentation

The most common presentation of IEMC is due to raised intracranial pressure or direct compressive impact on surrounding structures. Intraoperative findings of these tumors are seen as smooth tumors, with a color ranging from grey to red, depending on the grade. During tumor resection, they are firm to hard to the touch with a gritty sensation.<sup>6,9,10</sup> The histological features are not consistent. IEMCs typically have the appearance of a small round cell cluster or sheet with or without hyaline cartilage islands.<sup>9</sup> Due to the absence of this characteristic cartilaginous part in histopathology, the diagnosis of IEMC has become very challenging. In a case like ours, where the typical histological pattern is absent, other common differential diagnoses should be ruled out first. In the pediatric age group, parenchymal lesions such as supratentorial primitive neuroectodermal tumor, high-grade non-Hodgkin's lymphoma, malignant hemangiopericytoma, or lesions originating from the base of the skull, such as chondrosarcoma at the skull base, embryonal rhabdomyosarcoma, or small cell osteosarcoma, should be the other differentials.<sup>11-15</sup> That is why, IHC is important to distinguish between those diagnoses, but no proper Immunohistochemistry (IHC) patterns have been identified till now, which is characteristic of IEMC. However, it is almost always positive for vimentin and S-100 and negative for synaptophysin, chromogranin, and EMA, but occasionally positive for GFAP (25% of the time).

### Origin of the Tumor

Intracranial chondrosarcoma can be divided into classic, mesenchymal, and myxoid variants. The difference lies in the findings in histopathology, presentation, and outcome. Due to its rarity, the origin of intracranial mesenchymal chondrosarcoma is still not clear. In different studies, multiple hypotheses were proposed. The primary origin of the tumor is thought to be from either the meningeal layers or intraparenchymal. It can also be from the embryonic cartilaginous rest cells in the cranial bones and dura, as there were reported cases in pediatric patients, or pre-mesenchymal chondroprogenitor cells, meningeal fibroblasts, or mes-

enchymal cells in the dura or arachnoid. Among them, dural-based lesions were more abundant (66%) than parenchymal (37%) lesions in the pediatric group of patients.<sup>4,16</sup> Previous reports have usually shown that dural-based lesions have better survival rates than parenchymal lesions. In this series, dural-based lesions had a mean overall survival of 53.8 months, compared with 28 months for parenchymal lesions, and there was a trend toward improved survival in patients with tumors having dural attachment.

### Location

Eighty percent of these tumors are supratentorial in location, and the origin is dural-based. In our review, we found that this was also true for the pediatric group of patients. Almost 86% ( $n = 18$ ) of the tumors are supratentorial in location, with the most common site being the frontal region. In our case, the tumor is supratentorial- and parenchymal-based. Chondrosarcomas that arise at the skull base should be differentiated from intracranial mesenchymal chondrosarcomas, as the origin of skull base tumors is cartilaginous synchondroses that are usually located in the parasellar region, the cerebellopontine angle, cavernous sinuses, larger skull foramina, and the petrous part of the thoracic bone region. In our series, very few reported cases ( $n = 3$ ) have origins in other locations in the brain; thus, survival differences in different locations cannot be determined.

### Role of Surgery

All the cases in the literature review have been treated primarily with surgery (→ **Table 1**), including our reported case that underwent more than one resection despite lacking any consensus about the treatment strategy.<sup>17,18</sup> The majority of these tumors have been described as highly vascular lesions. Despite this, radical removal of these lesions is the mainstay of management, regardless of their anatomic location. When treated surgically, maximum safe resection is the goal. Gross total resection (GTR) is the most desirable for any intracranial tumor, and it is not different for IEMC. According to our review, 57% of patients had GTR and had a higher survival rate (mean overall survival = 49 months) than STR, which had a lower survival rate (mean overall survival = 39 months). This could be a poor prognostic factor that is related to an inability to get a GTR to prevent tumor spread and recurrence.<sup>9,10,19</sup>

### Role of Radiotherapy

Adjuvant RT should be an appropriate therapeutic option as this is a locally aggressive tumor with a high rate of local recurrence. In the literature review, there was no overall survival difference between adjuvant RT and non-RT patients. However, there is a significant improvement in overall survival with adjuvant RT after STR (STR + adjuvant RT,  $n = 5$ , mean OS = 54.4 months vs STR without RT,  $n = 4$ , mean OS = 20 months). Thus, postoperative adjuvant RT is a preferred treatment for the tumor that could not be completely resected. Some authors also consider adjuvant RT if the diffuse or infiltrative nature of the tumor is described by the neurosurgeon even after GTR.<sup>2</sup> Also, other

**Table 1** Previously published case with our case report of intracranial extraskeletal chondrosarcoma in pediatric population

Serial number	Study	Age	Sex	Size	Location	Attachment	Surgery	RT	Dose	CT	Drug	Follow-up	Recurrence	Metastasis	Location
1	Flyger et al 1963 <sup>17</sup>	11 y	M	5 × 4 × 3	Frontal	Parenchymal	GTR	No		No		3	No	No	
2	Scheithauer et al 1978 <sup>9</sup>	7 y	M		Parietotemporal	Dura	GTR	No		No		84	Yes	No	
3	Rollo et al 1979 <sup>7</sup>	11 y	M		Parietal	Dura	STR	Yes	48 Gy	No		96	Yes	Yes	Spinal
4	Kobayashi et al 1980 <sup>20</sup>	11 y	M		Parietal	Dura	GTR	No		No		216	Yes	No	
5	Rodda et al 1984 <sup>31</sup>	12 y	F		Frontoparietal	Parenchymal	GTR	No		No		7	No	No	
6	Chhem et al 1992 <sup>21</sup>	11 y	F	3.5 × 3.5	Parietal	Parenchymal	STR	Yes	60 Gy	No		18	No	No	
7	Schut et al 1994 <sup>22</sup>	1 y	M		Frontal	Dura	STR	No		No		NK	Yes	No	
8	Schut et al 1994 <sup>22</sup>	12 y	F		Frontal	Dura	STR	Yes	NK	Yes		NK	Yes	No	
9	Rushing et al 1996 <sup>19</sup>	5 y	M		Frontal	Dura	GTR	Yes	44 Gy	No		14	No	No	
10	Rushing et al 1996 <sup>19</sup>	7 y	F		Sphenoid	Dura	STR	No		No		60	No	No	
11	Rushing et al 1996 <sup>19</sup>	11 y	F		Frontal	Dura	STR	Yes	55 Gy	No		20	No	No	
12	Malik et al 1996 <sup>23</sup>	8 y	M		Cerebellum	Parenchymal	GTR	Yes	NK	Yes		NK	No	No	
13	Crosswell et al 2000 <sup>24</sup>	6 mo	M	10 × 9 × 6	Frontoparietal	Dura	GTR	No		Yes	A + E + C	2	No	No	
14	Sardi et al	12 y	M		Frontal	Dura	GTR	No		No		NK	No	No	
15	Sardi et al <sup>32</sup>	12 y	F		Falcine	Dura	GTR	No		No		30	No	No	
16	Kan et al 2012 <sup>25</sup>	11 y	F		Parietal	Parenchymal	GTR	Yes	NK	No		18	Yes	No	
17	Sadashiv et al <sup>33</sup>	7 y	M		Occipital	Parenchymal	STR	No		No		6	Yes	No	
18	Waliuddin et al 2006 <sup>26</sup>	4 y	M	9 × 8 × 6	Temporoparietal	Dura	GTR	Yes	NK	No		4	Yes	No	
19	De Cecio et al 2008 <sup>11</sup>	2 mo	M	11 × 9 × 6	Parietal	Dura	GTR	No		No		NK	No	No	
20	Fanburg-Smith et al 2010 <sup>27</sup>	12 y	F		Frontal	Dura	STR	No		No		NK	No	No	
21	Our study	11 y	M	5.8 × 5 × 4.6	Frontal	Parenchymal	STR	Yes	56 Gy	Yes	V + A + C	84	Yes	Yes	Lung

Abbreviations: CT, chemotherapy; GTR, gross total resection; RT, radiotherapy; STR, subtotal resection; A, Adriamycin; E, Etoposide; C, Cyclophosphamide; V, Vincristine; NK, Not Known.

chondrosarcomas, even those that originated at the base of the skull, are treated with surgery followed by adjuvant RT with or without adjuvant chemotherapy.<sup>5,28</sup> In regard to unresectable IEMC and those with residual disease in previously published cases, the authors mentioned that RT with or without concurrent chemotherapy is the best treatment option for these patients. As a result, adjuvant RT should be considered in all patients and made mandatory in those with inadequate surgery.

### Role of Chemotherapy

Mesenchymal chondrosarcoma of other sites is typically a high-grade tumor, and multiagent chemotherapy in the form of neoadjuvant and adjuvant therapy, as with Ewing's sarcoma, is the mainstay of treatment. The benefits of chemotherapy in intracranial mesenchymal chondrosarcoma are still unclear, as these tumors have no current reliable evidence for its effectiveness, and a very limited number of patients received chemotherapy in an adjuvant setting, which failed to show any survival benefit. Chemotherapy is being studied; more data are needed to prove any benefit, but chemotherapy has been recommended in previous published cases.<sup>29,30</sup> However, in a metastatic setting, chemotherapy should be a part of treatment. Nevertheless, as the mesenchymal chondrosarcoma of the extracranial region is treated as Ewing's sarcoma, multiagent chemotherapy (vincristine, cyclophosphamide, doxorubicin, actinomycin-D, ifosfamide, and etoposide in different combinations) can be considered in adjuvant settings as well, especially in high-grade tumors or tumors with incomplete surgical resection.

### Survival and Prognostic Factors

If we consider all subsites in the body, mesenchymal chondrosarcoma has a 5- and 10-year survival rate of 55 and 27%.<sup>9</sup> In pediatric patients, the 2-year overall survival rate is 48% in our review. Our review's 5- and 10-year overall survival rates of 33 and 10%, respectively, are slightly lower than those of conventional mesenchymal chondrosarcoma, indicating the tumor's most malignant nature, which is locally aggressive with a high rate of recurrence.<sup>6</sup> After discussing all those mentioned factors, we propose that the underlying factors that influence the prognosis of the tumor and overall survival include grade, location (supratentorial or infratentorial), origin of the tumor (dural or parenchymal), type of surgical resection (GTR or STR), and use of postoperative adjuvant RT or chemotherapy.

### Review of Previous Published Cases

From our data sources, 20 cases have been reported in the literature before our patient. The ages ranged from 2 months to 12 years, with 8.5 years being the average (median age: 11 years). In our discussion, we only restrict ourselves to previously published pediatric cases with an age group of 12 or less patients and their clinical and available management details. In the pediatric group of patients, there is a slight male preponderance with a male-to-female ratio of 1.6:1. The size of the tumor ranges from 3 to 11 cm at its largest diameter. We found the origin of the tumor was also

divided on the basis of dural or parenchymal. In our case report, the patient had a tumor of parenchymal origin without any dural attachment. In previously reviewed studies, dural and parenchymal tumors had a ratio of 3:2 (dural:  $n = 14$ ; parenchymal:  $n = 7$ ). Among all the patients, more than half underwent GTR ( $n = 12$ , 57%) compared with STR ( $n = 9$ , 42%). Of the 21 ( $n = 9$ ; 42% of total) patients that received RT postsurgery with a dose of 44 to 60 Gy, only 4 (19%) had chemotherapy as an adjuvant setting, and chemotherapy details for 1 patient are available. Nine patients had local recurrences at the same site of origin. Only one patient had a distant recurrence to the spinal cord and was treated with palliative RT. The median overall survival for the entire set of reported cases where follow-up was provided was 20 months. Patients with GTR had a slightly better median survival than patients with STR. Patients with or without a RT group have no difference in overall survival.

### Conclusion

IEMC in the pediatric population is an extremely rare and variable-grade neoplasm with a very high tendency to local failure and distant metastasis. Due to the lack of specific radiological and histopathological findings, it is a challenge to differentiate it from other common tumors. The treatment options are GTR followed by close postoperative follow-up with or without adjuvant treatment, or STR with adjuvant RT with or without adjuvant chemotherapy. RT may be considered to reduce the risk of local recurrence, and chemotherapy may be useful for systemic control. As these tumors are highly aggressive with the potential for local and distant failure, the patient should be kept under regular follow-up.

### Authors' Contributions

D.S.: design, manuscript preparation; S.G.: clinical studies, data analysis; R.R.: literature search; S.A.: diagnosis; D.M.J.: manuscript editing; M.G.: manuscript review. This manuscript has been read and approved by all the authors.

### Source of Funding

None.

### Conflict of Interest

None declared.

### Acknowledgement

We are thankful to our medical physics team for role in making excellent radiotherapy plan.

### References

- Dahlin DC, Henderson ED. Mesenchymal chondrosarcoma. Further observations on a new entity. *Cancer* 1962;15:410-417
- Lightenstein L, Bernstein D. Unusual benign and malignant chondroid tumors of bone. A survey of some mesenchymal cartilage tumors and malignant chondroblastic tumors, including a few multicentric ones, as well as many atypical benign chondroblastomas and chondromyxoid fibromas. *Cancer* 1959;12:1142-1157

- 3 Lin L, Varikatt W, Dexter M, Ng T. Diagnostic pitfall in the diagnosis of mesenchymal chondrosarcoma arising in the central nervous system. *Neuropathology* 2012;32(01):82–90
- 4 Harsh GRI IV, Wilson CB. Central nervous system mesenchymal chondrosarcoma. Case report. *J Neurosurg* 1984;61(02):375–381
- 5 Bingaman KD, Alleyne CH Jr, Olson JJ. Intracranial extraskelatal mesenchymal chondrosarcoma: case report. *Neurosurgery* 2000;46(01):207–211, discussion 211–212
- 6 Hassounah M, Al-Mefty O, Akhtar M, Jinkins JR, Fox JL. Primary cranial and intracranial chondrosarcoma. A survey. *Acta Neurochir (Wien)* 1985;78(3–4):123–132
- 7 Rollo JL, Green WR, Kahn LB. Primary meningeal mesenchymal chondrosarcoma. *Arch Pathol Lab Med* 1979;103(05):239–243
- 8 Waga S, Matsushima M, Ando K, Morii S. Intracranial chondrosarcoma with extracranial metastases. Case report. *J Neurosurg* 1972;36(06):790–794
- 9 Scheithauer BW, Rubinstein LJ. Meningeal mesenchymal chondrosarcoma: report of 8 cases with review of the literature. *Cancer* 1978;42(06):2744–2752
- 10 Heros RC, Martinez AJ, Ahn HS. Intracranial mesenchymal chondrosarcoma. *Surg Neurol* 1980;14(04):311–317
- 11 De Cecio R, Migliaccio I, Falletti J, Del Basso De Caro M, Pettinato G. Congenital intracranial mesenchymal chondrosarcoma: case report and review of the literature in pediatric patients. *Pediatr Dev Pathol* 2008;11(04):309–313
- 12 González-Cámpora R, Otal Salaverri C, Gomez Pascual A, Hevia Vazquez A, Galera Davidson H. Mesenchymal chondrosarcoma of the retroperitoneum. Report of a case diagnosed by fine needle aspiration biopsy with immunohistochemical, electron microscopic demonstration of S-100 protein in undifferentiated cells. *Acta Cytol* 1995;39(06):1237–1243
- 13 Misra V, Singh PA. Cytodiagnosis of extraosseous mesenchymal chondrosarcoma of meninges: a case report. *Acta Cytol* 2008;52(03):366–368
- 14 Trembath DG, Dash R, Major NM, Dodd LG. Cytopathology of mesenchymal chondrosarcomas: a report and comparison of four patients. *Cancer* 2003;99(04):211–216
- 15 Walaas L, Kindblom LG, Gunterberg B, Bergh P. Light and electron microscopic examination of fine-needle aspirates in the preoperative diagnosis of cartilaginous tumors. *Diagn Cytopathol* 1990;6(06):396–408
- 16 Steiner GC, Mirra JM, Bullough PG. Mesenchymal chondrosarcoma. A study of the ultrastructure. *Cancer* 1973;32(04):926–939
- 17 Flyger G, Freidenfeldt H, Orell SR. Intracerebral, possibly malignant osteochondrofibroma in a child. *Acta Pathol Microbiol Scand* 1963;58:299–305
- 18 Guccion JG, Font RL, Enzinger FM, Zimmerman LE. Extraskelatal mesenchymal chondrosarcoma. *Arch Pathol* 1973;95(05):336–340
- 19 Rushing EJ, Armonda RA, Ansari Q, Mena H. Mesenchymal chondrosarcoma: a clinicopathologic and flow cytometric study of 13 cases presenting in the central nervous system. *Cancer* 1996;77(09):1884–1891
- 20 Kobayashi T, Yoshida J, Kageyama N, Makita Y, Aoyama I, Yamashita J. Mesenchymal chondrosarcoma arising from dura mater (author's transl) [in Japanese]. *No Shinkei Geka* 1980;8(09):881–887
- 21 Chhem RK, Bui BT, Calderon-Villar H, Fontaine S. Case report: primary mesenchymal chondrosarcoma of the brain. *Clin Radiol* 1992;45(06):422–423
- 22 Schut L, Canady AI, Sutton LN, Bruce DA. Meningeal tumors in children. 1983. *Pediatr Neurosurg* 1994;20(03):207–212, discussion 213
- 23 Malik SN, Farmer PM, Hajdu SI, Rosenthal A. Mesenchymal chondrosarcoma of the cerebellum. *Ann Clin Lab Sci* 1996;26(06):496–500
- 24 Crosswell H, Buchino JJ, Sweetman R, Reisner A. Intracranial mesenchymal chondrosarcoma in an infant. *Med Pediatr Oncol* 2000;34(05):370–374
- 25 Kan Z, Li H, Zhang J, You C. Intracranial mesenchymal chondrosarcoma: case report and literature review. *Br J Neurosurg* 2012;26(06):912–914
- 26 Waliuddin A, Jamjoom AB, Thomas J. Intracranial extraskelatal mesenchymal chondrosarcoma. *Neurosciences (Riyadh)* 2006;11(03):205–209
- 27 Fanburg-Smith JC, Auerbach A, Marwaha JS, et al. Immunoprofile of mesenchymal chondrosarcoma: aberrant desmin and EMA expression, retention of INI1, and negative estrogen receptor in 22 female-predominant central nervous system and musculoskeletal cases. *Ann Diagn Pathol* 2010;14(01):8–14
- 28 Kubota T, Hayashi M, Yamamoto S. Primary intracranial mesenchymal chondrosarcoma: case report with review of the literature. *Neurosurgery* 1982;10(01):105–110
- 29 Parker JR, Zarabi MC, Parker JC Jr. Intracerebral mesenchymal chondrosarcoma. *Ann Clin Lab Sci* 1989;19(06):401–407
- 30 Salvador AH, Beabout JW, Dahlin DC. Mesenchymal chondrosarcoma—observations on 30 new cases. *Cancer* 1971;28(03):605–615
- 31 Rodda RA, Franklin CI. Intracranial meningeal chondrosarcoma—probable mesenchymal type. *Aust N Z J Surg* 1984;54(04):387–390
- 32 Sardi I, Massimo M, Genitori L, Buccoliero AM, Giangaspero F, Ferrari A. Intracranial mesenchymal chondrosarcoma: report of two pediatric cases. *Pediatr Blood Cancer* 2011;56(04):685–686
- 33 Sadashiva N, Sharma A, Shukla D, Rajalakshmi P, Mahadevan A, Devi BI. Intracranial Extraskelatal Mesenchymal Chondrosarcoma. *World Neurosurg* 2016;95(618):e1–618.e6