

Pelvic Venous Disorders: An Update in Terminology, Diagnosis, and Treatment

Meghan R. Clark, MD¹ Amy C. Taylor, MD¹

¹Division of Vascular and Interventional Radiology, Department of Radiology and Medical Imaging, University of Virginia Health System, Charlottesville, Virginia

Address for correspondence Amy C. Taylor, MD, Division of Vascular and Interventional Radiology, Department of Radiology and Medical Imaging, University of Virginia Health System, Charlottesville, VA 22908 (e-mail: actaylor@virginia.edu).

Semin Intervent Radiol 2023;40:362–371

Abstract

Keywords

- ▶ pelvic venous disease
- ▶ pelvic pain
- ▶ embolization
- ▶ sclerotherapy
- ▶ interventional radiology
- ▶ women's health

Pelvic venous disorder (PeVD) is a term that encompasses all the interrelated causes of chronic pelvic pain (CPP) and perineal/lower extremity varicose veins of pelvic venous origin historically known as nutcracker syndrome, pelvic congestion syndrome, and May-Thurner syndrome, resulting in a more precise diagnosis that accounts for the underlying pathophysiology and anatomy. PeVD manifests as CPP with associated vulvar and lower-extremity varicosities, left flank pain and hematuria, and lower extremity pain and swelling secondary to obstruction or reflux in the left renal, ovarian, or iliac veins. This article will focus specifically on the most current nomenclature, evaluation, and management of CPP of venous origin.

Chronic pelvic pain (CPP) is noncyclical pelvic pain lasting for more than 6 months with associated functional disability or requiring medical care.¹ CPP is very common, affecting 15% of people aged 18 to 50 years with female-assigned pelvic anatomy in the United States, and up to 27% worldwide.^{2,3} Patients with CPP undergo gynecological surgeries and consume medications at a rate three to four times higher than healthy patients.³ The cost of CPP in the United States in 2020 was conservatively estimated to be \$5.8 billion, though is likely underestimated as it is based on a valuation from 1996.^{2,4} CPP accounts for 12% of hysterectomies and 40% of diagnostic laparoscopies in the United States, but only 60% of diagnostic laparoscopies performed for CPP are able to identify the underlying cause of the patient's symptoms.^{5–7} The broad differential diagnosis for CPP includes gynecologic, neurologic, musculoskeletal, gastrointestinal, urologic, vascular, and psychiatric etiologies. Furthermore, CPP is often associated with other conditions with overlapping symptoms, such as fibromyalgia, neuropathic pain, chronic low back pain, irritable bowel syndrome, interstitial cystitis, and endometriosis which makes the diagnostic process even more challenging.⁴ As a result, physicians often struggle to accurately diagnose the cause of patients' CPP, particularly when the underlying cause is venous in origin, which leads to delayed diagnoses, frustration, ineffective treatments, and

prolonged pain and suffering for patients. Distinguishing pelvic venous congestion from other causes of CPP is further hindered by lack of recognition of CPP of venous origin by the broader medical and gynecologic communities. For example, CPP of venous origin was not even mentioned in a recent review article on CPP published in the *Journal of the American Medical Association*, and a history and physical template developed by the International Pelvic Pain Society (IPPS) largely overlooks questions that could identify pelvic venous disease as a cause of CPP.⁴ Several factors contribute to this lack of recognition, including the historical nomenclature's failure to capture the spectrum of pelvic venous disease, the absence of validated diagnostic criteria and disease-specific definitions, and limited evidence for existing treatments.

Systems-Varices-Pathophysiology Classification

Previously, terms such as May-Thurner, nutcracker, and pelvic congestion syndromes were utilized to describe typical presentations of PeVD; however, these terms fail to accurately depict the pathophysiology and intricate overlapping nature of this disease spectrum. Lack of validated diagnostic tools and disease-specific definitions has precluded development of clinical trials and thus limited the ability

to amass clinical evidence supporting treatments for PeVD. To address this problem, a multidisciplinary panel representing all stakeholders was assembled to create a disease-specific discriminative tool to accurately categorize patients with PeVD. The panel ultimately created the Systems-Varices-Pathophysiology (SVP) classification system for PeVD, with the goal of establishing a standardized approach to the characterization, diagnosis, and management of the disease spectrum.⁸ This instrument is analogous to the CEAP (clinical, etiology, anatomy, pathophysiology) classification system for lower extremity venous disorders and is composed of three domains.^{8,9} The symptoms (S) and varices (V) domains describe the primary clinical manifestations of PeVD, and the pathophysiology (P) domain is a composite domain made up of involved anatomy (A), hemodynamic abnormalities (H), and etiology (E), which are reported as subscripts of P (P_{AHE} ; see ► **Table 1**). For example, a person with CPP and bilateral ovarian vein reflux who would have previously been diagnosed with “pelvic congestion syndrome” would be characterized: $S_2V_2P_{BGV,R,NT}$. Fortunately, the panel behind the SVP classification system had the foresight to develop a smartphone app available for iPhones and Androids so the classification need not be memorized. Moving forward, it is critical that physicians caring for these patients use this system in clinical practice to serve as a reporting standard and provide clarity in clinical communication. Although the SVP tool is useful for categorization, it is a classification tool only and cannot be used to assess disease severity, progression, or treatment response. At the time of writing, a patient-reported outcome instrument to assess quality-of-life (QoL) metrics specific to PeVD is currently being developed, which will allow for measurement of symptom severity and changes over time.^{8,10,11}

Anatomy and Pathophysiology

The primary venous outflow of the female pelvis is through the ovarian and internal iliac veins. The ovarian veins have asymmetric drainage patterns, with the left ovarian vein draining into the left renal vein prior to draining into the inferior vena cava (IVC) and the right ovarian vein draining directly into the IVC. The internal iliac veins drain into the common iliac veins which join to form the IVC (► **Fig. 1**). The left renal hilum, visceral and parietal pelvic veins, and superficial extrapelvic veins are the relevant venous reservoirs in PeVD.^{8,11} The pelvic venous reservoir intercommunicates with the veins in the thighs and perineum (superficial extrapelvic veins) through the pelvic floor at pelvic escape points, as well as the left renal hilum through the left ovarian vein. Venous reflux, obstruction, or a combination thereof in the pelvic veins results in pelvic venous congestion which can then be transmitted to the adjacent venous reservoirs, causing associated symptoms and varices.^{8,11} Pain from venous hypertension is thought to be related to activation of nociceptors from venous distention as well as endothelial dysfunction setting off an inflammatory response, which further potentiates valvular and endothelial dysfunction.^{12,13} Estrogen and progesterone are thought to play a

major role in the pathophysiology of pelvic venous insufficiency through their vasodilatory effects.^{13–15} Pregnancy can precipitate and worsen existing pelvic venous disease due to the extreme physiologic levels of progesterone and estrogen in pregnancy combined with the mechanical venous outflow obstruction by the gravid uterus, and increased circulating blood volume, which may explain why patients can experience progression of symptoms with each pregnancy.^{16–18} Central sensitization, a neurobiological phenomenon of abnormal pain processing that can result in amplification of pain signals which can spread to adjacent organs, is also thought to contribute to the pain associated with pelvic venous disease, and offers an explanation of how the severity of pelvic venous insufficiency does not correlate with severity of symptoms.¹²

Clinical Presentation and Indications for Intervention

The most common presentation of pelvic venous congestion is CPP and pelvic varices involving the vulva, perineum, or upper thigh. The pain associated with PeVD is often described as dull, noncyclical throbbing pelvic pain (unilateral or bilateral), worsened with long periods of standing or walking and punctuated by intermittent sharp pain. Prolonged postcoital ache, tenderness over the ovarian point, and increased pain with standing have been found to be >70% sensitive and specific for discerning CPP of venous origin from other causes of CPP.^{19,20} Dysmenorrhea and deep dyspareunia are also common; however, these symptoms are essentially universal among most causes of CPP. Symptoms of pelvic venous congestion exhibit daily fluctuations similar to those seen in lower extremity venous disease, often worse at the end of the day with improvement of symptoms after lying down. Patients are typically multiparous women in their 30s or 40s who report progression of symptoms with each pregnancy.

Imaging

There are currently no published consensus diagnostic imaging criteria for PeVD and no agreement on the optimal imaging assessment of CPP of suspected venous origin, but despite this, imaging does play a crucial role in the evaluation of CPP of suspected venous origin. Catheter venography remains the gold standard for the diagnosis of PeVD due to its superior assessment of venous hemodynamics, ability to take pressure measurements, and ability to perform provocative maneuvers (Valsalva, table tilting, etc.). However, non-invasive imaging modalities are often used for initial evaluation to justify invasive venography and for procedural planning. Transabdominal and transvaginal duplex ultrasound are a common and reasonable first choice in imaging considering their availability, cost-effectiveness, and ability to assess venous reflux and perform provocative maneuvers. Cross-sectional imaging modalities are helpful for assessing pelvic venous insufficiency secondary to vascular compression as well as evaluating for other potential etiologies of CPP. Traditional contrasted MRI and CT are poorly suited for

Table 1 Symptoms-Varices-Pathophysiology classification of PeVD⁸

Symptoms	
S ₀	No symptoms of PeVD (no renal, pelvic, or extrapelvic symptoms)
S ₁	Renal symptoms of venous origin
S ₂	Chronic pelvic pain of venous origin
S ₃	Extrapelvic symptoms of venous origin a. Localized symptoms (pain, discomfort, tenderness, itching, bleeding, and superficial venous thrombosis) associated with veins of the external genitalia (vulva and scrotum) b. Localized symptoms associated with pelvic origin nonsaphenous veins of the leg. These include those related to pelvic origin varices of the posteromedial thigh (pain, discomfort, tenderness, itching, superficial venous thrombosis) c. Venous claudication (must include CEAP classification or full characterization)
Varices	
V ₀	No abdominal, pelvic, or pelvic origin extrapelvic varices on clinical or imaging examination
V ₁	Renal hilar varices
V ₂	Pelvic varices
V ₃	Pelvic origin extrapelvic varices a. Genital varices (vulvar varices and varicocele) b. Pelvic origin lower extremity varicose veins arising from the pelvic escape points and extending into the thigh. Includes visible varicosities, typically over the posteromedial thigh as well as sciatic varices and other refluxing veins transitioning the pelvic floor which are usually visualized only on ultrasound
Pathophysiology— anatomy, hemodynamics, etiology	
Anatomy	
IVC	Inferior vena cava
LRV	Left renal vein
GV	Gonadal (testicular, ovarian) vein
LGV	Left gonadal vein
RGV	Right gonadal vein
BGV	Bilateral gonadal veins
CIV	Common iliac vein
LCIV	Left common iliac vein
RCIV	Right common iliac vein
BCIV	Bilateral common iliac veins
EIV	External iliac vein
LEIV	Left external iliac vein
REIV	Right external iliac vein
BCIV	Bilateral external iliac veins
IIV	Internal iliac vein
LIIV	Left internal iliac vein
RIIV	Right internal iliac vein
BIIV	Bilateral internal iliac veins
PELV	Pelvic escape veins; inguinal, obturator, pudendal, and/or gluteal
Hemodynamics	
O	Obstruction—thrombotic or nonthrombotic
R	Reflux—thrombotic or nonthrombotic
Etiology	
T	Thrombotic—venous reflux or obstruction after a DVT
N	Nonthrombotic—reflux arising from a degenerative process of the vein wall or proximal obstruction; obstruction arising from extrinsic compression
C	Congenital—congenital venous or mixed vascular malformation

Abbreviations: CEAP, clinical, etiology, anatomy, pathophysiology; DVT, deep venous thrombosis; PeVD, pelvic venous disorders.

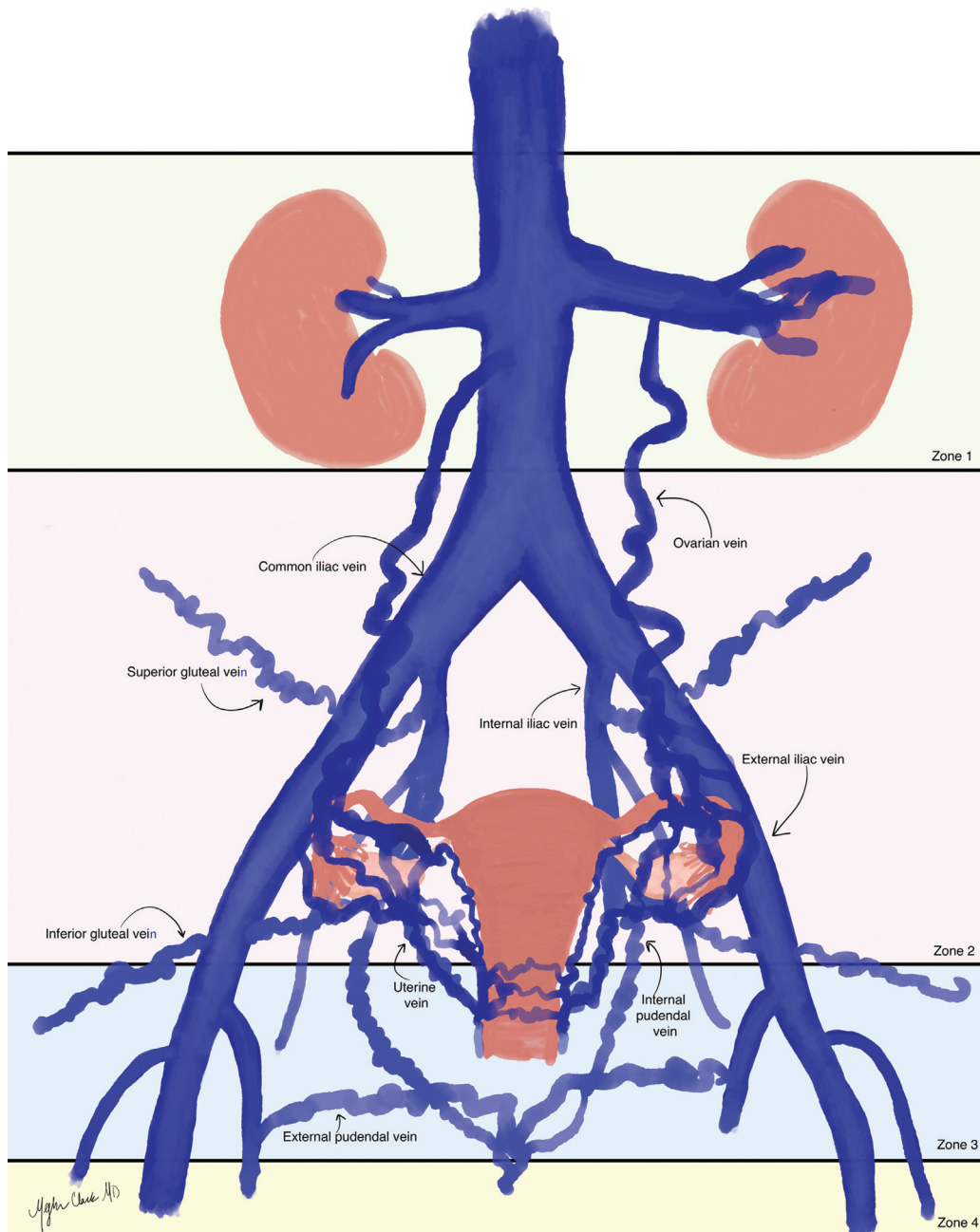


Fig. 1 The SVP classification system applies to anatomic Zones 1–3 while the CEAP classification system applies to Zone 4. Zone 1 (light green) encompasses the left renal hilum venous reservoir; venous hypertension in this reservoir is associated with renal symptoms of venous origin (flank pain, hematuria, etc.). When severe enough, venous hypertension in the left renal hilum can spill over into the pelvic venous reservoir (Zone 2, pink) via reflux into the left ovarian vein. Zone 2 encompasses the pelvic venous reservoir (ovarian veins, internal iliac veins, and pelvic venous plexus) and venous insufficiency in this reservoir is classically associated with symptoms of chronic pelvic pain of venous origin. Zone 3 (light blue) encompasses the pelvic-origin extrapelvic venous reservoir, where venous insufficiency results in vulvar and upper thigh varices due to reflux in pelvic-origin extrapelvic veins through pelvic escape points. Zone 4—yellow.

hemodynamic assessment, specifically looking for retrograde flow in the ovarian or internal iliac veins; however, MR venography with time-resolved imaging (► **Figs. 2** and **3**) can demonstrate venous reflux with good sensitivity (66–75%) and specificity (100%).²¹ Ultimately, the best imaging approach depends on local expertise and available resources. Some authors even contend that experienced sonographers may eliminate the need for cross-sectional imaging.¹⁰ See ► **Table 2** for imaging findings of PeVD as

well as pros and cons of the different imaging modalities used in the evaluation of PeVD.

Imaging findings suggestive of pelvic venous insufficiency across all modalities are ovarian vein reflux, either spontaneous or provoked (the most sensitive and specific imaging finding for PeVD)^{22,23}; a dilated ovarian vein ≥ 6 mm, though this finding alone is not indicative or sufficient to support the diagnosis of PeVD, as dilated veins can be competent and smaller veins can reflux; and pelvic varices, defined by the

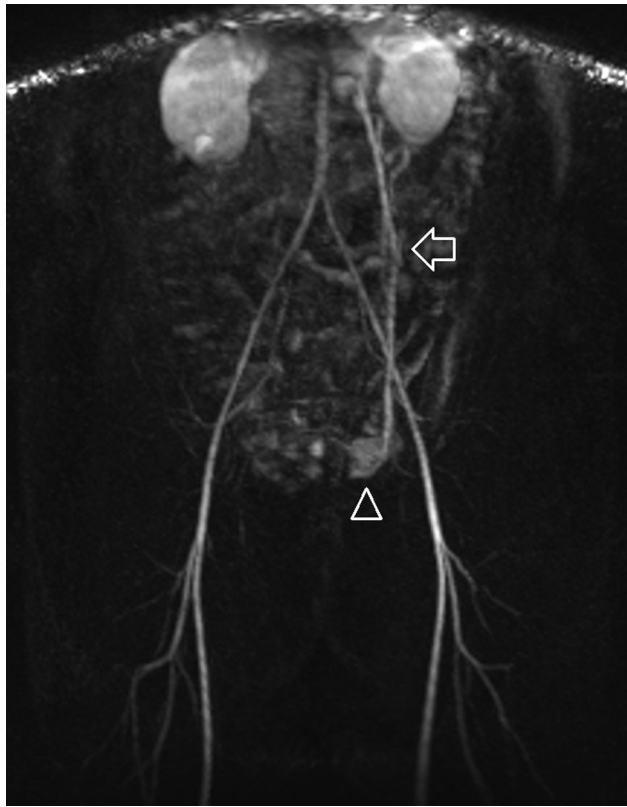


Fig. 2 Arterial phase image on time-resolved MR angiography demonstrates retrograde flow in an enlarged left ovarian vein (arrow) and opacification of prominent paraovarian varices (arrowhead).

SVP classification consensus document as multiple tortuous dilated veins around the uterus or ovaries measuring ≥ 5 mm in diameter.⁴

Treatment and Complications

Prior to the development of endovascular therapies, the first-line treatment for PeVD was medical management by decreasing levels of estrogen with either medroxyprogesterone or GnRH agonists.^{24,25} These medications provided marginal symptomatic benefit with an unfavorable side effect profile (including weight changes, decreased bone density, menstrual irregularities, and menopausal symptoms) precluding them from long-term use.²⁴ Surgical options for pelvic venous insufficiency have evolved over the years. Traditional surgical management was hysterectomy with or without oophorectomy. Open extraperitoneal ovarian vein resection was described in the 1980s with symptomatic improvement reported in 73% of patients.²⁶ By the next decade, laparoscopic ovarian vein ligation was the standard of care for definitive surgical management, with a small study in 2003 reporting promising results of complete resolution of symptoms at 1 year in all 23 patients.²⁷ Despite encouraging results, complications included retroperitoneal hematoma, DVT, ureteral injury, and adhesive disease. Transcatheter interventions (**→Figs. 4–6**) have largely replaced open and laparoscopic ovarian vein ligation due to their invasiveness and potential complications, with the caveat that ovarian

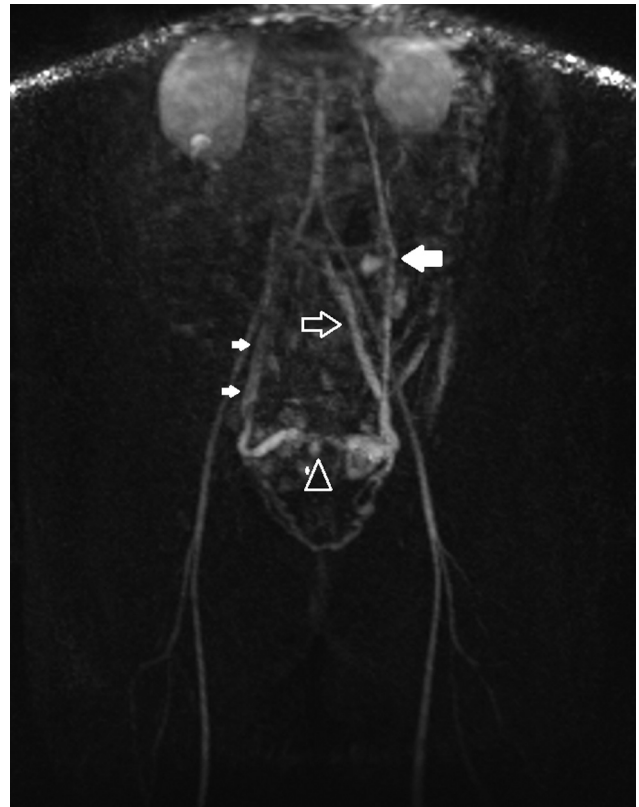


Fig. 3 Venous phase image on time-resolved MR angiography demonstrates a dilated left ovarian vein (large solid arrow) with numerous bilateral utero-ovarian varices, cross pelvic collaterals (arrowhead), and outflow via the left internal iliac (open arrow) and right ovarian veins (small solid arrows), which demonstrate normal antegrade flow.

vein transposition can be performed in the setting of combined CPP and renal symptoms of venous origin ($S_{1,2}$) or isolated renal symptoms of venous origin (S_1).²⁸

The availability of evidence-based guidelines and the ability to study patient outcomes for treatments and the natural history of PeVD are hindered by the lack of a standardized evaluative tool for monitoring disease progression and improvement. To date, all studies assessing treatment outcomes in PeVD utilize nonstandard patient questionnaires or visual analog scale (VAS) pain scores, which are unidimensional and do not fully capture the burden of disease or impact of treatment on patients' QoL. Fortunately, a QoL assessment tool is currently being developed by a similar multidisciplinary panel responsible for the new SVP classification. Ovarian vein embolization has been shown to have high rates of technical and clinical success for the treatment of CPP secondary to pelvic venous insufficiency in multiple small retrospective studies, and though randomized controlled trials for endovascular therapies are lacking, they are in development. The most recent practice guidelines by the Society for Vascular Surgery and the American Venous Forum are from 2011, which recommend mechanical embolization (coils or plugs) and/or transcatheter sclerotherapy for the treatment of symptomatic PeVD based on level 2B evidence.²⁹ Transcatheter techniques vary considerably based on local practice patterns, operator

Table 2 Imaging protocols optimized for evaluating pelvic venous insufficiency and imaging findings suggestive of PeVD across different modalities^{10,22,45–50}

Modality	Protocol/Findings	Pros/Cons
US	<p>Transabdominal:</p> <ul style="list-style-type: none"> Assess IVC, left renal vein, CIVs, EIVs, IIVs, ovarian veins, periuterine veins, and tributaries of the IIVs with color, greyscale, and spectral Doppler low-frequency curvilinear probe Patient fasting Supine + reclined 30–45 degrees Assess size of vessels, direction of flow, and spontaneous reflux +/- provocative maneuvers (Valsalva, manual compression of left iliac fossa) Transvaginal (Holdstock-Harrison protocol): Assess labial, ovarian, and IIVs for reflux > 1 s, dilation with Valsalva Presence of pelvic varicosities (sensitivity 100% and specificity 83–100%)²² Cross pelvic collaterals >5 mm in diameter Assess morphologic appearance of uterus and ovaries to look for other causes of CPP Some contend TV US should be the gold standard for diagnosing pelvic venous insufficiency⁴⁹ 	<p>Pros:</p> <ul style="list-style-type: none"> Dynamic imaging Can be performed in different positions Lack of ionizing radiation Relatively low cost, accessible <p>Cons:</p> <ul style="list-style-type: none"> Technologist dependent Limited by body habitus Deep abdominopelvic veins are difficult to visualize sonographically Must be specifically ordered, vascular imaging is not a component of the standard TA/TV pelvic US
CT	<ul style="list-style-type: none"> Somewhat limited in the evaluation of pelvic venous congestion, however, may be obtained for other reasons CT abdomen/pelvis obtained for the evaluation of pelvic venous congestion should image abdomen through thighs to capture LE varicosities <ul style="list-style-type: none"> Deep breath hold (Valsalva) 2 phase exam <ul style="list-style-type: none"> (20–30 s) arterial–corticomedullary phase to visualize reflux into left ovarian vein (65–95 s) venous delayed phase demonstrating enlarged ovarian veins and pelvic varices Assess for nutcracker phenomenon (aortomesenteric angle of <39 degrees), May–Thurner anatomy Look for other causes of venous obstruction (pelvic or retroperitoneal mass, lymphadenopathy, retroperitoneal fibrosis, AAA, etc.) 	<p>Pro:</p> <ul style="list-style-type: none"> Exclude other causes of venous obstruction/insufficiency Option for patients with limited ultrasound exam or cannot have an MRI <p>Con:</p> <ul style="list-style-type: none"> Supine positioning Lower sensitivity than MRI/MRV Ionizing radiation
MRI/MRA/MRV	<ul style="list-style-type: none"> Image abdomen through thighs to capture LE varicosities Protocol optimized for dynamic vascular imaging as well as pelvic soft tissues High temporal-resolution time-resolved MR angiography <ul style="list-style-type: none"> Look for retrograde (caudal) flow in ovarian vein and filling of pelvic varicosities Multiplanar T2 and T1 pre- and post-contrast <ul style="list-style-type: none"> Look for other potential causes of CPP and morphologic findings of PeVD Heterogeneous or T2-hyperintensity of ovarian vein due to slow flow Grading system has been described in the literature based on time-resolved imaging, but is beyond the scope of this article 	<p>Pros:</p> <ul style="list-style-type: none"> Very sensitive for pelvic varices Dynamic imaging Excellent soft-tissue evaluation makes it very sensitive for nonvascular pelvic pathology, so can exclude other causes of CPP <p>Cons:</p> <ul style="list-style-type: none"> Costly Supine positioning

(Continued)

Table 2 (Continued)

Modality	Protocol/Findings	Pros/Cons
Venography	<ul style="list-style-type: none"> • Dilated ovarian, uterine, and utero-ovarian arcade veins to at least 5 mm (with the caveat that diameter measurements do not preclude treatment if constellation of findings and symptoms suggest PeVD) • Free reflux in the ovarian vein with valvular incompetence • Contralateral reflux of contrast across midline • Opacification of vulvar or thigh varices • Stagnation of contrast medium in pelvic veins • Pressure measurements +/- IVUS if suspected compression 	<p>Pros:</p> <ul style="list-style-type: none"> • Considered gold standard • Dynamic imaging • Can obtain simultaneous pressure measurements and IVUS <p>Cons:</p> <ul style="list-style-type: none"> • Ionizing radiation • Invasive

Abbreviations: AAA, abdominal aortic aneurysm; CIV, common iliac vein; CPP, chronic pelvic pain; CT, computed tomography; EIV, external iliac vein; IIV, internal iliac vein; IVC, inferior vena cava; IVUS, intravascular ultrasound; LE, lower extremity; MRA, magnetic resonance angiography; MRI, magnetic resonance imaging; MRV, magnetic resonance venography; PeVD, pelvic venous disorders; TA, transabdominal; TV, transvaginal; US, ultrasound.

preference and experience, and inventory availability. A 2022 systematic review and meta-analysis of embolization for the treatment of symptomatic pelvic venous insufficiency that included 1,426 patients across 19 studies found significant variability in embolization technique: 76.5% used a combination of coils and vascular plugs, 4% used liquid embolics alone, and 19.4% used a combination of mechanical and liquid embolics.³⁰ Interestingly, technical success was reported to be between 96 and 100% despite the variability in technique. Furthermore, in subanalysis of pre- and post-intervention VAS pain scores, there was improvement in dyspareunia, dysuria, and dysmenorrhea in 79.8, 77.3, and 46.7% of patients, respectively.³⁰ In two recent prospective studies evaluating the efficacy of different endovascular therapies (fibered coils vs. endovascular plugs and Onyx combined with sclerotherapy), authors reported near 100% technical and clinical success in the range of 89.7–95.9% based on a threshold decrease in pre- and postprocedure VAS scores.^{31,32} In addition to significant heterogeneity in endovascular techniques in the PeVD literature, there is also significant heterogeneity in the targeted territory of embolization: bilateral ovarian veins, isolated left ovarian vein, bilateral ovarian and internal iliac veins, and internal iliac vein embolization combined with left or bilateral ovarian vein embolization in the setting of internal iliac vein reflux on venography have all been described.^{30–42} Interestingly, there is no statistically significant difference in clinical outcomes reported between bilateral ovarian vein and isolated left ovarian vein embolization in the setting of bilateral versus left ovarian vein reflux on venography, respectively.^{38,43} Commonly described endovascular approaches include mechanical embolization with coils and vascular plugs, liquid embolics (n-butyl cyanoacrylate and Onyx), sclerotherapy, absorbable gelatin sponge, and various combinations of the aforementioned agents. Until further data emerge, the choice is operator dependent, as currently no single method has been shown to be superior with regard to technical or clinical success. Contraindications to gonadal vein embolization are the same as general venography and embolization: anaphylactic reaction

to contrast, pregnancy, active infection, renal insufficiency, and severe/uncontrollable coagulopathy.

Fortunately, endovascular therapies for the treatment of PeVD are generally low risk and complications are uncommon. Coil migration is the most common major complication (~2%), usually in the setting of internal iliac vein embolization.³⁰ Vessel perforation, hematoma, local thrombophlebitis, postembolization syndrome, contrast reaction, and symptom recurrence have also been reported, although less frequently.³⁰ Symptomatic recurrence is rarely reported; in a recent meta-analysis that included 19 studies and over 1,300 patients, recurrence rates were reported only in three studies, with a mean time to recurrence between 8.5 and 21 months.³⁰ Reported reintervention rates are low (5.25%) and of the reported reinterventions, the majority of them were performed in an untreated vascular territory.^{30,35} There are very limited published data on pregnancy after endovascular treatment of PeVD; however, the available information is promising. A small retrospective study of 12 patients with infertility attributed to pelvic venous insufficiency who were treated with ovarian vein embolization found that 8/12 (66.7%) patients became pregnant during the 24- to 36-month follow-up period.⁴⁴ Furthermore, no statistical difference in LH and FSH before and after embolization has been shown.^{37,44}

Conclusion

Pelvic venous insufficiency is an established cause of CPP with the diagnosis suggested on noninvasive imaging modalities, though the gold standard remains catheter venography. Endovascular treatment with ovarian vein embolization has been shown to be safe and effective, though large-scale clinical trials are needed and in development to ensure that patients continue to have access to this option.

Conflict of Interest

None declared.

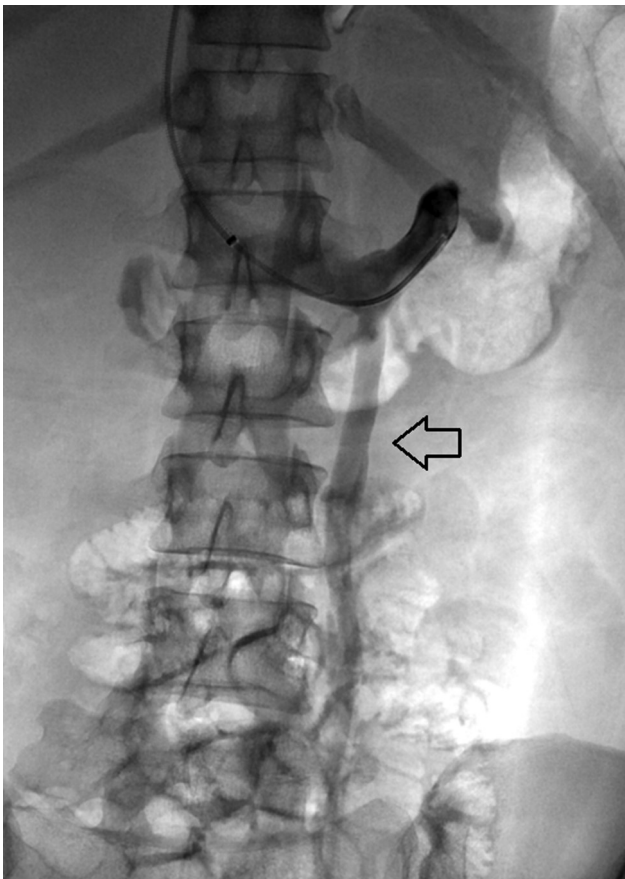


Fig. 4 Catheter venography with injection from the left renal hilum demonstrates reflux into the dilated left ovarian vein (arrow) consistent with venous incompetence.

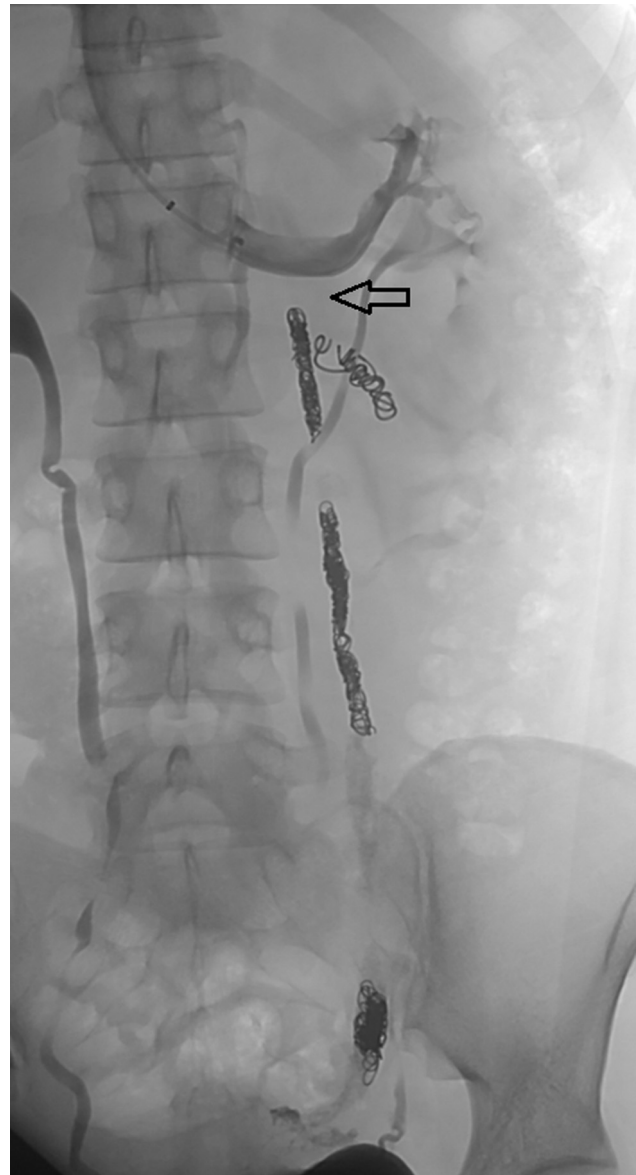


Fig. 6 Postembolization venography from the left renal hilum demonstrates complete occlusion of the left ovarian vein (arrow).

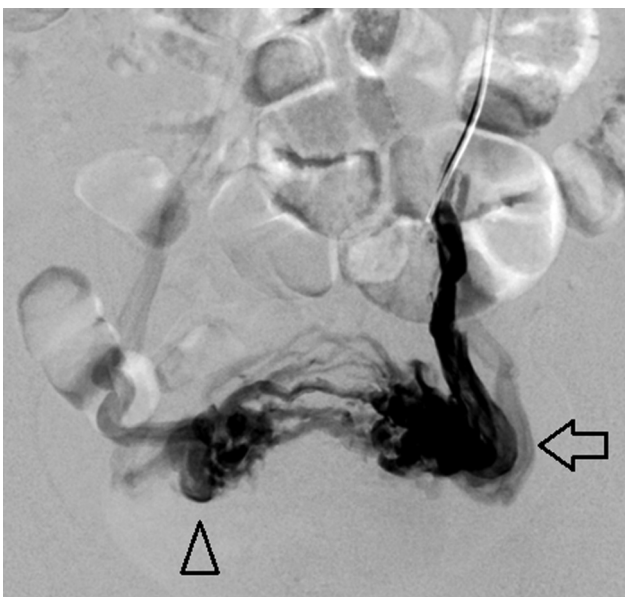

Fig. 5 Digital subtraction angiography from the peripheral left ovarian vein demonstrates numerous left utero-ovarian varicosities (arrow) and cross pelvic collaterals opacifying right utero-ovarian varicosities (arrowhead).

References

- 1 Chronic pelvic pain: ACOG Practice Bulletin, number 218. *Obstet Gynecol* 2020;135(03):e98–e109
- 2 Mathias SD, Kuppermann M, Liberman RF, Lipschutz RC, Steege JF. Chronic pelvic pain: prevalence, health-related quality of life, and economic correlates. *Obstet Gynecol* 1996;87(03):321–327
- 3 Ahangari A. Prevalence of chronic pelvic pain among women: an updated review. *Pain Physician* 2014;17(02):E141–E147
- 4 Lamvu G, Carrillo J, Ouyang C, Rapkin A. Chronic pelvic pain in women: a review. *JAMA* 2021;325(23):2381–2391
- 5 Merrill RM. Hysterectomy surveillance in the United States, 1997 through 2005. *Med Sci Monit* 2008;14(01):CR24–CR31
- 6 Howard FM. The role of laparoscopy in the evaluation of chronic pelvic pain: pitfalls with a negative laparoscopy. *J Am Assoc Gynecol Laparosc* 1996;4(01):85–94
- 7 Tirlapur SA, Daniels JP, Khan KS MEDAL Trial Collaboration. Chronic pelvic pain: how does noninvasive imaging compare with diagnostic laparoscopy? *Curr Opin Obstet Gynecol* 2015;27(06):445–448

- 8 Meissner MH, Khilnani NM, Labropoulos N, et al. The Symptoms-Varices-Pathophysiology classification of pelvic venous disorders: a report of the American Vein & Lymphatic Society International Working Group on Pelvic Venous Disorders. *J Vasc Surg Venous Lymphat Disord* 2021;9(03):568–584
- 9 Lurie F, Passman M, Meisner M, et al. The 2020 update of the CEAP classification system and reporting standards. *J Vasc Surg Venous Lymphat Disord* 2020;8(03):342–352
- 10 Topper SR, Winokur RS. Imaging of pelvic venous disorders (PeVD): Should every patient get an MRI? *Tech Vasc Interv Radiol* 2021;24(01):100731
- 11 Khilnani NM, Meissner MH, Learman LA, et al. Research priorities in pelvic venous disorders in women: recommendations from a multidisciplinary research consensus panel. *J Vasc Interv Radiol* 2019;30(06):781–789
- 12 Khilnani NM, Winokur RS, Scherer KL, Meissner MH. Clinical presentation and evaluation of pelvic venous disorders in women. *Tech Vasc Interv Radiol* 2021;24(01):100730
- 13 Maratto S, Khilnani NM, Winokur RS. Clinical Presentation, Patient Assessment, Anatomy, Pathophysiology, and Imaging of Pelvic Venous Disease. Thieme Medical Publishers, Inc.; 2021: 233–238
- 14 Ascitto G, Mumme A, Ascitto KC, Geier B. Oestradiol levels in varicose vein blood of patients with and without pelvic vein incompetence (PVI): diagnostic implications. *Eur J Vasc Endovasc Surg* 2010;40(01):117–121
- 15 Ignacio EA, Dua R, Sarin S, et al. Pelvic Congestion Syndrome: Diagnosis and Treatment. Thieme Medical Publishers; 2008: 361–368
- 16 Durham JD, Machan L. Pelvic Congestion Syndrome. Thieme Medical Publishers; 2013:372–380
- 17 Gibson K, Minjarez R, Ferris B, et al. Clinical presentation of women with pelvic source varicose veins in the perineum as a first step in the development of a disease-specific patient assessment tool. *J Vasc Surg Venous Lymphat Disord* 2017;5(04): 493–499
- 18 Ford RW, Winokur RS. Pelvic Venous Disorders (PeVD). Thieme Medical Publishers, Inc.; 2022:483–489
- 19 Herrera-Betancourt AL, Villegas-Echeverri JD, López-Jaramillo JD, López-Isanoa JD, Estrada-Alvarez JM. Sensitivity and specificity of clinical findings for the diagnosis of pelvic congestion syndrome in women with chronic pelvic pain. *Phlebology* 2018;33(05): 303–308
- 20 Beard RW, Highman JH, Pearce S, Reginald PW. Diagnosis of pelvic varicosities in women with chronic pelvic pain. *Lancet* 1984;2 (8409):946–949
- 21 Yang DM, Kim HC, Nam DH, Jahng GH, Huh CY, Lim JW. Time-resolved MR angiography for detecting and grading ovarian venous reflux: comparison with conventional venography. *Br J Radiol* 2012;85(1014):e117–e122
- 22 Steenbeek MP, van der Vleuten CJM, Schultze Kool LJ, Nieboer TE. Noninvasive diagnostic tools for pelvic congestion syndrome: a systematic review. *Acta Obstet Gynecol Scand* 2018;97(07): 776–786
- 23 Gavrilov S, Karalkin A, Mishakina N, Efremova O, Grishenkova A. Relationships of pelvic vein diameter and reflux with clinical manifestations of pelvic venous disorder. *Diagnostics (Basel)* 2022;12(01):145
- 24 Cheong YC, Smotra G, Williams AC. Non-surgical interventions for the management of chronic pelvic pain. *Cochrane Database Syst Rev* 2014;(03):CD008797
- 25 Soysal ME, Soysal S, Vicdan K, Ozer S. A randomized controlled trial of goserelin and medroxyprogesterone acetate in the treatment of pelvic congestion. *Hum Reprod* 2001;16(05):931–939
- 26 Rundqvist E, Sandholm LE, Larsson G. Treatment of pelvic varicosities causing lower abdominal pain with extraperitoneal resection of the left ovarian vein. *Ann Chir Gynaecol* 1984;73(06): 339–341
- 27 Gargiulo T, Mais V, Brokaj L, Cossu E, Melis GB. Bilateral laparoscopic transperitoneal ligation of ovarian veins for treatment of pelvic congestion syndrome. *J Am Assoc Gynecol Laparosc* 2003; 10(04):501–504
- 28 Gilmore BF, Benrashid E, Geersen D, Shortell CK. Gonadal vein transposition is a safe and effective treatment of nutcracker syndrome. *J Vasc Surg Venous Lymphat Disord* 2021;9(03): 712–719
- 29 Gloviczki P, Comerota AJ, Dalsing MC, et al; Society for Vascular Surgery American Venous Forum. The care of patients with varicose veins and associated chronic venous diseases: clinical practice guidelines of the Society for Vascular Surgery and the American Venous Forum. *J Vasc Surg* 2011;53(5, Suppl):2S–48S
- 30 de Carvalho SFC, Metzger PB, Fernandez MG, Ribeiro WB, Nogueira AKS, e Souza JPR. Pelvic venous reflux embolization in the treatment of symptomatic pelvic congestive syndrome: a systematic review with meta-analysis. *J Vasc Surg Venous Lymphat Disord* 2023;11(02):412–421
- 31 Guirola JA, Sánchez-Ballestín M, Sierre S, Lahuerta C, Mayoral V, De Gregorio MA. A randomized trial of endovascular embolization treatment in pelvic congestion syndrome: fibered platinum coils versus vascular plugs with 1-year clinical outcomes. *J Vasc Interv Radiol* 2018;29(01):45–53
- 32 Jambon E, Le Bras Y, Coussy A, et al. Embolization in pelvic venous disorders using ethylene vinyl alcohol copolymer (Onyx®) and Aetoxysclerol: a prospective evaluation of safety and long-term efficacy. *Eur Radiol* 2022;32(07):4679–4686
- 33 Mahmoud O, Vikatmaa P, Aho P, et al. Efficacy of endovascular treatment for pelvic congestion syndrome. *J Vasc Surg Venous Lymphat Disord* 2016;4(03):355–370
- 34 Daniels JP, Champaneria R, Shah L, Gupta JK, Birch J, Moss JG. Effectiveness of embolization or sclerotherapy of pelvic veins for reducing chronic pelvic pain: a systematic review. *J Vasc Interv Radiol* 2016;27(10):1478–1486.e8
- 35 Brown CL, Rizer M, Alexander R, Sharpe EE III, Rochon PJ. Pelvic Congestion Syndrome: Systematic Review of Treatment Success. Thieme Medical Publishers; 2018:035–040
- 36 Chen H, Wu Z, Wu Z, et al. Proximal coil occlusion preceding distal sclerotherapy in patients with pelvic congestion syndrome: a multi-center retrospective study. *J Vasc Surg Venous Lymphat Disord* 2022
- 37 Kim HS, Malhotra AD, Rowe PC, Lee JM, Venbrux AC. Embolotherapy for pelvic congestion syndrome: long-term results. *J Vasc Interv Radiol* 2006;17(2, Pt 1):289–297
- 38 Maleux G, Stockx L, Wilms G, Marchal G. Ovarian vein embolization for the treatment of pelvic congestion syndrome: long-term technical and clinical results. *J Vasc Interv Radiol* 2000;11(07): 859–864
- 39 Meissner MH, Gibson K. Clinical outcome after treatment of pelvic congestion syndrome: sense and nonsense. *Phlebology* 2015;30 (1, Suppl):73–80
- 40 Nasser F, Cavalcante RN, Affonso BB, Messina ML, Carnevale FC, de Gregorio MA. Safety, efficacy, and prognostic factors in endovascular treatment of pelvic congestion syndrome. *Int J Gynaecol Obstet* 2014;125(01):65–68
- 41 Laborda A, Medrano J, de Blas I, Urriaga I, Carnevale FC, de Gregorio MA. Endovascular treatment of pelvic congestion syndrome: visual analog scale (VAS) long-term follow-up clinical evaluation in 202 patients. *Cardiovasc Intervent Radiol* 2013;36 (04):1006–1014
- 42 Chung M-H, Huh C-Y. Comparison of treatments for pelvic congestion syndrome. *Tohoku J Exp Med* 2003;201(03):131–138
- 43 Meneses L, Fava M, Diaz P, et al. Embolization of incompetent pelvic veins for the treatment of recurrent varicose veins in lower limbs and pelvic congestion syndrome. *Cardiovasc Intervent Radiol* 2013;36(01):128–132
- 44 Liu J, Han L, Han X. The effect of a subsequent pregnancy after ovarian vein embolization in patients with infertility caused by

- pelvic congestion syndrome. *Acad Radiol* 2019;26(10):1373–1377
- 45 Bookwalter CA, VanBuren WM, Neisen MJ, Bjarnason H. Imaging appearance and nonsurgical management of pelvic venous congestion syndrome. *Radiographics* 2019;39(02):596–608
- 46 Cura M, Cura A. What is the significance of ovarian vein reflux detected by computed tomography in patients with pelvic pain? *Clin Imaging* 2009;33(04):306–310
- 47 Labropoulos N, Jasinski PT, Adrahtas D, Gasparis AP, Meissner MH. A standardized ultrasound approach to pelvic congestion syndrome. *Phlebology* 2017;32(09):608–619
- 48 Dos Santos SJ, Holdstock JM, Harrison CC, Lopez AJ, Whiteley MS. Ovarian vein diameter cannot be used as an indicator of ovarian venous reflux. *Eur J Vasc Endovasc Surg* 2015;49(01):90–94
- 49 Whiteley MS, Dos Santos SJ, Harrison CC, Holdstock JM, Lopez AJ. Transvaginal duplex ultrasonography appears to be the gold standard investigation for the haemodynamic evaluation of pelvic venous reflux in the ovarian and internal iliac veins in women. *Phlebology* 2015;30(10):706–713
- 50 Black CM, Thorpe K, Venrbux A, et al. Research reporting standards for endovascular treatment of pelvic venous insufficiency. *J Vasc Interv Radiol* 2010;21(06):796–803