

Recanalization of Proximal Fallopian Tube Obstruction in the Treatment of Infertility

Priya Mody, MD¹ Gloria Salazar, MD, FSIR¹ Maureen P. Kohi, MD, FSIR, FAHA¹

¹Department of Radiology, University of North Carolina at Chapel Hill, Chapel Hill, North Carolina

Address for correspondence Priya Mody, MD, Department of Radiology, University of North Carolina at Chapel Hill, 101 Manning Drive, Campus Box 7510, Chapel Hill, NC 27599-7510 (e-mail: priya_mody@med.unc.edu).

Semin Intervent Radiol 2023;40:379–383

Abstract

Infertility affects approximately 15% of patients worldwide, with up to 40% of cases attributed to tubal disease, and up to 25% of those being proximal fallopian tube obstruction (FTO). Evaluation of tubal patency can be performed via laparoscopic chromopertubation, hysterosalpingography, or hysterosalpingo-contrast-sonography (HyCoSy). In patients with proximal tubal obstruction, fallopian tube recanalization (FTR) can result in up to 100% technical success rate with pregnancy rates of 12.8 to 51%. More pregnancies occur when oil-soluble contrast media are used versus water-soluble contrast media. Complications of FTR are rare and include tubal perforation, ectopic pregnancy, and pelvic infection. Reocclusion of fallopian tubes may occur in 20 to 50% of patients; however, FTR may be repeated in these cases. Overall, FTR is underutilized in the treatment of infertility secondary to proximal FTO and it can obviate costly and time-consuming assistive reproductive techniques such as in vitro fertilization in some patients, as well as decreasing physical and emotional stress.

Keywords

- ▶ fallopian tube occlusion
- ▶ recanalization
- ▶ tubal infertility
- ▶ women's health
- ▶ interventional radiology

Infertility is diagnosed when a biological female fails to become pregnant after 12 months of regular unprotected sexual intercourse (if younger than 35 years) or after 6 months (if aged 35 and above).¹ Primary infertility occurs in patients who have never had a documented pregnancy, while secondary infertility occurs in patients who have previously had an established pregnancy, regardless of the outcome.² Etiologies include uterine, tubal, ovarian, genetic, posttreatment, and systemic pathologies.³ Current estimates regarding the prevalence of infertility range from 7 to 15% but it is likely higher.⁴ Identifying and resolving treatable causes of infertility can save the patient time, emotional and physical stress, and financial strain.

Tubal pathology accounts for up to 40% of cases of female infertility,⁵ with proximal fallopian tube obstruction (FTO) in 10 to 25% cases.⁶ The proximal fallopian tube or isthmus is very narrow in caliber, measuring approximately 1 mm in width, and is easily subject to total luminal occlusion as a result of mucus, debris, or other pathologies.⁷ The most common underlying pathology for proximal FTO is pelvic inflammatory disease (PID) secondary to genital tract infections such as *Neisseria gonorrhoea* or *Chlamydia trachomatis*.⁵

The risk of infertility increases with the number and severity of infections.⁸ Other causes include uterotubal spasm, mucous plugging/debris, endometriosis, lower abdominal infection/inflammation (e.g., secondary to inflammatory bowel disease), postsurgical scarring and adhesions, prior pelvic radiation, and pelvic tuberculosis.⁵

Diagnosing Fallopian Tube Obstruction

A thorough history and physical exam is the first step in evaluating infertility. The patient may have a known history of prior sexually transmitted genital infection, inflammatory bowel disease, or prior pelvic radiation, which can contribute to tubal infertility.⁵ Some underlying endocrine conditions can manifest physically with hirsutism, acne, or thyromegaly and can be associated with infertility, but may not necessarily be associated with an FTO.⁵

The gold standard for the diagnosis of FTO is laparoscopy with chromopertubation.⁹ Colored fluid (dilute methylene blue, toluidine blue dye, indigo carmine, etc.) is instilled into the uterus via a balloon catheter and the physician directly examines the abdominal cavity for staining of the tubes and

spillage into the peritoneal cavity, indicating patency.^{3,10} Laparoscopy also allows for evaluation of anatomic abnormalities such as hydrosalpinx or tubal tortuosity, adhesive disease, and endometriosis.⁸ Disadvantages of this procedure include invasiveness, need for anesthesia, cost, and potential for subsequent development of new adhesions (which can further worsen secondary infertility).^{8,9}

Hysterosalpingography (HSG) is a minimally invasive option and commonly performed as part of the infertility workup. The procedure entails instillation of radiopaque contrast into the uterus via a balloon occlusion catheter and evaluating for peritoneal spillage under fluoroscopy.^{11,12} The benefit of HSG is that recanalization may be performed concurrently if a proximal FTO is identified. Additionally, it can demonstrate other abnormalities that contribute to infertility such as submucosal uterine fibroids, Müllerian anomalies, and mucosal irregularities.¹³ The main downside is radiation to the pelvis and gonadal structures; however, with appropriate dose-reduction techniques, absorbed dose should be minimal.¹⁴

Hysterosalpingo-contrast-sonography (HyCoSy), also referred to as sonohysterography (SHG), is an alternative to HSG and does not require radiation exposure to the patient.¹⁵ Initial transvaginal ultrasound is performed to evaluate for hydrosalpinx or other gross abnormalities.⁹ Contrast is instilled into the uterine cavity via a balloon occlusion catheter under sonographic visualization, allowing assessment of the endometrial cavity.¹⁵ Common contrast agents include sterile saline, mixed air-saline, and ultrasound contrast media such as Echovist (Schering AG, Berlin).¹⁶ If at least one fallopian tube is patent, spilled contrast will be seen in the posterior cul-de-sac.³ The disadvantage of this procedure is that it is difficult to delineate laterality in cases of unilateral FTO unless other imaging abnormalities are present (e.g., hydrosalpinx). Additionally, visualization may be difficult depending on the location and contents of adjacent bowel.

Fallopian Tube Recanalization: Indications and Contraindications

Fallopian tube recanalization (FTR) is indicated in patients with proximal FTO. Distal occlusions of the tube are often related to pelvic adhesions or sequelae of PID and are more appropriately treated by laparoscopy and tubal surgery.¹⁷ FTR should not be performed in the setting of active pelvic infection, pregnancy, uncontrolled uterine or vaginal bleeding, recent tubal or uterine surgery, or patients with significant cardiac or renal dysfunction.¹² Allergy to contrast media is a relative contraindication, and oil-soluble contrast media should not be used in patients with uncontrolled thyroid disease (due to risk of transient hypothyroidism) or who are breastfeeding (due to risk of neonatal hypothyroidism).³

Fallopian Tube Recanalization Technique

Preprocedure

The optimal timing for recanalization is during the proliferative phase of the menstrual cycle, prior to ovulation; this is approximately at days 5 to 11 of the cycle.³ During this

period, the endometrium is thin, providing better visualization of the contour.¹² The physician obtains informed consent and confirms the patient has a negative urine pregnancy test on the day of procedure.

Antibiotic prophylaxis is not routinely recommended but should be administered in patients with a history of PID or if the tubes are noted to be dilated at the time of procedure as there is a small (1.5–3.5%) risk of developing postprocedural PID.¹⁸ A 5-day course of doxycycline 100 mg BID can be started 2 days before the procedure if these circumstances are known prior to FTR.^{19,20} Alternatively, a single dose of doxycycline given preprocedurally has also been shown to reduce the risk of infection.¹⁸ Moderate sedation is administered at the discretion of the operator and may help reduce uterotubal spasm.¹

Procedural Technique

There are four steps to recanalization—uterine access, HSG, recanalization, and salpingography (→Fig. 1).²¹ Once in the procedural suite, the patient should be placed on the fluoroscopy table in lithotomy position. Following preparation of the external genitalia and maximal sterile draping, the operator inserts a sterile speculum into the vagina. Warming the speculum can improve patient comfort and reduce uterotubal spasm; using a device with an attached light may help visibility for the operator. Adequate visualization is necessary to successfully cannulate the cervix. In cases of challenging cervical cannulation, pressure on the speculum or utilization of a tenaculum to affix the cervix may be necessary.^{11,21} The cervix is then prepped with Betadine.

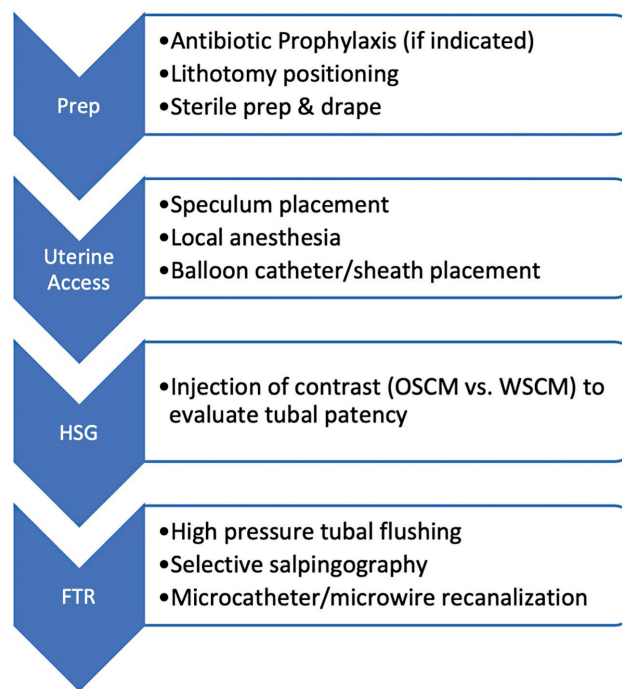


Fig. 1 Basic steps for simultaneous assessment of tubal patency and fallopian tube recanalization. OSCM, oil-soluble contrast medium; WSCM, water-soluble contrast medium; HSG, hysterosalpingography; FTR, fallopian tube recanalization.

Local anesthesia can be injected or topically applied to the cervix at the discretion of the operator.¹¹

A balloon occlusion catheter or sheath is placed through the cervix into the uterine cavity and the balloon is inflated. Dilute contrast is then slowly injected through the catheter under fluoroscopy to perform an HSG. Gentle injection is recommended to prevent uterotubal spasm and to ensure the tubes are not overdistended if there is hydrosalpinx.⁷ Possible findings include patent tubes with peritoneal contrast spillage, or obstruction of one or both tubes either proximally or distally.

If a proximal FTO is observed (►Fig. 2), selective catheterization of the culprit tubal ostium is performed.²² This is achieved by placement of an angled or curved diagnostic catheter through the balloon catheter or balloon-tip introducer sheath with the assistance of a hydrophilic guidewire (typically 0.038-in diameter; ►Fig. 3).⁷ In difficult cases, a microcatheter (3 Fr) and 0.018-in guidewire may be required to traverse the occlusion. The Rösch-Thurmond Fallopian Tube Catheterization set is available from Cook Medical (Cook Inc, Bloomington, IL) and contains all needed materials, except for the 9-Fr intrauterine access balloon catheter (Cook Inc), which is available separately (►Fig. 4). After recanalization, salpingography is performed to confirm tubal patency (►Fig. 5). While FTR can be performed alone after prior diagnosis of proximal FTO with HSG, performing the HSG at the same time can decrease the overall radiation to the patient.¹

Though recanalization can be attempted for distal FTO, these tend to be less technically successful either due to hydrosalpinx or adhesions.²³

Oil-Soluble versus Water-Soluble Contrast Media

A large prospective randomized controlled trial demonstrated a higher rate of post-HSG pregnancy and live births following HSG with oil-soluble contrast media such as lipiodol (Guerbet, France) compared to water-soluble contrast media and therefore oil-soluble contrast should be used in infertile women with low risk for tubal pathology.²⁴ The mechanism is not clearly established, but proposed mechanisms include increased hydrostatic pressure due to higher viscosity, resulting in clearing of mucous and debris from the tube.²⁵ Oil-soluble contrast media have several disadvantages, including a higher rate of intravasation with a small potential for oil embolization and poor visualization due to high density of the fluid.²⁵ Oil-soluble contrast media are also more costly than water-soluble contrast media, though still lower than the cost of in vitro fertilization.²⁴

Postprocedural Management

Following recanalization, patients are briefly monitored if they have received sedation and can be discharged with nonsteroidal anti-inflammatory medications. Patients can expect a small amount of postprocedural discharge, spotting, and mild cramping for 1 to 2 days postprocedure.²¹ Sexual intercourse can be resumed as soon as the patient has recovered from the procedure.

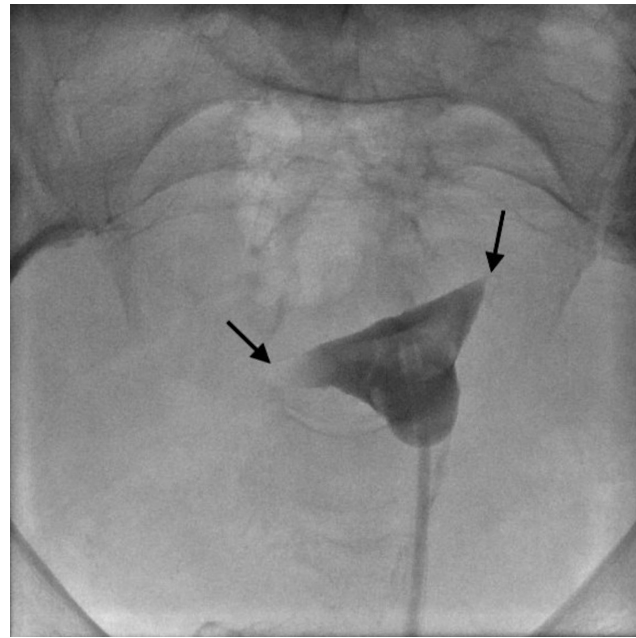


Fig. 2 Hysterosalpingography demonstrating bilateral proximal tubal occlusion (arrows).

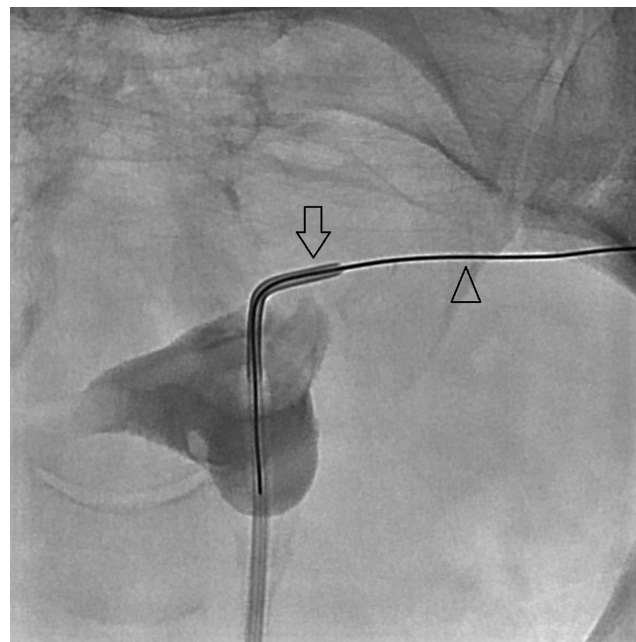


Fig. 3 Selective catheterization of the left tubal ostium with a 5-Fr angled catheter (arrow) and passage of a 0.035-in hydrophilic guidewire (arrowhead) through the left fallopian tube.

Fallopian Tube Recanalization Outcomes

Technical success of FTR can range up to 100%.²⁶ Post-FTR pregnancy rates are reported ranging from 12.8 to 51% in the literature, averaging around 33%.^{27,28} Successful conception is more likely in patients who require less intervention, that is, can be recanalized with high-pressure contrast injection alone versus those who require microcatheter/microwire

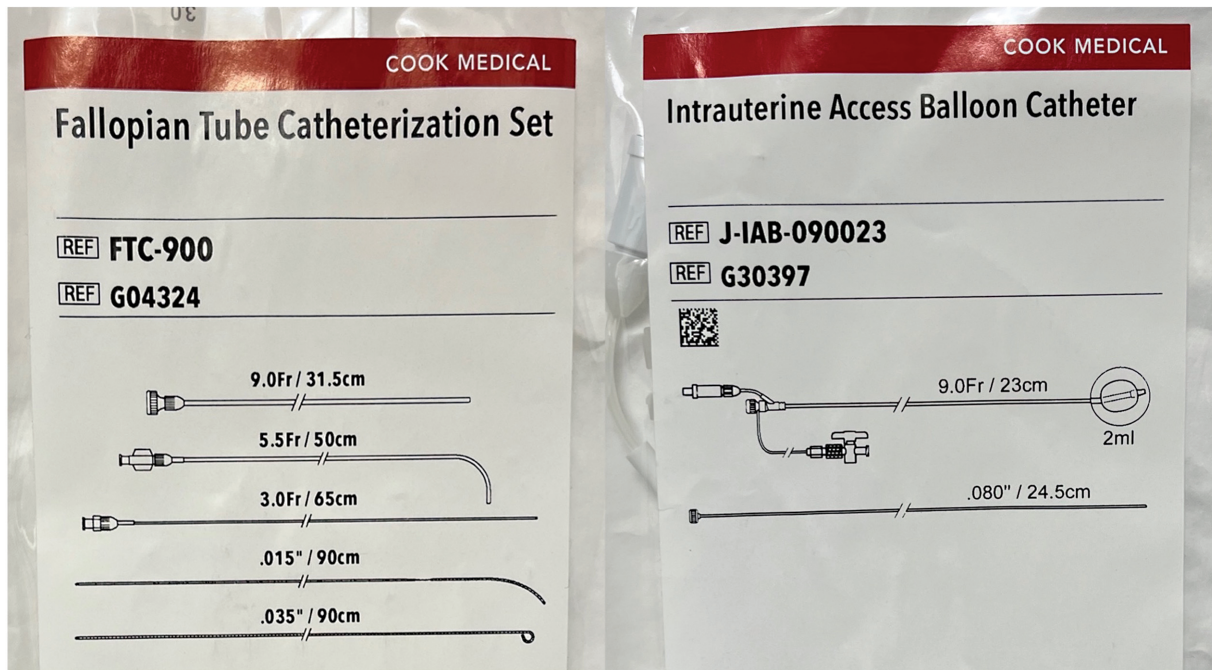


Fig. 4 Fallopian tube catheterization kit and intrauterine access balloon catheter from Cook Medical (Cook Inc., Bloomington, IL).

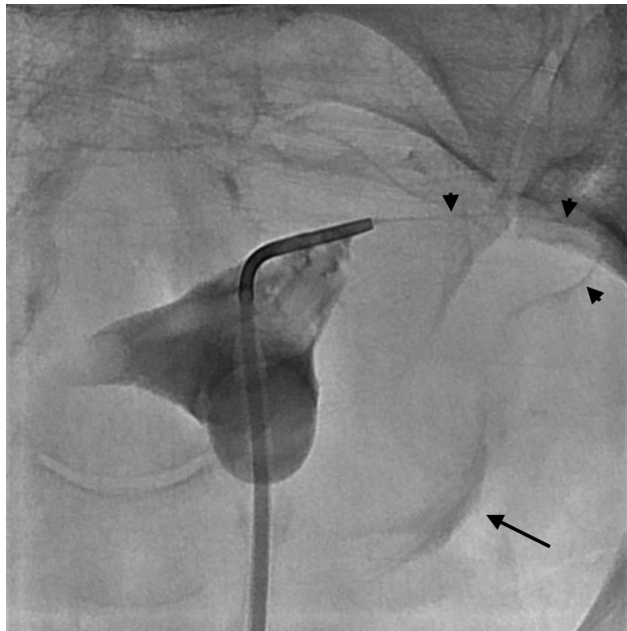


Fig. 5 Post-fallopian tube recanalization salpingography demonstrating contrast in the left fallopian tube (arrowheads) with intraperitoneal spillage (arrow).

manipulation to recanalize the tube.⁶ The recognition that tubal flushing improves pregnancy rates in women undergoing oil-soluble contrast media as compared to no-intervention was initially documented in a Cochrane review, and these findings were later confirmed in a randomized controlled trial comparing water-based and oil-based contrast during HSG for women with infertility, with short- and long-term follow-up data.²⁴

Time to conception is not frequently discussed in the literature and can be variable as FTO may not be the sole

cause of infertility in most patients. These patients may require additional reproductive assistance (in vitro fertilization, intrauterine insemination, ovulatory stimulation, etc.) and successfully conceive later.¹⁷ One study of 72 patients mentions an average time to conception of 16.2 months.²⁹ Time to conception has been shown to be lower in patients who had FTR performed with oil-soluble contrast media.²⁵

Complications are overall rare after FTR and may include tubal perforation (2%), tubal ectopic pregnancy (3%), and pelvic infection/PID (1%).¹¹ Reocclusion rates following FTR range from 20 to 50% at 6 months after recanalization.⁷ Recanalization can be repeated multiple times if necessary; however, there is an increased risk for tubal perforation.⁶ A retrospective analysis by Shen et al establishes risk factors for tubal ectopic pregnancy after FTR, including age 35 years or older, secondary infertility, 5 or more years of duration of infertility, history of ectopic pregnancy, history of abdominal surgery, and prior D&C.²⁸ A study of radiation dose during FTR reported an average procedural fluoroscopy time of 8.5 minutes with average radiation exposure less than 1 rad (10 mGy),¹⁴ well below threshold for causing significant deterministic effects.

Conclusion

Fallopian tube recanalization has been utilized as an adjunct treatment of infertility for over 30 years; yet, its utilization depends on patient referrals and access to subspecialized IR care.³⁰ However, given the procedure is low in cost and invasiveness and has a high technical success rate, FTR should be offered to infertile patients with proximal FTO, regardless of whether they subsequently require additional reproductive assistance to conceive.

Conflict of Interest

The authors have no financial conflicts of interest to disclose.

References

- 1 Roberts A. Fallopian tube recanalization for the management of infertility. *CVIR Endovasc* 2023;6(01):13
- 2 Vander Borgh M, Wyns C. Fertility and infertility: definition and epidemiology. *Clin Biochem* 2018;62:2–10
- 3 Grigovich M, Kacharia VS, Bharwani N, Hemingway A, Mijatovic V, Rodgers SK. Evaluating fallopian tube patency: what the radiologist needs to know. *Radiographics* 2021;41(06):1876–18961
- 4 Thoma ME, McLain AC, Louis JF, et al. Prevalence of infertility in the United States as estimated by the current duration approach and a traditional constructed approach. *Fertil Steril* 2013;99(05):1324–1331.e1
- 5 Dun EC, Nezhat CH. Tubal factor infertility: diagnosis and management in the era of assisted reproductive technology. *Obstet Gynecol Clin North Am* 2012;39(04):551–566
- 6 Allahbadia GN, Merchant R. Fallopian tube recanalization: lessons learnt and future challenges. *Womens Health (Lond Engl)* 2010;6(04):531–548, quiz 548–549
- 7 Thurmond AS. Fallopian tube catheterization. *Semin Intervent Radiol* 2008;25(04):425–431
- 8 Ambildhuke K, Pajai S, Chimegave A, Mundhada R, Kabra P. A review of tubal factors affecting fertility and its management. *Cureus* 2022;14(11):e30990
- 9 Watrelot A, Hamilton J, Grudzinskas JG. Advances in the assessment of the uterus and fallopian tube function. *Best Pract Res Clin Obstet Gynaecol* 2003;17(02):187–209
- 10 Carson SA, Kallen AN. Diagnosis and management of infertility. *JAMA* 2021;326(01):65–76
- 11 Thurmond AS, Machan LS, Maubon AJ, et al. A review of selective salpingography and fallopian tube catheterization. *Radiographics* 2000;20(06):1759–1768
- 12 Chalazitis A, Tzovara I, Laspas F, Porfyridis P, Ptohis N, Tsimitelis G. Hysterosalpingography: technique and applications. *Curr Probl Diagn Radiol* 2009;38(05):199–205
- 13 Schankath AC, Fasching N, Urech-Ruh C, Hohl MK, Kubik-Huch RA. Hysterosalpingography in the workup of female infertility: indications, technique and diagnostic findings. *Insights Imaging* 2012;3(05):475–483
- 14 Hedgpeth PL, Thurmond AS, Fry R, Schmidgall JR, Rösch J. Radiographic fallopian tube recanalization: absorbed ovarian radiation dose. *Radiology* 1991;180(01):121–122
- 15 Cullinan JA, Fleischer AC, Kepple DM, Arnold AL. Sonohysterography: a technique for endometrial evaluation. *Radiographics* 1995;15(03):501–514, discussion 515–516
- 16 Saunders RD, Shwayder JM, Nakajima ST. Current methods of tubal patency assessment. *Fertil Steril* 2011;95(07):2171–2179
- 17 Marlow JA, Picus D, Gould J, Connolly S, Mani NB. Outcomes after successful fallopian tube recanalization: a single institution experience: observational retrospective study. *Clin Imaging* 2021;76:70–73
- 18 Van Eyk N, van Schalkwyk J. No. 275 - Antibiotic prophylaxis in gynaecologic procedures. *J Obstet Gynaecol Can* 2018;40(10):e723–e733
- 19 Pereira N, Hutchinson AP, Lekovich JP, Hobeika E, Elias RT. Antibiotic prophylaxis for gynecologic procedures prior to and during the utilization of assisted reproductive technologies: a systematic review. *J Pathogens* 2016;2016:4698314
- 20 Prevention of infection after gynecologic procedures. *Obstet Gynecol* 2018;131(06):
- 21 Kohi MP. Interventional radiologist's approach to fallopian tube recanalization. *Tech Vasc Interv Radiol* 2021;24(01):100736
- 22 Velling TE, Brennan FJ, Hall LD, Watabe JT. Role of the interventional radiologist in treating obstetric-gynecologic pathology. *AJR Am J Roentgenol* 2000;175(05):1273–1278
- 23 Maubon A, Rouanet JP, Cover S, Courtieu C, Mares P. Fallopian tube recanalization by selective salpingography: an alternative to more invasive techniques? *Hum Reprod* 1992;7(10):1425–1428
- 24 van Rijswijk J, Pham CT, Dreyer K, et al. Oil-based or water-based contrast for hysterosalpingography in infertile women: a cost-effectiveness analysis of a randomized controlled trial. *Fertil Steril* 2018;110(04):754–760
- 25 Pinto ABM, Hovsepian DM, Wattanakumtornkul S, Pilgram TK. Pregnancy outcomes after fallopian tube recanalization: oil-based versus water-soluble contrast agents. *J Vasc Interv Radiol* 2003;14(01):69–74
- 26 Al-Omari MH, Obeidat N, Elheis M, Khasawneh RA, Gharaibeh MM. Factors affecting pregnancy rate following fallopian tube recanalization in women with proximal fallopian tube obstruction. *J Clin Med* 2018;7(05):110
- 27 Wang JW, Rustia GM, Wood-Molo M, et al. Conception rates after fluoroscopy-guided fallopian tubal cannulation: an alternative to *in vitro* fertilization for patients with tubal occlusion. *Ther Adv Reprod Health* 2020;14:2633494120954248
- 28 Shen H, Cai M, Chen T, et al. Factors affecting the success of fallopian tube recanalization in treatment of tubal obstructive infertility. *J Int Med Res* 2020;48(12):300060520979218
- 29 Al-Jaroudi D, Herba MJ, Tulandi T. Reproductive performance after selective tubal catheterization. *J Minim Invasive Gynecol* 2005;12(02):150–152
- 30 Thurmond AS, Novy M, Uchida BT, Rösch J. Fallopian tube obstruction: selective salpingography and recanalization. *Work in progress. Radiology* 1987;163(02):511–514