



# Intracranial Interdural and Extradural Cerebellar Convexity Dermoid Cyst: A Case Report of Rare Tumor at the Rarest Location

Manish Kumar Mishra<sup>1</sup>  Vikrant Yadav<sup>1</sup> Ravi Shekhar Pradhan<sup>1</sup> Ravi Shankar Prasad<sup>1</sup>

<sup>1</sup>Department of Neurosurgery, Institute of Medical Sciences, Varanasi, U.P., India

Address for correspondence Manish Kumar Mishra, MS, DNB, MRCS (Ed), A-605, French Apartments, Sec 16B, Greater Noida (West), U.P., 201308, India (e-mail: drmanishmishravmmc@gmail.com).

Asian J Neurosurg 2023;18:631–635.

## Abstract

Intracranial dermoid cysts are rare dysembryonic tumors of benign nature. These are uncommon in adults. If present, they are usually located in the midline or along the lines of embryonic fusion. The posterior fossa region is an infrequent site. Extradural or interdural locations are even more rare. In this case report, the authors report a laterally located large posterior fossa right cerebellar convexity interdural and extradural dermoid cyst over the sigmoid sinus. It was managed by totally extradural maximum possible safe decompression with microneurosurgical technique. The authors share their experience of addressing this rare pathology at the rarest location with unusual imaging findings.

## Keywords

- ▶ cerebellar convexity
- ▶ dermoid cyst
- ▶ epidermoid
- ▶ extradural
- ▶ interdural
- ▶ maximum safe decompression
- ▶ microneurosurgery
- ▶ posterior fossa
- ▶ sigmoid sinus
- ▶ total resection

## Introduction

Intracranial dermoid cysts (DCs) are rare dysembryonic tumors of benign nature, accounting for 0.04 to 0.7% of all intracranial space-occupying lesions.<sup>1</sup> Because of their congenital origin, they are mostly seen in infants and young adults, and comparatively rarely in older age groups.<sup>2</sup> They have a predilection for midline or lines of embryonic fusion. The common locations are cisternal spaces, mainly in the cerebellopontine angle and the parasellar cisterns. DCs of the suboccipital and occipital

regions are uncommon. If present, they are remarkably in midline within the vermis or in the fourth ventricle. Laterally located intracerebellar dermoids are also reported.<sup>3</sup> DCs of interdural space or extradural space are infrequent and only few cases have been reported.<sup>1,2,4</sup> Herein, the authors present an interesting case of a large cerebellar convexity DC with both interdural and extradural components, compromising venous drainage of the ipsilateral transverse and sigmoid sinus. The patient was managed successfully by microneurosurgical decompression.

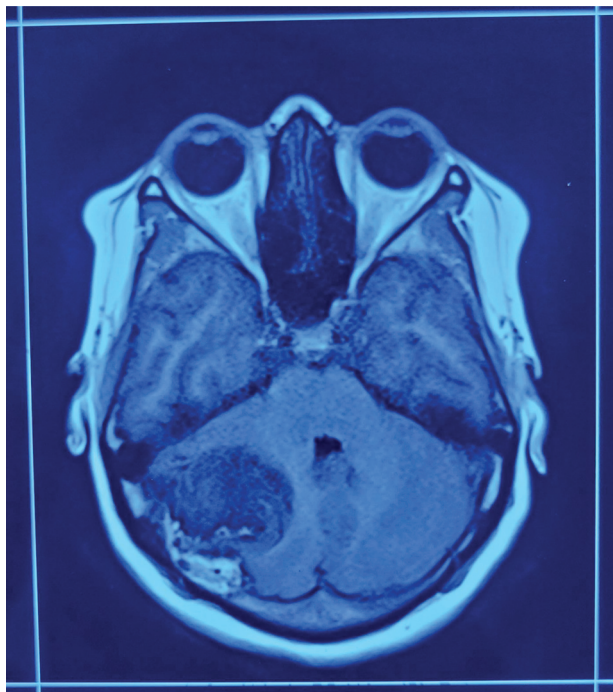
article published online  
September 22, 2023

DOI <https://doi.org/10.1055/s-0043-1771325>.  
ISSN 2248-9614.

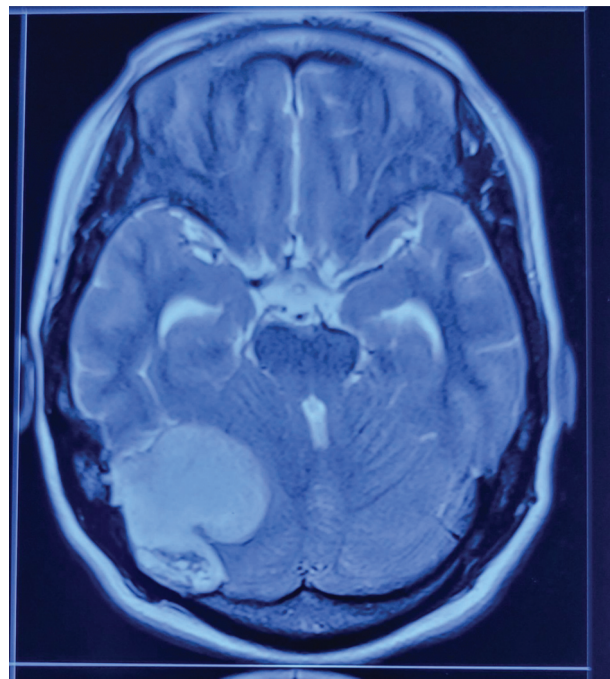
© 2023. Asian Congress of Neurological Surgeons. All rights reserved.

This is an open access article published by Thieme under the terms of the Creative Commons Attribution-NonDerivative-NonCommercial-License, permitting copying and reproduction so long as the original work is given appropriate credit. Contents may not be used for commercial purposes, or adapted, remixed, transformed or built upon. (<https://creativecommons.org/licenses/by-nc-nd/4.0/>)

Thieme Medical and Scientific Publishers Pvt. Ltd., A-12, 2nd Floor, Sector 2, Noida-201301 UP, India



**Fig. 1** T1-weighted sequence showing broad dural-based extra-axial right cerebellar mass lesion with mixed signal intensity with cerebellar midline shift to the left.



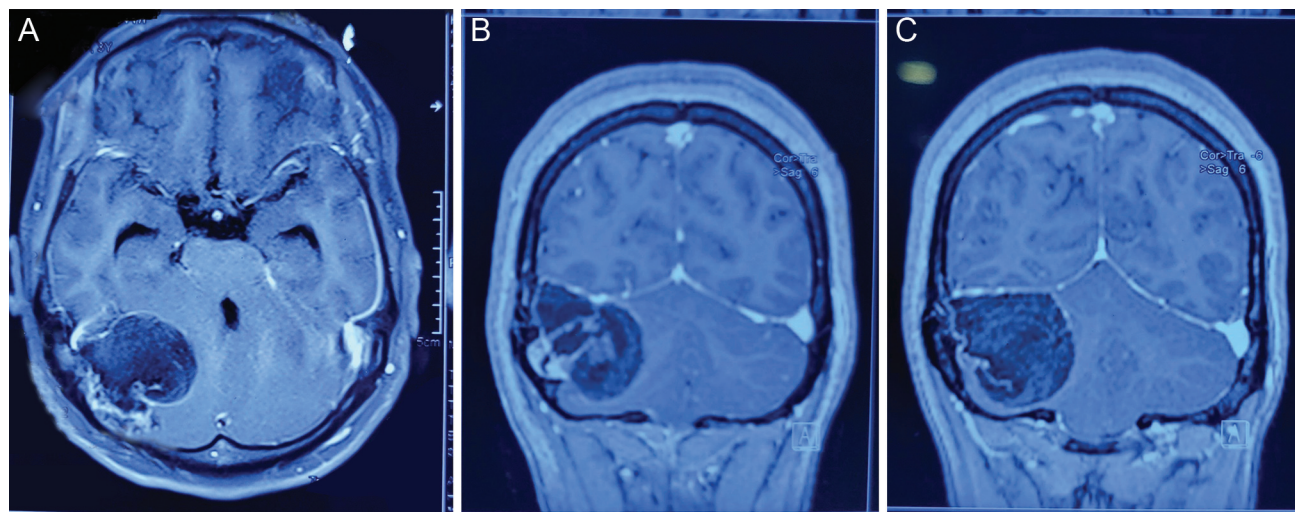
**Fig. 2** T2-weighted sequence showing hyperintense right cerebellar space-occupying lesion.

### Case Report

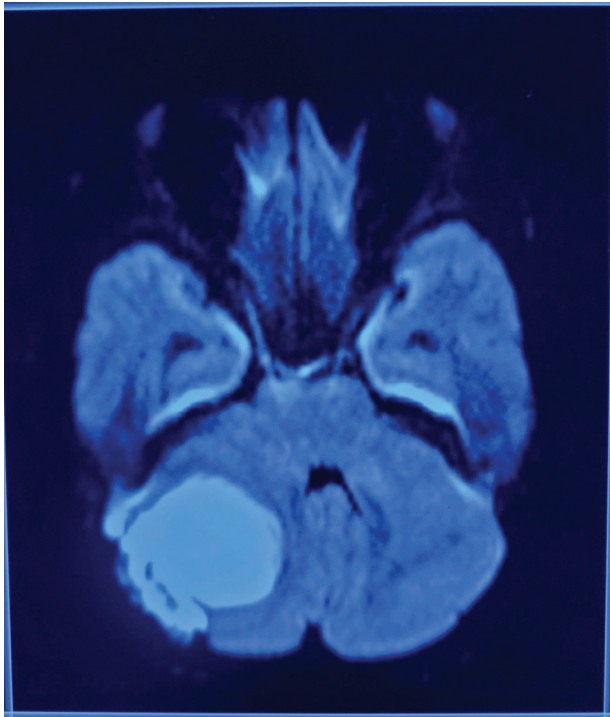
A 34-year-old lady presented to our department with a 4-month history of headache with on and off vomiting. On clinical examination, she had left cerebellar signs. Her magnetic resonance imaging (MRI) revealed a  $35 \times 48 \times 46$  mm broad dural-based extra-axial right cerebellar mass lesion. It had mixed signal intensity on T1 (**Fig. 1**) and was hyperintense on T2 (**Fig. 2**). There were areas of peripheral enhancement on contrast administration (**Fig. 3A–C**) with diffusion restriction on apparent diffusion-weighted (ADW) imaging (**Fig. 4**). There was no obvious surrounding edema.

The right transverse sinus was not appreciable, the fourth ventricle was chinked with mild upstream hydrocephalus, and there was cerebellar midline shift to the left. Magnetic resonance venogram (MRV) showed nonvisualization of the right transverse and sigmoid sinus (**Fig. 5**).

Right paramedian suboccipital craniotomy was contemplated under general anesthesia. Postcraniotomy grayish-white adipose tissues with desquamated debris and hairs were found in the extradural space extending interdurally between the leaves of the tentorium cerebelli (**Figs. 6 and 7**). Maximum possible safe decompression without injuring the dura mater was done (**Fig. 8**). Histopathology



**Fig. 3** (A–C) Postcontrast magnetic resonance imaging (MRI) brain sequences showing areas of peripheral enhancement. (A) also shows dilated temporal horns of lateral ventricles.

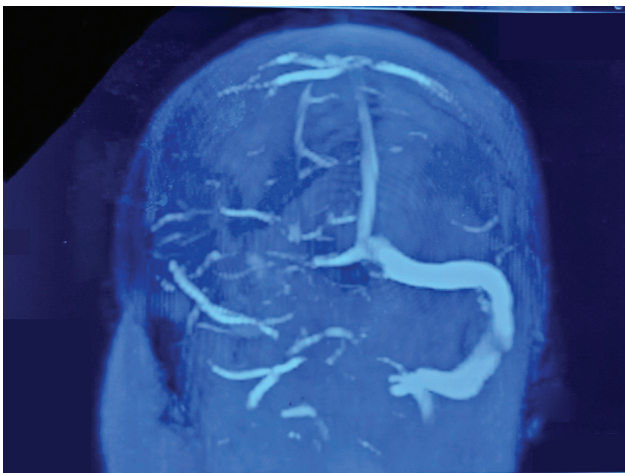


**Fig. 4** Apparent diffusion-weighted (ADW) sequence showing diffusion-restricted right cerebellar mass lesion with cerebellar midline shift to the left.

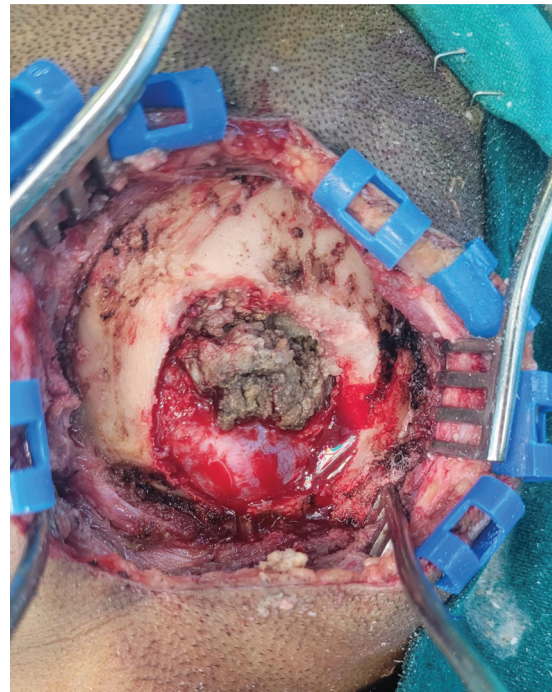
was consistent with DC. Postoperative MRI of the cranium had minimal residual disease adhered at the dural surface of the sinus (► **Fig. 9**). The postoperative course was uneventful.

### Discussion

The history of intracranial dermoid and epidermoid cysts dates back to 1829 when Cruveilhier coined the term “tumeur perlees” for them.<sup>5</sup> These tumors possess both ectodermal and mesodermal components. They are supposed to originate from inclusion of the ectodermal elements within the neural tube during its closure between the third

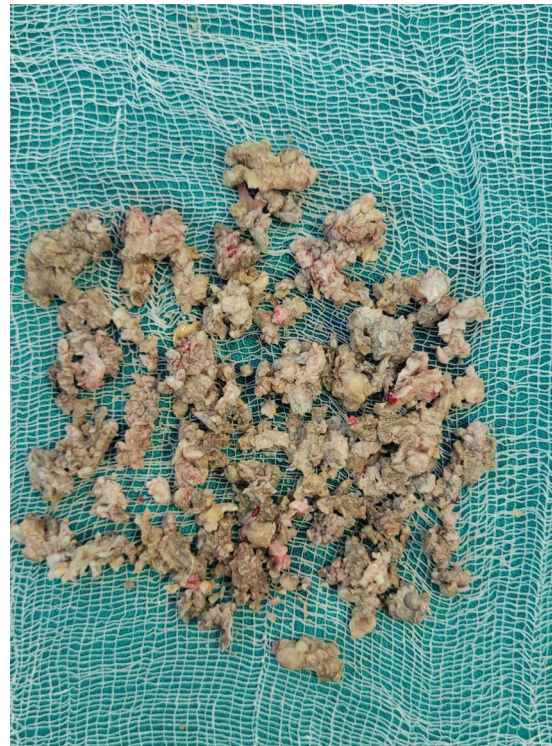

**Fig. 5** Magnetic resonance venogram (MRV) brain showing non-visualization of the right transverse and sigmoid sinus.

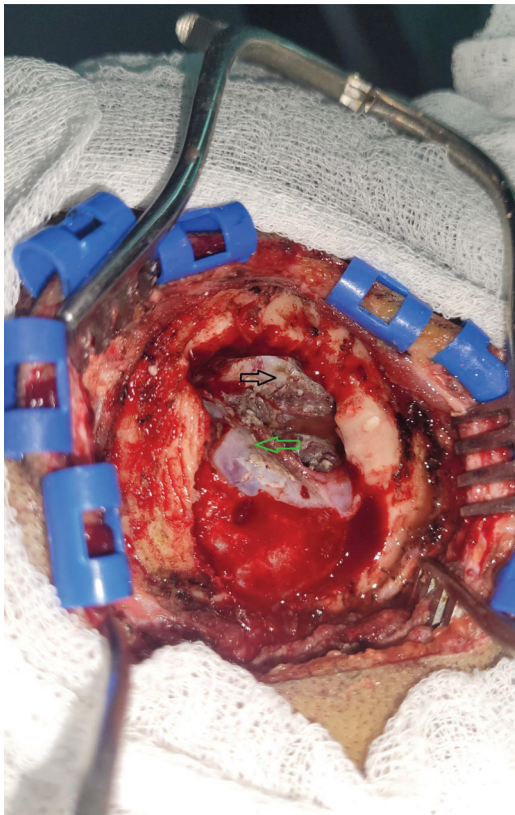


**Fig. 6** Extradural component of cerebellar convexity dermoid cyst following right paramedian suboccipital craniotomy.

and fifth week of embryonic development.<sup>3</sup> This explains their preponderance in midline, in the diploe of the fontanel extracranially, and in the parasellar region intracranially.<sup>6</sup> Traumatic implantation has also been an alternate hypothesis in the genesis of dermoids.<sup>5</sup> Lateral extradural dermoids have been postulated to develop from dural multipotent



**Fig. 7** Specimen showing adipose tissues with desquamated debris and hairs.



**Fig. 8** Postdecompression image showing leaves of the dura mater (green and black arrows).

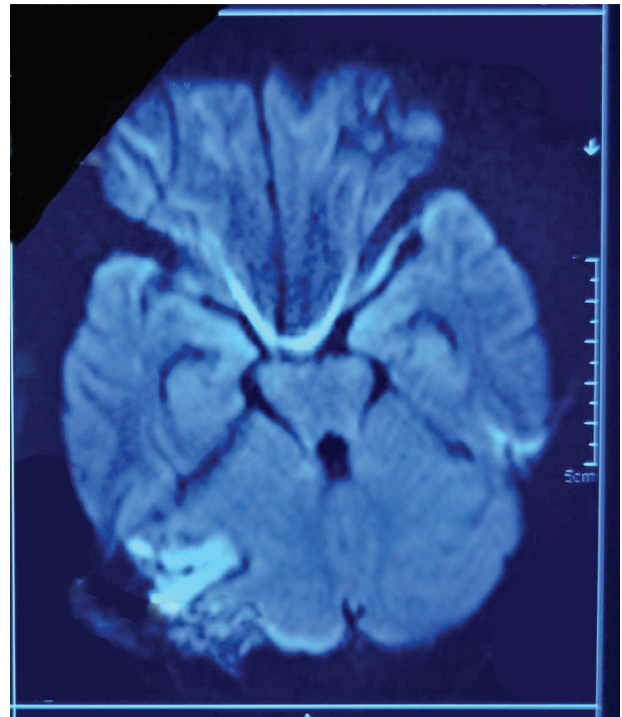
embryonic cells or from translocation of the epithelial cells of developing neovasculature.<sup>7</sup>

These rare tumors account for 0.04 to 0.7% of all intracranial lesions. These are mostly intradural lesions located at the frontobasal, suprasellar, parasellar, etc., regions. Extradural DCs are much rarer and have been reported in the midline of the posterior fossa, anterior fontanel, and orbital region in children.<sup>1,2</sup> Interdural DC in the lateral wall of cavernous sinus has also been cited.<sup>1,4</sup> But DC in the region of cerebellar convexity at an unusual lateral location with both interdural and extradural components holds its paucity. Esaki et al have described an atomically similar case.<sup>8</sup>

These are commonly diagnosed in infants to young adults owing to their congenital origin and association with sinuses and sinus tract infections. Thus, they are relatively rare in the middle-aged or elderly population.<sup>2</sup>

There is a wide array of presenting symptoms of these slow-growing tumors, depending upon the size and location, namely headache, dizziness, seizure, blurring of vision, progressive hearing loss, facial deviation, lower cranial nerve palsy, etc. Rupture may lead to severe aseptic meningitis, ventriculitis, and death.<sup>5</sup>

MRI of the cranium is the investigation of choice. Dermoids show variable relaxation time depending upon fat content. Typically, these are hyperintense on T1- and T2-weighted images due to partially liquified fat content. However, low-/mixed-intensity T1-weighted images can also be found, as in the indexed case, because of solid crystalline cholesterol and



**Fig. 9** Postoperative apparent diffusion-weighted (ADW) sequence showing minimal residual disease (adhered at the dural surface of the sinus).

keratin. Usually, these tumors do not enhance on contrast administration, but there was peripheral enhancement in our case. It can be attributed to peripheral granulation with or without previous infection.<sup>9</sup> These show diffusion restriction in ADW images.

These are benign slow-growing radio-resistant tumors with rare chance of malignant transformation in long-standing cases. Tsugu et al reported a case of squamous cell carcinoma arising in an intracranial DC.<sup>10</sup> Complete surgical excision renders effective treatment for prevention of recurrence and complications. But in cases of extensive adhesion between the cyst wall and the surrounding vital neurovascular structures, subtotal resection can be contemplated.<sup>1,2,4</sup>

## Conclusion

The authors have reported an extremely rare case of laterally located cerebellar convexity DC in a middle-aged lady with both interdural and extradural components with unusual MRI findings in T1-weighted and postcontrast sequence images. Maximum safe resection should be the goal of surgery considering the low risk of recurrence.

### Funding

None.

### Conflict of Interest

None declared.

## References

- 1 Özgür O, Mammadkhanlı O, Doğan İ, Eroğlu Ü, Ünlü AH. Three rare localizations of intracranial dermoid tumors. *Journal of Ankara University Faculty of Medicine*. 2018;71(02):192–196
- 2 Endo H, Murakami K, Watanabe M, Tominaga T. Extradural dermoid cyst of the parasellar region: a case report. *Skull Base Rep* 2011;1(01):003–6
- 3 Benzagmout M, Agharbi S, Chakour K, Chaoui ME. Dermoid cyst of the posterior fossa. *Neurosciences (Riyadh)* 2011;16(02):153–155
- 4 Tun K, Celikmez RC, Okutan O, Gurcan O, Beskonakli E. Dermoid tumour of the lateral wall of the cavernous sinus. *J Clin Neurosci* 2008;15(07):820–823
- 5 Albastaki A, AlThawadi R, Alajaimi J, Ali KF, Almayman T. An intracranial extradural dermoid cyst presenting with two dermal sinuses and an abscess in a child. *Case Rep Neurol Med* 2021: 9917673
- 6 Gormley WB, Tomecek FJ, Qureshi N, Malik GM. Craniocerebral epidermoid and dermoid tumours: a review of 32 cases. *Acta Neurochir (Wien)* 1994;128(1–4):115–121
- 7 Ko SJ, Park KJ, Park DH, Kang SH. Extradural dermoid cyst located in the lateral sphenoid ridge. *Brain Tumor Res Treat* 2014;2(01): 39–42
- 8 Esaki T, Harada Y, Nakao Y, Yamamoto T, Mori K. Unusual case of trigeminal neuralgia caused by remote effect of dermoid cyst in the ipsilateral cerebellar hemisphere. *Clin Neurol Neurosurg* 2013;115(03):339–341
- 9 Eren S, Erman Z, Kadioğlu HH. An extradural dermoid tumour in the posterior fossa with atypical imaging findings. *Eur J Radiol Extra* 2003;45(02):43–46
- 10 Tsugu H, Fukushima T, Hayashi S, Iwaasa M, Matsuda T. Squamous cell carcinoma arising in an intracranial dermoid cyst: case report. *Neurol Med Chir (Tokyo)* 2001;41(04):213–216