



Simplifying the Technique of Awake Brain Surgery in a Condition of Less Equipped Neurosurgical Institution in Uzbekistan

Dilshod Mukhammadvalievich Mamadaliev¹ Gayrat Maratovich Kariev^{1,2}
 Ulugbek Maksudovich Asadullaev¹ Jakhongir Bakhodirovich Yakubov¹
 Kamoliddin Sodikjonovich Zokirov³ Khabibullo Abdukholikovich Khasanov⁴
 Tokhir Makhmudovich Akhmediev⁴ Dmitriy Sergeyeovich Korotkov^{5,6}

¹ Department of Skull Base Surgery, Republican Specialized Scientific-Practical Medical Center of Neurosurgery, Tashkent, Uzbekistan

² Department of Nervous Diseases and Neurosurgery, Peoples Friendship University of Russia, Moscow, Russia

³ Department of Anesthesiology and ICU, Republican Specialized Scientific Practical Medical Center of Neurosurgery, Tashkent, Uzbekistan

⁴ Department of Traumatology, Orthopedics, Military-Field Surgery, and Neurosurgery, Tashkent Medical Academy, Tashkent, Uzbekistan

Address for correspondence Dilshod Mamadaliyev Mukhammadvalievich, MD, Neurosurgeon, Department of Skull base surgery, Republican Specialized Scientific-Practical Medical Center of Neurosurgery, Tashkent, 100190, Uzbekistan (e-mail: dr.mdm@mail.ru).

⁵ Department of Neurosurgery, National Children Medical Center, Tashkent, Uzbekistan

⁶ Federal University of Sao Paulo, Sao Paulo, Brazil

Asian J Neurosurg 2023;18:636–645.

Abstract

Currently, awake craniotomy (AC) is one of the most often employed procedures to map and resect tumors in eloquent brain areas, avoiding the use of general anesthesia (GA) and thereby reducing anesthesia-related complications and cost of surgery. Resource limitations are one of the basic reasons for avoiding AC in low- and middle-income countries (LMICs). The aim of this study is to describe the simplified protocol of awake brain surgery that can be implemented in a limited financial setting in LMICs and to share our first experience. Twenty-five patients diagnosed with tumor of the left frontotemporal lobes, all involving Broca's and Wernicke's areas, were operated on using AC. Brain mapping was executed using mono- and bipolar direct electrical stimulation including cortical and subcortical (axonal) mapping profiles, investigating basically cortical language centers. Neither neuronavigation nor intra-operative magnetic resonance imaging (MRI) was utilized due to financial constraints. AC was performed successfully in 23 of 25 patients, achieving a near-total resection in 16 (69.5%) patients, subtotal resection in 4 patients (17.39%) patients, and partial

Keywords

- ▶ awake craniotomy
- ▶ cortical mapping
- ▶ electrophysiological monitoring
- ▶ language testing
- ▶ brain tumor

article published online
September 22, 2023

DOI <https://doi.org/10.1055/s-0043-1771326>.
ISSN 2248-9614.

© 2023. Asian Congress of Neurological Surgeons. All rights reserved.

This is an open access article published by Thieme under the terms of the Creative Commons Attribution-NonDerivative-NonCommercial-License, permitting copying and reproduction so long as the original work is given appropriate credit. Contents may not be used for commercial purposes, or adapted, remixed, transformed or built upon. (<https://creativecommons.org/licenses/by-nc-nd/4.0/>)

Thieme Medical and Scientific Publishers Pvt. Ltd., A-12, 2nd Floor, Sector 2, Noida-201301 UP, India

resection in 3 (13.04%) patients. In two patients, due to psychological instability—agitation and fear during the awake phase—speech test was not technically possible, so they were reintubated by giving them GA. There was no mortality in the early or postoperative period. In spite of the absence of advanced pre- and intraoperative technologies such as intraoperative MRI and navigation systems, AC can be safely performed in LMICs. These tools along with intraoperative cortical mapping and language testing can guarantee better surgical outcomes and quality of life. However, our study confirms that omitting these tools does not make a huge difference in getting good results with AC and that AC is not absolutely impossible. AC can be performed successfully, preserving eloquent brain areas, with minimum and basic set of the armamentarium like system for cortical and subcortical intraoperative neurostimulation which provides cortical/subcortical brain mapping.

Introduction

“Arise! Awake! And stop not until the goal is reached”

– Swami Vivekananda

Awake craniotomy (AC) is a type of surgical procedure performed under local anesthesia while keeping the patient intentionally conscious and alert during some portion or the whole surgical procedure in order to save higher eloquent functions of the cerebral hemispheres. Patients are only sedated while being awake during the basic part of the surgery, thereby circumventing some of the complications often associated with general anesthesia (GA) and endotracheal (ET) intubation, and therefore need for ventilators, arterial lines, urethral catheters, and staying in intensive care units (ICU) postoperatively.¹ Furthermore, it is very helpful in avoiding morbidity and the side effects of GA. It is especially beneficial in less-resourced, limited financial settings in low- and middle-income countries (LMIC) as it also reduces the length of stay in the ICU.

Evolutionary Development of AC: A Historical Note

The earliest awake brain procedures were applied to the management of epilepsy in ancient times, as evidenced by diverse archeological data from Egypt, where ancient doctors attempted to do a trepanation of the skull, although it is unclear whether drugs that served as GA were used at the time.² Robert Bartholow's experimental operation in 1874 trying to map functional areas of the human brain in an awake patient has led to further investigations. Wilder Penfield was one of the first scientists to strive it for intractable seizures in 1920, and he and Andre Pasquet later published a paper on the use of intermittent anesthesia and surgical peculiarities of AC. However, Victor Horsley from England was the first to perform AC in 1886 by employing specific electric stimulation to localize the epileptic focus. In terms of brain tumor surgery, Archer was the first surgeon to use AC in 1988. H. Duffau later emphasized the importance of preserving not only the cortical centers but also the axonal pathways

that connect the speech centers to the motor areas and other parts of the cortex.³ In 2003, several authors from Japan, India, and Thailand⁴ reported one of the first cases of AC in Asia. Later, in 2007, some Malaysian authors used AC for deep brain stimulation (DBS) surgery in Parkinson's disease.^{4–6}

Present State of the AC Protocols in Use in Developed Countries

For AC, there are three main anesthesia protocols that are widely used (*asleep-awake-asleep*, *asleep-awake-awake*, and *awake-awake-awake*).⁷ The most common technique is monitored conscious sedation, with the other option being asleep-awake-asleep. Predominantly, the established protocols for surgical procedure in most neurosurgical centers from developed countries include rigid head fixation (Mayfield, Sugita, or other head clamps), use of brain navigation system in order to provide accurate skull positioning, and identifying the best angle to attack the lesion.⁸ Intravenous (IV) analgesia and local anesthesia—scalp block—are standard procedures to deliver adequate analgesia. Japanese guidelines for AC recommend using the Wada test to determine the dominant hemisphere stating that despite the availability of noninvasive test like functional magnetic resonance imaging (fMRI) and magnetoencephalography (MEG), they cannot absolutely determine the dominant side, because of the possibility of pseudolocalization.⁹ The goals of anesthetic management are to maintain general homeostasis, reduce interference between anesthetic drugs, and improve the accuracy of electrophysiological recordings. Key role is given to short-acting myorelaxants like rocuronium (1 mg/kg/min) and short-acting opioid analgesic like remifentanyl (0.05 µg/kg/min in 5 minutes). Hypnotic medication is usually IV propofol (2 µg/kg/min). As a rule, laryngeal mask airway (LMA) or ET tube should be used to secure the airway. Usually, later stage of anesthesia is maintained with IV propofol and remifentanyl infusions until awakening. For the awake part of the operation, patients are given dexmedetomidine infusions starting at 0.2 µg/kg/h with the dose titrated up to 0.7 µg/kg/h, as anxiolytic agent.⁸

Is There Hinderances to AC in Low-Resource Countries?

According to the investigations of Mofatteh Mohammad et al where the group of authors have conducted a scoping review under PRISMA²⁰ (Preferred Reporting Items for Systematic Reviews and Meta-Analysis) - Scoping Review of 19 studies (396 patients) utilizing guidelines from three databases (PubMed, Scopus, and Web of Science) deficiency of appropriate infrastructure; deficiency of neurosurgeons, nurses, and anesthesia personnel; long waiting time; and low quality of appropriate training are some of the hindering factors of neurosurgical care in LMICs. The safety and feasibility of AC in low-resource settings where modern and expensive technologies, such as fMRI and intraoperative MRI (iMRI), intraoperative cortical mapping, and electrophysiology, are not available are a serious challenge. Nine studies (47.4%)¹¹⁻¹⁹ reported infrastructure limitations as an obstacle to performing AC operations with one study noting that lack of head pins at their hospital served as an obstacle to AC.²⁰ In our opinion, despite these constraints in technical and equipment facilities, awake surgery can be executed in LMIC settings. We will share our experience in a single institution study.

Aim

The purpose of this study is to concisely describe the simplified protocol of awake brain surgeries that can be implemented in a limited financial setting in LMICs and to share our first experience.

Methods

The study was done at the Republican Scientific Practical Medical Center of Neurosurgery (Tashkent) in 2022 to 2023, including 25 patients with the tumor of the left frontotemporal lobe, involving Broca's and Wernicke's areas.

Patient Selection

All patients were selected according to the criteria accepted by most awake surgery protocols: patients with no speech or sensorimotor deficits, patients with mild disturbances that are tolerable in general speech assessment, patients who are able to understand spoken speech, and patients with had healthy airways. Pre- and postoperative functional outcomes were assessed via a neurological examination.

Preoperative Preparation

All 23 patients were preoperatively prepared psychologically and physiologically by the operating team (assistant neurosurgeons), basically by showing the surgical videos from previous cases, by showing pictures, flash cards, and verb generating ability and semantic function. No special psychiatrists or psychologists were involved. All the patients received carbamazepine (400 mg/d) preoperatively in order to avoid intra-/postoperative seizures. Some institutions preferred using bolus IV fosphenytoin (15 mg/kg) as seizure prophylaxis.²¹ But we realized that oral prescription of carbamazepine is also effective enough. We have used MRI

tractography to evaluate white matter tracts and speech pathways as needed.

Anesthesiologic Features

Although key role is given to short-acting myorelaxants like rocuronium (1 mg/kg) and short-acting opioid analgesics like remifentanyl (0.05 mg/kg in 5 min), due to unavailability of identical alternatives in our country, we used fentanyl titrating its dose. As a sedative medication used IV propofol (2 mg/kg/1). A laryngeal mask device (LMA) is a useful tool to secure the airway. Later stage of anesthesia was maintained with IV propofol and fentanyl infusions until awakening. For the awake part of the operation, patients were given dexmedetomidine infusions starting at 0.2 µg/kg/h with the dose titrated up 0.8 µg/kg/h, as anxiolytic agent.

As for local anesthesia providing scalp block, six nerves of the scalp on the ipsilateral side were blocked using the solution of bupivacaine 0.5% (30 mL) with epinephrine (1:200,000). (nn. supraorbitalis, supratrochlearis, auriculotemporalis, zygomaticotemporalis, nn.occipitalis major et minor).

Setting up OR at a Minimum Basis

Positioning of the patients: For all of our patients, we used the right-sided lateral decubitus or the lateral park bench position, which we found more convenient for patient communication and airway management (→Fig. 1). We have used a single drape to cover the patient's head and body leaving open access to the facial side for communication. As we do not have Mayfield or other type of rigid head fixating clamps, we used a simple horseshoe head rest or head holder. In our opinion, it was even better avoiding the three-point head rigid fixation, as it simplifies airway management for the anesthesiologist during the intubation/extubation phase in the middle of the surgery and creates more comfort for the patient, decreasing the range of anxiety and painful uneasiness after awakening.

Cortical/Subcortical Stimulation and Language Mapping

Neurophysiological brain stimulation in the awake stage of the surgery was conducted using the Inomed Intraoperative Neuromonitoring (IONM) system (Tuttlingen AG, Germany). Basically, stimulation was applied with a bipolar stimulation frequency of 60 Hz, pulse duration of 1 millisecond, and intensity ranging from 3 to 6 mA by the method of Ojemann and Mateer.²² We begin our cortical stimulation from 3 mA then gradually elevating until we identify positive mapping sign- aphasia/dysphasia, if neurophysiologist detect after discharge potentials, we stop increasing current strength. In our experience, usually maximum amperage needed to stimulate cortex was 6 mA. And no seizure occurred. Positive mapping zones were marked with square sheets of paper. The loci around the area of interest showing no clinical signs of dysphasia are marked as negative zones, and corticectomy can be performed safely in these areas. There was no significant mass effect on the sensorimotor tracts or related clinical presentations, so we decided to map only the language cortex. No speech therapists or neuropsychologists were

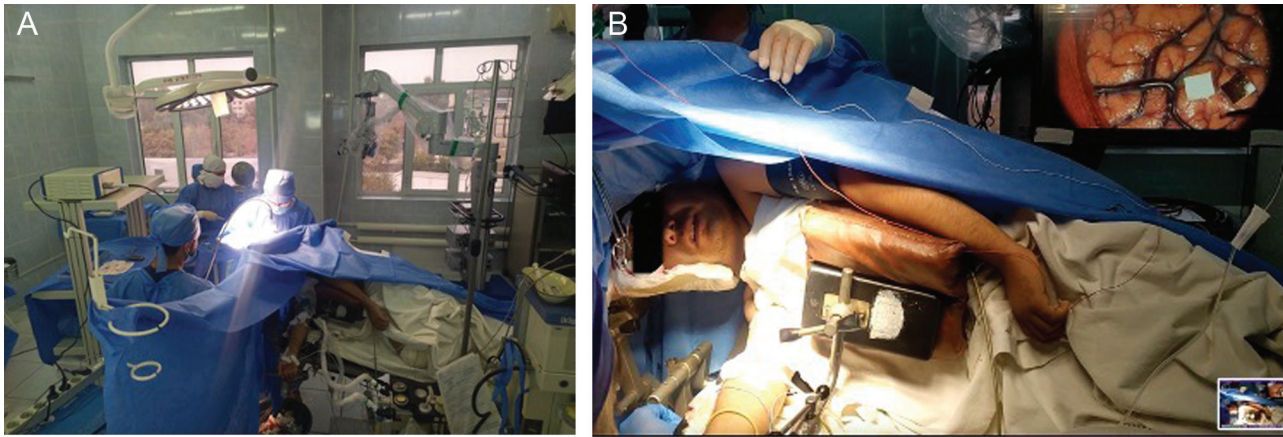


Fig. 1 (A) Operating room setup and patient's position. (B) The patient is awakened, and the language mapping is started.

involved in our surgeries since language functions were tested by a third assistant neurosurgeon standing nearby, using the standard speech test to evaluate object naming, verb generation, calculus, semantic association, etc.

Intraoperative Neuropsychological Tasks

All the patients underwent preoperative and intraoperative neuropsychological assessment tests. We recorded the results of the tasks before and after stimulation of the left frontotemporal area where the tumor was located. A task is considered to be successfully completed if the patient answers correctly to the task questions and “failed” if he or she answers wrongly or shows symptoms of clear dysphasia or fails to the answer, which is denominated as “speech arrest.” Intraoperative tasks included counting numbers from 1 to 10 and reverse counting from 10 to 1, object naming test (household objects and pets), pyramid and palm tree test (PPTT) for a semantic association test, word repetition test to check transcortical speech, and simultaneous left leg movement to check multitasking capability. During resection of the tumor, the arcuate fasciculus was stimulated to check for phonological disorder and mental activity, and the superior longitudinal fasciculus was stimulated to register working memory and attention using mono- and bipolar stimulating profiles.

Results

Tumor Resection

In our study, AC was successfully performed in 23 of 25 patients, achieving near total resection in 16 (69.5%) patients, subtotal resection in 4 patients (17.39%), and partial resection in 3 (13.04%) patients. Speech test was not possible in two patients due psychological instability—agitation and fear—during the awake phase, so they were reintubated with GA. There was no mortality in early or postoperative period.

Twenty-three cases in our study, tumors resection in the left dominant hemisphere was performed using blunt dissection, bipolar coagulation, and the Cavitron Ultrasonic Surgical Aspirator (CUSA) ultrasonic aspirator (Integra). The extent of tumor resection confirmed was with postop-

erative computed tomography (CT). Sixteen (69.5%) patients had near total resection, 3 patients (13.04%) had partial resection, and 4 patients (17.39%) had subtotal resection. There was no mortality in the early or postoperative period. After language mapping was complete, we reintubated our patients with propofol.

Illustrative Case

We present our first case of awake brain tumor surgery in Uzbekistan. A 55-year-old woman was admitted to our center with headache, slight memory impairment, and general fatigue. The symptoms began 4 months ago, and she had previously seen an oncologist and empirically received 12 days of chemotherapy with temozolomide on the spot. (Unfortunately, they have lost the first MRI series, so we could not present it.) The patient rejected surgical excision and opted for chemotherapy (→Fig. 2A). After 1 month of chemotherapy with temozolomide, there was slight improvements in her neurological status, and her headaches regressed. However, after 4 months, she experienced a severe headache, followed by memory deficit. She underwent brain MRI, which revealed an enlargement of the tumor's margins. She contacted us immediately. She was neurologically examined. She was right-handed and had a slight amnesic disorder. There were no motor or sensory deficits in the limbs.

On May 29, 2021 at the time of admission to our hospital, the volume of the tumor was significantly increased, with signs of hemorrhage within the tumor, causing serious mass effect and peritumoral edema apparent on MRI slices (→Fig. 2B) done the day after her general condition worsened with the symptoms of strong intracranial hypertension and slight amnesic disorders. After discussing the case (her neurological status and present speech abilities) with our team, we decided to utilize the chance of awake brain tumor surgery. Although it was a new procedure for everybody, we prepared all the necessities. The patient was trained by our team undergoing speech tests to control expressive and impressive speech components. There was some nominal dysphasia (about 12% wrong answers), which was in our

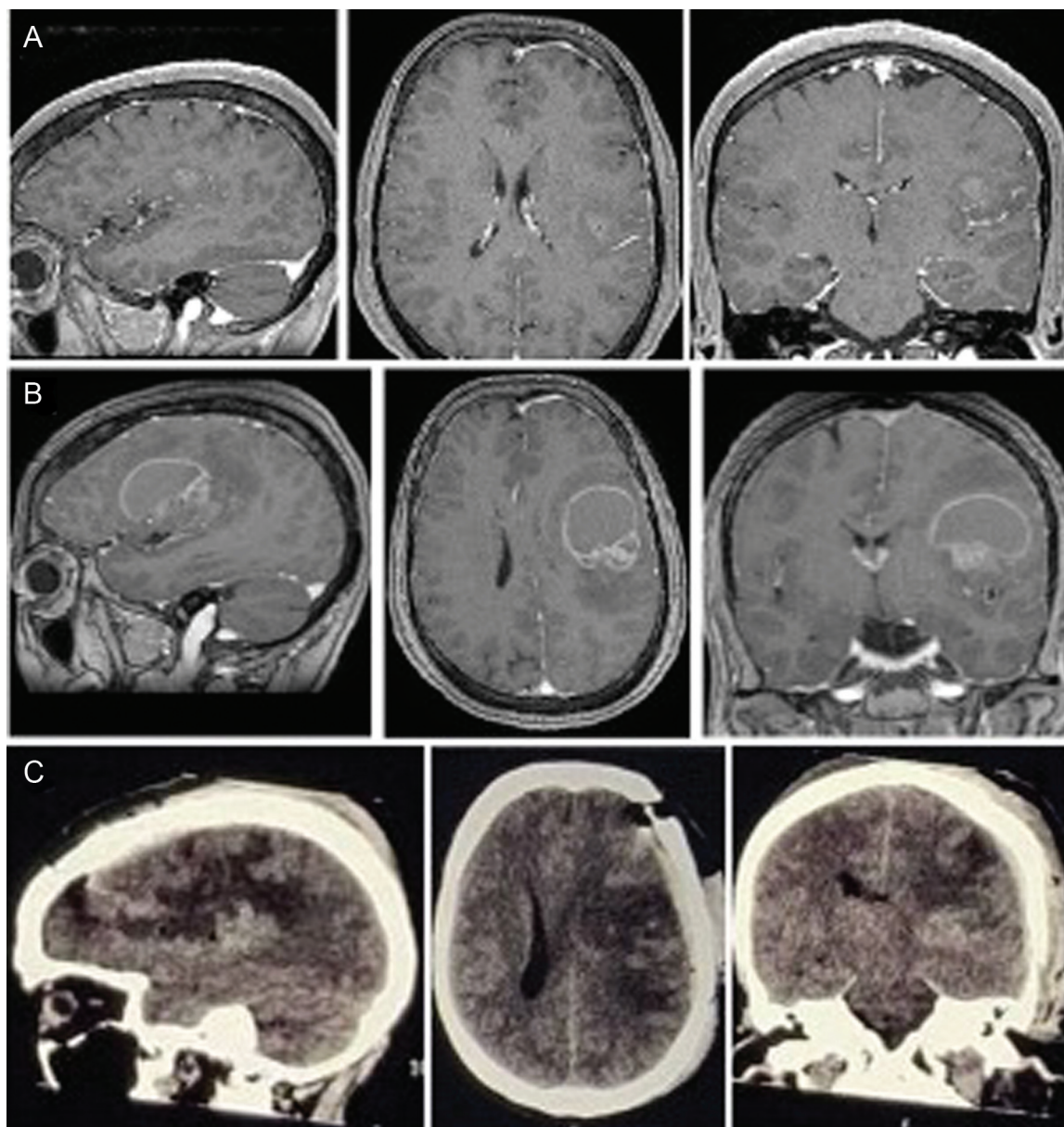


Fig. 2 (A) First magnetic resonance imaging (MRI) after having chemotherapy with temozolomide. Axial and sagittal MRI sequences on fast spoiled gradient echo (FSPGR) detected a 17×14 mm hyperintense lesion on the posterior parts of the inferior frontal gyrus of the frontotemporal area of the left hemisphere. (B) Preoperative MRI from May 29, 2021, showing progressive tumor growth and marked peritumorous edema causing a brain shift of 9.6 mm. MRI showing active growth of the tumor with large cystic component, causing midline shift and mass effect. (C) Early postoperative computed tomography (CT) depicts remnants of the tumor in the peri-insular area and slight brain edema of the tumor bed.

opinion quite tolerable. Nevertheless, she felt comfortable and confident during the awake stage of the operation. The OR was preoperatively prepared; the team consisted of neurosurgeons, a neurophysiologist, and an anesthesiologist. Everybody preoperatively trained and learned their function during the upcoming procedure.

Anesthesia

Anesthesia was done utilizing “asleep-awake-asleep” protocol for our awake brain tumor surgery as planned. During the induction phase of anesthesia, brain relaxation was provided using an IV infusion of mannitol 1 mg/kg and hyperventila-

tion when needed. As an analgetic, fentanyl was used, and dexmedetomidine was injected 5 minutes prior to the awakening phase.

Surgical Procedure

We used a park bench position, softly fixing the head on a horseshoe head rest using tapes, elevating the head side to 30 degrees. Skin electrodes were placed appropriately. After local anesthesia with bupivacaine 0.5% - 30ml with epinephrine (1:200,000), the skin was incised in a regular curvilinear fashion, performing a regular left-sided frontotemporal craniotomy. The dura was opened in a usual horseshoe fashion

and wrapped with lidocaine-soaked cottonoids. The brain was relaxed. The anesthesiologist awakened the patient smoothly as planned. After regaining adequate and clear consciousness, our neurologist started his conversation with the patient. The answers to the given tests were up to 90% correct and she felt no panic or pain. Afterward, we started electrical stimulation of the cortex with a bipolar stimulator, giving a current of 3 mA. As we have not detected speech arrest or signs of disarticulation, we proceeded with 5 mA. Finally, we elicited a region of the inferior frontal gyrus where she had experienced “speech arrest.” After removing the stimulator, her abilities were regained, and we marked this point with sterile material (square-shaped paper). The same procedure was performed to reveal the sensory *speech area of Wernicke*. As soon as there was symptom of semantic aphasia and paraphasia in the subcortical level, we ceased resection of the tumor to avoid damaging the subcortical tracts and the arcuate fasciculus. The tumor was removed in a piecemeal fashion, subtotally. During resection of the deeper parts of the tumor in the vicinity of the arcuate fasciculus, subcortical stimulation was conducted with a monopolar stimulator (with 4–5 mA). Some remnants of the tumor were left to preserve the deep arcuate fibers. The approximate extent of the tumor resection was 80%. After removing the tumor, there was an obvious slight

congestion of the sylvian veins, most probably because of the use of retractors. Pathology report was anaplastic astrocytoma G III.

Postoperative Period

During the postoperative period, the first day was uneventful. She was talking, with slight errors in naming objects (amnesic aphasia). But later, in the morning of the second day, nurses reported that she was not quite alert and responsive. Neurologically, she was somnolent (Glasgow Coma Scale [GCS]: 9–10). CT scan showed a huge edema and brain shift (►Fig. 2C), which pushed us to perform an emergency decompressive craniotomy. The patient awakened successfully after 5 to 6 hours and the postoperative period was uneventful. Postoperative CT shows (►Fig. 3A,B) venous edema bony decompression. Fortunately, her speech performance did not change in the postoperative period. She was discharged on postoperative day 10 with a recommendation to receive adjuvant chemotherapy and radiotherapy. Later, she received the necessary chemotherapy and radiotherapy and came to us with a follow-up MRI after 5 and 11 months showing a very good effect of adjuvant treatment (►Figs. 4 and 5). Her amnesia and speech disorders were significantly improved.

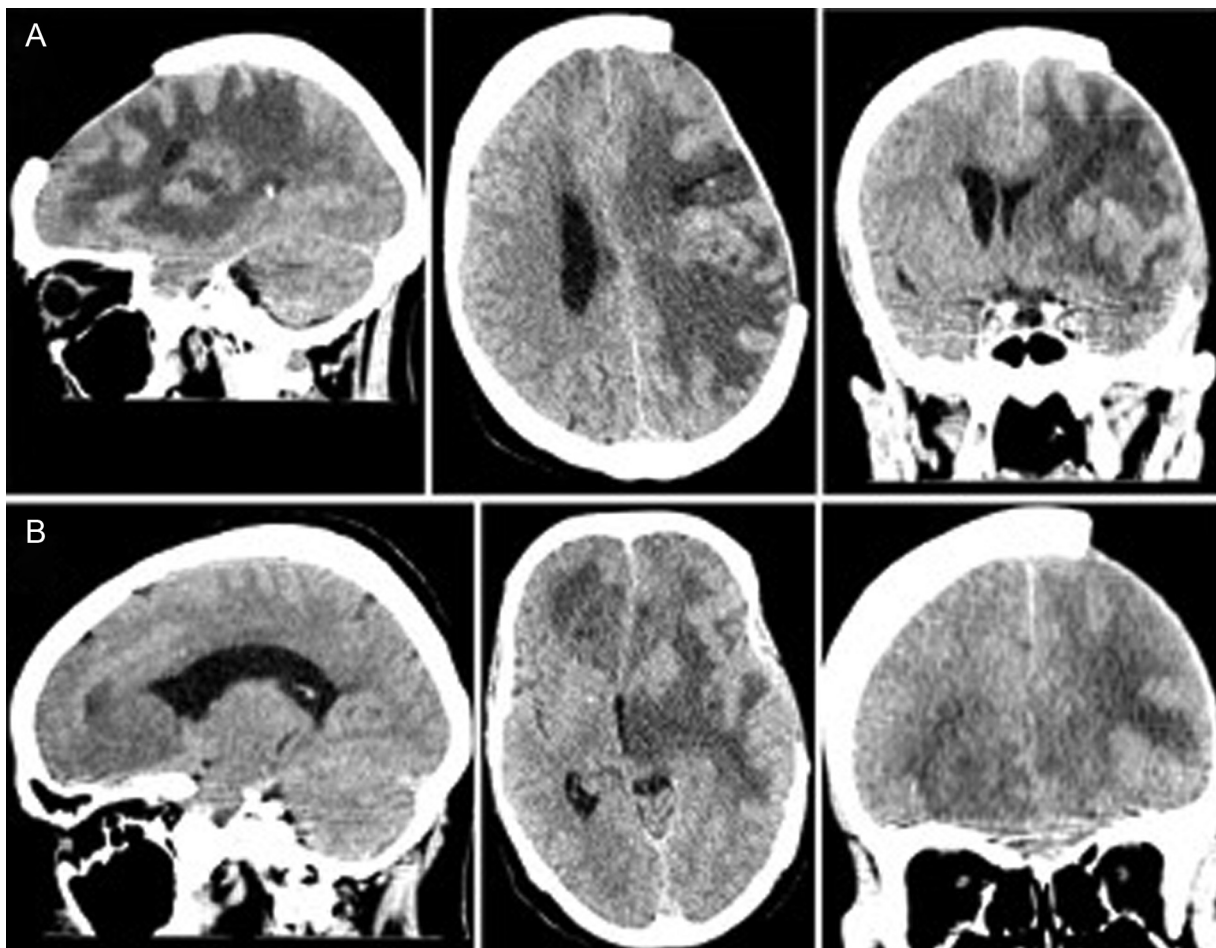


Fig. 3 (A,B) Computed tomography (CT) after performing decompressive craniectomy of the left frontotemporal region. Hyperdense areas of the left frontotemporal lobes show persisting ischemic changes.

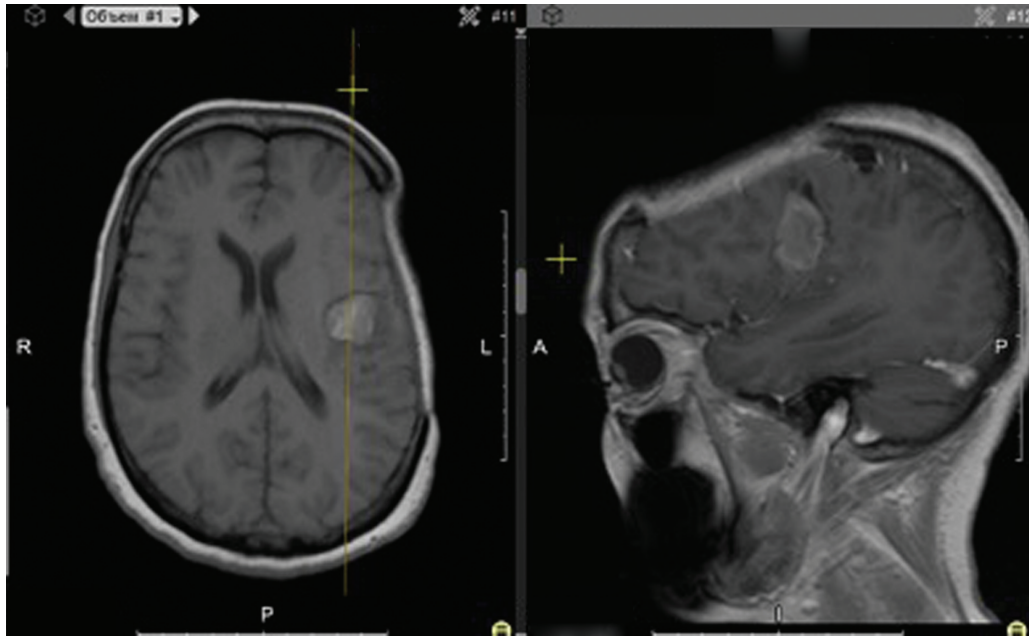


Fig. 4 Follow-up magnetic resonance imaging (MRI) investigation 5 months later after adjuvant chemotherapy depicts a small remnant of the tumor, which was controllable with chemotherapeutic agents.

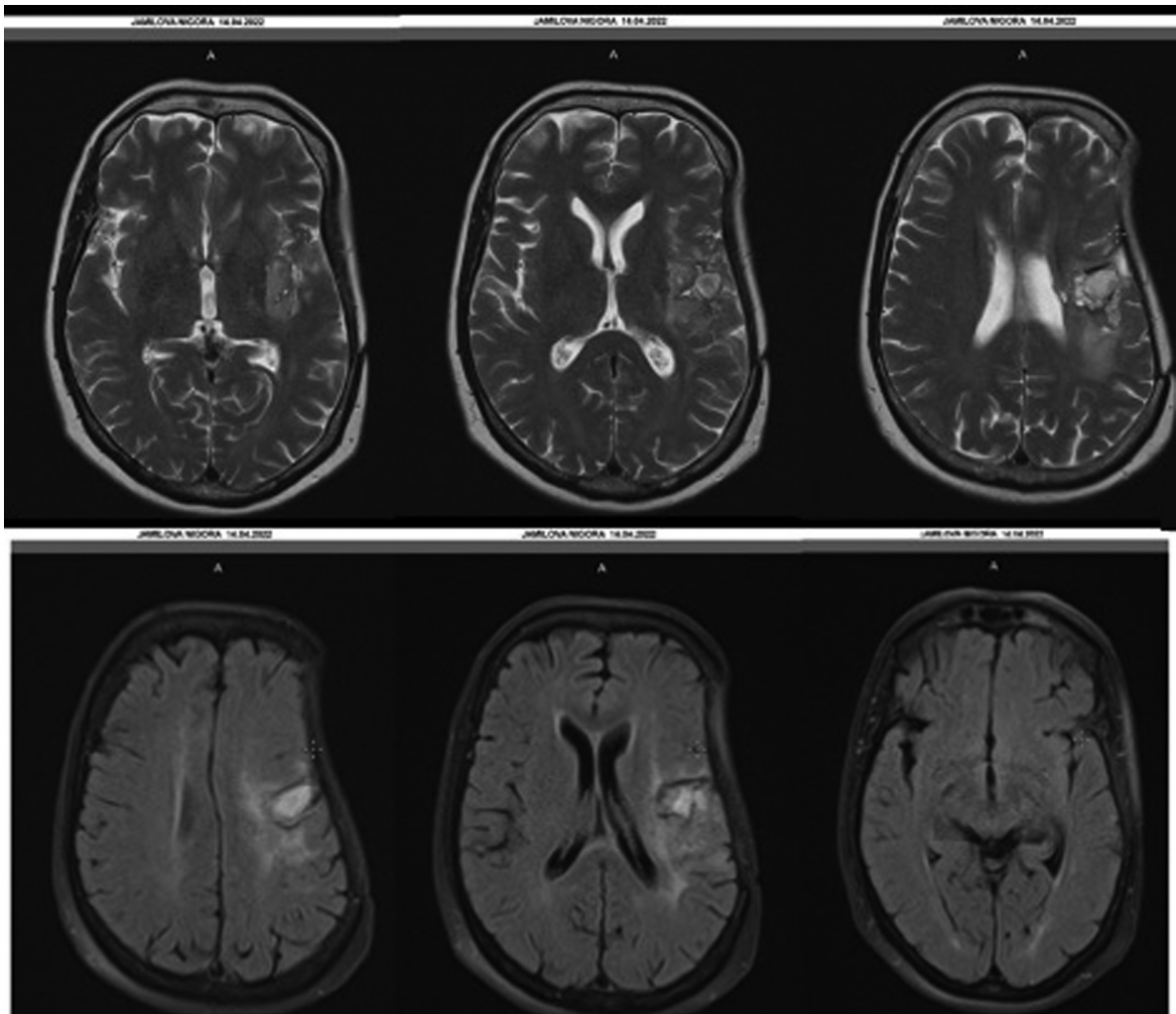


Fig. 5 Follow-up magnetic resonance imaging (MRI) 11 months later (April 14, 2022) after adjuvant chemotherapy. Axial T1- and T2-weighted images show the remnant of the tumor has decreased significantly.

Discussion

Utilization of awake surgery provides preservation of the eloquent cortical centers and subcortical white matter tracts. Direct electrical stimulation of the eloquent cortex serves as a mapping of language, motor, sensory, and other essential higher brain functions like emotional processing, which is localized in the insular area.²³ Using intraoperative motor and sensory evoked potential can help find out the precise localization of the eloquent brain areas.²⁴

Surgical outcomes in such patients are directly related to the quality of tumor excision using both advanced preoperative and intraoperative technologies such as diffusion tensor imaging (DTI), iMRI, and navigation systems. Some studies suggest co-registration of iMRI with preoperative fractional anisotropy color maps is useful for intraoperative localization of the subcortical tracts.²⁵ These tools along with intraoperative cortical mapping and language testing can guarantee better surgical outcomes and quality of life.

The main goal of awake surgery is to achieve a safer and wider resection by preserving the eloquent areas of the brain. However, the extent of resection truly correlates with longer progression-free survival rates of patients with grade 2 and 3 gliomas except for aggressive isocitrate dehydrogenase (IDH) wild type of diffuse astrocytoma and anaplastic astrocytoma.²⁶ Taylor et al highlighted the usefulness of AC even as a routine adjunct procedure not only for eloquent cortex but also for all supratentorial locations regardless of the functionality of the cerebral cortex.²⁷ In addition to this, the effectiveness of awake surgery can be improved by employing iMRI^{28,29} and navigation.³⁰ For sure, having all high-tech facilities indeed intensifies the quality and extent of resection of tumors in eloquent brain areas. But in our opinion, there are still some adjunct equipment that can be partially abandoned in order to adjust awake surgery protocol in LMIC on a minimum basis, in less equipped conditions without losing the safety and basic philosophy of the procedure.

Comparing the guidelines and protocols provided by several authors, according to the investigated literature, a small number of the patients still complain of pain and anxiety in the postoperative period, which is mostly attributed to the rigid pinning of the skull to a Mayfield head pin.^{8,31–33} Almost all awake surgery protocols recommend the use of rigid head fixation. It provides a stable and still head position, thereby allowing the surgeon to work safely and confidently. At the stage of awakening, many patients feel uncomfortable because their skull is fixed with pins and they unable to move which is a key factor for anxiety. We consider to alleviate this inconvenience and used soft fixation with tapes. In contrast to that, we have used a simple horseshoe head holder, which has many benefits. It serves as a gentle cushion for patient's head, and with its use, airways and laryngeal mask replacement are easily accessed, causing no pain. To protect and avoid undeliberate head movement during awake phase, we use simple medical tapes to softly fix the patients head, which are applied loosely and softly. In our

cases, due to an absence of iMRI, navigation system, and preoperative DTI studies, our main goal was a bit limited. We performed an awake surgery for the first time in the history of Uzbekistan, and we initially decided to preserve the language function. These inconveniences with pre- and intraoperative assessment along with intraoperative language and movement testing limited our success in terms of maximum resection in order to avoid damaging the descending motor pathways in the corona radiata, which might be closer to or within the tumor. This resulted in a shortening of tumor progression and the patient experienced further tumor growth even after chemotherapy and radiation therapy. Even a recent report³⁰ suggested that awake surgery might not be realized in developing countries for the next several years. However, our experience shows that this procedure can be utilized in these conditions as well. The example of an awake surgery in our report proves that procedures with limited technologies can be helpful for patients with gliomas in the eloquent areas of the brain since it at least could help preserve the language and movement function by achieving a safer maximum resection compared to conventional brain tumor surgery.

Summarizing the above-reviewed literature and our team's experience in this direction, we highlights some points in this regard as following section.

Conclusion

High-grade gliomas within the functional areas of the brain usually penetrate into the critical subcortical tracts that are responsible for complex high brain functions. These tumors often represent multiple symptoms such as language and movement problems, especially involving the eloquent brain areas. While patients with severe preoperative speech disturbances cannot qualify for awake surgery, patients with mild or asymptomatic patients are candidates for awake surgery. Although, LMICs do not have these high-tech facilities, we should not wait for it. We need to improve our current state and go further to reach our goals and alternative ways. Intraoperative cortical mapping and language testing with awake surgery can be affordable, and even employing them without the above-mentioned tools can lead to better outcomes in terms of preservation of language and movements compared to conventional brain tumor surgical procedures.

Simplifying the Technique in the Setting of Limited Financial Conditions

- Performing awake brain surgery is necessary and feasible even in limited financial settings.
- There is no need for a rigid head fixation during surgical procedures since adequate scalp block with long-acting anesthetic agent provides smooth and comfortable procedure while also eliminating any possible range of pain and discomfort for the patient. In our case series, we have used only medical tape to provide gentle and soft fixation.

- There is no need for remifentanyl, since timely titration of an ordinary fentanyl can sustain pre-awake anesthesia if well calculated by the anesthesiologist.
- There is no need for neuronavigation. Good knowledge of craniometric points and intraoperative cortical anatomy along with qualified mapping technique gives enough information at a real time (excluding deep-seated lesions).
- There is no need for intraoperative electroencephalographic (EEG) monitoring, since neurological evaluation of subtle signs of awakening helps in control of (increasing/decreasing) anesthetic agents.

Informed Consent

Activities included in the study were conducted in agreement with applicable regulations. Informed written consent was obtained from patients whose photographs are used in this manuscript.

Conflict of Interest

None declared.

Acknowledgements

We acknowledge our patients and their families for their trust and support. We appreciate the tremendous contribution to this study by our neurosurgical team, anesthesiologists, neurophysiologists, and nurses.

References

- Motomura K, Fujii M, Maesawa S, Kuramitsu S, Natsume A, Wakabayashi T. Association of dorsal inferior frontooccipital fasciculus fibers in the deep parietal lobe with both reading and writing processes: a brain mapping study. *J Neurosurg* 2014;121(01):142–148
- July J, Manninen P, Lai J, Yao Z, Bernstein M. The history of awake craniotomy for brain tumor and its spread into Asia. *Surg Neurol* 2009;71(05):621–624, discussion 624–625
- Duffau H, Gatignol P, Mandonnet E, Peruzzi P, Tzourio-Mazoyer N, Capelle L. New insights into the anatomo-functional connectivity of the semantic system: a study using cortico-subcortical electrostimulations. *Brain* 2005;128(Pt 4):797–810
- Kaewborisutsakul A, Sae-heng S, Kitsiripant C, Benjhawaleemas P. The first awake craniotomy for eloquent glioblastoma in southern Thailand. *J Health Sci Med Res* 2019;38(01). Doi: 10.31584/jhsmr.202077
- Wan Hassan WM. The history of awake craniotomy in hospital universiti sains malaysia. *Malays J Med Sci* 2013;20(05):67–69. PMID: 24643321; PMCID: PMC3957358
- Bonhomme V, Franssen C, Hans P. Awake craniotomy. *Eur J Anaesthesiol* 2009;26(11):906–912
- Singh K, Dua A. *Anesthesia for Awake Craniotomy*. Treasure Island, FL: StatPearls Publishing; 2023
- Shen E, Calandra C, Geralemou S, et al. The Stony Brook awake craniotomy protocol: a technical note. *J Clin Neurosci* 2019; 67:221–225
- Kayama TG. Guidelines committee of the Japan awake surgery conference. The guidelines for awake craniotomy guidelines committee of the Japan awake surgery conference. *Neurol Med Chir (Tokyo)* 2012;52(03):119–141
- Moher D, Liberati A, Tetzlaff J, Altman DG. PRISMA Group. Preferred reporting items for systematic reviews and meta-analyses: the PRISMA statement. *PLoS Med* 2009;6(07):e1000097
- Ali MZ, Fadel NA, Abouldahab HA. Awake craniotomy versus general anesthesia for managing eloquent cortex low-grade gliomas. *Neurosciences (Riyadh)* 2009;14(03):263–272
- Waly S, Nasr Y, Morsy A. Quasi-experiment as an initial experience for conscious sedation in awake craniotomy: dexmedetomidine versus midazolam. *Res Opin Anesth Intensive Care* 2020;7(01):31–40
- Abdelhameed E, Abdelghany MS, Abdelkhalik H, Elatrozy HIS. Awake surgery for lesions near eloquent brain under scalp block and clinical monitoring: experience of single center with limited resources. *Egypt J Neurol Psychiat Neurosurg* 2021;57(01):78
- Idowu OK, Adeleye AO, Amanor-Boadu SD. Awake craniotomy for intracranial lesions: an audit of the anaesthetists' initial experience at the University College Hospital, Ibadan. *Egypt J Anaesth* 2016;32(04):559–564
- Balogun JA, Kayode Idowu O, Obanisola Malomo A. Challenging the myth of outpatient craniotomy for brain tumor in a Sub-Saharan African setting: a case series of two patients in Ibadan, Nigeria. *Surg Neurol Int* 2019;10:71–76
- Okunlola A, Okunlola C, Babalola O, et al. Challenges and prospects of awake craniotomy in a resource-poor setting. *Int J Neuro Brain Dis* 2019;6:17–29
- Okunlola AI, Babalola OF, Okunlola CK, Akinmade A, Abiola P, Orewole TO. Awake craniotomy in neurosurgery: shall we do it more often? *Interdiscip Neurosurg* 2020;21:100770
- Okunlola AI. Awake craniotomy in a Covid-19 positive patient: the challenges and outcome. *Interdiscip Neurosurg* 2021;24:101064
- Benyaich Z, Hajhouji F, Laghmari M, et al. Awake craniotomy with functional mapping for glioma resection in a limited-resource-setting: preliminary experience from a lower-middle income country. *World Neurosurg* 2020;139:200–207
- Mofatteh M, Mashayekhi MS, Arfaie S, Adeleye AO, Jolayemi EO, Ghoms NC, Shlobin NA, Morsy AA, Esene IN, Laeke T, Awad AK, Labuschagne JJ, Ruan R, Abebe YN, Jabang JN, Okunlola AI, Barrie U, Lekuya HM, Idi Marcel E, Kabulo KDM, Bankole NDA, Edem IJ, Ikwuegbuenyi CA, Nguembu S, Zolo Y, Bernstein M. Awake craniotomy in Africa: a scoping review of literature and proposed solutions to tackle challenges. *Neurosurgery* 2023;93;02:274–291. Doi: 10.1227/neu.0000000000002453. Epub ahead of print. PMID: 36961213; PMCID: PMC10319364
- Axelsson HW, Latini F, Jemstedt M, Ryttefors M, Zetterling M. Continuous subcortical language mapping in awake glioma surgery. *Front Oncol* 2022;12:947119
- Ojemann G, Mateer C. Human language cortex: localization of memory, syntax, and sequential motor-phoneme identification systems. *Science* 1979;205(4413):1401–1403
- Motomura K, Terasawa Y, Natsume A, et al. Anterior insular cortex stimulation and its effects on emotion recognition. *Brain Struct Funct* 2019;224(06):2167–2181
- Mamadaliev DM, Kariev GM, Asadullaev UM, et al. Awake . brain surgery. neurosurgical and . anesthesiological aspects. *Problems of biology and medicine. Samarkand, Uzbekistan* 2021;6(132): 234–239
- Tamura M, Kurihara H, Saito T, et al. Combining pre-operative diffusion tensor images and intraoperative magnetic resonance images in the navigation is useful for detecting white matter tracts during glioma surgery. *Front Neurol* 2022;12:805952
- Motomura K, Chalise L, Ohka F, et al. Impact of the extent of resection on the survival of patients with grade II and III gliomas using awake brain mapping. *J Neurooncol* 2021;153(02):361–372
- Taylor MD, Bernstein M. Awake craniotomy with brain mapping as the routine surgical approach to treating patients with supratentorial intraaxial tumors: a prospective trial of 200 cases. *J Neurosurg* 1999;90(01):35–41
- Matsumae M, Nishiyama J, Kuroda K. Intraoperative MR. imaging during glioma resection. *Magn Reson Med Sci* 2022;21(01): 148–167

- 29 Motomura K, Natsume A, Iijima K, et al. Surgical benefits of combined awake craniotomy and intraoperative magnetic resonance imaging for gliomas associated with eloquent areas. *J Neurosurg* 2017;127(04):790–797
- 30 Bukhari SS, Shamim MS. Can awake glioma surgery be the new standard of care in developing countries? *Surg Neurol Int* 2020; 11:434
- 31 Danks RA, Rogers M, Aglio LS, Gugino LD, Black PM. Patient tolerance of craniotomy performed with the patient under local anesthesia and monitored conscious sedation. *Neurosurgery* 1998;42(01):28–34, discussion 34–36
- 32 Joswig H, Bratelj D, Brunner T, Jacomet A, Hildebrandt G, Surbeck W. Awake craniotomy: first-year experiences and patient perception. *World Neurosurg* 2016;90:588–596.e2
- 33 Whittle IR, Midgley S, Georges H, Pringle AM, Taylor R. Patient perceptions of “awake” brain tumour surgery. *Acta Neurochir (Wien)* 2005;147(03):275–277, discussion 277