



# Acute Hemorrhagic-Onset Atypical Meningioma: A Report of Two Cases with Emergent Resection Achieving Mid-Term Tumor Control and Neurological Preservation

Takahiro Tsuchiya<sup>1</sup> Yuki Shinya<sup>1,2</sup> Tomohiro Inoue<sup>1,3</sup> Kenta Ohara<sup>1,4</sup> Teppei Morikawa<sup>5</sup>  
Takeo Tanishima<sup>1</sup> Akira Tamura<sup>1</sup> Isamu Saito<sup>1</sup> Hideaki Ono<sup>1,2</sup>

<sup>1</sup>Department of Neurosurgery, Fuji Brain Institute and Hospital, Fujinomiya-shi, Shizuoka, Japan

<sup>2</sup>Department of Neurosurgery, The University of Tokyo Hospital, Tokyo, Japan

<sup>3</sup>Department of Neurosurgery, NTT Medical Center Tokyo, Tokyo, Japan

<sup>4</sup>Department of Neurosurgery, Tokyo Metropolitan Geriatric Hospital and Institute of Gerontology, Tokyo, Japan

<sup>5</sup>Department of Diagnostic Pathology, NTT Medical Center Tokyo, Tokyo, Japan

Address for correspondence Hideaki Ono, MD, Department of Neurosurgery, The University of Tokyo Hospital, 7-3-1 Hongo, Bunkyo-ku, Tokyo 113-8655, Japan (e-mail: onoh@m.u-tokyo.ac.jp).

Asian J Neurosurg 2024;19:526–530.

## Abstract

The majority of meningiomas are slow-growing benign tumors that can potentially be highly vascularized; however, acute hemorrhagic onset is rare. Herein, we describe two patients who presented with disturbance of consciousness and severe hemiplegia due to spontaneous hemorrhage from a falx atypical meningioma. A 49-year-old female presenting with a sudden disturbance of consciousness and severe left hemiplegia was found to have a falx meningioma and acute hemorrhage. Emergent resection achieved neurological relief and tumor control. A 60-year-old female with aphasia and severe right hemiplegia also had falx meningioma and hematoma, and successfully treated by emergent resection. Tumor was diagnosed as atypical meningioma in both cases. Both patients achieved mid-term tumor control for 4 and 7 years. Both patients were treated successfully with emergent surgical resection, and neurological relief and mid-term tumor control (7 and 4 years, respectively) were achieved. Given this success, immediate surgical resection with hematoma evacuation should be considered an acceptable therapeutic option for acute hemorrhagic atypical meningioma.

## Keywords

- ▶ atypical meningioma
- ▶ hemorrhagic onset
- ▶ resection
- ▶ tumor control

article published online  
June 25, 2024

DOI <https://doi.org/10.1055/s-0043-1771328>.  
ISSN 2248-9614.

© 2024. Asian Congress of Neurological Surgeons. All rights reserved.

This is an open access article published by Thieme under the terms of the Creative Commons Attribution-NonDerivative-NonCommercial-License, permitting copying and reproduction so long as the original work is given appropriate credit. Contents may not be used for commercial purposes, or adapted, remixed, transformed or built upon. (<https://creativecommons.org/licenses/by-nc-nd/4.0/>)

Thieme Medical and Scientific Publishers Pvt. Ltd., A-12, 2nd Floor, Sector 2, Noida-201301 UP, India

## Introduction

Meningiomas are benign brain tumors that typically grow slowly and, therefore, do not usually require emergency therapeutic intervention.<sup>1</sup> Thus, adequate radiological follow-up and therapeutic intervention at the appropriate time are necessary, and a thorough therapeutic strategy is crucial before surgical intervention.<sup>2</sup> However, in rare cases, meningiomas can present with acute hemorrhage, with a reported incidence of 0.5 to 2.4%, which results in the need for emergency intervention.<sup>1,3-6</sup> The pathophysiology and clinical course of spontaneous hemorrhage from meningiomas are still not fully elucidated owing to its rarity; therefore, there is no definitive evidence-based consensus, and treatment interventions for hemorrhagic meningiomas need to be tailored to individual cases.

Here, we describe two patients who presented with acute hemorrhage from an atypical falx meningioma that was successfully treated with emergency surgical resection, achieving mid-term tumor control.

## Case Presentation

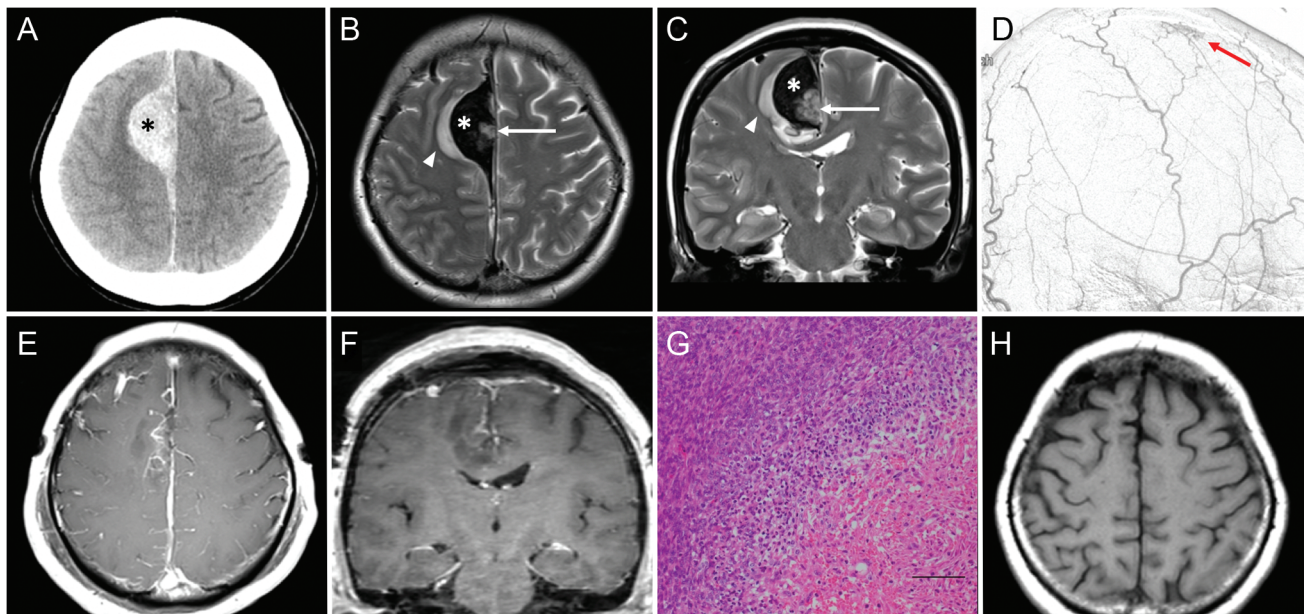
### Case 1

A 49-year-old woman presented with a sudden disturbance of consciousness and left hemiplegia, with a Glasgow Coma Scale (GCS) score of 14. Plain computed tomography (CT) of the head revealed an acute hemorrhage along the falx cerebri, with a maximum diameter of 40 mm (►Fig. 1A). T2-weighted magnetic resonance imaging (MRI) demon-

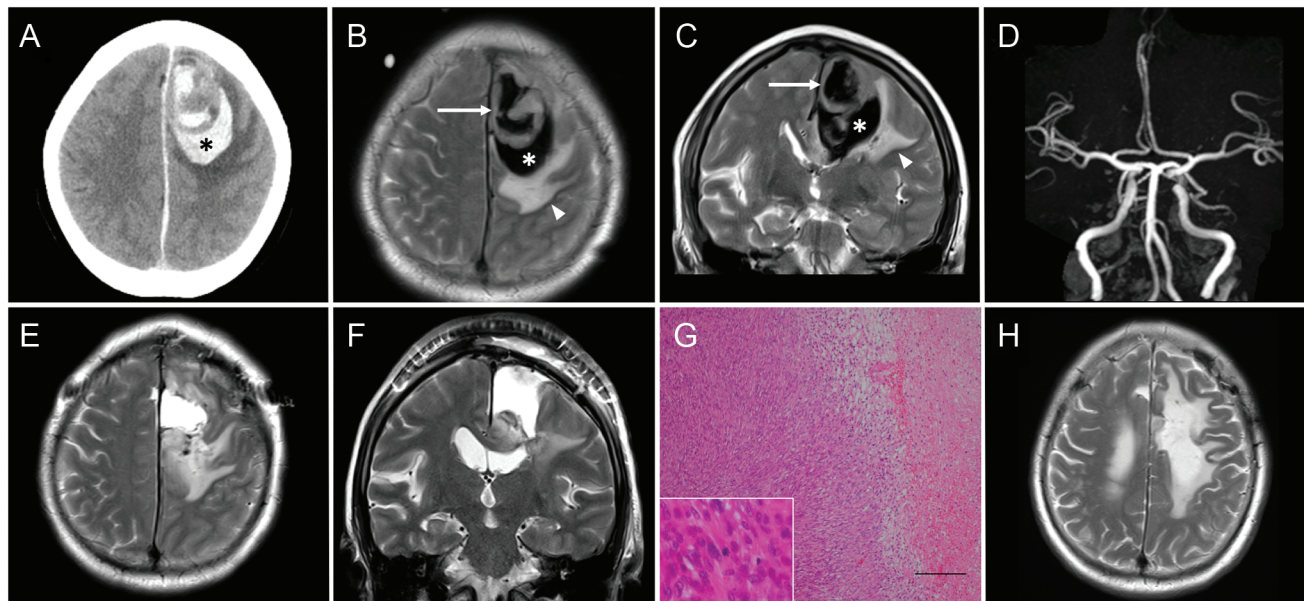
strated a tumor attached to the falx cerebri in the hemorrhage (►Fig. 1B,C). Furthermore, the hematoma compressed the right frontal lobe, causing cerebral edema. Digital subtraction angiography revealed a tumor feeding from the right superficial temporal artery (►Fig. 1D). No other abnormal findings, such as cerebral venous occlusion, were identified. The patient did not have any abnormal laboratory data (such as coagulation dysfunctions) or a history of trauma or radiation exposure. Based on these findings, we diagnosed hemorrhage from the tumor, probably a falx meningioma, and planned an emergency surgical resection via an inter-hemispheric approach on the admission day, aiming to achieve immediate neurological relief.

After the induction of general anesthesia, the patient was placed in the supine position and fixed with a Mayfield 3-point head holder. Motor- and somatosensory-evoked potentials were monitored throughout the surgery.

After craniotomy, the hematoma was first removed. The tumor was indeed attached to the falx cerebri, and it was completely resected along with the attached dura (Simpson grade I; ►Fig. 1E,F). There was no tumor involvement of the superior sagittal sinus. Microscopically, spindle-shaped tumor cells with high cellularity and proliferation in a fascicular or storiform arrangement and psammoma bodies were observed. Tumor necrosis and hemorrhage were also observed. The mitotic count was 3 per 10 high-power fields (HPFs). The tumor was diagnosed as an atypical meningioma (►Fig. 1G). The Ki-67 index was 10%. Pathological diagnosis was based on the 2016 World Health Organization (WHO) classification.<sup>7</sup> The postoperative course was uneventful,



**Fig. 1** Pre- and postoperative findings of case 1. (A) Preoperative computed tomography revealed an acute hemorrhage with a maximum diameter of 40 mm (asterisk) along the falx cerebri. (B,C) Axial (B) and coronal (C) T2-weighted magnetic resonance imaging revealed a tumor attached to the falx cerebri (arrow) and the acute hemorrhage (asterisk) forcefully compressing the right frontal lobe, causing cerebral edema (arrowhead). (D) Digital subtraction angiography revealed that the tumor received a blood supply from the right superficial temporal artery (arrow). (E,F) Postoperative gadolinium-enhanced T1-weighted magnetic resonance imaging revealed the adequate hematoma evacuation and complete resection of the tumor and the attached falx cerebri (a: axial, b: coronal). (G) Microscopical evaluation revealed spindle-shaped tumor cells with high cellularity, proliferating in a fascicular arrangement. Tumor necrosis and hemorrhage were also observed (right bottom). Bar: 100  $\mu$ m. (H) T1-weighted magnetic resonance imaging, 46 months after surgery, revealed no recurrence of the tumor.



**Fig. 2** Pre- and postoperative findings of case 2. (A) Preoperative computed tomography revealed an acute hemorrhage with a maximum diameter of 52 mm (asterisk) along the falx cerebri. (B,C) Axial (B) and coronal (C) T2-weighted magnetic resonance (MR) imaging revealed that the tumor was attached to the falx cerebri (arrow) and that the acute hemorrhage (asterisk) was strongly compressing the left frontal lobe, causing cerebral edema (arrowhead). (D) No vascular malformations were evident upon MR angiography. (E,F) Postoperative T2-weighted MR imaging revealed adequate hematoma evacuation and complete resection of the tumor and the attached falx cerebri (a: axial, b: coronal). (G) Microscopic evaluation revealed spindle-shaped tumor cells, proliferating in a fascicular arrangement. Tumor necrosis and hemorrhage were also observed (right). The inset shows a mitotic figure. Bar: 200  $\mu$ m. (H) T2-weighted MR imaging, 85 months after surgery, revealed no recurrence of the tumor.

with significant improvement of the patient's left hemiplegia. At discharge, her cognitive function was evaluated using the Mini Mental State Examination and confirmed to be well maintained (a full score [30/30]). Upon follow-up at 4 years post-surgery, the patient showed no signs of tumor recurrence or neurological dysfunction (**Fig. 1H**).

### Case 2

A 60-year-old woman who presented with aphasia and right hemiplegia, with a GCS score of 8, was emergently transported to our hospital within 1 day of symptom onset. Plain CT revealed acute hemorrhage along the falx cerebri, with a maximum diameter of 52 mm (**Fig. 2A**). T2-weighted MRI demonstrated that the tumor was attached to the falx cerebri within the hemorrhage (**Fig. 2B,C**). In addition, the hematoma compressed the left frontal lobe, causing cerebral edema. Vascular malformations were not evident on MR angiography (**Fig. 2D**). The patient also did not have any abnormal laboratory data (such as coagulation dysfunctions) or a history of trauma or radiation exposure. We performed emergency surgical resection via an interhemispheric approach using the same procedure on the admission day as in case 1. After craniotomy, the hematoma was first removed. The tumor was indeed attached to the falx cerebri, and it was completely resected along with the attached dura (Simpson grade I; **Fig. 2E,F**). There was no tumor involvement of the superior sagittal sinus.

Microscopically, spindle-shaped tumor cells with high cellularity and proliferation in a fascicular arrangement were observed. Tumor necrosis and hemorrhage were also

observed. The mitotic count was 4 per 10 HPFs. The tumor was diagnosed as an atypical meningioma (**Fig. 2G**). The Ki-67 index was 10%. Pathological diagnosis was based on the 2007 WHO classification.<sup>7</sup> The right hemiplegia improved after surgery and rehabilitation; on discharge, the patient could walk with the support of a cane. Although higher brain dysfunction was observed, the patient was able to return to society. Upon follow-up at 7 years post-surgery, the patient had no signs of tumor recurrence or neurological worsening (**Fig. 2H**).

Written informed consent was obtained from the patients for publication of this case report and any accompanying images.

### Discussion

Here, we report two cases of spontaneous hemorrhage from a falx atypical meningioma presenting with disturbance of consciousness and hemiplegia. Emergency surgical resection contributed to rapid neurological relief and mid-term tumor control.

Since acute hemorrhage from atypical meningioma is remarkably rare, the available information regarding this condition is limited (**Table 1**).<sup>4,8,9</sup> Kuzeyli et al<sup>10</sup> reported that meningiomas have a relatively substantial hemorrhage rate, with 1.6% radiological macroscopic hemorrhages and 7.1% microscopic hemorrhages. Conversely, meningiomas that present with acute hemorrhage and neurological dysfunction are rare, and the reported hemorrhagic incidence is 0.5 to 2.4%.<sup>1,3,5</sup> Regarding the associated risks, the clinical

**Table 1** The outcomes of acute hemorrhagic caused by atypical meningioma in previous cases and the present case

| Author, Year                                 | Age | Sex | Tumor location | Prior radiotherapy | Treatment | Postoperative surgical morbidity | K <sub>i</sub> -67 index | Follow-up (months) |
|--|-----|-----|----------------|--------------------|-----------|----------------------------------|--------------------------|--------------------|
| Munivenkatappa and Shukla, 2014 <sup>4</sup> | 65  | F   | Convexity      | None               | GTR + HE  | None                             | NA                       | 1                  |
| Mangubat and Byrne, 2010 <sup>9</sup>        | 62  | F   | Petroclivus    | GKS                | GTR + HE  | None                             | 14%                      | 6                  |
| Lin and Shen, 2016 <sup>8</sup>              | 63  | F   | Convexity      | None               | GTR       | None                             | 10%                      | 1                  |
| Case 1                                       | 49  | F   | Falx           | None               | GTR + HE  | None                             | 10%                      | 46                 |
| Case 2                                       | 60  | F   | Falx           | None               | GTR + HE  | None                             | 10%                      | 85                 |

Abbreviations: F, female; GKS, gamma knife radiosurgery; GTR, gross total resection; HE, hematoma evacuation; NA, not available.

features of patients aged more than 70 years or less than 30 years, the presence of hypertension, anticoagulation therapy, head trauma, serotonin-modulating therapy, and high-dose estrogen replacement have been reported.<sup>6,11</sup> Intraventricularly, convexity, parasagittal, and falx cerebri tumors, and those that are malignant, fibrous, mesotheliomatous, or angioblastic are most likely to cause tumor-related hemorrhage.<sup>11,12</sup> The associated morbidity rates are high, reportedly accounting for 36% of the overall major morbidity rate.<sup>11</sup> Mortality rates are also high, reportedly reaching up to 21.1%, but falling to 9.5% with surgical intervention.<sup>11</sup> Many clinicians believe that early intervention should be undertaken in patients with lateral ventricular meningioma, even if it is small or the patient is asymptomatic.<sup>12</sup> However, the appropriate timing for surgical intervention remains controversial. Furthermore, the mid- to long-term outcomes of these patients remain unknown.

In both our cases, the tumor location (in the falx cerebri) and pathological features (atypical meningioma with a K<sub>i</sub>-67 index of 10%) were relevant risks. Previously reported risk factors, such as patients aged more than 70 years or less than 30 years, the presence of hypertension, anticoagulation therapy, head trauma, serotonin-modulating therapy, and high-dose estrogen replacement were not applicable in either of our cases.<sup>6,11</sup> The mechanism of bleeding related to meningioma is unclear; however, compensatory enlargement and weakening of blood vessels supplying or draining from the tumor have been proposed as such.<sup>4,11</sup> Emergency surgical intervention might have contributed to preventing morbidity and mortality in our case, and meticulous hematoma evacuation and tumor removal (Simpson grade I, similar to that achieved with planned surgery) might have contributed to the prevention of recurrent hemorrhage<sup>13</sup> and mid-term tumor control of the atypical meningiomas. When treating hemorrhagic meningiomas, consideration of the possibility of malignant meningioma may also be essential.<sup>14</sup> Regarding higher brain dysfunction, cognitive decline is generally observed in a high percentage of patients after intracerebral hemorrhage.<sup>15</sup> In case 1, however, no cognitive decline occurred, owing to the prompt timing of surgical intervention and meticulous tumor removal. In case 2, the patient had collapsed by

the time she was discovered, and approximately a day may have passed between the hemorrhage and arrival at our hospital. In contrast to case 1, failure to promptly decompress the hemorrhage after onset may have led to the sequelae of higher brain dysfunction.

## Conclusion

We describe two patients who presented with acute hemorrhagic onset from an atypical falx meningioma that was successfully treated with emergency surgical resection. Given that adequate neurological relief and mid-term tumor control were achieved, immediate surgical resection with hematoma evacuation may be considered an acceptable therapeutic option for acute hemorrhagic meningioma.

### Patients' Consent

This study was reviewed and approved by the institutional review board. The authors certify that they have obtained all appropriate patient consent forms. In the form, the patient(s) has/have given his/her/their consent for his/her/their images and other clinical information to be reported in the journal. The patients understand that their names and initials will not be published and due efforts will be made to conceal their identity, but anonymity cannot be guaranteed.

### Conflict of Interest

None declared.

## References

- Wakai S, Yamakawa K, Manaka S, Takakura K. Spontaneous intracranial hemorrhage caused by brain tumor: its incidence and clinical significance. *Neurosurgery* 1982;10(04):437-444
- Chen ZY, Zheng CH, Tang Li T, et al. Intracranial meningioma surgery in the elderly (over 65 years): prognostic factors and outcome. *Acta Neurochir (Wien)* 2015;157(09):1549-1557, discussion 1557
- Martínez-Lage JF, Poza M, Martínez M, Esteban JA, Antúnez MC, Sola J. Meningiomas with haemorrhagic onset. *Acta Neurochir (Wien)* 1991;110(3-4):129-132
- Munivenkatappa A, Shukla DP. Atypical meningioma and acute subdural hemorrhage. *J Neurosci Rural Pract* 2014;5(02):203-204

- 5 Niino M, Ishimaru K, Hirano H, Yunoue S, Kuratsu J. Clinicopathological study of meningiomas with haemorrhagic onset. *Acta Neurochir (Wien)* 2003;145(09):767–772
- 6 Pressman E, Penn D, Patel NJ. Intracranial hemorrhage from meningioma: 2 novel risk factors. *World Neurosurg* 2020;135:217–221
- 7 Louis DN, Perry A, Wesseling P, et al. The 2021 WHO classification of tumors of the central nervous system: a summary. *Neuro-oncol* 2021;23(08):1231–1251
- 8 Lin R, Shen C. Meningioma with purely intratumoral hemorrhage mimicked intracerebral hemorrhage: case report and literature review. *J Med Sci* 2016;36(04):158–161
- 9 Mangubat EZ, Byrne RW. Major intratumoral hemorrhage of a petroclival atypical meningioma: case report and review of literature. *Skull Base* 2010;20(06):469–474
- 10 Kuzeyli K, Cakir E, Usul H, et al. Intratumoral haemorrhage: a clinical study. *J Clin Neurosci* 2004;11(05):490–492
- 11 Bosnjak R, Derham C, Popović M, Ravnik J. Spontaneous intracranial meningioma bleeding: clinicopathological features and outcome. *J Neurosurg* 2005;103(03):473–484
- 12 Sumi K, Suma T, Yoshida R, et al. Massive intracranial hemorrhage caused by intraventricular meningioma: case report. *BMC Neurol* 2021;21(01):25
- 13 Lefranc F, Nagy N, Dewitte O, Balériaux D, Brotchi J. Intracranial meningiomas revealed by non-traumatic subdural haematomas: a series of four cases. *Acta Neurochir (Wien)* 2001;143(10):977–982, discussion 982–983
- 14 Abolfotoh M, Brzezicki G, Fiester P, Tavanaiepour D. A rare case of life-threatening multicompartmental spontaneous intracranial hemorrhage from a grade 1 convexity meningioma. *Cureus* 2021;13(11):e19178
- 15 Pasi M, Sugita L, Xiong L, et al. Association of cerebral small vessel disease and cognitive decline after intracerebral hemorrhage. *Neurology* 2021;96(02):e182–e192